



HAL
open science

Tendon transfers to restore elbow flexion

A. Cambon-Binder, M. Chammas, B. Coulet, C. Lazerges, M.-N. Thauray

► **To cite this version:**

A. Cambon-Binder, M. Chammas, B. Coulet, C. Lazerges, M.-N. Thauray. Tendon transfers to restore elbow flexion. *Hand Surgery and Rehabilitation*, 2022, 41, pp.S76-S82. 10.1016/j.hansur.2020.09.015 . hal-04542416

HAL Id: hal-04542416

<https://hal.science/hal-04542416v1>

Submitted on 22 Jul 2024

HAL is a multi-disciplinary open access archive for the deposit and dissemination of scientific research documents, whether they are published or not. The documents may come from teaching and research institutions in France or abroad, or from public or private research centers.

L'archive ouverte pluridisciplinaire **HAL**, est destinée au dépôt et à la diffusion de documents scientifiques de niveau recherche, publiés ou non, émanant des établissements d'enseignement et de recherche français ou étrangers, des laboratoires publics ou privés.

Copyright

Tendon transfers to restore elbow flexion

Transferts de réanimation de la flexion du coude

Adeline Cambon-Binder¹, Michel Chammas², Bertrand Coulet², Cyril Lazerges²,
Marie-Noëlle Thauray³

1 : Service d'orthopédie et de chirurgie du membre supérieur, Hôpital Saint-Antoine, 184, rue du Faubourg Saint-Antoine, 75012 Paris, France

2 : Service de chirurgie de la main et du membre supérieur, chirurgie des nerfs périphériques Hôpital Lapeyronie, CHU de Montpellier, 371, avenue du Doyen Gaston Giraud, 34295 Montpellier cedex 5, France

3 : Clinique de rééducation et de réadaptation fonctionnelle du Dr Ster. 9, avenue du Dr Jean Ster, 34240 Lamalou-les-Bains, France

Auteur correspondant :

Pr Michel Chammas

Service de chirurgie de la main et du membre supérieur, chirurgie des nerfs périphériques Hôpital Lapeyronie, CHU de Montpellier, 371 Av. du Doyen Gaston Giraud, 34295 Montpellier cedex 5, France

tél : 0467338538

fax : 0467337966

email : m-chammas@chu-montpellier.fr

Conflits d'intérêts :

Les auteurs déclarent ne pas avoir de liens d'intérêts.

Abstract

Elbow flexion paralysis is one of most significant deficiencies in the upper limb. When secondary to brachial plexus palsy or nerve trunk lesions, restoration of elbow flexion by means of early nerve surgery or palliative transfers should be part of a comprehensive treatment plan. Tendon transfers are indicated in long-standing palsies, in those who are poor candidates for nerve surgery or when the results of nerve surgery are inadequate. A regional pedicled muscle transfer is performed if available. In this case, a "strong" donor is preferred (pectoralis major with pectoralis minor transfer, triceps brachii to biceps brachii transfer, or bipolar latissimus dorsi transfer). A "weak" transfer is indicated in patients who have incomplete recovery of elbow flexion (MRC 2 strength): isolated pectoralis minor transfer, medial epicondylar muscle transfer according to Steindler technique, or advancement of biceps brachii tendon on forearm. When no donor muscle is available, a free reinnervated muscle transfer may be indicated if age and nerve regeneration conditions are favorable.

Résumé

Au membre supérieur, la paralysie de la flexion du coude représente l'un des handicaps les plus importants. Lorsqu'elle fait suite à une paralysie du plexus brachial ou des lésions tronculaires multiples, une chirurgie nerveuse directe précoce ou la chirurgie palliative doit être intégrée dans un programme thérapeutique global. Les transferts musculaires sont indiqués en première intention dans les cas tardifs ou chez des patients non-candidats à la chirurgie nerveuse directe, ou en deuxième intention en cas de résultat insuffisant de la chirurgie nerveuse. S'il existe des muscles transférables régionaux, un transfert musculaire pédiculé sera réalisé. Dans ce cas, en l'absence de tout fléchisseur du coude, un transfert "fort" est privilégié (transfert partiel de pectoralis major et de pectoralis minor, transfert du triceps brachii sur le biceps brachii, transfert bipolaire du latissimus dorsi). Un transfert "faible" n'est indiqué qu'en présence de fléchisseurs du coude ayant récupéré

incomplètement à M2 : transfert isolé du pectoralis minor, transfert des muscles épicondyliens médiaux selon Steindler, voire avancement de l'insertion distale du biceps brachii. S'il n'existe pas de muscle transférable, un transfert musculaire libre vascularisé réinnervé peut être indiqué si âge et potentiel de régénération nerveuse le permettent.

Keywords: Elbow flexion paralysis; Latissimus dorsi transfer; Pectoralis major and minor transfer; Steindler; Free vascularized muscle transfer; Brachial plexus; Tendon transfer

Mots-clés : Paralysie de la flexion du coude ; Transfert du latissimus dorsi ; Transfert du pectoralis major et minor ; Steindler ; Transfert libre musculaire réinnervé ; Plexus brachial ; Transfert tendineux

1. Introduction

Elbow flexion is a basic function of the upper limb; its paralysis is especially disabling. The main causes are brachial plexus palsy, lesions to the musculocutaneous nerve and destruction of the muscles that flex the elbow. We will not touch on paralysis due to central nervous system damage or those that happen during the course of progressive neurological diseases. Various muscle transfers can be used to restore elbow flexion [1]. They are indicated as a first-line treatment in patients for whom primary nerve surgery is not possible, or as a secondary treatment if the results of nerve surgery are not satisfactory.

2. Anatomy of elbow flexion

The elbow flexion muscles are separated into two groups (Table 1):

- the main flexor muscles: biceps brachii (BB), brachialis
- the accessory flexors, which are the forearm muscles that insert on the humerus: brachioradialis and the medial and lateral epicondylar muscles.

The innervation of elbow flexion mainly comes from three nerves:

- musculocutaneous nerve (biceps and brachialis)
- radial nerve (brachioradialis and lateral forearm muscles) and a somewhat significant portion of the brachialis in 67% of cases [2]
- median nerve (medial epicondylar muscles, except the flexor carpi ulnaris that is innervated by the ulnar nerve).

The main elbow flexors need the C5 and C6 roots to be intact. The nerve root innervation of the accessory flexors spans from C6 to T1.

The BB also has a supinating action in combination with the supinator muscle, which is innervated by the radial nerve and C5-C6. Thus supination is completely controlled by the C5 and C6 roots.

The contribution of various nerves to elbow flexion force has been determined [2]: the musculocutaneous nerve contributes 42% of elbow flexion force and 47% of supination force; the radial nerve contributes 27% of elbow flexion force and 64% of supination force; the

medial epicondylar muscles contributed 30% to elbow flexion force, thus their action is called a “pseudo-Steindler effect”.

3. Etiology of elbow flexion paralysis

There are three types of neurological causes:

- Total paralysis of the main flexors and total paralysis of the accessory flexors is observed in complete brachial plexus lesions (from C5 to T1). It could also be due to simultaneous median, musculocutaneous and radial nerve lesions secondary to arm amputation or a gunshot wound for instance.
- Total paralysis of the main flexors and partial paralysis of the accessory flexors is most often secondary to high brachial plexus palsy (C5C6 or C5C6C7) and more rarely to lesions of the musculocutaneous and radial nerves (e.g. humerus fracture with large displacement).
- Partial paralysis of the main flexors (BB and brachialis) can be due to a lesion of the lateral cord, or a lesion of the musculocutaneous nerve. The latter can be an iatrogenic injury, especially after bone block surgery for shoulder instability.

The muscle-related causes are muscle destruction in the anterior compartment of the arm, damage secondary to tumor resection, an ischemic origin (compartment syndrome [3], trauma, sequelae of transbrachial replantation [4]), or even a congenital anomaly (congenital absence of elbow flexors, arthrogryposis).

4. Clinical assessment

The clinical evaluation seeks to determine the patient’s demands and needs, to specify whether palliative transfer to revive elbow flexion can be proposed, to identify any contraindications, and to look for prognostic factors to provide patients with information about the expected outcomes.

4.1. Etiology determination

The etiology is determined to establish the chronicity of the deficit and its potential for spontaneous recovery using repeated clinical evaluations, electromyogram and sometimes imaging (looking for pseudomeningocele in brachial plexus palsy cases).

The lack of recovery potential after a nerve lesion must be confirmed before considering doing surgery to restore elbow function. Also, muscle transfer will only be proposed when it is impossible to reinnervate the elbow flexors using a graft or nerve transfer. In cases of non-traumatic nerve damage, a multidisciplinary team is involved in determining the prognosis of the condition and the course of the disease. Progressive deficits are typically contraindications for tendon transfer.

4.2. Assessment of entire upper limb

An analytical muscle evaluation is carried out based on the British Medical Research Council grading system [5], with the goals of identifying which muscles are weak and of measuring the strength of candidate muscles for transfer. A muscle should only be transferred if its strength is graded at 4 or higher.

The range of motion at the elbow is measured to look for stiffness, which may need to be treated before the transfer procedure. While a moderate extensor lag makes it easier to flex the elbow, a flexion deficit is not well tolerated if the hand is functional, and could justify arthrolysis if conservative treatment does not resolve it.

Hand and shoulder function is evaluated, along with the vascular status, skin viability and bone stability.

Lastly, sensory testing is done. One looks for deafferentation or neuralgic pain, which is a contraindication – at least temporarily – to any functional surgery, as it could prevent use of the upper limb.

4.3. Patient needs and contract for objectives

During the multidisciplinary evaluation and discussions with the patient, the treatment goals are laid out. Thus, a functional and sensible hand requires a strong upper limb to be able to

lift heavy objects. In patients' whose hand is not functional, the aim of elbow flexion is to allow them to place their hand on a working surface, to act as a platter and to improve the overall look of the limb, which directly impacts the individuals' quality of life.

5. Treatment indications (Fig. 1)

5.1. Neurological causes of paralysis in the elbow flexors

In brachial plexus palsy cases, elbow flexion is at the top of the hierarchy of functions to re-establish.

Several conditions must be met for a primary nerve procedure to be done. The time to surgery must be as short as possible since the potential for nerve regeneration decreases over time and the target muscles start to atrophy [6]. Unfavorable conditions related to the patient are older age, active smoking habit, presence of local remodeling secondary to the initial trauma or to a prior surgical incision (extra-anatomic bypass).

If direct nerve surgery is possible, either a graft from one of the two superior nerve roots in the direction of the anterior contingent of the superior primary trunk or the musculocutaneous nerve is done [7] if the root is not avulsed, or a nerve transfer is performed while preserving the non-avulsed root for shoulder re-innervation. If there is no graftable root, nerve transfers can be used to reinnervate the BB and brachialis [8]: fascicles from the median nerve and/or ulnar nerve [9] in cases of high palsy or from the intercostal nerves [10] in complete palsy cases.

If the results of the initial nerve surgery are not good enough, too much time has elapsed, or the prognosis for a nerve procedure is poor, palliative surgery is proposed.

The choice of which muscle to transfer depends on the preoperative strength of the various donor muscles and the main and accessory flexor muscles, whether the functional and cosmetic sequelae at the donor site will be acceptable. If there is no elbow flexion, a "strong" transfer is proposed. Conversely, "weak" transfers are used as a supplement for spontaneous reinnervation or after inadequate results of surgery (M2). If there is no donor

muscle in the region, a free vascularized muscle transfer may be indicated if the patient's age and nerve regeneration potential allow it.

A stable shoulder is essential to achieving effective elbow flexion. Thus, glenohumeral fusion is effective at improving elbow flexion strength and must be proposed to patients whose shoulder is paralyzed [11]. In fact, the BB loses some of its strength at the shoulder level if the latter is paralyzed, by reducing the inferior subluxation and inducing internal rotation.

In the case of a progressive neurological disorder, one must not transfer a muscle that could eventually be affected by the disease.

5.2. Muscular causes of paralysis

Only palliative transfers are possible. Their selection mainly depends on the associated soft tissue lesions and the surgeon's preferences in cases when most donor muscles are functional.

6. Strong transfers: indications and techniques

6.1. Bipolar pedicled latissimus dorsi transfer (Fig. 2)

Transfer of the latissimus dorsi (LD) was first described by Schottstaedt et al. [12] and Hovnanian [13] in its monopolar form. Zancolli and Mitre [14] described a bipolar transfer, which is now widely used; however it has been criticized for being too long and tricky to set the tension [15]. Given its volume, an additional skin paddle is often needed. This is also used for monitoring. The LD is frequently affected by superior nerve root palsy, often making it unusable. The best indication for this transfer is destruction of the main flexor muscles [3,16,17]. Its harvesting does not cause any perceptible functional deficit, except in patients who need to use crutches and to make transfers (paraplegics).

The published results of bipolar transfer are good, with 75% of patients able to flex their elbow against 1 kg to 8 kg load [3,16,17].

6.1.1. Anatomy

The LD inserts on the last 3 or 4 ribs, the spinous process of the last 5 or 6 thoracic and lumbar vertebrae, the thoracolumbar fascia, and the posterior third of the iliac crest. It has an additional insertion on the inferior corner of the scapula. It terminates on the medial edge of the intertubercular groove. It produces adduction, retraction and internal rotation of the arm. It is innervated by the thoracodorsal nerve (C6, C7, C8 roots) and vascularized by the thoracodorsal artery.

6.1.2. Surgical technique (Fig. 3)

The patient is installed in a 3/4 supine position with a pad under the buttock and the medial side of the scapula. The surgical approach follows the anterior side of the LD from the iliac crest then makes a zigzag pattern to the axillary fossa. If a skin paddle is needed, it is traced on either side of the pedicle making sure that it corresponds to the muscle deeper down. The anterior side is located. This provides access to the neurovascular bundle, which is an average of 8 to 10 cm from the humeral insertion, located with a neurostimulator. The position of the skin paddle is confirmed (the anterior side is often thought to be more posterior than it really is). It is secured by interrupted sutures to the muscle to protect the perforators. The muscle is released from its proximal insertions and detached from its deep and superficial attachments with careful hemostasis. A running whipstitch on the proximal muscular cross-section can be useful. Once the pedicle has been isolated, the terminal tendon is transected flush with the bone, then secured to the coracoid process by transosseous sutures. The vascularization of the fleshy fibers is evaluated, potentially justifying minimal recutting. The distal fixation is made to the distal biceps tendon and potentially to the upper third of the ulnar crest [3]. The tension is set such that the elbow remains spontaneously in 90° flexion, with the forearm in supination.

In the postoperative course, the patient's arm is immobilized in a splint in 100° flexion for 4 to 6 weeks. Later, rehabilitation will focus on flexion; the recovery of extension will be delayed, leaving a persistent flexion deformity.

6.2. Partial transfer of pectoralis major and pectoralis minor

This transfer, which was described by Tsai et al. [18] combines transposition of the sternocostal bundle of the pectoralis major (PM) in the Clark procedure modified by Merle D'Aubigné [19] with a transposition of the pectoralis minor (Pm).

In superior nerve root palsy, the PM is missing some of its innervation (that of the clavicular head). Adding the Pm reinforces its strength ability. The goal is to preserve all the PM's innervation, which is difficult when using standard dissection, since the Pm and the sternocostal head of the PM have a common neurovascular bundle that partially crosses the Pm before rejoining the PM.

Complete harvesting of the pectoral muscles can reduce the strength of brachiothoracic squeeze [20] although shoulder fusion can compensate for this effect when the shoulder is paralyzed. The main drawbacks of this transfer are the cosmetic sequelae at the donor site in heavily muscled men and the difficult distal fixation due to shortness of the muscles. To get around this problem, the transfer can be extended by an anterior sheath of the rectus abdominis fascia [21] or a fascia lata strip [22].

The published results are generally good with about 75% of patients recovering the ability to flex their elbow against resistance [23].

6.2.1. Anatomy

The PM inserts on the medial two-thirds of the anterior edge of the clavicle (clavicular head) on the anterior side of the sternal manubrium, the cartilage of ribs 2 to 6, and the fascia of the rectus abdominis (sternocostal head). It terminates as an inverse J under the deltoid, on the lateral side of the intertubercular groove; the costosternal portion forms the deep part of the J. It produces adduction, flexion and internal rotation of the arm and is an accessory inspiration muscle. The clavicular head is innervated by the lateral pectoral nerve coming from the anterior division of the superior trunk (C5–C7); the sternocostal head is innervated by the medial pectoral nerve and the pectoral loop (C6–T1). The innervation mostly crosses

the Pm before innervating the PM, hence the benefit of harvesting both the PM and Pm. It is vascularized mainly by the thoracoacromial artery, but also by the lateral thoracic and intercostal arteries.

The Pm inserts on the medial edge of the coracoid process. It terminates on ribs 3 to 5 through three distinct strips near the cartilage along with the fascia covering the intercostal muscles. It lowers the shoulder stump (it closes the costoclavicular squeeze grip) and is an accessory inspiration muscle. It is innervated by the medial pectoral nerve ((C6), **C7, C8**, T1) and vascularized primarily by the lateral thoracic artery and secondarily by the thoracoacromial artery.

6.2.2. Surgical technique (Fig. 3)

The patient is placed supine. The incision follows the inferior edge of the PM on the midline of the sternum until the humeral insertion is reached. The inferior edge of the muscle is lifted to expose the proximal insertion of the Pm and detach it with its digitations, rib periosteum and intercostal fascia. The site where the motor branches cross the Pm to innervate the PM is identified with a neurostimulator. Similarly, the medial pectoral nerve and the thoracoacromial artery are identified laterally relative to the hemi-clavicle. Superficial to the PM, the perimysium is incised at the middle portion of the clavicle to separate the clavicular bundle from the sternocostal bundle. The sternocostal bundle of the PM and Pm are then fully detached with the arm in adduction-antepulsion.

The humeral tendon of the PM is fixed to the coracoid process by transosseous sutures. The BB is located through a broken line incision at the elbow crease, coming back longitudinally on the anterior side of the arm. A subcutaneous tunnel is made towards the proximal incision by making an incision in the brachial fascia. Tension is placed on the two transferred muscles using the traction sutures, then the muscles are retrieved distally. Distal fixation is done with the elbow in 100° flexion, arm in antepulsion-adduction and any rotation, forearm supinated. The Pm is fixed with several nonabsorbable sutures to the muscle belly of the BB. The PM is fixed to the BB tendon and to its muscle belly. The tension is set such that

the elbow remains spontaneously in 50° flexion. The postoperative course is similar to that for LD transfer. Placing the arm in 60° flexion will make it easier to reach the BB tendon [24].

6.3. Triceps brachial

Transfer of the triceps brachii onto the BB according to Bunnell [25] then Carroll & Hill [26] is particularly indicated in cases of triceps–biceps co-contractions, after spontaneous recovery or after nerve surgery. However, there is no compensation for triceps brachii harvesting; thus, patients lose active elbow extension, which is hard to tolerate if they have active elevation above 90°, use crutches or need to do transfers. Consequently, this transfer is not done very often. More recently, isolated transfer of the long head of triceps brachii has been proposed to allow independent elbow extension [27].

6.3.1. Anatomy

The triceps brachii is innervated by the radial nerve (C6C7C8T1).

6.3.2. Surgical technique

The first posterior midline incision goes around the olecranon and allows the ulnar nerve to be identified and released; the triceps brachii is detached from the olecranon with a band of antebrachial fascia and the medial head is detached up to the groove of the radial nerve, which is preserved. A second anterior Z-shaped incision is made at the elbow crease to locate the distal BB tendon and the radial nerve in the lateral bicipital groove. The lateral brachial intermuscular septum is opened widely. The triceps brachii is passed subcutaneously before being fixed to the BB, elbow flexed 90°, forearm supinated to allow the transfer to hold the elbow in 50° flexion by itself. It is important to make sure the ulnar and radial nerves are not being compressed (assuming they are functional). The postoperative course is like that of the other strong transfers.

7. Weak transfers: indications and technique

7.1. Transfer of pectoralis minor (Fig. 4)

This transfer, described by Le Cœur [28], is fairly weak, thus it is indicated in cases when the elbow flexors already have M2 strength [29]. This is often a secondary procedure in patients with high brachial plexus palsy. Testing of this muscle (innervation by C6C7C8T1 and pectoral nerves) is tricky: the patients strongly presses their elbow on the examiners hand in a vertical lowering motion of the shoulder, while the examiner's other hand palpates the muscle on the coracoid process. This is facilitated by the paralysis of the clavicular bundle of the PM.

The surgical incision follows the inferior edge of the Pm in men and the inframammary fold in women. The PM is elevated, then the costal insertions of the Pm are detached with strips of periosteum and fascia from the intercostal muscles, which will make it easier to fix the transplant distally. The pedicle can be located with a nerve stimulator. Lastly, the muscle is extended by a fascia lata strip that is tunneled in the arm and secured to the distal biceps tendon. The muscle is also sutured to the muscle belly of the biceps. Tension setting and the postoperative course are no different than for PM transfer.

7.2. Transfer of medial epicondylar muscles according to Steindler (Fig 5)

The principle of this procedure is to transfer more proximally the insertion of the accessory flexors of the elbow that insert on the medial epicondyle to increase their moment arm. The Steindler procedure [30] is mainly indicated in C5C6 palsy cases when elbow flexion strength is graded at M2. C5C6C7 palsy is a poor indication, given the weakness of the medial epicondylar muscles, and the risk of a parasitic effect during elbow flexion (forearm pronation, wrist and finger flexion) related to paralysis of the wrist and finger extensors. Similarly, the possibility of doing the Steindler procedure must be discussed in the rare case when a double nerve transfer for elbow flexion fails. In fact, prior use of the fascicles of the median and ulnar nerves for the extrinsic muscles (medial epicondylar) could limit the flexion strength of these muscles and thereby, the results of the transfer.

Through a medial elbow approach extending from the arm to the forearm, the ulnar nerve is released. After protecting the branches of the median nerve, a 1.5 to 2 cm bone chip is cut from the medial epicondyle, taking the medial epicondylar muscles except for the ulnar head of the FCU, and preserving the medial collateral ligament, then transferred on the anterior side of the humerus, about 4 cm above the joint space. It is secured by a screw with washer with the elbow at 90° after decortication; it may be useful to drill a pilot hole for the screw. A splint is used to immobilize the elbow in 100° with the wrist in neutral position for 4 to 6 weeks.

7.3. Advancement of biceps tendon insertion

This technique, described by Nemoto et al. [31], aims to increase the moment arm of the BB by reinserting the biceps tendon 2 cm more distally on the radius. This technique is indicated when the biceps has recovered M3 strength.

8. Free vascularized muscle transfer: indications and technique

This technique allows patients to recover active elbow flexion when the palsy is discovered late and the potential for nerve regeneration still exists [32]. The most used muscles are the gracilis reinnervated by the intercostal nerves [33] and the LD reinnervated by the external ramus of the accessory nerve. The advantages of using the gracilis muscle are no donor site functional sequelae, minimal cosmetic impact and easier fixation. The drawbacks are that its strength is slightly less than the LD and it has a slightly shorter vascular pedicle.

The preoperative workup consists of a vascular assessment, determining the smoking habits in patients who often have axillary and subclavian lesions and looking for contraindications to the harvesting of the intercostal nerves (phrenic palsy and history of rib fracture).

In the literature, patients can flex the elbow against 2.5 kg load on average [34] after this procedure, although the failure rate due to vascular thrombosis can reach 15%.

Gracilis transfer is a complex procedure that requires extensive experience in

microsurgery and the simultaneous work of two teams (Fig. 6). While one team verifies the possibility of vascular branching at the recipient site and dissects the three intercostal nerves (T3, T4, T5), the other harvests the gracilis muscle with a skin paddle. The muscle is fixed to the coracoid process and conjoined tendon, then revascularized by the brachial artery and a regional vein. The intercostal nerves are sutured to the gracilis nerve, then its distal tendon is fixed to that of the BB. The postoperative course is similar to that of strong transfers. The first signs of reinnervation appear between 6 and 8 months postoperatively.

Conclusion

There are multiple palliative options for restoring elbow flexion. It is important to be familiar with the range of possible techniques and to perform a detailed clinical examination in order to propose the technique that is best suited to the patient. The patient's functional needs and an evaluation of the transferable muscles in the region are the main elements guiding the selection.

Conflict of interest:

The authors have no conflicts of interest to declare.

References

1. Chammas M, Coulet B. Paralysies de la flexion et de l'extension du coude. EMC - Techniques chirurgicales - Orthopédie-Traumatologie, 2014. 9(3): p. 1-22.
2. Roukoz S, Naccache N, Sleilaty G. The role of the musculocutaneous and radial nerves in elbow flexion and forearm supination: a biomechanical study. *J Hand Surg Eur* 2008;33:201-4.
3. Cambon-Binder A, Belkheyar Z, Durand S, Rantissi M, Oberlin C Elbow flexion restoration using pedicled latissimus dorsi transfer in seven cases. *Chir Main* 2012;31:324-30.
4. Parmaksizoglu F, Beyzadeoglu T. Functional latissimus dorsi island pedicle musculocutaneous flap to restore elbow flexion in replantation or revascularisation of above-elbow amputations. *Handchir Mikrochir Plast Chir* 2003;35:51-6.
5. Medical research council. Aids to the investigation of peripheral nerve injuries. 2nd ed. London: Her Majesty's Stationery Office, 1943.
6. Allieu Y, Chammas M, Picot MC. Paralysies du plexus brachial par lesions supraclaviculaires chez l'adulte. Resultats comparatifs a long terme des greffes nerveuses et des transferts nerveux. *Rev Chir Orthop Reparatrice Appar Mot* 1997;83:51-9.
7. Alnot JY, Daunois O, Oberlin C, Bleton R. Total paralysis of the brachial plexus caused by supra-clavicular lesions]. *Rev Chir Orthop Reparatrice Appar Mot* 1992;78:495-504.
8. Forli A, Bouyer M, Aribert M, Curvale C, Delord M, Corcella D, Moutet F. Upper limb nerve transfers: A review. *Hand Surg Rehabil* 2017;36(3):151-72.
9. Oberlin C, Béal D, Leechavengvongs S, Salon A, Dauge MC, Sarcy JJ. Nerve transfer to biceps muscle using a part of ulnar nerve for C5-C6 avulsion of the brachial plexus: anatomical study and report of four cases. *J Hand Surg Am* 1994;19:232-7.
10. Coulet B, Boretto JG, Lazerges C, Chammas M. A comparison of intercostal and partial ulnar nerve transfers in restoring elbow flexion following upper brachial plexus injury (C5-C6+/-C7). *J Hand Surg Am* 2010;35:1297-303.

11. Chammas M, Goubier JN, Coulet B, Reckendorf GM, Picot MC, Allieu Y. Glenohumeral arthrodesis in upper and total brachial plexus palsy. A comparison of functional results. *J Bone Joint Surg Br* 2004;86:692-5.
12. Schottstaedt ER, Larsen LJ, Bost FC. Complete muscle transposition. *J Bone Joint Surg Am* 1955;37:897-918.
13. Hovnanian AP. Latissimus dorsi transplantation for loss of flexion or extension at the elbow; a preliminary report on technic. *Ann Surg* 1956;143:493-9.
14. Zancolli E, Mitre H. Latissimus dorsi transfer to restore elbow flexion. An appraisal of eight cases. *J Bone Joint Surg Am* 1973;55:1265-75.
15. Wood MB. Restoration of elbow flexion by tendon or muscle transfer, in *Conférences d'enseignement 1992. Cahier d'enseignement de la S.O.F.C.O.T. 1992, Expansion scientifique française, Paris. p. 51-60.*
16. Stern PJ, Carey JP. The latissimus dorsi flap for reconstruction of the brachium and shoulder. *J Bone Joint Surg Am* 1988;70:526-35.
17. Hirayama T, Takemitsu Y, Atsuta Y, Ozawa K. Restoration of elbow flexion by complete latissimus dorsi muscle transposition. *J Hand Surg Br* 1987;12:194-8.
18. Tsai TM, Kalisman M, Burns J, Kleinert HE. Restoration of elbow flexion by pectoralis major and pectoralis minor transfer. *J Hand Surg Am* 1983;8:186-90.
19. D'Aubigne RM, Deburge A. Traitement des paralysies du plexus brachial *Rev Chir Orthop Reparatrice Appar Mot* 1967;53:199-215.
20. Alnot JY, Abols Y. Réanimation de la flexion du coude par transferts tendineux dans les paralysies traumatiques du plexus brachial de l'adulte. A propos de 44 blessés. *Rev Chir Orthop Reparatrice Appar Mot* 1984;70:313-23.
21. Wahegaonkar AL, Doi K, Hattori Y, Addosooki AI. Surgical technique of pedicled bipolar pectoralis major transfer for reconstruction of elbow flexion in brachial plexus palsy. *Tech Hand Up Extrem Surg* 2008;12:12-9.
22. Beaton DE, Dumont A, Mackay MB, Richards RR. Steindler and pectoralis major flexorplasty: a comparative analysis. *J Hand Surg Am* 1995;20:747-56.

23. Sedel L. Traitement palliatif d'une serie de 103 paralysies par elongation du plexus brachial. Evolution spontanee et resultat. Rev Chir Orthop Reparatrice Appar Mot 1977;63:651-65.
24. Cambon-Binder A, Walch A, Marcheix PS, Belkheyar Z. Bipolar transfer of the pectoralis major muscle for restoration of elbow flexion in 29 cases. J Shoulder Elbow Surg 2018;27:e330-6
25. Bunnell S. Restoring flexion to the paralytic elbow. J Bone Joint Surg Am 1951;33:566-71.
26. Carroll RE, Hill NA. Triceps transfer to restore elbow flexion. A study of fifteen patients with paralytic lesions and arthrogryposis. J Bone Joint Surg Am 1970;52:239-44.
27. Naidu S, Lim A, Poh LK, Kumar VP. Long head of the triceps transfer for elbow flexion. Plast Reconstr Surg 2007;119:45e-47e.
28. Le Cœur P. Procédés de restauration de la flexion du coude paralytique. Rev Chir Orthop Reparatrice Appar Mot 1953;39:655-6.
29. Rostoucher P, Alnot JY, Touam C, Oberlin C. Tendon transfers to restore elbow flexion after traumatic paralysis of the brachial plexus in adults. Int Orthop 1998;22:255-62.
30. Steindler A. A muscle plasty for the relief flail elbow in infantile paralysis. Interstate Med J 1918;35:235-41.
31. Nemoto K, Itoh Y, Horiuchi Y, Sasaki T. Advancement of the insertion of the biceps brachii muscle: a technique for increasing elbow flexion force. J Shoulder Elbow Surg 1996;5:433-6.
32. Chuang DC. Functioning free muscle transplantation for brachial plexus injury. Clin Orthop Relat Res 1995;314:104-11.
33. Chammas M, Allieu Y. Free muscle transfer in brachial plexus palsy. Tech Hand Up Extrem Surg 1999;3:23-31.
34. Coulet B, Boch C, Boretto J, Lazerges C, Chammas M. Free gracilis muscle transfer to restore elbow flexion in brachial plexus injuries. Orthop Traumatol Surg Res 2011;97:785-92.

Table titles

Table 1. Trunk and nerve root innervation of the elbow flexor muscles

Figure legends

Fig. 1. Decision-making tree for surgical indications in paralysis of elbow flexion (based on Chammas M and Coulet B [1]).

Fig. 2. Transfer of latissimus dorsi on the biceps brachii. Initial dissection to identify the anterior margin of the latissimus dorsi (A). Separation of latissimus dorsi and serratus anterior (B). Development of myocutaneous latissimus dorsi flap and exposure of pedicle (C). Double fixation of the muscle to the coracoid process and the biceps brachii (D). 1: axillary artery and vein; 2: subscapular artery and vein; 3: scapular circumflex artery and vein; 4: thoracodorsal artery and vein; 5: thoracodorsal nerve; 6: lateral thoracic artery and vein (from Chammas M and Coulet B [1]).

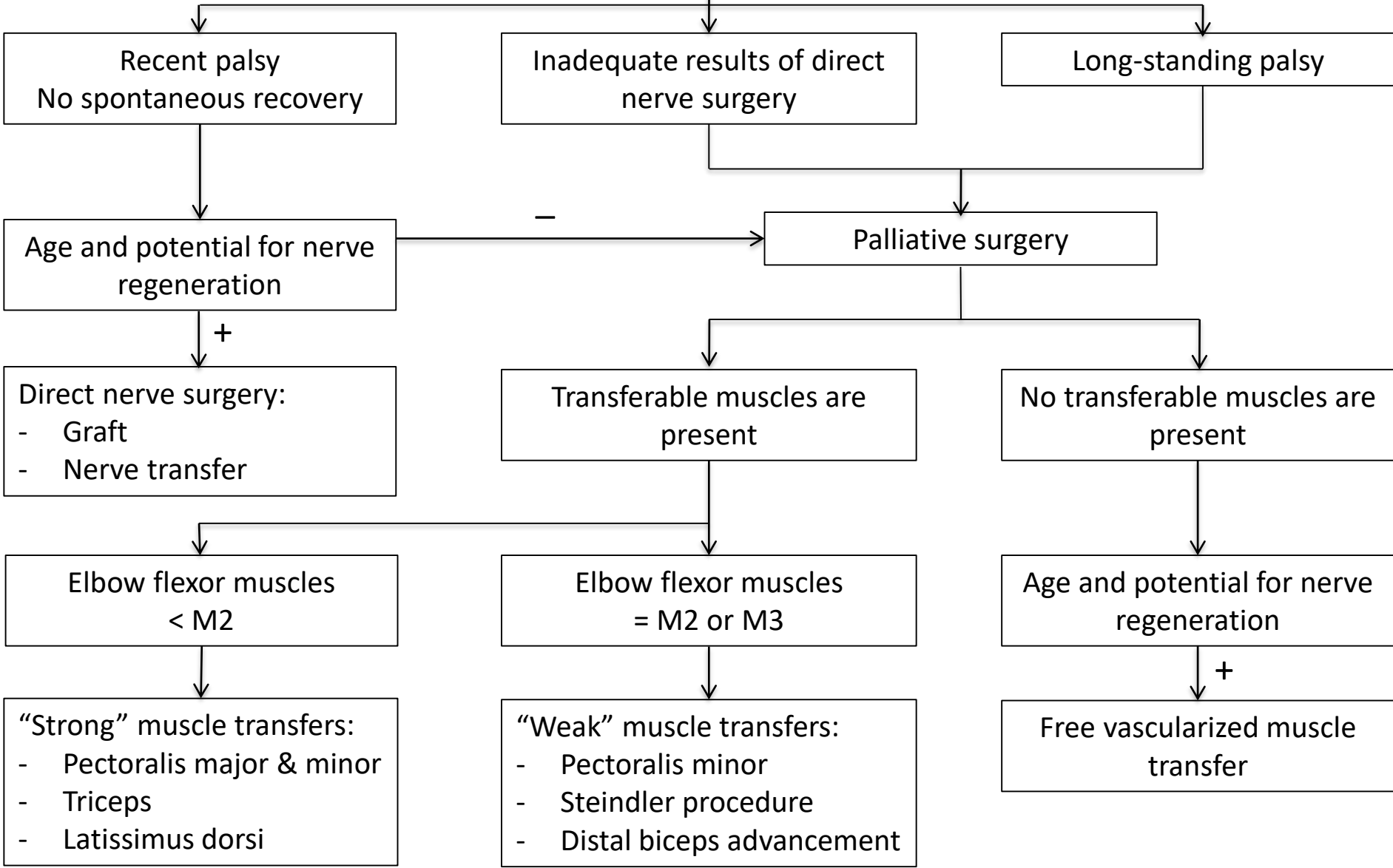
Fig. 3. Transfer of the sternocostal head of the pectoralis major muscle and the pectoralis minor on the biceps brachii. Incisions (A). Individualization of the sternocostal head of pectoralis major (B). Elevation of pectoralis major and view of the branches of the medial pectoral nerve (C). Fixation of pectoralis major to coracoid process, then the two muscles to the biceps brachii (D) (from Chammas M and Coulet B [1]).

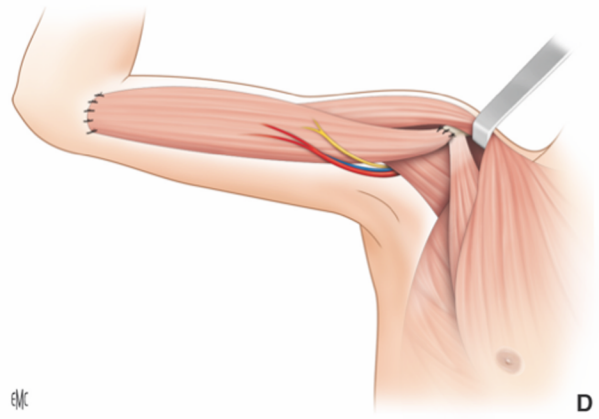
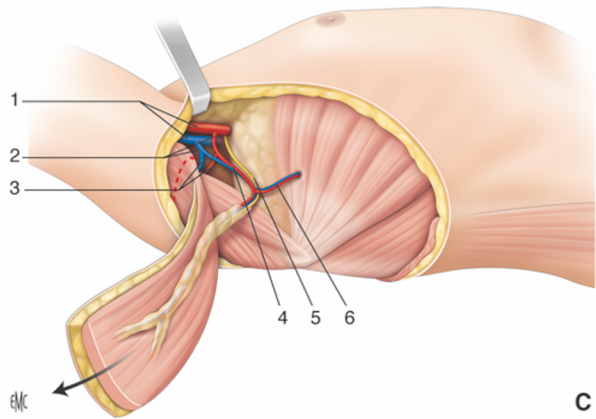
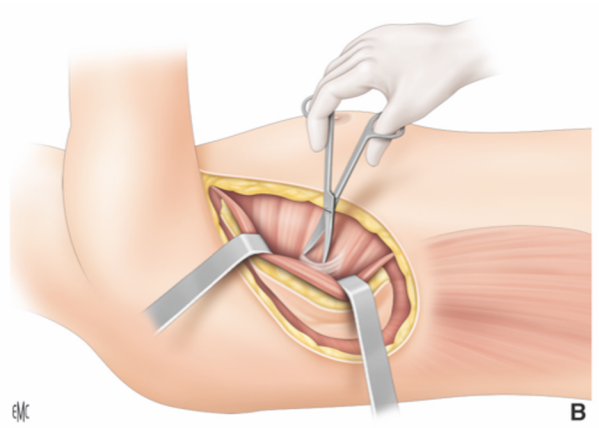
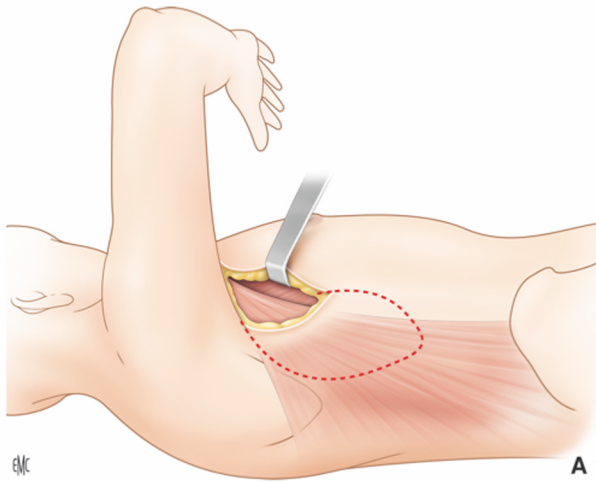
Fig. 4. Transfer of pectoralis minor on the biceps brachii. Detachment of the digitations of the pectoralis minor with the rib periosteum (A). Fixation by a fascia lata strip sutured by interlacing proximally and distally to the level of the distal tendon of the biceps brachii, and to the biceps brachii that has been folded upon itself (B) (from Chammas M and Coulet B [1]).

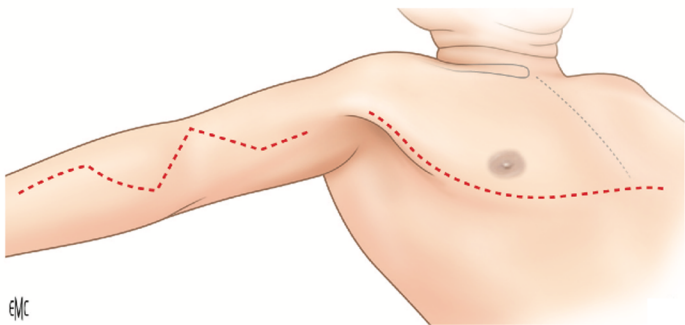
Fig. 5. Steindler procedure. Medial incision at the elbow (A). Osteotomy of the medial epicondyle with protection of the median and ulnar nerves and the brachial artery (B). Translocation of the medial epicondyle with screw fixation and anterior transposition of the ulnar nerve (C) (from Chammas M and Coulet B [1]).

Fig. 6. Transfer of the gracilis muscle reinnervated by the intercostal nerves (T3, T4, T5) on the biceps brachii. Dissection plane for the vascular pedicle of the gracilis (A). 1: femoral artery; 2: adductor longus muscle; 3: deep femoral artery; 4: adductor brevis muscle; 5: gracilis muscle; 6: adductor magnus muscle. Proximal fixation to the coracoid process. The distal tendon of the gracilis is anastomosed by whipstitching it to the distal tendon of the biceps brachii. End-to-side anastomosis of the vascular pedicle of the gracilis on the brachial artery and end-to-end anastomosis on a brachial vein. Transfer of the T3, T4, T5 intercostal nerves on the gracilis nerve (B). 1: coracoid process; 2: pectoralis major muscle, 3: anastomosis of the T3, T4, T5 intercostal nerves and the gracilis nerve; 4: myocutaneous gracilis flap, 5: distal tendon of the biceps brachii (from Chammas M and Coulet B [1]).

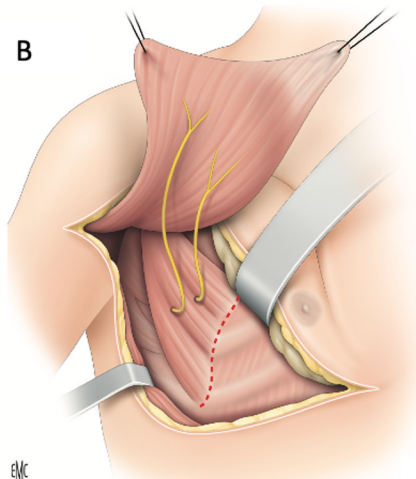
Paralysis of elbow flexion



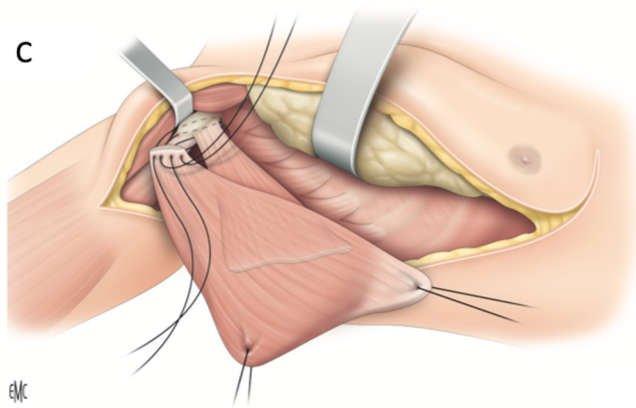


A

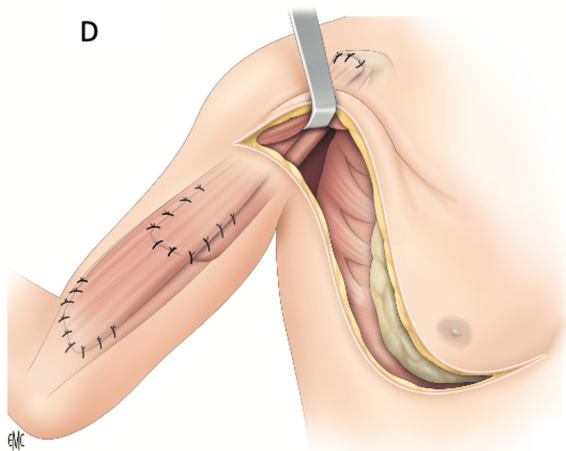
EMC

B

EMC

C

EMC

D

EMC

