



**HAL**  
open science

## A second individual with rhizomelic spondyloepimetaphyseal dysplasia and homozygous variant in GNPAT1

Quentin Sabbagh, Fanny Alkar, Karine Patte, Olivier Prodhomme, Caroline Janel, Renaud Touraine, Claire Jeandel, David Geneviève

► **To cite this version:**

Quentin Sabbagh, Fanny Alkar, Karine Patte, Olivier Prodhomme, Caroline Janel, et al.. A second individual with rhizomelic spondyloepimetaphyseal dysplasia and homozygous variant in GNPAT1. *European Journal of Medical Genetics*, 2022, 65 (6), pp.104495. 10.1016/j.ejmg.2022.104495 . hal-04527529

**HAL Id: hal-04527529**

<https://hal.science/hal-04527529v1>

Submitted on 22 Jul 2024

**HAL** is a multi-disciplinary open access archive for the deposit and dissemination of scientific research documents, whether they are published or not. The documents may come from teaching and research institutions in France or abroad, or from public or private research centers.

L'archive ouverte pluridisciplinaire **HAL**, est destinée au dépôt et à la diffusion de documents scientifiques de niveau recherche, publiés ou non, émanant des établissements d'enseignement et de recherche français ou étrangers, des laboratoires publics ou privés.



Distributed under a Creative Commons Attribution - NonCommercial 4.0 International License

## **A second individual with rhizomelic spondyloepimetaphyseal dysplasia and homozygous variant in *GNPNAT1***

Quentin Sabbagh<sup>1</sup>, Fanny Alkar<sup>1</sup>, Karine Patte<sup>2</sup>, Olivier Prodhomme<sup>3</sup>, Caroline Janel<sup>4</sup>, Renaud Touraine<sup>5</sup>, Claire Jeandel<sup>6</sup>, David Geneviève<sup>1\*</sup>

- <sup>1</sup> Montpellier University, ERN ITHACA, Génétique Clinique, Département de Génétique Médicale, Maladies Rares et Médecine Personnalisée, Centre Hospitalier Universitaire de Montpellier, Centre de Compétence Maladies Osseuses Constitutionnelles, INSERM U1183, Montpellier, France.
- <sup>2</sup> Institut Saint-Pierre, Département de Médecine Physique et Réadaptation Pédiatrique, Palavas-Les-Flots, France.
- <sup>3</sup> Montpellier University, Département d'Imagerie Pédiatrique, Centre Hospitalier Universitaire de Montpellier, Montpellier, France.
- <sup>4</sup> Service de Biochimie Médicale et Génétique Moléculaire, Centre Hospitalier Universitaire Gabriel Montpied, Laboratoire AURAGEN (Plan France Médecine Génomique 2025), Clermont-Ferrand, France.
- <sup>5</sup> Laboratoire de Génétique Chromosomique et Moléculaire, CHU-Hôpital Nord, Laboratoire AURAGEN (Plan France Médecine Génomique 2025), Saint Étienne, France.
- <sup>6</sup> Montpellier University, Département de Pédiatrie Spécialisée, Centre de Compétence Maladies Endocriniennes Rares, Centre Hospitalier Universitaire de Montpellier, Montpellier, France.

\* Correspondance to Pr David Geneviève, Département de Génétique Médicale, Maladies Rares et Médecine Personnalisée, Centre Hospitalier Universitaire de Montpellier, Centre de Compétence Maladies Osseuses Constitutionnelles, INSERM U1183, Montpellier, France.

Email : [d-genevieve@chu-montpellier.fr](mailto:d-genevieve@chu-montpellier.fr)

## **Abstract**

Spondyloepimetaphyseal dysplasias (SEMDs) belong to a clinically and genetically heterogeneous group of inherited skeletal disorders defined by a defect in the growth and shape of vertebrae, epiphyses and metaphyses. Rhizomelic SEMD is characterized by a disproportionate small stature caused by severe shortening and deformation of the limbs' proximal bones, with the cranio-facial sphere unaffected. We report a second individual, an 8-year-old girl, with autosomal recessive rhizomelic SEMD associated with a homozygous exonic missense variant, c.226G>A p.(Glu76Lys), in *GNPNAT1* identified by trio genome sequencing. Our data corroborate the recent findings of Ain *et al.* and further delineate the clinical and radiographic features of this form of SEMD associated with rhizomelic dysplasia while outlining a potential hotspot in this newly described genetic disorder.

## **Keywords**

Skeletal disorder - Spondyloepimetaphyseal dysplasia - *GNPNAT1* - Heparan sulfite

## **Introduction**

The family of spondyloepimetaphyseal dysplasias (SEMDs) correspond to a clinically and genetically heterogeneous group of inherited skeletal disorders defined by a defect in the growth and shape of vertebrae, epiphyses and metaphyses [1]. SEMDs are classified according to clinical pattern, radiographic findings and molecular pathway; however, most of these molecular mechanisms are still unexplored [2]. Rhizomelic SEMD is characterized by a disproportionate small stature caused by severe shortening and deformation of the limbs' proximal bones (*i.e.*, humerus and femur), with the cranio-facial sphere unaffected [3].

We report an 8-year-old girl displaying rhizomelic SEMD, with both characteristic morphotype and radiographic defects, associated with a homozygous missense variant in glucosamine 6-phosphate N-acetyltransferase 1 (*GNPNAT1*, MIM616510) identified by trio genome sequencing.

## **Clinical report**

### **Ethical statement**

Informed consent was obtained from all participants. Written consent was received for the use of photos. Clinical examination and molecular analysis were performed in routine care.

### **Clinical presentation and skeletal anomalies**

At age 3 years, the girl was referred to the competence center for skeletal dysplasia in the department of medical genetics, rare diseases and personalized medicine of the university hospital of Montpellier because of abnormal short stature with limb deformation. She was born at term after an uneventful pregnancy and delivery from

Moroccan consanguineous healthy parents (f = 1/16). Birth weight was 3,425 g (median), length 48.5 cm (-1 SD) and head circumference 34.5 cm (median). No skeletal disorders were reported in the family. Parent's height was normal (mother: 165 cm; father: 175 cm).

The first months of life revealed normal motor development: she walked at 12 months. Likewise, language and comprehension acquisition were preserved.

The clinical phenotype is characterized by severe short stature, with height at age 3 and 8 years about 84.5 cm (-3.5 SD) and 92.5 cm (-7 SD), respectively, associated with rhizomelic shortening of the limbs (Figure 1A-B). This considerable growth regression could be explained by the major joint limitations but also the severe metaphyseal involvement of both humerus and femur. Interestingly, her head circumference remained stable at -1.5 SD between 3 and 8 years of age. Her forearms are relatively long compared to her height, and the joints are enlarged. She displays abnormal gait with restricted range of motion because of mechanical constraints due to short femurs. The extremities show inequalities in both metacarpal and metatarsal length (Figure 1C-D). There is no facial features. Hearing and vision examination were normal. No symptoms of immune deficiency were reported.

X-rays of the arms show bilateral shortening of the humerus, enlarged and irregular metaphysis and dysplasia of the proximal epiphysis (Figure 1E). The radius and ulna appeared normal in shape and length. The femurs are short, while both hip and knee joints show significant dysplasia (Figure 1F-H). Thoracic and lumbar vertebrae are flat and show degenerative changes (Figure 1I). Results of skull X-rays were normal. Of note, blood and urine analyses gave normal results, as did assessment of serum electrolytes including calcium, phosphate and alkaline phosphatase.

## **Molecular analysis**

Trio genome sequencing performed with aid of the France Genomic Medicine Plan 2025 revealed a homozygous exonic missense variant, c.226G>A p.(Glu76Lys), in *GNPNAT1* (NM\_198066.4) in the girl; both healthy parents were heterozygous for the variant (Figure 2A-B). This variant is localized in the N-acetyltransferase domain of *GNPNAT1* (Figure 2C) and considered pathogenic in the ClinVar ([https://www.ncbi.nlm.nih.gov/clinvar/variation/1302024/?new\\_evidence=false](https://www.ncbi.nlm.nih.gov/clinvar/variation/1302024/?new_evidence=false)) and VarSome (<https://varsome.com/variant/hg38/chr14%3A52781903%3AC%3AT?>) databases according to the American College of Medical Genetics and Genomics and Association for Molecular Pathology classification (PVS<sub>3</sub>, PM<sub>2</sub>, PP<sub>3</sub>, PP<sub>4</sub>) and the functional studies performed by Ain and colleagues [4] [5].

## **Discussion**

SEMDs are a heterogeneous group of inherited skeletal conditions with more than 25 distinct entities and different inheritance modes according to the 2019 revision of the nosology and classification of genetic skeletal disorders. However, only a few genes have been identified, and most of the underlying molecular mechanisms remain unknown [1].

We report an 8-year-old girl displaying an autosomal recessive rhizomelic SEMD with both characteristic clinical features and skeletal defects including small and disproportionate stature with severe rhizomelic shortening of the limbs, wide extremities and limited extension of the large joints. Her cranio-facial sphere was preserved, as was her intellectual development. Genome sequencing identified a pathogenic bi-allelic exonic missense variant, c.226G>A p.(Glu76Lys), in *GNPNAT1*.

Several types of disproportionate SEMDs share some similarities with the skeletal disorder reported here. SEMD of the Geneviève type (MIM610442) is caused by a homozygous variant in the N-acetylneuraminase gene (*NANS*) and characterized by a disproportionate small stature associated with skeletal dysplasia, underdeveloped epiphyses and platyspondyly [6]. However, this condition includes infantile-onset developmental delay, facial features and hirsutism, in contrast to the girl described here. Likewise, opsismodysplasia (MIM258480) is different in that it is associated with small extremities, relative macrocephaly and distinctive facial features [7]. Finally, although SPONATRISME dysplasia (MIM271510) is also defined by disproportionate short-limb dwarfism, both epiphyseal and metaphyseal dysplasia and normal intellectual development, this condition is marked by midface hypoplasia, childhood cataract and hypogammaglobulinemia, which were absent in the individual reported here [8]. Of note, these three genetic conditions were also excluded molecularly based on trio genome sequencing results.

Skeletal defects have been further described in several congenital disorders of glycosylation (CDGs), a broad family of monogenic inherited conditions characterized by disruptions in glycosylation pathways hindering synthesis and attachment of glycans to glycoproteins and glycolipids [9]. Indeed, PMM2-CDG (MIM212065), ALG3-CDG (MIM601110) and ALG12-CDG (MIM607143) are defined by skeletal dysplasia with rhizomelic shortening and disproportionate small stature [10]. However, although *GNPNAT1* is ubiquitously expressed, no extra-skeletal signs were found in the girl reported here, in contrast to most CDGs.

Strikingly, variant c.226G>A p.(Glu76Lys) was recently described by Ain and colleagues (MIM619598) in a consanguineous Pakistani family: 4 siblings with a homozygous variant in *GNPNAT1* presented a similar phenotype, with severe

rhizomelic dysplasia (Table 1) [5]. Moreover, the authors identified *GNPNAT1* as a key player in chondrocyte proliferation and differentiation *in vivo*, thus suggesting its critical role for growth-plate chondrogenesis. This highly conserved gene across vertebrate species encodes for glucosamine 6-phosphate N-acetyltransferase 1 (GNPNAT1), a ubiquitous enzyme involved in the hexosamine biosynthetic pathway [11]. The hexosamine biosynthetic pathway is a glucose metabolism pathway resulting in production of UDP-N-acetylglucosamine, a nucleotide sugar used as a substrate for both O-linked protein glycosylation and proteoglycan synthesis *via* heparan sulfate chain elongation (Figure 3). Proteoglycans are a major component of the extracellular matrix and play a key role in cartilage development, whereas impaired heparan sulfate synthesis has been found responsible for several congenital skeletal dysplasias and connective-tissue conditions (Figure 3) [12] [13]. Therefore, the rhizomelic SEMD we report may represent a new form of heparan sulfate synthesis-related genetic disorder.

In conclusion, we describe a second individual with rhizomelic SEMD associated with the homozygous exonic variant c.226G>A p.(Glu76Lys) in *GNPNAT1*. Our data corroborate the recent findings of Ain *et al.* and further delineate the clinical and radiographic features of this form of SEMD associated with rhizomelic dysplasia while outlining a potential hotspot in this newly described genetic disorder.

### **Acknowledgments**

We thank the family for participating in the study. This research was possible by access to the data generated by the France Genomic Medicine Plan 2025.

### **Competing interests**



The authors declare no competing interests.

### **Legends of figures**

#### **Figure 1. Clinical and radiographic features of the affected girl. (A-B)**

Photographs of the girl at age 3 and 8 years showing disproportionate small stature with severe rhizomelic shortening of the limbs associated with enlarged joints and major knee flexum. The trunk is short and both hands and feet are relatively long and large as compared with the height. **(C-D)** Photographs of the extremities revealing global brachytelephalangy, mild fifth finger camptodactyly, bilateral hallux valgus and second toe overriding. **(E)** X-rays of the arms performed at 3 years of age showing severe bilateral shortening of the humerus, widening of diaphyses and severe dysplasia of the proximal epiphysis. **(F)** Likewise, femurs are short with large distal metaphysis. Tibia and fibula also feature diaphyseal dysplasia. **(G)** Pelvic X-rays revealing bilateral hip dysplasia, dysplasia of femoral head and a short neck. **(H)** The knee is also highly dysplastic, with both femoral and tibial epiphyses abnormally shaped. **(I)** Front and lateral view of thoracic and upper lumbar spine showing platyspondyly associated with degenerative changes.

**Figure 2. Trio genome sequencing results. (A-B)** Identification of a pathogenic homozygous exonic missense variant, c.226G>A p.(Glu76Lys), in *GNPNAT1* in the affected girl. Both healthy parents were heterozygous for the variant. **(C)** Linear and 3D representation of glucosamine 6-phosphate N-acetyltransferase 1 (<https://www.uniprot.org/uniprot/Q96EK6>). The variant is localized in the N-acetyltransferase domain of the protein.

**Figure 3. Heparan sulfate (HS) synthesis-related genetic disorders.** HS is a glycosaminoglycan ubiquitously expressed on cell surfaces and in the extracellular matrix. HS synthesis starts with the formation of a tetrasaccharide linkage region composed of a xylose (Xyl), 2 galactoses (Gal) and a glucuronic acid (GlucA) attached to a serine residue of a proteoglycan core protein. HS chain elongation is further completed by the binding of a specific molecular pattern including an N-acetylglucosamine (GlcNAc) and variable repetitions of GlucA/GlcNAc disaccharide. Several congenital skeletal dysplasias and connective-tissue disorders (**bold**) have been found associated with variants in enzymes (*italics*) involved in this linking sugar process and include Desbuquois dysplasia type 2 (DBQD2), spondylo-ocular syndrome (SOS), Ehlers-Danlos syndrome spondylodysplastic type 1-2 (EDSS1-2), spondyloepimetaphyseal dysplasia with joint laxity type 1 (SEMD-JL1), Larsen-like syndrome (LLS), immunoskeletal dysplasia and neurodevelopmental abnormalities (ISDNA) and hereditary multiple exostosis type 1-2 (HME1-2).

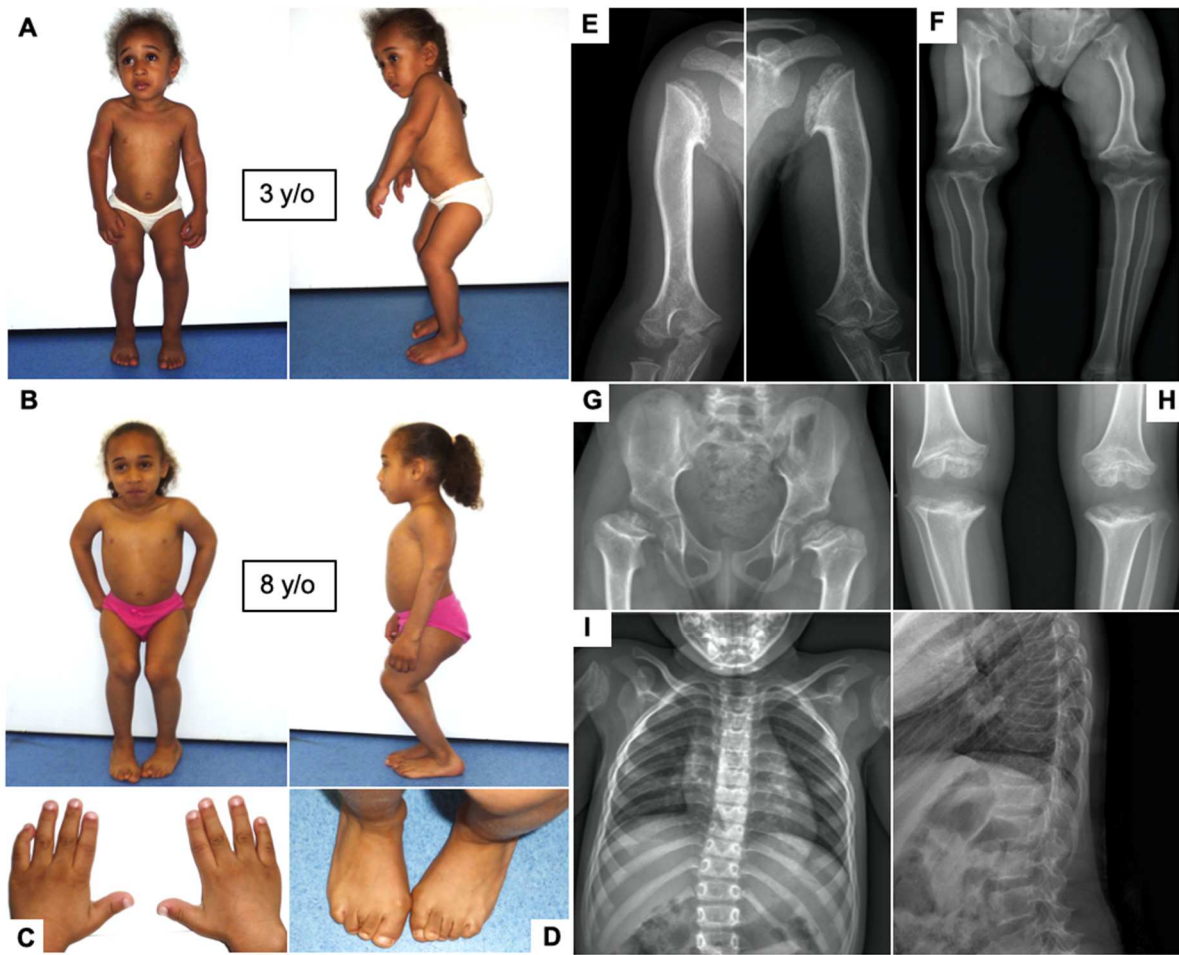
### **Legends of tables**

**Table 1. Phenotypic features of reported individuals with rhizomelic spondyloepimetaphyseal dysplasia (SEMD) associated with homozygous variant in *GNPNAT1*.**

### **References**


- [1] G. Mortier, D. Cohn, V. Cormier-Daire, C. Hall, D. Krakow, S. Mundlos, G. Nishimura, S. Robertson, L. Sangiorgi, R. Savarirayan, D. Sillence, A. Superti-Furga, S. Unger et M. Warman, «Nosology and classification of genetic skeletal disorders: 2019 revision,» *American Journal of Medical Genetics Part A*, vol. 179, pp. 2393-2419, 2019.
- [2] H. Taybi and R. Lachman, "Spondyloepimetaphyseal dysplasias," in *Radiology of syndromes, metabolic disorders and skeletal dysplasias*, St Louis, Mosby (4th edition), 1996, pp. 915-924.

- [3] T. Bieganski, Z. Lipczyk et K. Kozlowski, «Rhizomelic spondyloepimetaphyseal dysplasia,» *Clinical Dysmorphology*, vol. 10, pp. 285-288, 2001.
- [4] S. Richards, N. Aziz, S. Bale, D. Bick, S. Das, J. Gastier-Foster, W. Grody, M. Hegde, E. Lyon, E. Spector, K. Voelkerding et H. Rehm, «Standards and guidelines for the interpretation of sequence variants: a joint consensus recommendation of the American College of Medical Genetics and Genomics and the Association for Molecular Pathology,» *Genetics in Medicine*, vol. 5, pp. 405-424, 2015.
- [5] N. U. Ain, M. Baroncelli, A. Costantini, T. Ishaq, F. Taylan, O. Nilsson, O. Mäkitie and S. Naz, "Novel form of rhizomelic skeletal dysplasia associated with a homozygous variant in GNPAT1," *Journal of Medical Genetics*, vol. 58, pp. 351-356, 2021.
- [6] D. Geneviève, D. Héron, V. El Ghouzzi, C. Prost-Squarcioni, M. Le Merrer, A. Jacqueline, D. Sanlaville, F. Pinton, N. Villeneuve, G. Kalifa, A. Munnich et V. Cormier-Daire, «Exclusion of the dymeclin and PAPSS2 genes in a novel form of spondyloepimetaphyseal dysplasia and mental retardation,» *European Journal of Human Genetics*, vol. 5, pp. 541-546, 2005.
- [7] P. Maroteaux, V. Stanescu, R. Stanescu, B. Le Marec, C. Moraine et H. Lejarraga, «Opsismodysplasia: a new type of chondrodysplasia with predominant involvement of the bones of the hand and the vertebrae,» *American Journal of Medical Genetics*, vol. 1, pp. 171-182, 1984.
- [8] S. Fanconi, C. Issler, A. Giedion et A. Prader, «The SPONASTRIME dysplasia: familial short-limb dwarfism with saddle nose, spinal alterations and metaphyseal striation. Report of 4 sibs,» *Helvetica Paediatrica Acta*, vol. 3, pp. 267-280, 1983.
- [9] N. Ondruskova, A. Cechova, H. Hansikova, T. Honzik et J. Jaeken, «Congenital disorders of glycosylation: Still "hot" in 2020,» *Biochimica and Biophysica Acta - General Subjects*, vol. 1865, 2021.
- [10] D. Coman, M. Irving, P. Kannu, J. Jaeken et R. Savarirayan, «The skeletal manifestations of the congenital disorders of glycosylation,» *Clinical Genetics*, vol. 6, pp. 507-515, 2008.
- [11] J. Wang, X. Liu, Y.-H. Liang, L.-F. Li and X.-D. Su, "Acceptor substrate binding revealed by crystal structure of human glucosamine-6-phosphate N-acetyltransferase 1," *FEBS Letters*, vol. 582, pp. 2973-2978, 2008.
- [12] H. Xue, D. Tao, Y. Weng, Q. Fan, S. Zhou, R. Zhang, H. Zhang, R. Yue, X. Wang, Z. Wang and Y. Sun, "Glycosylation of dentin matrix protein 1 is critical for fracture healing via promoting chondrogenesis," *Frontiers in Medicine*, vol. 5, pp. 575-589, 2019.
- [13] C. Paganini, R. Costantini, A. Superti-Furga et A. Rossi, «Bone and connective tissue disorders caused by defects in glycosaminoglycans biosynthesis: a panoramic review,» *The FEBS Journal*, vol. 286, pp. 3008-3032, 2019.

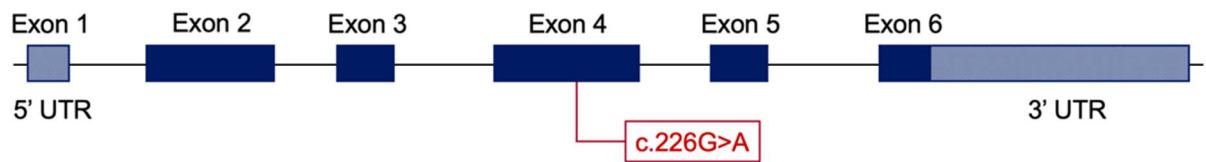


**Figure 1. Clinical and radiographic features of the affected girl.**

A



B



C

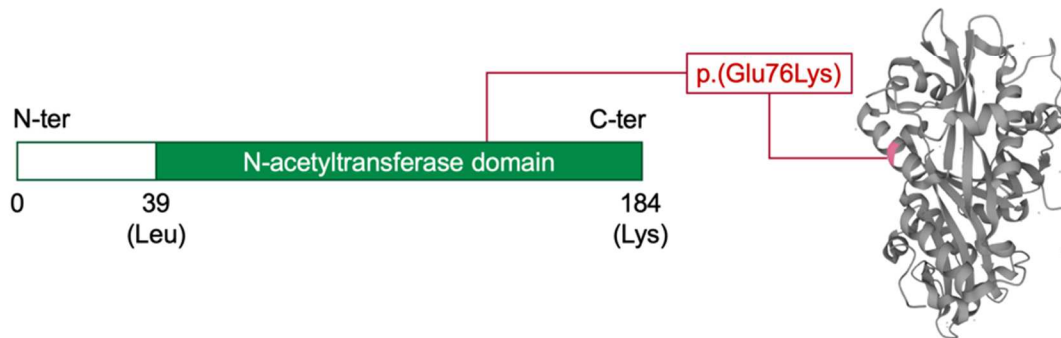
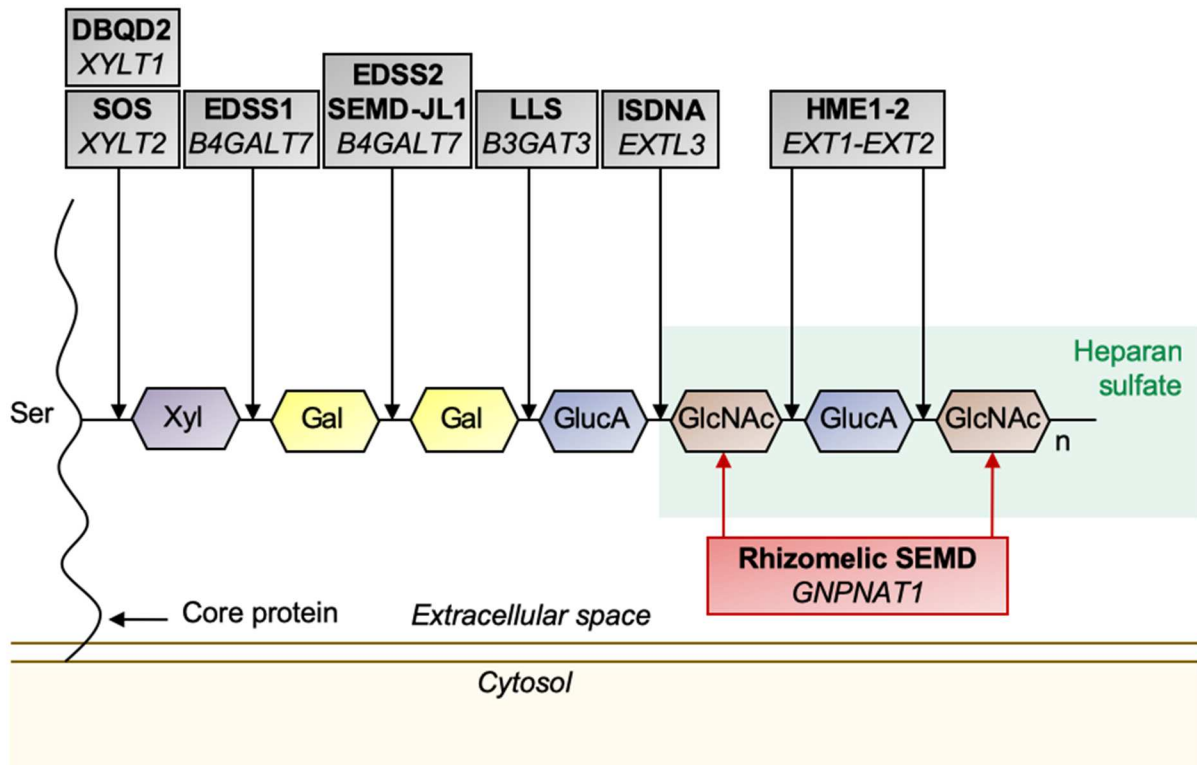


Figure 2. Trio genome sequencing results.



**Figure 3. Heparan sulfate (HS) synthesis-related genetic disorders.**

**Table 1. Phenotypic features of reported individuals with rhizomelic spondyloepimetaphyseal dysplasia (SEMD) associated with homozygous variant in *GPNAT1*.**

	Individual #1	Individual #2	Individual #3	Individual #4	Individual reported here
<b>General information</b>					
Age	48	50	45	46	8 (at last review)
Sex	M	M	F	F	F
Zygoty	Homozygous	Homozygous	Homozygous	Homozygous	Homozygous
Height (SD)	-9.4	-10.1	-9.9	-7.6	-7.0
Head circumference (SD)	+2.0	+2.0	+1.5	-1.3	-1.5
Cognition	Normal	Normal	Normal	Normal	Normal
Speech	Normal	Normal	Normal	Normal	Normal
Immune deficiency	No	No	No	No	No
<b>Clinical features</b>					
Facial features	No	No	No	No	No
Gait	Abnormal	Abnormal	Abnormal	Abnormal	Abnormal
Restricted range of motion	Yes	Yes	Yes	Yes	Yes
Rhizomelic shortening	Yes	Yes	Yes	Yes	Yes
Enlarged joints	Yes	Yes	Yes	Yes	Yes
Hip flexum	Unknown	Unknown	Unknown	Unknown	Yes (20°)
Knee flexum	Unknown	Unknown	Unknown	Unknown	Yes (50°)
Large hands and feet	Yes	Yes	Yes	Yes	Yes
Hallux valgus	No	No	No	No	Yes
Fifth finger camptodactyly	No	No	No	No	Yes
Overlapping toe	No	No	No	No	Yes
<b>Radiological features</b>					
Hip dysplasia	Yes	Yes	Yes	Yes	Yes
Knee dysplasia	Yes	Yes	Yes	Yes	Yes
Large distal metaphyses	Yes	Yes	Yes	Yes	Yes
Inequalities in metacarpal/metatarsal length	Yes	Yes	Yes	Yes	Yes
Platyspondyly	Yes	Yes	Yes	Yes	Yes