



HAL
open science

Edwards SAPIEN Transcatheter Pulmonary Valve Implantation

Julien Plessis, Sébastien Hascoët, Alban Baruteau, François Godart,
Laurianne Le Gloan, Karine Warin Fresse, Nabil Tahhan, Jean-Yves Riou,
Béatrice Guyomarch, Jérôme Petit, et al.

► **To cite this version:**

Julien Plessis, Sébastien Hascoët, Alban Baruteau, François Godart, Laurianne Le Gloan, et al..
Edwards SAPIEN Transcatheter Pulmonary Valve Implantation. JACC: Cardiovascular Interventions,
2018, 11 (19), pp.1909-1916. 10.1016/j.jcin.2018.05.050 . hal-04526575

HAL Id: hal-04526575

<https://hal.science/hal-04526575v1>

Submitted on 21 Nov 2024

HAL is a multi-disciplinary open access archive for the deposit and dissemination of scientific research documents, whether they are published or not. The documents may come from teaching and research institutions in France or abroad, or from public or private research centers.

L'archive ouverte pluridisciplinaire **HAL**, est destinée au dépôt et à la diffusion de documents scientifiques de niveau recherche, publiés ou non, émanant des établissements d'enseignement et de recherche français ou étrangers, des laboratoires publics ou privés.

Edwards SAPIEN Transcatheter Pulmonary Valve Implantation

Results From a French Registry

Julien Plessis, MD,^a Sébastien Hascoët, MD,^{b,c} Alban Baruteau, MD, PhD,^{a,d,e} François Godart, MD, PhD,^f Laurianne Le Gloan, MD,^a Karine Warin Fresse, MD,^a Nabil Tahhan, MD,^b Jean-Yves Riou, MD,^b Béatrice Guyomarch, MS,^a Jérôme Petit, MD,^b Patrice Guérin, MD, PhD^a

OBJECTIVES The aim of this study was to describe and analyze data from patients treated in France with the Edwards SAPIEN transcatheter heart valve (Edwards Lifesciences LLC, Irvine, California) in the pulmonary position.

BACKGROUND The Edwards SAPIEN valve has recently been introduced for percutaneous pulmonary valve implantation (PPVI).

METHODS From April 2011 to May 2017, 71 patients undergoing PPVI were consecutively included.

RESULTS The median age at PPVI was 26.8 years (range 12.8 to 70.1 years). Primary underlying diagnoses were conotruncal malformations (common arterial trunk, tetralogy of Fallot and variants; $n = 45$), Ross procedure ($n = 18$), and other diagnoses ($n = 8$). PPVI indication was pure stenosis in 33.8% of patients, pure regurgitation in 28.1%, and mixed lesions in 38.1%. PPVI was successfully implemented in 68 patients (95.8%). Pre-stenting of the right ventricular outflow tract was performed in 70 patients (98.6%). Early major complications occurred in 4 subjects (5.6%), including 1 death, 1 coronary compression, and 2 pulmonary valve embolizations. Three of the 4 major complications occurred in the first 15 operated patients. No significant regurgitation was recorded after the procedure. Transpulmonary gradient was significantly reduced from 34.5 to 10.5 mm Hg ($p < 0.0001$). No patient died during a 1-month follow-up period. At 1-year follow-up, the death rate was 2.9%, and 3 patients had undergone surgical reintervention (44%).

CONCLUSIONS Early results with the Edwards SAPIEN valve in the pulmonary position demonstrate an ongoing high rate of procedural success.

KEY WORDS congenital heart disease, Edwards SAPIEN pulmonic valve, percutaneous pulmonary valve implantation, pulmonary regurgitation, pulmonary stenosis

Acquired right ventricular outflow tract (RVOT) dysfunction (stenosis or regurgitation) after repair of congenital heart disease has been treated in the past 4 decades by surgical intervention. However, because of the nonliving nature of replacement conduits and valves, patient growth, and small homograft diameter, gradual degeneration occurs in the years following primary

From ^aCentre Hospitalier Universitaire de Nantes, Institut du Thorax, Fédération des Cardiopathies Congénitales, Service de Cardiologie, Nantes, France; ^bMarie-Lannelongue, Pole de Chirurgie des Cardiopathies Congénitales, M3C- Centre de Référence Malformations Cardiaques Congénitales Complexes, Université Paris-Sud, Paris, France; ^cInserm UMR-S999, Hôpital Marie Lannelongue, Université Paris-Sud, Université Paris-Saclay, Le Kremlin-Bicêtre, France; ^dINSERM, CNRS, Universitaire de Nantes, l'Institut du Thorax, Nantes, France; ^eEvelina London Children's Hospital, Guy's and St. Thomas's NHS Foundation Trust, London, United Kingdom; and the ^fDepartment of Pediatric and Congenital Heart Disease, University of Lille-Nord de France, Lille, France. The authors have reported that they have no relationships relevant to the contents of this paper to disclose.

intervention (1–3). Repeated open-heart surgery for pulmonary valve replacement is often required and associated with low mortality but significant morbidity. Early intervention to prevent the potentially irreversible dysfunction of the right ventricle is now generally accepted (4). Since the first percutaneous pulmonary valve implantation (PPVI) in 2000 (5), the transcatheter approach has become an approved treatment for the management of dysfunctional RVOT. Historically, the Melody valve (Medtronic, Minneapolis, Minnesota) was the first transcatheter heart valve system developed, with available diameters ranging from 18 to 22 mm, to replace a dysfunctional RVOT. Results from clinical trials have demonstrated its efficacy and safety (6–9). However, the RVOT at the time of intervention may exceed the available diameters, particularly in patients with transannular patch after tetralogy of Fallot (TOF) repair or in patients with large biological implants.

The Edwards SAPIEN transcatheter heart valve (Edwards Lifesciences, Irvine, California) was initially introduced as a transcatheter alternative to surgical valve replacement in elderly, inoperable patients with severe aortic stenosis (10,11). This new heart valve system obtained Conformité Européene certification in Europe for PPVI at the end of 2010. It is available in 20-, 23-, 26-, and 29-mm diameters. Although PPVI with the Melody valve may be feasible in large conduits (e.g. with stenting of the left pulmonary artery), the Edwards SAPIEN valve, developed for revaluations in RVOT conduits of diameters between 20 and 29 mm, could be an interesting alternative (12–14).

The aim of the present study was to describe the short-term efficacy and safety of the Edwards SAPIEN valve in a French registry of patients who underwent PPVI between 2011 and 2017.

METHODS

STUDY DESIGN AND PATIENT SELECTION CRITERIA.

Between April 2011 and May 2017, a prospective, nonrandomized, observational, multicenter registry collected data on the safety, procedural success, and short-term effectiveness of the Edwards SAPIEN valve in patients with full conduit or patched RVOT dysfunction. All consecutive patients who underwent transcatheter RVOT treatment using the Edwards SAPIEN XT or Edwards SAPIEN 3 were prospectively

enrolled from 3 tertiary French institutions (15,16). Patients were selected according to usual indications (17), including symptomatic patients with Doppler mean gradients >35 mm Hg and/or at least moderate pulmonary regurgitation (PR) and asymptomatic patients with echocardiographic criteria (Doppler mean gradient >40 mm Hg), and/or hemodynamic criteria (RVOT obstruction with right ventricular systolic pressure $\geq 2/3$ systemic pressure), and/or magnetic resonance imaging (MRI) criteria (right ventricular end-diastolic volume index >150 ml/m², right ventricular end-systolic volume index >80 ml/m² with significant pulmonary valve regurgitation). Patients <5 years of age and those weighing <30 kg were excluded. Patients with active endocarditis, infection or sepsis, or pregnancy were not suitable candidates for PPVI. The following primary outcomes were collected: procedural success (no or trivial regurgitation on post-implantation angiography and a post-implantation systolic peak-to-peak gradient ≤ 20 mm Hg), adverse events including PPVI-related death, and short-term follow-up success.

Informed consent was obtained from all patients and/or their legal guardians. The study was approved by French organizations (Commission Nationale de l'Informatique et des Libertés and Groupe Nantais d'Ethique dans le Domaine de la Santé). The reimbursement of the Edwards SAPIEN valve is not yet supported in France, and the study was funded by the Ministry of Health (Soutien aux Techniques Innovantes et Coûteuses, 2008).

PRE-PROCEDURAL EVALUATION. All patients underwent pre-procedural assessment including medical examination, standard laboratory testing, electrocardiography, chest radiography, and transthoracic echocardiography. Computed tomography and/or cardiac MRI was performed, unless contraindicated, to further define the size and anatomy of the RVOT and the relationship between the coronary arteries and the RVOT conduit. Cardiac MRI was also used to quantify ventricular volumes and function and PR fractions. The following echocardiographic data were obtained: RVOT gradient, presence of PR (18), right ventricular pressure, right and left ventricular diameters and systolic function, and left ventricular ejection fraction.

PROCEDURES. All procedures were performed through a percutaneous puncture of the femoral vein (right or left) or the right jugular vein, under general anesthesia and mechanical ventilation. Before the PPVI intervention, aortic root angiography (or selective coronary angiography) was systematically performed with balloon angioplasty simultaneously inflated in the RVOT to look for induced coronary

TABLE 1 Patient Characteristics (n = 71)

Age at PPVI (yrs)	26.8 (12.8–70.1)
Women	23 (32.4)
Weight (kg)	65.1 ± 16.1
BMI (kg/m ²)	23.3 ± 6.1
NYHA functional class	
I	9 (12.7)
IIa/IIb	33 (46.5)/13 (18.3)
III	14 (18.7)
IV	2 (2.8)
ECG	
Sinus rhythm	66 (92.9)
Atrial fibrillation	5 (7.1)
Pacemaker or implantable cardioverter-defibrillator	9 (12.7)
Right bundle branch block	59 (83.1)
QRS duration (ms)	141.8 ± 30.7
Congenital heart disease	
Tetralogy of Fallot	28 (39.5)
Aortic valve disease (Ross procedure)	18 (25.3)
Pulmonary atresia, ventricular septal defect	6 (8.4)
Common arterial trunk	8 (11.3)
Double-outlet right ventricle	3 (4.2)
Other	8 (11.3)
Previous cardiac surgeries	
0	1 (1.4)
1	12 (16.9)
2	21 (29.6)
3	28 (39.5)
4	6 (8.4)
5	3 (4.2)
Age at first surgery	274 days (1 day to 65.9 yrs)
Time since last surgery (yrs)	10.3 (0.3–47.1)
Primary indication for implantation	
Mixed lesion	27 (38.1)
Pulmonary stenosis	24 (33.8)
Pulmonary regurgitation	20 (28.1)

Values are median (range), n (%), or mean ± SD.

BMI = body mass index; ECG = electrocardiography; NYHA = New York Heart Association; PPVI = percutaneous pulmonary valve implantation.

compression. Thereafter, a medium-pressure balloon was placed through the RVOT to assess the maximal RVOT diameter. Most patients underwent previous or concomitant pre-stenting of the RVOT. The RVOT angiography was repeated before performing the PPVI as described previously (19).

All patients received peri-interventional antibiotic prophylaxis with second-generation cephalosporin and were pre-treated with heparin (70 IU/kg). Few patients received protamine after the procedure.

FOLLOW-UP. Clinical assessment, electrocardiography, and transthoracic echocardiography were performed at 24 h, at discharge, and 1 month after implantation. Chest radiography was performed at

TABLE 2 Anatomy of the Right Ventricular Outflow Tract (n = 71)

RVOT conduit size (mm)	22 ± 3.8
>22	48 (67.6)
>26	7 (9.9)
RVOT conduit type	
Bioprosthesis valve	40 (56.4)
Bioprosthesis	19 (26.8)
Homograft	21 (29.6)
Valved conduit (biological or synthetic)	12 (16.9)
Hancock	6 (8.5)
Contegra	4 (5.6)
Vascutek	2 (2.8)
Nonvalved conduit	3 (4.2)
Native (or noncircular patched RVOT)	16 (22.5)

Values are mean ± SD or n (%).

RVOT = right ventricular outflow tract.

24 h to assess valve morphology and evidence of stent fracture. Patient survival status and surgical or percutaneous reintervention at 1 year were collected.

STATISTICAL ANALYSIS. Continuous variables are expressed as median (range) or as mean ± SD or mean (range) if normally distributed. Nominal variables are expressed as numbers and percentages. A mixed model was used to evaluate global evolution after PPVI. Nominal variables were analyzed using the chi-square test, the Wilcoxon signed rank test, and the Mann-Whitney *U* test. A 2-tailed *p* value <0.05 was considered to indicate statistical significance. SPSS (SPSS Inc., Chicago, Illinois) was used for statistical analysis.

RESULTS

PATIENT CHARACTERISTICS. The characteristics of the population are summarized in **Table 1**. The median age was 26.8 years (range 12.8 to 70.1 years), and the majority of patients (64.8%) were in New York Heart Association functional class II. Conotruncal disease (common arterial trunk, TOF and variants) was present in 45 patients (63.4%), previous Ross surgery in 18 (25.3%), and other diagnoses in 8 (11.3%). Patients had a median of 2 previous cardiac surgical procedures (range 0 to 5). Indication for valve implantation was pure stenosis in 33.8% of patients, pure regurgitation in 28.1%, and mixed lesions in 38.1%. RVOT anatomy before the procedure is summarized in **Table 2**. The nature of the RVOT before PPVI was a bioprosthesis in 40 patients (56.4%), a conduit (valved or nonvalved) in 15 patients (21.1%),

TABLE 3 Procedural Characteristics (n = 71)

Vascular access	
Femoral vein	66 (92.9)
Jugular vein	5 (7.1)
Successfully implanted valves	68 (95.8)
Diameter of successfully implanted valves (mm)	
20	1 (1.5)
23	41 (60.3)
26	22 (32.3)
29	4 (5.9)
Valve generation	
SAPIEN XT	61 (89.7)
SAPIEN 3	7 (10.3)
RVOT pre-stenting	70 (98.6)
Stent placed at the time of PPVI	58 (82.9)
Stent placed before PPVI	12 (17.1)
Number of stent used per patients	
0	1 (1.4)*
1	57 (80.3)
2	9 (12.7)
3 or 4	4 (5.6)
Stent used	85 (100)
Stent intrastent LD max EV3	42 (49.4)
Covered CP 8 Zigs stent	21 (24.7)
Bare CP 8 Zigs stent	10 (11.8)
Palmaz Stent	3 (3.5)
Andrastent XXL	6 (7.1)
Sinus XL Optimed	3 (3.5)
Post-dilatation performed for pre-stenting	21 (24.7)
Procedure time (min)	135 (75-255)
Fluoroscopy time (min)	29.1 (6.6-96.5)
Amount of iodinated contrast (ml)	150 (55-306)

Values are n (%) or median (range). *This patient had a valved conduit (Hancock tube).

PA = pulmonary artery; other abbreviations as in Tables 1 and 2.

and native (or noncircular patched RVOT) in 16 patients (22.5%).

PROCEDURAL RESULTS. Procedural data are summarized in Table 3. Pre-stenting was performed in 70 patients (98.6%), of whom 12 (17.1%) had 1 or several stents placed during a previous procedure. All 16 patients with native RVOTs or patched RVOTs were pre-stented, either before (50%) or during (50%) the procedure. The valve was successfully delivered in 68 patients (95.8%). Post-dilatation was performed in 3 subjects using a 1-mm smaller balloon diameter than the delivery system diameter. In 1 patient (the first patient included in the study), transcatheter heart valve migration occurred after deployment and sub-optimal impaction. The migrated valve was surgically retrieved with a simultaneous and uneventful RVOT reconstruction with a Hancock valved conduit. In another patient, the procedure was aborted after pre-stenting because of failure of valve positioning in

the RVOT due to high angulation between the pulmonary trunk and the pulmonary arteries; the delivery system was surgically removed through the femoral vein without cardiopulmonary bypass. In another patient, the valve was positioned too distally in the left pulmonary artery with right pulmonary artery jailing, which required surgery several months later. Associated procedures were performed in 4 cases involving pulmonary artery angioplasties, with stenting for 3 patients and without stenting for 1 patient.

The median procedural time was 135 min (range 75 to 255 min).

PROCEDURAL COMPLICATIONS. Ten patients (14.1%) experienced adverse events. Major complications were reported in 4 patients (5.6%). Three of the 4 major complications occurred in the first 15 patients undergoing the procedure. Two major complications were associated with failed delivery, as described earlier. One-third complication involved the death of a 23-year-old man with TOF after successful PPVI. Major hemoptysis and hemothorax attributed to distal pulmonary artery perforation by the stiff guidewire occurred at the time of extubation, resulting in irreversible brain damage and death. A fourth complication was the occlusion of the left anterior descending coronary artery during PPVI. The patient was a 34-year-old woman with a history of radiotherapy for Hodgkin's disease and Ross procedure performed 16 years before for post-endocarditis aortic regurgitation. The valve was successfully implanted, but the patient experienced ventricular fibrillation because of the occlusion of the left anterior descending coronary artery. The cause was an extrinsic compression triggered by a mediastinal block displacement during valve implantation. Rescue percutaneous revascularization was performed with the implantation of a bare-metal stent, with a favorable outcome (20).

Minor complications occurred in 6 patients (10.5%): 1 arteriovenous fistula between the right femoral artery and vein needing vascular surgery, 1 false aneurysm of the left femoral artery, 2 minor bleeding events, 1 endovascular defibrillator lead displacement, and 1 local abscess at the right femoral access.

HEMODYNAMIC AND ECHOCARDIOGRAPHIC CHARACTERISTICS BEFORE AND AFTER THE PROCEDURE. Mean right ventricular systolic pressure, systolic peak-to-peak gradient across the RVOT, and right ventricular/aortic pressure ratio were all significantly reduced after the procedure (Table 4). PR was graded as 2 or more in 40 patients (70.2%) before

TABLE 4 Hemodynamic Characteristics Before and After Pulmonary Valve Implantation

	Before Procedure (n = 68)	After Procedure (n = 68)	p Value
RV systolic pressure (mm Hg)	59.2 (19-120)	34.5 (20-59)	<0.0001
PA pressure (mm Hg)	13.6 (5-27)	16.9 (8-46)	<0.0001
Systolic peak-to-peak RV-PA gradient (mm Hg)	34.5 (1-87)	10.5 (1-28)	<0.0001
RV/aortic pressure ratio	0.65 (0.21-1.2)	0.31 (0.21-0.9)	<0.0001

Values are mean (range).

PA = pulmonary artery; RV = right ventricular.

the procedure and was assessed as none (n = 61) or trivial (n = 7) after PPVI.

Transthoracic echocardiography before and after PPVI showed significant decreases in estimated right ventricular systolic pressure and mean gradient at discharge (Table 5). One month after PPVI, PR was assessed as none or trivial in 66 of 67 patients who underwent transthoracic echocardiography.

FOLLOW-UP. The median hospital stay was 4 days (range 2 to 49 days), and all patients were followed for at least 1 month. Two major adverse events occurred during follow-up, including acute pulmonary edema few hours after PPVI and hemolysis needing post-dilatation at 15 days. The first event was experienced by a 64-year-old woman medically treated for chronic severe respiratory failure. She had undergone 3 previous open-heart cardiac procedures for TOF, and PPVI was indicated for pure regurgitation. She had severe left and right systolic ventricular dysfunction. A few hours after successful PPVI, she experienced major acute pulmonary edema that resolved with diuretic agents, continuous positive airway pressure, and inotropic supports. The other patient with an event was a 26-year-old man (the second patient included in the study) with a history of Ross procedure. Ten days after PPVI, the patient experienced transient hemolysis, and post-dilatation was performed for mild PR related to a submaximal valve deployment.

At 1-year follow-up (1-year follow-up information were available in 92% of patients), the death rate was 2.9%. As mentioned, the first death occurred a few hours after PPVI. The second case was observed 11 months after the procedure, secondary to heart failure. Three patients underwent surgical reintervention (4.4%) (indications for reintervention: 1 subacute endocarditis, 1 bioprosthesis dysfunction, and 1 heart transplantation).

TABLE 5 Echocardiographic Characteristics Before and After Pulmonary Valve Implantation

	Before Procedure (n = 71)	At Discharge (n = 65)	At 1 Month (n = 67)
RV pressure (mm Hg)	74.9 (35-116)	42.9 (25-70)*	40.1 (20-48)
Flow velocity RVOT (m/s)	3.8 (1.8-5.3)	2.5 (1.5-3.9)	2.4 (1.7-3.1)
Mean gradient (mm Hg)	38.1 (7-87)	16.7 (5-42)*	13.8 (6-24)
Pulmonary regurgitation			
None/trivial	17	52	53
Mild	12	1	0
Moderate	16	0	0
Severe	12	0	0
LEVF (%)	56.3 (30-70)	56.8 (30-75)	56.2 (30-70)

Values are mean (range) or n. *p < 0.0001.

LEVF = left ventricular ejection fraction; other abbreviations as in Tables 2 and 4.

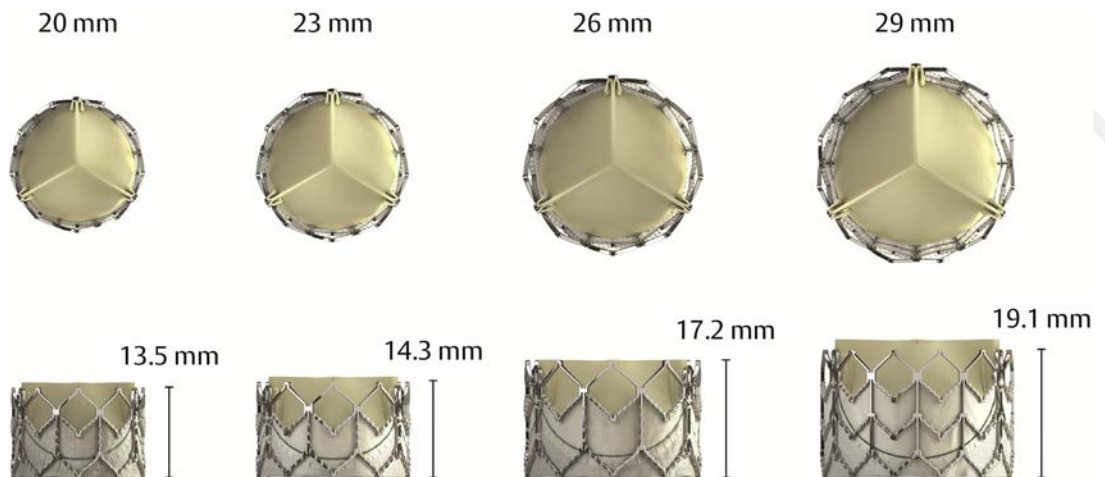
DISCUSSION

This study demonstrates that PPVI using the Edwards SAPIEN pulmonic valve can be safely performed in patients with RVOT dysfunction with promising short-term outcomes. To the best of our knowledge, it is the largest national cohort ever reported of patients treated with the Edwards SAPIEN valve implanted in the pulmonary position.

PPVI is performed to prolong the life span of RVOT conduits and to allow a reduction in the number of subsequent open-heart procedures in patients with congenital heart diseases and dysfunctional RVOTs (17,21). The first experience of PPVI was reported in 2000 with the Melody valve (5), which is still the most widely used valve nowadays. It is composed of a segment of bovine jugular vein with a central valve that is sewn inside an expanded platinum-iridium stent. The Melody valve size is limited to a single diameter of 18 mm (dilatable up to 22 mm), and concerns have been reported about stent fracture (7,22) and long-term endocarditis (23,24). The Edwards SAPIEN valve was initially introduced for transcatheter aortic valve replacement (11,25) and subsequently demonstrated promising short-term functionality and durability in the pulmonary position (13,14,26). The Edwards SAPIEN valve is made of a trileaflet bovine pericardial valve sewn into a stainless steel stent (Figure 1). Most important, it is available in 20-, 23-, 26-, and 29-mm diameters allowing suitable match to the patient anatomy.

In our study, the implantation success rate (95.8%) is comparable with that of other studies using the Melody valve (7,27) and the Edwards SAPIEN valve (13). The characteristics of our study

FIGURE 1 Edwards SAPIEN Pulmonic Valve



population, such as age (median 26.3 years) and the presence of a majority of conotruncal diseases (68.4%), are similar to those reported elsewhere. The immediate hemodynamic effectiveness is in line with the findings reported in the COMPASSION (COngenital Multicenter Trial of Pulmonic Valve Regurgitation Studying the SAPIEN IntervENTIONAL THV) trial (13), which assessed the safety and effectiveness of the Edwards SAPIEN valve implanted in the pulmonary position. Our registry thus confirms that the Edwards SAPIEN valve is functional, with significant reduction in invasively measured RVOT gradient and limited paravalvular leak.

Indication for PPVI was initially limited to the treatment of dysfunctional prosthetic conduits inserted in the RVOT but has extended to include the more frequent native and noncircular patched RVOT (28-31). Moreover, the Edwards SAPIEN valve can be implanted in a native conduit with a diameter up to 28 mm, which is not possible with the Melody[®] valve. In our study, 16 patients (22.5%) had native RVOTs (or patched RVOTs) before PPVI. All of these patients underwent pre-stenting, and one-half had a 2-step procedure. Some investigators argue that a 2-step procedure is preferable to allow embedding of the stent into the pulmonary artery wall and to provide a stable and safe landing zone for the valve to be implanted (14,26,29). As previously described (26), we confirm that PPVI using the Edwards SAPIEN valve in native or patched RVOT is technically feasible.

Our procedural complication rate was 14.1% (60% of which were minor complications). This high rate is not unexpected, as PPVI is a complex procedure

performed in high-risk patients (many with previous surgery). However, we report 1 case of early procedural death. Periprocedural mortality is usually very low with PPVI and can be caused by coronary compression leading to acute myocardial infarction (7,8), conduit rupture (32), and pulmonary artery perforation. In our patient's case, major hemoptysis and hemothorax were probably related to guidewire injury to the left upper pulmonary lobe, an adverse event that has been previously described (33). Another patient, described in a separate case report (20), experienced extrinsic coronary compression. The coronary compression due to PPVI is a well-known and previously described complication (32,34,35). Coronary compression occurs in approximately 5% to 6% of all patients undergoing PPVI (21,36,37) during balloon compression testing but not with actual PPVI; the rate with PPVI is considerably lower because of the compression testing performed prior to the procedure. Commonly, coronary compression is associated with abnormal coronary artery anatomy (especially in patients with TOF or transposition of the great arteries). Yet our patient had normal coronary anatomy, reassuring pre-procedural imaging, and normal balloon angioplasty with a balloon 22 mm in diameter. The coronary compression turned out to be secondary to chest radiotherapy, which may require special caution in these patients.

As previously described (33), this study shows a marked learning curve affecting outcomes after PPVI, with improved safety and decreased adverse event occurrence (such as valve migration, coronary artery compression) observed with time and experience.

Most procedural complications occurred in the first patients undergoing the procedure. Moreover, 2 of the 3 patients in whom the valve could not be delivered (because of migration after deployment and failure of valve positioning in the RVOT) were the first patients at their respective centers. The Edwards SAPIEN valve is difficult to position because of the RVOT anatomy and the valve design. The Edwards SAPIEN 3 valve with the Commander delivery system facilitates implantation thanks to improved device flexibility and decreased delivery profile.

STUDY LIMITATIONS. This study was limited by its descriptive nature and its relatively small size, although it is the largest national cohort ever described. Standardized pre-procedural and follow-up assessments, including exercise capacity and cardiac MRI, were not available for all patients. The short follow-up period does not compare with the Melody data and does not allow us to rule out the occurrence of late endocarditis.

CONCLUSIONS

Our French nationwide registry supports the feasibility, safety, and effectiveness of Edwards SAPIEN valve implantation in the pulmonary position in patients with dysfunctional RVOTs and reports

favorable short-term outcomes. Significant improvements in pressure gradient and PR were achieved. However, long-term outcomes must be assessed in further collaborative studies.

ADDRESS FOR CORRESPONDENCE: Dr. Julien Plessis, Service de Cardiologie, Centre Hospitalier Universitaire de Nantes, Hôpital Nord-Laennec, Boulevard Jacques Monod, 44093 Nantes Cedex, France. E-mail: julien.plessis@chu-nantes.fr.

PERSPECTIVES

WHAT IS KNOWN? The Edwards SAPIEN valve was initially designed as a transcatheter alternative to surgical aortic valve replacement, and experience in the pulmonary position is still limited.

WHAT IS NEW? In a large cohort of 71 patients included from April 2011 to May 2017, PPVI with the Edwards SAPIEN valve was safe and effective in patients with dysfunctional right ventricle-to-pulmonary artery conduits.

WHAT IS NEXT? Long-term studies are required to confirm the short-term functionality and durability of the Edwards SAPIEN valve implanted in the pulmonary position.

REFERENCES

1. Bielefeld MR, Bishop DA, Campbell DN, Mitchell MB, Grover FL, Clarke DR. Reoperative homograft right ventricular outflow tract reconstruction. *Ann Thorac Surg* 2001;71:482-7.
2. Stark J, Bull C, Stajevic M, Jothi M, Elliott M, de Leval M. Fate of subpulmonary homograft conduits: determinants of late homograft failure. *J Thorac Cardiovasc Surg* 1998;115:506-14.
3. Oosterhof T, Meijboom FJ, Vliegen HW, et al. Long-term follow-up of homograft function after pulmonary valve replacement in patients with tetralogy of Fallot. *Eur Heart J* 2006;27:1478-84.
4. Lim C, Lee JY, Kim WH, et al. Early replacement of pulmonary valve after repair of tetralogy: is it really beneficial? *Eur J Cardiothorac Surg* 2004; 25:728-34.
5. Bonhoeffer P, Boudjemline Y, Saliba Z, et al. Percutaneous replacement of pulmonary valve in a right-ventricle to pulmonary-artery prosthetic conduit with valve dysfunction. *Lancet* 2000;356: 1403-5.
6. Fraisse A, Aldebert P, Malekzadeh-Milani S, et al. Melody (R) transcatheter pulmonary valve implantation: results from a French registry. *Arch Cardiovasc Dis* 2014;107:607-14.
7. McElhinney DB, Hellenbrand WE, Zahn EM, et al. Short- and medium-term outcomes after transcatheter pulmonary valve placement in the expanded multicenter US melody valve trial. *Circulation* 2010;122:507-16.
8. Eicken A, Ewert P, Hager A, et al. Percutaneous pulmonary valve implantation: two-centre experience with more than 100 patients. *Eur Heart J* 2011;32:1260-5.
9. Cheatham JP, Hellenbrand WE, Zahn EM, et al. Clinical and hemodynamic outcomes up to 7 years after transcatheter pulmonary valve replacement in the US melody valve investigational device exemption trial. *Circulation* 2015;131:1960-70.
10. Webb JG, Chandavimol M, Thompson CR, et al. Percutaneous aortic valve implantation retrograde from the femoral artery. *Circulation* 2006;113: 842-50.
11. Gilard M, Eltchaninoff H, Jung B, et al. Registry of transcatheter aortic-valve implantation in high-risk patients. *N Engl J Med* 2012;366:1705-15.
12. Ewert P, Horlick E, Berger F. First implantation of the CE-marked transcatheter Sapien pulmonic valve in Europe. *Clin Res Cardiol* 2011;100:85-7.
13. Kenny D, Hijazi ZM, Kar S, et al. Percutaneous implantation of the Edwards SAPIEN transcatheter heart valve for conduit failure in the pulmonary position: early phase 1 results from an international multicenter clinical trial. *J Am Coll Cardiol* 2011;58:2248-56.
14. Haas NA, Moysich A, Neudorf U, et al. Percutaneous implantation of the Edwards SAPIEN(TM) pulmonic valve: initial results in the first 22 patients. *Clin Res Cardiol* 2013;102:119-28.
15. Hascoet S, Jalal Z, Baruteau A, et al. Stenting in paediatric and adult congenital heart diseases: a French multicentre study in the current era. *Arch Cardiovasc Dis* 2015;108:650-60.
16. Hascoet S, Mauri L, Claude C, et al. Infective endocarditis risk after percutaneous pulmonary valve implantation with the Melody and SAPIEN valves. *J Am Coll Cardiol Interv* 2017;10:510-7.
17. Hascoet S, Acar P, Boudjemline Y. Transcatheter pulmonary valvulation: current indications and available devices. *Arch Cardiovasc Dis* 2014;107:625-34.
18. Lancellotti P, Fattouch K, La Canna G. Therapeutic decision-making for patients with fluctuating mitral regurgitation. *Nat Rev Cardiol* 2015; 12:212-9.
19. Boone RH, Webb JG, Horlick E, et al. Transcatheter pulmonary valve implantation using the Edwards SAPIEN transcatheter heart valve. *Catheter Cardiovasc Interv* 2010;75: 286-94.
20. Baruteau AE, Petit J, Brenot P, Riou JY, Angel CY. Left anterior descending coronary artery occlusion during transcatheter pulmonary valve

- implantation: successful rescue percutaneous revascularization. *J Am Coll Cardiol Interv* 2014;7:1073-4.
- 21.** Gillespie MJ, McElhinney DB. Transcatheter pulmonary valve replacement: a current review. *Curr Pediatr Rep* 2013;1:83-91.
- 22.** Nordmeyer J, Khambadkone S, Coats L, et al. Risk stratification, systematic classification, and anticipatory management strategies for stent fracture after percutaneous pulmonary valve implantation. *Circulation* 2007;115:1392-7.
- 23.** McElhinney DB, Benson LN, Eicken A, Kreutzer J, Padera RF, Zahn EM. Infective endocarditis after transcatheter pulmonary valve replacement using the Melody valve: combined results of 3 prospective North American and European studies. *Circ Cardiovasc Interv* 2013;6:292-300.
- 24.** Patel M, Iserin L, Bonnet D, Boudjemline Y. Atypical malignant late infective endocarditis of Melody valve. *J Thorac Cardiovasc Surg* 2012;143:e32-5.
- 25.** Thomas M, Schymik G, Walther T, et al. One-year outcomes of cohort 1 in the Edwards SAPIEN Aortic Bioprosthesis European Outcome (SOURCE) registry: the European registry of transcatheter aortic valve implantation using the Edwards SAPIEN valve. *Circulation* 2011;124:425-33.
- 26.** Demkow M, Ruzyllo W, Biernacka EK, et al. Percutaneous Edwards SAPIENTM valve implantation for significant pulmonary regurgitation after previous surgical repair with a right ventricular outflow patch. *Catheter Cardiovasc Interv* 2014;83:474-81.
- 27.** Butera G, Milanese O, Spadoni I, et al. Melody transcatheter pulmonary valve implantation. Results from the registry of the Italian Society of Pediatric Cardiology. *Catheter Cardiovasc Interv* 2013;81:310-6.
- 28.** Momenah TS, El Oakley R, Al Najashi K, Khoshhal S, Al Qethamy H, Bonhoeffer P. Extended application of percutaneous pulmonary valve implantation. *J Am Coll Cardiol* 2009;53:1859-63.
- 29.** Boshoff DE, Cools BL, Heying R, et al. Off-label use of percutaneous pulmonary valved stents in the right ventricular outflow tract: time to rewrite the label? *Catheter Cardiovasc Interv* 2013;81:987-95.
- 30.** Boudjemline Y, Brugada G, Van-Aerschot I, et al. Outcomes and safety of transcatheter pulmonary valve replacement in patients with large patched right ventricular outflow tracts. *Arch Cardiovasc Dis* 2012;105:404-13.
- 31.** Malekzadeh-Milani S, Ladouceur M, Cohen S, Iserin L, Boudjemline Y. Results of transcatheter pulmonary valvulation in native or patched right ventricular outflow tracts. *Arch Cardiovasc Dis* 2014;107:592-8.
- 32.** Boudjemline Y, Malekzadeh-Milani S, Patel M, et al. Predictors and outcomes of right ventricular outflow tract conduit rupture during percutaneous pulmonary valve implantation: a multicentre study. *EuroIntervention* 2016;11:1053-62.
- 33.** Lurz P, Coats L, Khambadkone S, et al. Percutaneous pulmonary valve implantation: impact of evolving technology and learning curve on clinical outcome. *Circulation* 2008;117:1964-72.
- 34.** Mauri L, Frigiola A, Butera G. Emergency surgery for extrinsic coronary compression after percutaneous pulmonary valve implantation. *Cardiol Young* 2013;23:463-5.
- 35.** Sridharan S, Coats L, Khambadkone S, Taylor AM, Bonhoeffer P. Images in cardiovascular medicine. Transcatheter right ventricular outflow tract intervention: the risk to the coronary circulation. *Circulation* 2006;113:e934-5.
- 36.** Morray BH, McElhinney DB, Cheatham JP, et al. Risk of coronary artery compression among patients referred for transcatheter pulmonary valve implantation: a multicenter experience. *Circ Cardiovasc Interv* 2013;6:535-42.
- 37.** Fraisse A, Assaidi A, Mauri L, et al. Coronary artery compression during intention to treat right ventricle outflow with percutaneous pulmonary valve implantation: incidence, diagnosis, and outcome. *Catheter Cardiovasc Interv* 2014;83:E260-8.

ABBREVIATIONS AND ACRONYMS

MRI = magnetic resonance imaging

PPVI = percutaneous pulmonary valve implantation

PR = pulmonary regurgitation

RVOT = right ventricular outflow tract

TOF = tetralogy of Fallot