



HAL
open science

Black esophagus: complete esophageal necrosis with lower esophageal perforation.

Lucile Héroin, Pierre-Yves Christmann, Francois Habersetzer, Pierre Mayer

► **To cite this version:**

Lucile Héroin, Pierre-Yves Christmann, Francois Habersetzer, Pierre Mayer. Black esophagus: complete esophageal necrosis with lower esophageal perforation.. *Endoscopy*, 2024, 56 (S 01), <10.1055/a-2226-0404>. <hal-04524171>

HAL Id: hal-04524171

<https://hal.science/hal-04524171v1>

Submitted on 2 Apr 2024

HAL is a multi-disciplinary open access archive for the deposit and dissemination of scientific research documents, whether they are published or not. The documents may come from teaching and research institutions in France or abroad, or from public or private research centers.

L'archive ouverte pluridisciplinaire **HAL**, est destinée au dépôt et à la diffusion de documents scientifiques de niveau recherche, publiés ou non, émanant des établissements d'enseignement et de recherche français ou étrangers, des laboratoires publics ou privés.



Distributed under a Creative Commons CC BY 4.0 - Attribution - International License

Black esophagus: complete esophageal necrosis with lower esophageal perforation

OPEN
ACCESS

Black esophagus or acute esophageal necrosis is a rare condition, mainly reported as case reports in the literature [1]. Its pathogenesis seems to be multifactorial, with ischemia appearing to be the most common etiology in patients with cardiovascular risk factors and chronic medical conditions [2]. Diagnosis can be suggested by computed tomography (CT) findings but is based on upper gastrointestinal endoscopy. Mortality is high (30%). Treatment is conservative in most cases (75.4%), but endoscopic or surgical interventions can be required (25.6%) [3]. We report the case of a 72-year-old man, with no medical history other than diabetes, which was managed with biguanides, who was admitted to the emergency room because of urinary tract infection with sepsis. He was rapidly transferred to intensive care because of hemodynamic instability.

Biology showed acute inflammation with leukocytosis and hyperlactatemia, and acute renal failure. Blood cultures were positive for *Corynebacterium confusum* and *Streptococcus sanguinis*. *Aspergillus* antigen was also positive. The CT scan with injection and ingestion showed a circumferential hydroaeric infiltration of the distal esophagus, with a suspected esophageal rupture, a left basal pneumonitis, and bilateral pleural effusion (► Fig. 1, ► Video 1).

Upper gastrointestinal endoscopy was performed and showed complete esophageal necrosis, from the upper esophagus to the gastroesophageal junction (► Fig. 2), where the necrosis abruptly stopped. The stomach was unharmed. Opacification showed a perforation in the lower esophagus (► Fig. 3).

The patient had expressed his opposition to intensive care when he was alive. The treatment therefore consisted solely of symptomatic therapy, and the patient died within a few hours.

Endoscopy_UCTN_Code_CCL_1AB_2AC_3AH

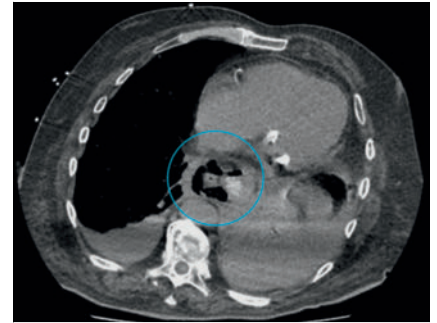
Conflict of Interest

The authors declare that they have no conflict of interest.

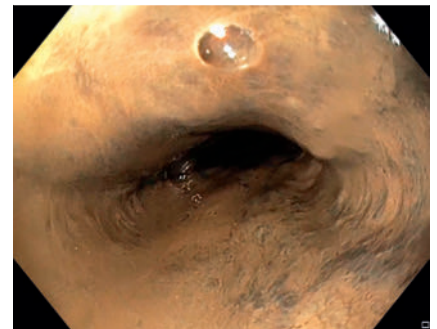
The authors

Lucile Héroin^{1,2}, Pierre-Yves Christmann^{1,2}, François Habersetzer^{1,2,3}, Pierre Mayer^{1,2}

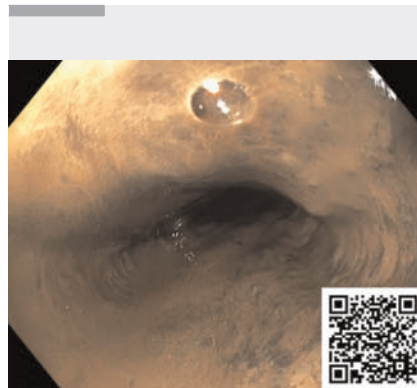
- 1 Department of Hepatology and Gastroenterology, Pôle Hépato-digestif, Nouvel Hôpital Civil, Hôpitaux Universitaires de Strasbourg (HUS), Strasbourg, France
- 2 Digestive Endoscopy, IHU-Strasbourg (Institut Hospitalo-Universitaire), Strasbourg, France
- 3 Inserm U1110, Institute for Viral and Liver Diseases, LabEx HepSYS, University of Strasbourg, Faculty of Medicine, Strasbourg, France



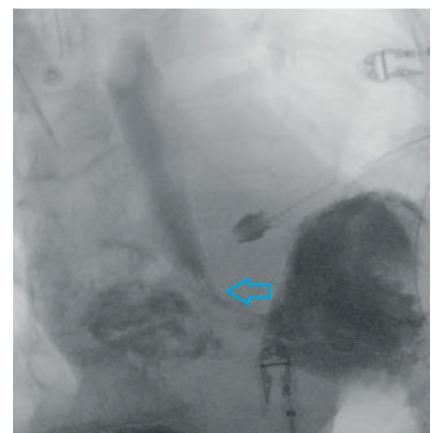
► Fig. 1 Computed tomography scan with injection and ingestion, showing a circumferential hydroaeric infiltration of the distal esophagus, with a suspected esophageal rupture (blue circle)



► Fig. 2 Complete esophageal necrosis.



► Video 1 Complete esophageal necrosis with lower esophageal perforation.



► Fig. 3 Opacification showing the lower esophageal perforation (arrow).

Corresponding author

Lucile Héroin, MD

Service d'Hépatogastroentérologie,
Hôpitaux Universitaires de Strasbourg,
Nouvel Hôpital Civil, Quai Louis Pasteur 1,
67000 Strasbourg, France
lucileheroin@gmail.com

References

- [1] Dias E, Santos-Antunes J, Macedo G. Diagnosis and management of acute esophageal necrosis. *Ann Gastroenterol* 2019; 32: 529–540. doi:10.20524/aog.2019.0418
- [2] Gurvits GE. Black esophagus: acute esophageal necrosis syndrome. *World J Gastroenterol* 2010; 16: 3219–3225. doi:10.3748/wjg.v16.i26.3219

- [3] Schizas D, Theochari NA, Mylonas KS et al. Acute esophageal necrosis: a systematic review and pooled analysis. *World J Gastrointest Surg* 2020; 12: 104–115. doi:10.4240/wjgs.v12.i3.104

Bibliography

Endoscopy 2024; 56: E53–E54

DOI 10.1055/a-2226-0404

ISSN 0013-726X

© 2024. The Author(s).

This is an open access article published by Thieme under the terms of the Creative Commons Attribution License, permitting unrestricted use, distribution, and reproduction so long as the original work is properly cited.

(<https://creativecommons.org/licenses/by/4.0/>)

Georg Thieme Verlag KG, Rüdigerstraße 14,
70469 Stuttgart, Germany



ENDOSCOPY E-VIDEOS

<https://eref.thieme.de/e-videos>



E-Videos is an open access online section of the journal *Endoscopy*, reporting on interesting cases and new techniques in gastroenterological endoscopy. All papers include a high-quality video and are published with a Creative Commons CC-BY license. Endoscopy E-Videos qualify for HINARI discounts and waivers and eligibility is automatically checked during the submission process. We grant 100% waivers to articles whose corresponding authors are based in Group A countries and 50% waivers to those who are based in Group B countries as classified by Research4Life (see: <https://www.research4life.org/access/eligibility/>).

This section has its own submission website at
<https://mc.manuscriptcentral.com/e-videos>