



HAL
open science

Anastomotic biliary stricture after orthotopic liver transplantation: what can we propose after failure of classic ERCP technique to cannulate the stricture?

Pierre Mayer, Pierre-Yves Christmann, Lucile Héroin, Francois Habersetzer

► **To cite this version:**

Pierre Mayer, Pierre-Yves Christmann, Lucile Héroin, Francois Habersetzer. Anastomotic biliary stricture after orthotopic liver transplantation: what can we propose after failure of classic ERCP technique to cannulate the stricture?. *Endoscopy*, 2024, 56 (S 01), 10.1055/a-2248-6398 . hal-04524169

HAL Id: hal-04524169

<https://hal.science/hal-04524169>

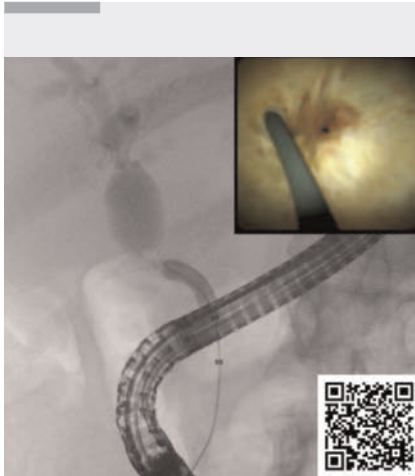Submitted on 27 Mar 2024

HAL is a multi-disciplinary open access archive for the deposit and dissemination of scientific research documents, whether they are published or not. The documents may come from teaching and research institutions in France or abroad, or from public or private research centers.

L'archive ouverte pluridisciplinaire **HAL**, est destinée au dépôt et à la diffusion de documents scientifiques de niveau recherche, publiés ou non, émanant des établissements d'enseignement et de recherche français ou étrangers, des laboratoires publics ou privés.

Anastomotic biliary stricture after orthotopic liver transplantation: what can we propose after failure of classic ERCP technique to cannulate the stricture?

OPEN
ACCESS

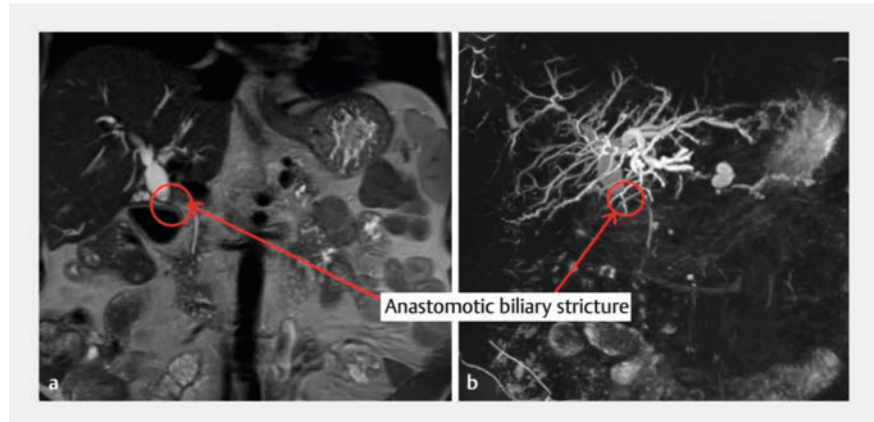


▶ Video 1 Use of single operator cholangioscopy for selective cannulation of punctiform anastomotic stricture post liver transplantation, after failure of cannulation with standard endoscopic retrograde cholangiopancreatography techniques.

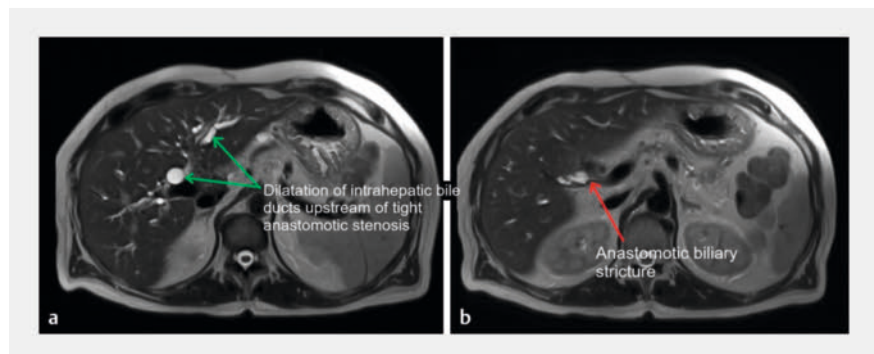
Liver transplantation is the only curative treatment for severe liver disease. Unfortunately, there are several complications associated with liver transplantation. Biliary complications occur in around 15%–30% of cases, with an estimated mortality rate of 10% [1–3].

We report the case of a 66-year-old patient, with a history of recent liver transplantation for alcoholic cirrhosis. He presented with the progressive onset of jaundice associated with disturbances in hepatic tests. Magnetic resonance imaging revealed a biliary anastomosis stricture, with an upstream dilated common bile duct (17 mm) (▶ **Fig. 1**, ▶ **Fig. 2**). We therefore performed an endoscopic retrograde cholangiopancreatography (ERCP).

Biliary cannulation and endoscopic sphincterotomy presented no difficulty. Biliary opacification revealed a short, very tight anastomotic stricture (▶ **Fig. 3**).



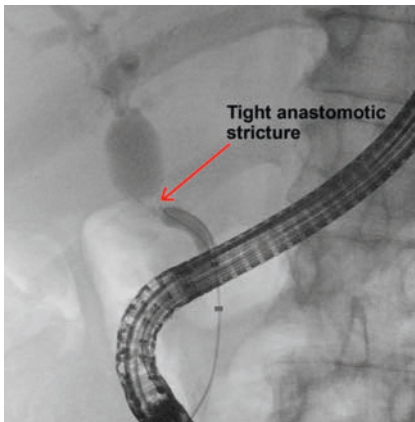
▶ Fig. 1 Coronal section magnetic resonance imaging (MRI) image showing a disparity in caliber between the recipient bile duct and the graft bile ducts. **a** T2 MRI sequence showing anastomotic stricture with dilatation of the upstream bile ducts (circle and red arrow). **b** Three-dimensional MRI reconstruction showing anastomotic stricture with dilatation of upstream bile ducts (circle and red arrow).



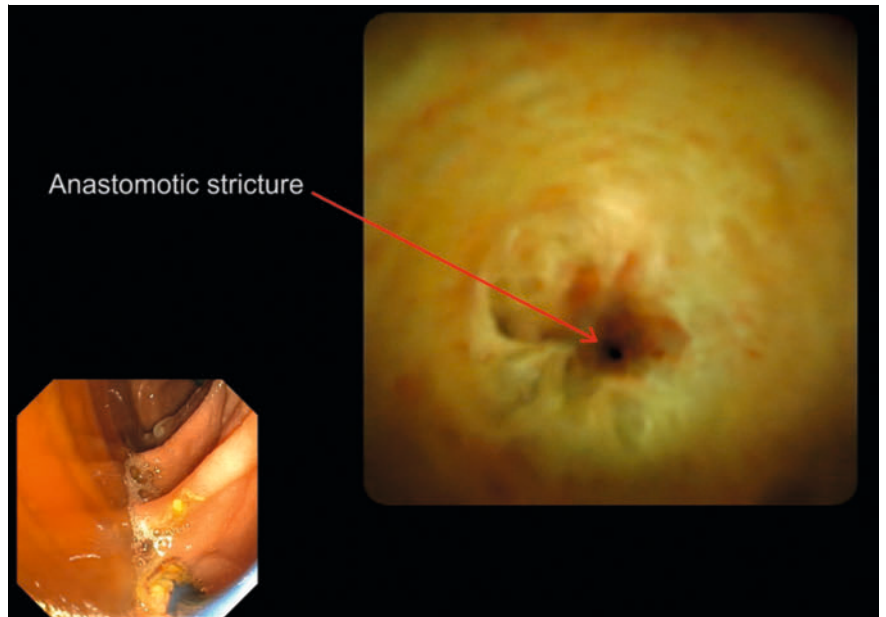
▶ Fig. 2 Cross-sectional magnetic resonance imaging (MRI) image showing a disparity in caliber between the recipient bile duct and the graft bile ducts. **a** T2 MRI scan showing dilatation of the common hepatic duct and intrahepatic bile ducts (green arrows). **b** T2 MRI scan showing biliary anastomotic stricture (red arrow).

However, despite several attempts, it was impossible under fluoroscopy guidance to pass a 0.035-inch or 0.025-inch angled and straight guidewire through the stricture. Given the impossibility of positioning a guidewire through the stricture with the standard technique, we decided to perform a single operator cholangioscopy (SOC).

The use of SOC revealed a punctiform benign stricture with an anastomotic recess (▶ **Fig. 4**). A 0.025-inch straight guidewire was then used, and could be inserted into the right intrahepatic bile ducts under endoscopic and fluoroscopic guidance (▶ **Video 1**). The stricture was then dilated with a 6-mm balloon, followed by placement of a 10 × 80 mm covered metal stent (▶ **Fig. 5**).



► **Fig. 3** Retrograde cholangiography showing tight stricture of the biliary anastomosis (red arrow).



► **Fig. 4** Cholangioscopy image showing punctiform stricture at the biliary anastomosis, with perianastomotic recess.

Few studies in the literature focus on the contribution of SOC as a therapeutic device (such as selective cannulation of the bile ducts under endoscopic control) apart from lithotripsy. SOC probably has its place in the therapeutic management of complex biliary strictures, enabling selective cannulation of the area to be drained or to cross complex strictures such as those occurring after post liver transplantation, as illustrated in this case [4, 5].

Endoscopy_UCTN_Code_TTT_1AR_2AG

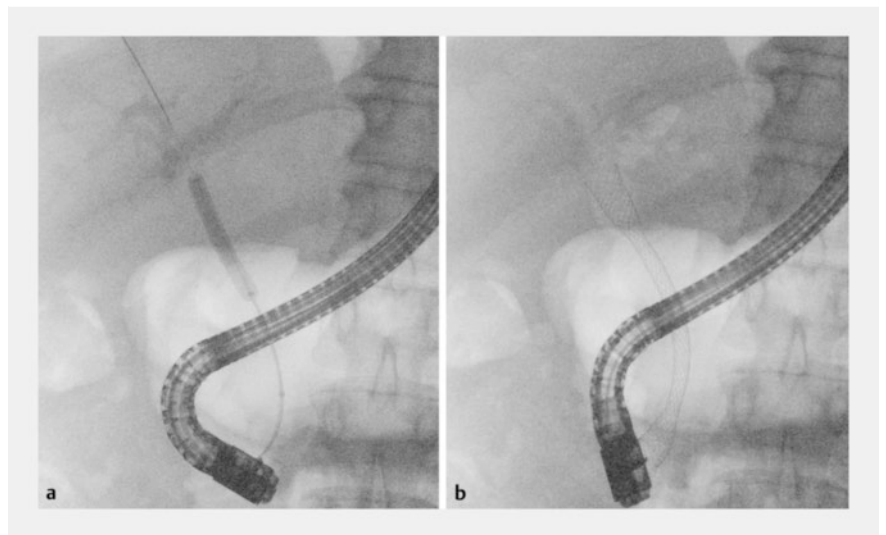
Conflict of Interest

The authors declare that they have no conflict of interest.

The authors

Pierre Mayer^{1,2}, **Pierre-Yves Christmann**^{1,2}, **Lucile Héroin**^{1,2}, **François Habersetzer**^{1,2,3}

- 1 Department of Gastroenterology and Hepatology, Pôle Hépatodigestif, Nouvel Hôpital Civil, Les Hôpitaux Universitaires de Strasbourg (HUS), Strasbourg, France
- 2 Digestive Endoscopy Unit, IHU-Strasbourg (Institut Hospitalo-Universitaire), Strasbourg, France
- 3 Inserm U1110, Institute for Viral and Liver Diseases, LabEx HepSYS, University of Strasbourg, Faculty of Medicine, Strasbourg, France



► **Fig. 5** Endoscopic retrograde cholangiopancreatography after cannulation of the stricture under cholangioscopy. **a** Balloon dilatation of the anastomosis. **b** Placement of a 10 × 80 mm covered metal stent.

Corresponding author

Pierre Mayer, MD
 Department of Gastroenterology and Hepatology, Pôle Hépatodigestif, Nouvel Hôpital Civil, Hôpitaux Universitaires de Strasbourg (HUS), Place de l'Hôpital 1, 67000 Strasbourg, France
 pierre-emmanuel.mayer@chru-strasbourg.fr

References

- [1] Moy BT, Birk JW. A review on the management of biliary complications after orthotopic liver transplantation. *J Clin Transl Hepatol* 2019; 7: 61–71. doi:10.14218/JCTH.2018.00028
- [2] Thuluvath PJ, Pfau PR, Kimmey MB et al. Biliary complications after liver transplantation: the role of endoscopy. *Endoscopy* 2005; 37: 857–863. doi:10.1055/s-2005-870192

- [3] Wojcicki M, Milkiewicz P, Silva M. Biliary tract complications after liver transplantation: a review. *Dig Surg* 2008; 25: 245–257. doi:10.1159/000144653
- [4] Bokemeyer A, Gross D, Brückner M et al. Digital single-operator cholangioscopy: a useful tool for selective guidewire placements across complex biliary strictures. *Surg Endosc* 2019; 33: 731–737. doi:10.1007/s00464-018-6334-6
- [5] Woo YS, Lee JK, Noh DH et al. SpyGlass cholangioscopy-assisted guidewire placement for post-LDLT biliary strictures: a case series. *Surg Endosc* 2016; 30: 3897–3903. doi:10.1007/s00464-015-4695-7

Bibliography

Endoscopy 2024; 56: E150–E152

DOI 10.1055/a-2248-6398

ISSN 0013-726X

© 2024. The Author(s).

This is an open access article published by Thieme under the terms of the Creative Commons Attribution License, permitting unrestricted use, distribution, and reproduction so long as the original work is properly cited.

(<https://creativecommons.org/licenses/by/4.0/>)

Georg Thieme Verlag KG, Rüdigerstraße 14,
70469 Stuttgart, Germany



ENDOSCOPY E-VIDEOS

<https://eref.thieme.de/e-videos>



E-Videos is an open access online section of the journal *Endoscopy*, reporting on interesting cases and new techniques in gastroenterological endoscopy. All papers include a high-quality video and are published with a Creative Commons CC-BY license. *Endoscopy E-Videos* qualify for HINARI discounts and waivers and eligibility is automatically checked during the submission process. We grant 100% waivers to articles whose corresponding authors are based in Group A countries and 50% waivers to those who are based in Group B countries as classified by Research4Life (see: <https://www.research4life.org/access/eligibility/>).

This section has its own submission website at <https://mc.manuscriptcentral.com/e-videos>