

# Longitudinal MR vascular fingerprinting approach tracking physiological changes during repeated MR guided focused ultrasound mediated BBB opening on rats.

**Sébastien Rigollet**<sup>1,2</sup>, Aurélien Delphin<sup>3</sup>, Thomas Ador<sup>4</sup>, Erik Dumont<sup>1</sup>, Chantal Pichon<sup>4,5,6</sup>, Emmanuel Barbier<sup>2,3</sup>, Anthony Delalande<sup>4,5</sup>, Vasile Stupar<sup>2,3</sup>

<sup>1</sup> *Image Guided Therapy, Pessac, France*

<sup>2</sup> *Univ. Grenoble Alpes, Inserm U1216, Grenoble Institut des Neurosciences, Grenoble, France*

<sup>3</sup> *Univ. Grenoble Alpes, Inserm, CHU Grenoble Alpes, CNRS, IRMaGe, Grenoble, France*

<sup>4</sup> *Université d'Orléans, CNRS, UPR 4301, Centre de Biophysique Moléculaire, Orléans, France*

<sup>5</sup> *ART ARNm, Inserm UMS55 and University of Orléans, Orléans, France*

<sup>6</sup> *Institut Universitaire de Paris, Paris, France*

## Introduction

Long-term drug delivery through repeated FUS-induced BBB opening transforms treatment strategies for improved patient outcomes<sup>1</sup>. To optimize and refine treatment parameters for enhanced therapeutic precision, vascular modifications were evaluated with MRI after multiple MR-guided FUS (MRgFUS) treatments on rats. Based on an MR vascular fingerprinting (MRvF) approach<sup>2,3</sup>, we quantified blood volume fraction (BVf), vessel radius (R), and tissue oxygenation saturation (SO<sub>2</sub>). Coupled with cerebral blood flow (CBF) and ex vivo analysis, we propose a complete study of secondary effects on the CNS.

## Methods

BBB was permeabilized with MRgFUS at 4.7T on 18 Wistar rats 4 or 8 times over 4 weeks. A control group of 20 rats received a single treatment and were followed over 1 or 4 weeks (Fig1.A). We transiently opened the BBB with a bolus injection of 1.5E8 homemade lipidic MB followed by a raster scan of 3.8x4mm<sup>2</sup> with continuous 1.5MHz ultrasound pulses during 40s. Two pressures were tested (390kPa and 440kPa peak negative). BBB permeability was assessed using a dynamic contrast enhanced sequence (DCE). The MRI protocol was acquired after FUS treatment including pCASL datasets for CBF quantification, GESFIDSE sequences and USPIO injection (200µmol/kg) to evaluate vascular parameters with MRvF approach<sup>4</sup>. Brains were harvested 1 week after the last treatment for histological quantifications.

## Results/Discussion

BBB was successfully permeabilized after each FUS treatment (Fig.1.D) with increase in area under the curve (AUC) maps, without evident damage in T2-w images and oedema in ADC maps as well as no significant changes in T1 and T2 parameters. After the last treatment, significant increase of BVf and R was observed in the treated region for the 8 treatments at 440kPa group, suggesting vasodilation confirmed by transient CBF reduction<sup>5</sup> (Fig.1.E). Histological staining of BBB seems to confirm our measurements with vessel diameter increase in treated area for the heaviest treatment (Fig.2.D). Tissue

oxygenation is significantly reduced between week 1 and 4 in the treated area (Fig.2.B2). 1 week after the last treatment, astrocytic recruitment increases in the treated area (Fig.2.D). Coupled with increased vascularization (R, BVf) we can suggest higher tissue stress. SO<sub>2</sub> values are always above hypoxic threshold (>40%) and CBF above 50mL/min/100g. Therefore, we are not in a critical situation.

## Conclusion

Long-term repeated BBB opening is safe for the different experimental conditions evaluated but coupled with effects that shouldn't be underestimated such as transient reduction in CBF and SO<sub>2</sub> for rats treated twice a week at 440kPa. Regarding the translation of these therapeutic strategies to deliver anti-tumor drugs to glioblastoma rat models, one shouldn't exceed one session a week to avoid an increase of hypoxia-induced tumor aggressiveness.

## Novelty

Optimizing long-term drug delivery after multiple MRgFUS BBB opening via MR fingerprint analysis of vascular changes.

## Impact

For optimal repeated treatment with FUS induced BBB opening, assessing vascular changes in the CNS is crucial to fine-tune treatment parameters.

## Disclosure

or one of my co-authors have **the following financial interest** or **relationship(s)** to disclose regarding the subject matter of this presentation:

- Erik Dumont owns Image Guided company

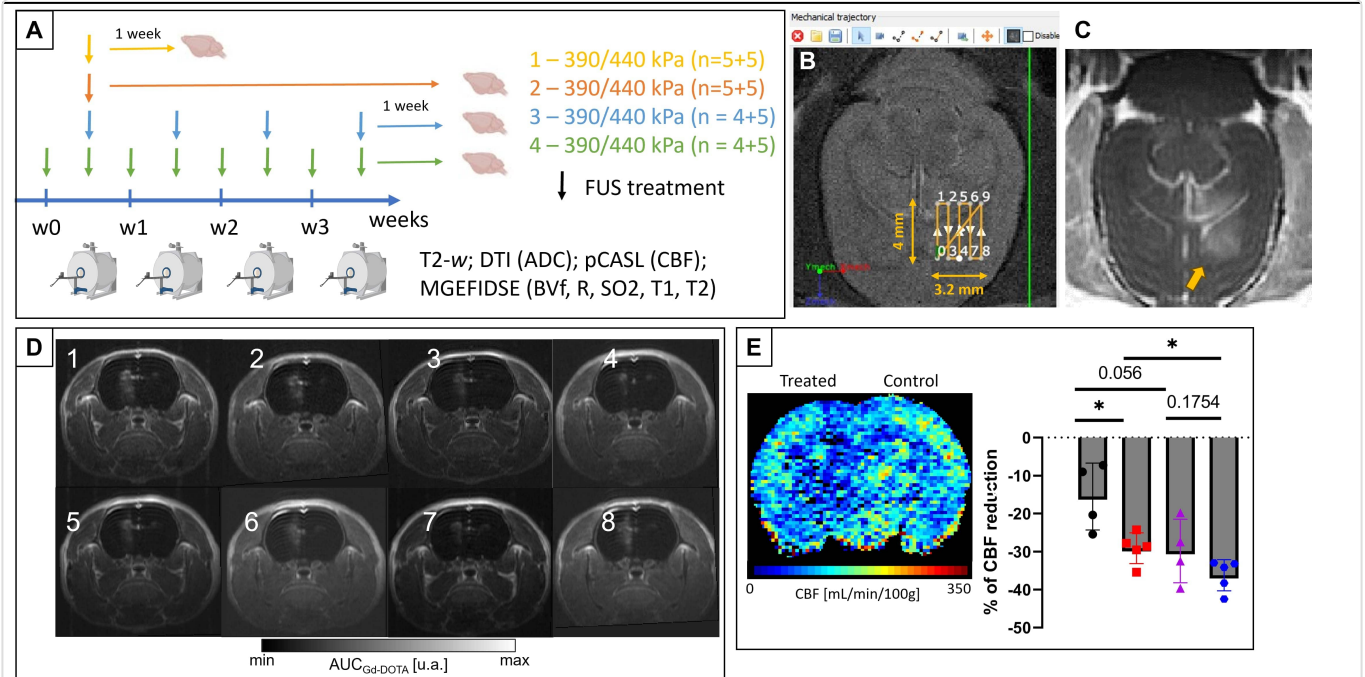
## Acknowledgment

The IRMaGe facility are gratefully acknowledged as well as FRC Neurodon for the fundings.

### Affix

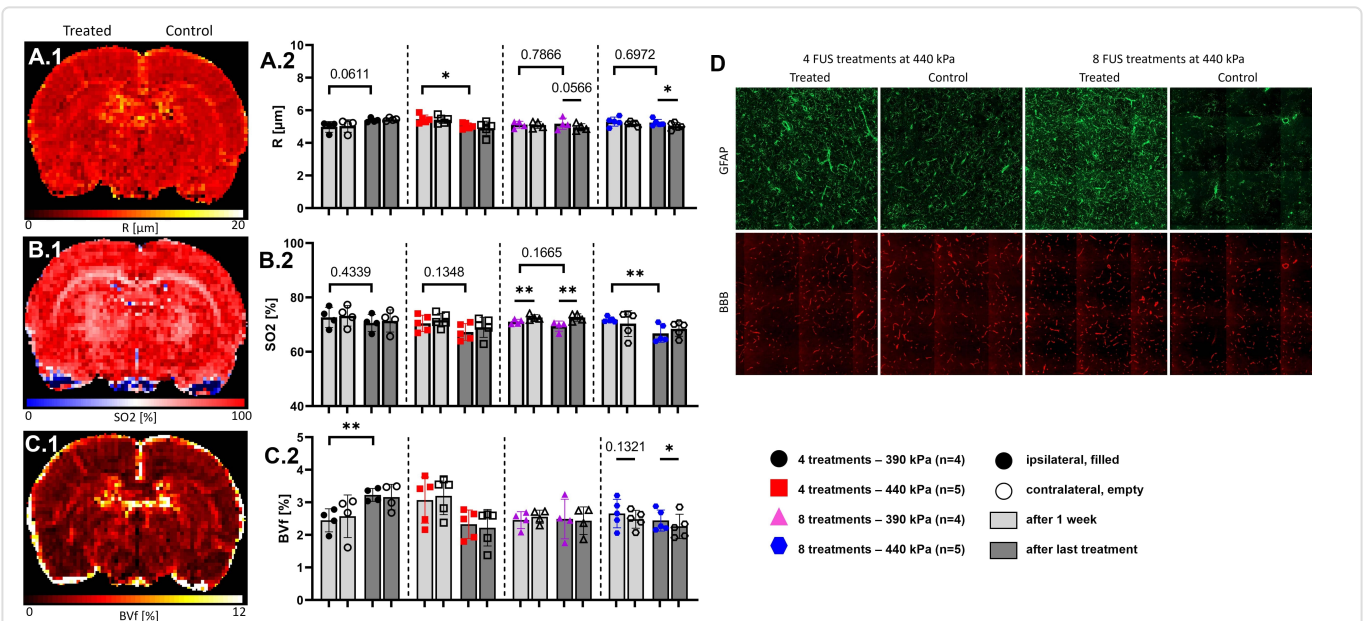
#### References

- 1 Idbah, A. *et al.*, 'Safety and Feasibility of Repeated and Transient Blood-Brain Barrier Disruption by Pulsed Ultrasound in Patients with Recurrent Glioblastoma', *Clinical Cancer Research* 25, 2019, 3793-3801
- 2 Christen, T. *et al.*, 'MR vascular fingerprinting: A new approach to compute cerebral blood volume, mean vessel radius, and oxygenation maps in the human brain', *NeuroImage* 89, 2014, 262-270
- 3 Lemasson, B. *et al.*, 'MR Vascular Fingerprinting in Stroke and Brain Tumors Models', *Scientific Reports* 6, 2016, 37071
- 4 Delphin, A. *et al.* Using 3D realistic blood vessel structures machine learning for MR vascular Fingerprinting. in ISMRM 31st Annual Meeting & Exhibition, May 2022, London, United Kingdom, 2022
- 5 Rigollet, S. *et al.*, 'Cerebral perfusion monitoring after FUS mediated blood-brain barrier opening: a study to evaluate ultrasound bioeffect', in 22nd Annual International Symposium on Therapeutic Ultrasound (ISTU 2023), April 2023, Lyon, France



**Figure 1: Study workflow, BBB permabilization and CBF reduction**

A) Study overview with the FUS treatment, MRI acquisitions and brain harvesting timepoints. B) MR guided FUS trajectory of 3.2 x 4mm<sup>2</sup> drawn on a T2-w scan on Thermoguide®. The striatum is a large subcortical structure allowing an homogeneous BBB opening and it can be targeted easily from one session to another. C) The corresponding T1-w image after Gd-DOTA injection. D) Representative AUC maps from DCE acquisition for a rat that received 8 FUS treatments at 440kPa. E) Representative CBF map and CBF reduction in the treated area at week 4 (color code in Fig.2).



**Figure 2: vascular modifications and neuroinflammation**

Representative parametric maps of R (A.1), SO2 (B.1) and BVf (C.1) reconstructed with MRvF approach. (A-C.2) Corresponding evolution between week 1 and week 4 in ipsi- and contralateral regions. After the last treatment, vascular parameters tend to be modified significantly in the treated region, with increase in R, BVf and reduction of SO2. Student's t-tests were performed (\*p < 0.05; \*\*p < 0.01). D) Representative micrograph of GFAP and BBB staining in the striatum for ipsi- and contralateral areas showing increased astrocytic recruitment and vasodilation for the heaviest treatment.