



HAL
open science

Hepatic non-Gaussian apparent diffusion in NAFLD patients: a dual role for steatosis

Omaïma Saïd, Sabrina Doblas, Dominique Valla, Valérie Paradis, Bernard E van Beers, Philippe Garteiser

► **To cite this version:**

Omaïma Saïd, Sabrina Doblas, Dominique Valla, Valérie Paradis, Bernard E van Beers, et al.. Hepatic non-Gaussian apparent diffusion in NAFLD patients: a dual role for steatosis. European Society of Magnetic Resonance in Medicine and Biology, Oct 2023, Basel (CH), Switzerland. hal-04523455

HAL Id: hal-04523455

<https://hal.science/hal-04523455v1>

Submitted on 27 Mar 2024

HAL is a multi-disciplinary open access archive for the deposit and dissemination of scientific research documents, whether they are published or not. The documents may come from teaching and research institutions in France or abroad, or from public or private research centers.

L'archive ouverte pluridisciplinaire **HAL**, est destinée au dépôt et à la diffusion de documents scientifiques de niveau recherche, publiés ou non, émanant des établissements d'enseignement et de recherche français ou étrangers, des laboratoires publics ou privés.

Hepatic non-Gaussian apparent diffusion in NAFLD patients: a dual role for steatosis

Saïd O.¹, Doblaz S.¹, Valla D.^{1,2}, Paradis V.^{1,3}, Van Beers B.E.^{1,4}, Garteiser P.¹

¹ Inserm, Université Paris Cité, Center for Research on Inflammation Inserm U1149, Paris, France ; ² Beaujon University Hospital, AP-HP, Department of Hepatology, Clichy, France ; ³ Beaujon University Hospital, AP-HP, Department of Pathology, Clichy, France ; ⁴ Beaujon University Hospital, AP-HP, Department of Radiology, Clichy, France

BACKGROUND & AIM

In nonalcoholic fatty liver disease (NAFLD), hepatic fibrosis is strongly associated with patient survival(1). Diffusion imaging is proposed to monitor fibrosis due to the potential effect of the accumulated extracellular matrix components on the diffusion of water molecules(2). In NAFLD, lipid vesicles in the hepatocytes (steatosis) may also alter the diffusion of water molecules (3). Steatosis also has an effect on the measured apparent diffusion coefficient through the imperfect suppression of the fat component from the MR signal(4). Non-Gaussian diffusion imaging, where the apparent diffusion coefficient reflects diffusion kurtosis through the use of large b-values and the addition of second order terms in the signal model, is proposed as a potential marker of hepatic fibrosis(5,6), although performance is not as high in NAFLD patients despite the application of a fat correction method(7).

The main objective of this work is to evaluate the diagnostic performance of non-Gaussian diffusion imaging for liver fibrosis in NAFLD patients in absence of fat correction, with the fat correction proposed and tested by Hanniman & al (7) and with the fat correction proposed by Le Bihan & al (8).

METHOD

Study Population	250
Proportion	67% male
Median age	60 years
Fibrosis stage	54 F0, 64 F1, 41 F2, 67 F3 and 24 F4
Steatosis grade	9 S0, 73 S1, 129 S2 and 39 S3

Table 1 : Patients data

A diffusion sequence was acquired (3T MRI) with 6 b values including a b0 with no diffusion encoding, and the b1 = 200 and b2 = 1500 s/mm² values previously identified as important for the diagnosis of fibrosis (5). The non-Gaussian ADC was calculated without fat correction ("sADC") as described in fig.1-eqn1 (5) and with the correction methods from Hanniman (fig. 1-eqn2) and the Le Bihan (fig.1-eqn3); with Sbi the signal at b-value bi, η the proton density fat fraction (measured separately on each patient using the mDixonQuant method), TE the sequence echo time (75 ms), T2w and T2f the T2 of water (23 ms) and fat (62 ms), respectively(4), and γ the residual fat percentage due to incomplete fat suppression (8.7 % according to (4)).

$$sADC = \frac{\ln(S_{b1}/S_{b2})}{b_2 - b_1} \quad (1)$$

$$sADC_{Hanniman}^{corr} = \frac{1}{b_2} \cdot \ln \left(\frac{(1-\eta) \cdot \exp(-TE/T2_w)}{\frac{S_{b2}}{S_{b1}} \cdot ((1-\eta) \cdot \exp(-TE/T2_w) \cdot \exp(-b_1 \cdot ADC_m^{0-b_2}) + \gamma \cdot \eta \cdot \exp(-TE/T2_f)) - \gamma \cdot \eta \cdot \exp(-TE/T2_f)} \right) \quad (2)$$

$$sADC_{LeBihan}^{corr} = \frac{b_2 \cdot ADC_w^{0-b_2} - b_1 \cdot ADC_w^{0-b_1}}{b_2 - b_1} \quad (3)$$

$$ADC_w^{0-b} = \frac{1}{b} \cdot \ln \left(\frac{(1-\eta) \cdot \exp(-TE/T2_w)}{\frac{S_b}{S_0} \cdot ((1-\eta) \cdot \exp(-TE/T2_w) \cdot \exp(-b_1 \cdot ADC_m^{0-b}) + \gamma \cdot \eta \cdot \exp(-TE/T2_f))} \right) \quad (3a)$$

Figure 1: equations used for sADC evaluations, depicting the different fat correction methods.

Diagnostic performance was assessed using Kruskal-Wallis analysis and multivariate regression with NASH-CRN fibrosis stages and steatosis grades as independent variables.

RESULTS

The population studied consisted of 250 patients (67% male, median age 60 years; 54 F0, 64 F1, 41 F2, 67 F3 and 24 F4; 9 S0, 73 S1, 129 S2 and 39 S3). Significant steatosis (S2 or S3) was present in 42% of F0 patients, 78% of F1 patients, 83% of F2 patients, 75% of F3 patients and 46% of F4 patients. sADC and sADC_{Hanniman}^{corr} were not significantly different between fibrosis stages, and sADC_{LeBihan}^{corr} was significantly different between fibrosis stages (Kruskall-Wallis p = 0.034). When considering steatosis, a significant variation of sADC was obtained without fat correction (figure 2) (Kruskall-Wallis p<0,000001). sADC_{Hanniman}^{corr} and sADC_{LeBihan}^{corr} both did not display any significant differences between steatosis grades. At multivariate regression analysis, sADC and sADC_{Hanniman}^{corr} were significantly determined by steatosis (r_{partial} / p of -0.39 / <0.0001 and -0.13 / 0.03, respectively), while sADC_{LeBihan}^{corr} was not found to be determined by fibrosis or steatosis.

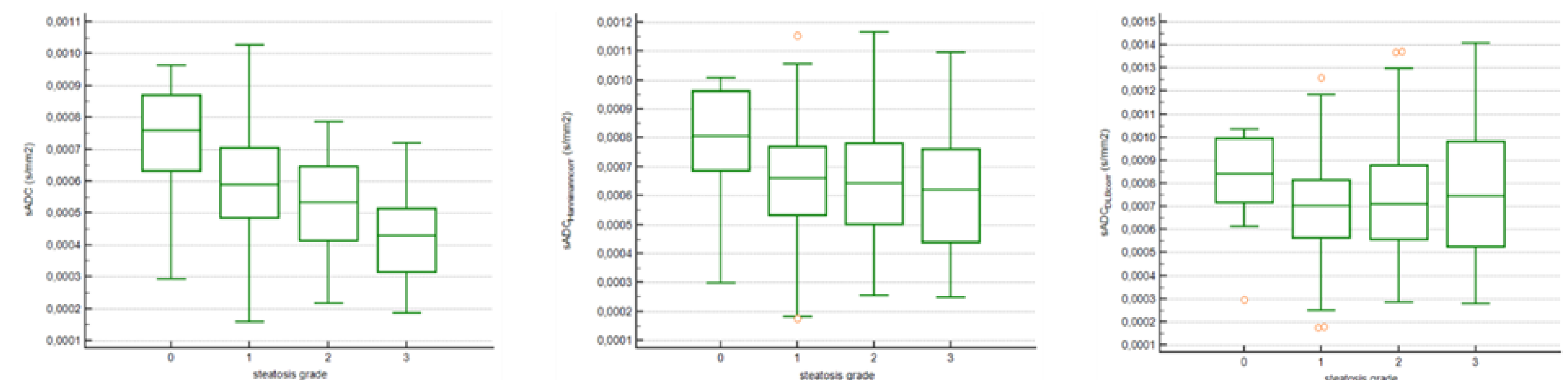


Figure 2: Box plots of sADC vs. steatosis grades (left: no fat correction, middle: Hanniman correction, right: Le Bihan correction). The application of fat correction methods suppresses the effect of steatosis on the apparent diffusion coefficients.

DISCUSSION

Based on our results, it appears that suppressing the residual fat from the signal removes the effect of steatosis on the non-Gaussian ADC. This points towards a diminished importance of lipid vesicles as diffusion barriers and an increased importance of the confounding effect of fat on the MR signal, as determinants of the apparent ADC in the presence of both fibrosis and steatosis. In accordance with previous results on a comparable but different population(7), this NAFLD patient study confirms that sADC_{Hanniman}^{corr} does not appear to depend on fibrosis stages. The correction applied for sADC_{LeBihan}^{corr} removes the influence of steatosis on the diffusion, enabling an effect of fibrosis on the diffusivity of water molecules to appear.

CONCLUSION

The dual effects of hepatic steatosis on diffusion coefficients, through an indirect effect on the MR signal, and through a direct effect on the diffusivity of water molecules, must be carefully unraveled before diffusion-based markers such as the non-Gaussian apparent diffusion coefficient can be considered as potentially useful for fibrosis diagnosis in NAFLD patients.

REFERENCES

- (1) Sanyal AJ, et al. N Engl J Med 2021.
- (2) Taouli B, et al. J Magn Reson Imaging 2008.
- (3) Leitao HS, et al. Radiology 2017.
- (4) Hansmann J, et al. Magn Reson Med 2013.
- (5) Le Bihan D, et al. Radiology 2017.
- (6) Kromrey ML, et al. Radiology 2020.
- (7) Hanniman E, et al. J Magn Reson Imaging 2022.
- (8) Le Bihan D, et al. J Magn Reson Imaging 2023.