



HAL
open science

An unusual complication of acute biliary pancreatitis: an incidental discovery of hemobilia

Pierre Mayer, Antoine Wackenthaler, Pierre-Yves Christmann, François Habersetzer, Pierre de Marini, Lucile Héroin

► **To cite this version:**

Pierre Mayer, Antoine Wackenthaler, Pierre-Yves Christmann, François Habersetzer, Pierre de Marini, et al.. An unusual complication of acute biliary pancreatitis: an incidental discovery of hemobilia. *Endoscopy*, 2023, 55 (S 01), pp.E631 - E632. <10.1055/a-2058-8527>. <hal-04522696>

HAL Id: hal-04522696

<https://hal.science/hal-04522696v1>

Submitted on 27 Mar 2024

HAL is a multi-disciplinary open access archive for the deposit and dissemination of scientific research documents, whether they are published or not. The documents may come from teaching and research institutions in France or abroad, or from public or private research centers.

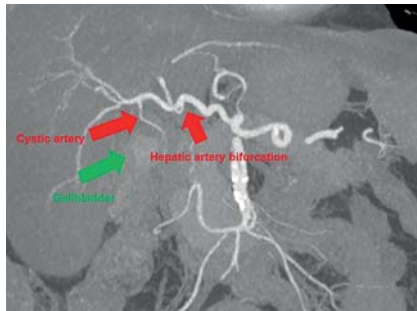
L'archive ouverte pluridisciplinaire **HAL**, est destinée au dépôt et à la diffusion de documents scientifiques de niveau recherche, publiés ou non, émanant des établissements d'enseignement et de recherche français ou étrangers, des laboratoires publics ou privés.



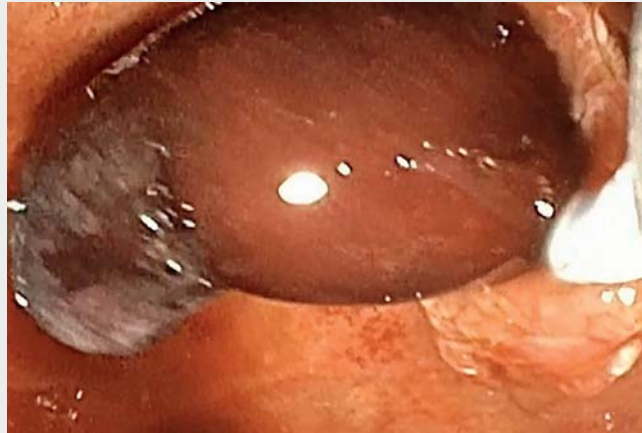Distributed under a Creative Commons CC BY-NC-ND 4.0 - Attribution - Non-commercial use - No Derivative Works - International License

An unusual complication of acute biliary pancreatitis: an incidental discovery of hemobilia

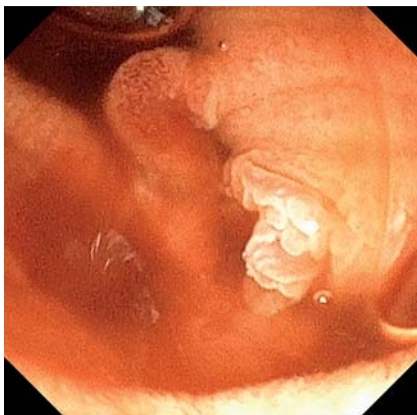OPEN
ACCESS



► **Fig. 1** Coronal section of the initial computed tomography scan, performed to assess the severity of the acute pancreatitis, showing the vascular supply of the liver and gallbladder.



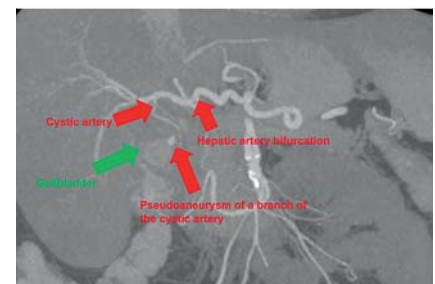
► **Video 1** Initial findings in a patient with early recurrence of biliary pain; endoscopic ultrasonography and endoscopic retrograde cholangiopancreatography revealing hemobilia; subsequent discovery of a pseudoaneurysm of the cystic artery on a repeat computed tomography scan; angiographic findings and successful embolization.



► **Fig. 2** Endoscopic retrograde cholangiopancreatography image showing blood coming from the papilla, confirming hemobilia before biliary cannulation had been performed.

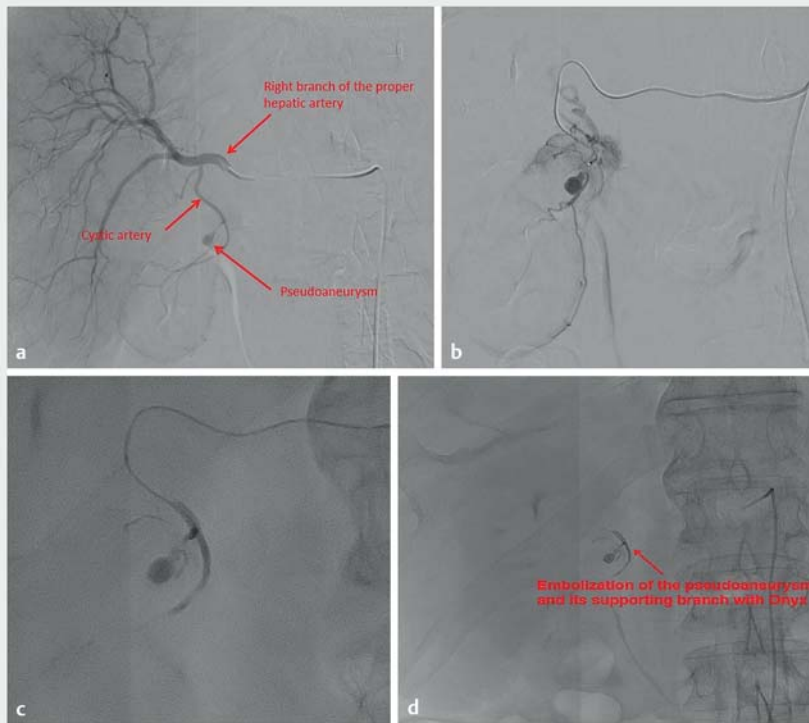
We report here the case of a 71-year-old patient, with a medical history of chronic lung disease and lung adenocarcinoma, who was admitted to our unit with acute biliary pancreatitis. He was on treatment with clopidogrel for a central retinal vein thrombosis. Abdominal ultrasonography revealed dysmorphic hepatomegaly and microlithiasis in the gallbladder. There was no evidence of bile duct dilatation. A computed tomography (CT) scan showed interstitial edematous pancreatitis with no vascular complications (► **Fig. 1**).

While hospitalized, the patient presented with a recurrence of pain and increased disruption of hepatic parameters. An endoscopic ultrasonography (EUS) found echogenic material in the common bile duct, associated with dilatation of the biliary tract and a hepatized gallbladder. Endoscopic retrograde cholangiopancreatography (ERCP) found blood coming out of the papilla (► **Fig. 2**) and an endoscopic sphincterotomy allowed blood clots to be evacuated. At the end of the procedure, the common bile duct was empty and there was no active bleeding

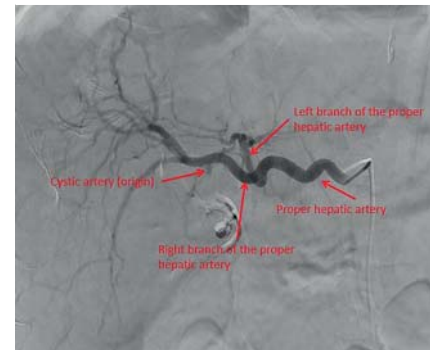


► **Fig. 3** Coronal section from a repeat computed tomography scan, performed 8 days after the first scan and after the discovery of a hemobilia during the endoscopic retrograde cholangiopancreatography, showing a pseudoaneurysm of a branch of the cystic artery.

(► **Video 1**). A post-procedure CT scan showed a pseudoaneurysm of the cystic artery branch (► **Fig. 3**), which had probably developed in the aftermath of the acute pancreatitis. Embolization of this pseudoaneurysm was performed (► **Fig. 4** and ► **Fig. 5**) and led to definitive cessation of the hemorrhage.



► **Fig. 4** Images during embolization of the pseudoaneurysm from the cystic artery showing: **a** the initial angiography from the right branch of the hepatic artery with a Cobra catheter (4Fr); **b** supraselective angiography with Pursue (2.0Fr); **c** a fluoroscopic view; **d** embolization by Onyx.



► **Fig. 5** Angiographic image with a Cobra catheter (4Fr) after embolization; there is no gastroduodenal artery in this patient, with the duodenal and gastroepiploic branches being supplied by the pancreatic-duodenal arches of the superior mesenteric artery.

References

- [1] Berry R, Han J, Girotra M et al. Hemobilia: perspective and role of the advanced endoscopist. *Gastroenterol Res Pract* 2018; 2018: 3670739
- [2] Cathcart S, Birk JW, Tadros M et al. Hemobilia: an uncommon but notable cause of upper gastrointestinal bleeding. *J Clin Gastroenterol* 2017; 51: 796–804
- [3] Parvinian A, Fletcher JG, Storm AC et al. Challenges in diagnosis and management of hemobilia. *Radiographics* 2021; 41: 802–813
- [4] Zhornitskiy A, Berry R, Han JY et al. Hemobilia: historical overview, clinical update, and current practices. *Liver Int* 2019; 39: 1378–1388

Bibliography

Endoscopy 2023; 55: E631–E632

DOI 10.1055/a-2058-8527

ISSN 0013-726X

© 2023. The Author(s).

This is an open access article published by Thieme under the terms of the Creative Commons Attribution-NonDerivative-NonCommercial License, permitting copying and reproduction so long as the original work is given appropriate credit. Contents may not be used for commercial purposes, or adapted, remixed, transformed or built upon. (<https://creativecommons.org/licenses/by-nc-nd/4.0/>)

Georg Thieme Verlag KG, Rüdigerstraße 14, 70469 Stuttgart, Germany



In this case, hemobilia was discovered incidentally, with there being no external bleeding and in the context of nonsevere pancreatitis with no underlying vascular disease. ERCP plays an important role in the removal of biliary obstruction and can provide at least temporary hemostasis. Interventional radiology allows etiological treatment after identification of the mechanism of bleeding during angiography [4].

Endoscopy_UCTN_Code_CCL_1AB_2AC_3AG

Competing interests

The authors declare that they have no conflict of interest.

The authors

Pierre Mayer^{1,2}, Antoine Wackenthaler³, Pierre-Yves Christmann^{1,2}, François Habersetzer^{1,2,4}, Pierre de Marini⁵, Lucile Héroin^{1,2}

- 1 Department of Hepatology and Gastroenterology, Pôle Hépatodigestif, Nouvel Hôpital Civil, Hôpitaux Universitaires de Strasbourg (HUS), Strasbourg, France
- 2 IHU-Strasbourg (Institut Hospitalo-Universitaire), Strasbourg, France
- 3 Department of Radiology, Nouvel Hôpital Civil, Hôpitaux Universitaires de Strasbourg (HUS), Strasbourg, France
- 4 Inserm U1110, Institute for Viral and Liver Diseases, LabEx HepSYS, University of Strasbourg, Faculty of Medicine, Strasbourg, France
- 5 Department of Interventional Radiology, Nouvel Hôpital Civil, Hôpitaux Universitaires de Strasbourg (HUS), Strasbourg, France

Corresponding author

Pierre Mayer, MD

Department of Hepatology and Gastroenterology, Hôpitaux Universitaires de Strasbourg (HUS), 1, place de l'Hôpital, 67000 Strasbourg, France

pierre-emmanuel.mayer@chru-strasbourg.fr