



**HAL**  
open science

## **Superior vena cava graft infection in thoracic surgery: a retrospective study of the French EPITHOR database**

Laura Filaire, Olaf Mercier, Agathe Seguin-Givelet, Olivier Tiffet, Pierre Emmanuel Falcoz, Pierre Mordant, Pierre-Yves Brichon, Philippe Lacoste, Axel Aubert, Pascal Thomas, et al.

### ► **To cite this version:**

Laura Filaire, Olaf Mercier, Agathe Seguin-Givelet, Olivier Tiffet, Pierre Emmanuel Falcoz, et al.. Superior vena cava graft infection in thoracic surgery: a retrospective study of the French EPITHOR database. *Interactive Cardiovascular and Thoracic Surgery*, 2022, 34 (3), pp.378-385. 10.1093/icvts/ivab337 . hal-04522441

**HAL Id: hal-04522441**

**<https://hal.science/hal-04522441>**

Submitted on 21 May 2024

**HAL** is a multi-disciplinary open access archive for the deposit and dissemination of scientific research documents, whether they are published or not. The documents may come from teaching and research institutions in France or abroad, or from public or private research centers.

L'archive ouverte pluridisciplinaire **HAL**, est destinée au dépôt et à la diffusion de documents scientifiques de niveau recherche, publiés ou non, émanant des établissements d'enseignement et de recherche français ou étrangers, des laboratoires publics ou privés.

Cite this article as: Filaire L, Mercier O, Seguin-Givelet A, Tiffet O, Falcoz PE, Mordant P *et al.* Superior vena cava graft infection in thoracic surgery: a retrospective study of the French EPITHOR database. *Interact CardioVasc Thorac Surg* 2022;34:378–85.

## Superior vena cava graft infection in thoracic surgery: a retrospective study of the French EPITHOR database

Laura Filaire <sup>a,\*</sup>, Olaf Mercier <sup>b</sup>, Agathe Seguin-Givelet <sup>c</sup>, Olivier Tiffet <sup>d</sup>, Pierre Emmanuel Falcoz <sup>e</sup>,  
Pierre Mordant <sup>f</sup>, Pierre-Yves Brichon <sup>g</sup>, Philippe Lacoste <sup>h</sup>, Axel Aubert <sup>i</sup>, Pascal Thomas <sup>j</sup>,  
Françoise Le Pimpec-Barthes <sup>k</sup>, Ioana Molnar <sup>l</sup>, Magali Vidal <sup>m</sup>, Marc Filaire <sup>a</sup> and Géraud Galvaing <sup>a</sup>

<sup>a</sup> Department of Thoracic and Endocrine Surgery, Jean Perrin Comprehensive Cancer Centre, Clermont-Ferrand, France

<sup>b</sup> Department of Thoracic and Vascular Surgery and Heart and Lung Transplantation, Hôpital Marie Lannelongue, Paris, France

<sup>c</sup> Thoracic Department, Curie-Montsouris Thorax Institute, Paris, France

<sup>d</sup> Department of Thoracic Surgery, North Hospital, Saint-Étienne, France

<sup>e</sup> Thoracic Surgery Department, Nouvel Hôpital Civil, Strasbourg, France

<sup>f</sup> Division of Thoracic and Vascular Surgery, Hôpital Bichat, Paris, France

<sup>g</sup> Department of Thoracic and Endocrine Surgery, University Hospital of Grenoble, Grenoble, France

<sup>h</sup> Department of Thoracic and Cardiovascular Surgery, Nantes Hospital University, Nantes, France

<sup>i</sup> Department of Thoracic Surgery, Clinique Belledone, Grenoble, France

<sup>j</sup> Department of Thoracic Surgery, Disease of the Oesophagus and Lung Transplantation, North Hospital, Marseille, France

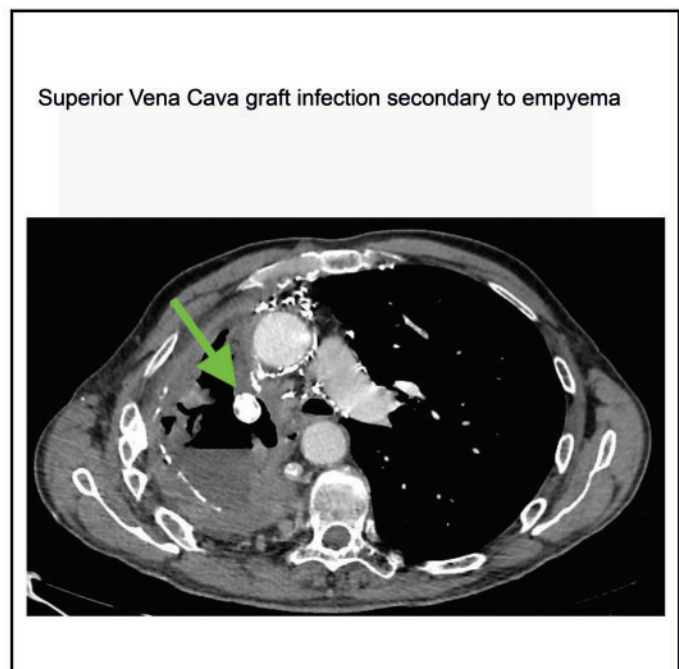
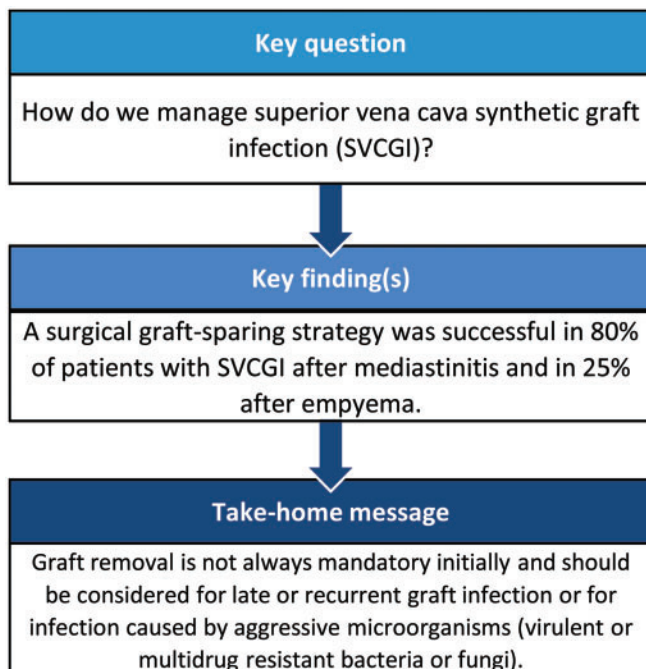
<sup>k</sup> Department of Thoracic Surgery and Lung Transplantation, Hôpital Européen Georges Pompidou, Paris, France

<sup>l</sup> Department of Clinic Research, Jean Perrin Comprehensive Cancer Centre, Clermont-Ferrand, France

<sup>m</sup> Infectious Diseases Unit, Gabriel-Montpied University Hospital, Clermont-Ferrand, France

\* Corresponding author. Department of Thoracic and Endocrine Surgery, Jean Perrin Comprehensive Cancer Centre, 58 rue Montalembert, 63011 Clermont-Ferrand, France. Tel: +33-473278080; fax: +33-473278064; e-mail: laura.filaire@clermont.unicancer.fr (L. Filaire).

Received 1 September 2021; received in revised form 22 October 2021; accepted 31 October 2021



Presented at the virtual French Society of Thoracic and Cardiovascular Surgery meeting, 17 December 2020.

## Abstract

**OBJECTIVES:** To report our experience on the management of superior vena cava graft infection.

**METHODS:** Between 2001 and 2018, patients with superior vena cava synthetic graft or patch reconstruction after resection of intrathoracic tumours or benign disease were selected retrospectively from the French EPITHOR database and participating thoracic centres. Our study population includes patients with superior vena cava graft infection, defined according to the MAGIC consensus. Superior vena cava synthetic grafts in an empyema or mediastinitis were considered as infected.

**RESULTS:** Of 111 eligible patients, superior vena cava graft infection occurred in 12 (11.9%) patients with a polytetrafluoroethylene graft secondary to contiguous contamination. Management consisted of either conservative treatment with chest tube drainage and antibiotics ( $n = 3$ ) or a surgical graft-sparing strategy ( $n = 9$ ). Recurrence of infection appears in 6 patients. Graft removal was performed in 2 patients among the 5 reoperated patients. The operative mortality rate was 25%.

**CONCLUSIONS:** Superior vena cava graft infection may develop as a surgical site infection secondary to early mediastinitis or empyema. Graft removal is not always mandatory but should be considered in late or recurrent graft infection or in infections caused by aggressive microorganisms (virulent or multidrug resistant bacteria or fungi).

**Keywords:** Graft infection • Superior vena cava reconstruction • Non-small-cell lung cancer • Empyema • Mediastinal tumours • Mediastinitis

### ABBREVIATIONS

BPF	Bronchopleural fistula
COPD	Chronic obstructive pulmonary disease
MRSA	Methicillin-resistant <i>Staphylococcus aureus</i>
MSSA	Methicillin-sensitive <i>Staphylococcus aureus</i>
MT	Mediastinal tumour
NPWT	Negative pressure wound therapy
NSCLC	Non-small-cell lung cancer
OWT	Open window thoracostomy
PTFE	Polytetrafluoroethylene
SVC	Superior vena cava
SVCGI	Superior vena cava graft infection

## INTRODUCTION

Surgery extended to the superior vena cava (SVC) for locally advanced non-small-cell lung cancer (NSCLC) or mediastinal tumours (MT) has been shown to have a proven benefit with 5-year survival rates of 36% [1] and 62.5% [2], respectively. Graft reconstruction is performed when >30% of the SVC circumference is involved, without extensive thrombosis and no bulky N2. Different materials are available for initial reconstruction, either biological (venous or pericardial grafts, arterial allografts) or synthetic [Dacron®, polytetrafluoroethylene (PTFE)] with the preferential use of PTFE. Although the surgical results of SVC graft replacement have been well described [3], secondary graft infection has only been reported in a few cases or briefly mentioned in retrospective studies focusing on long-term survival or patency after NSCLC or MT resection. The incidence of SVC graft infection (SVCGI) ranges from 7% to 10%, representing only 2 patients in each study [3, 4]. Recent vascular guidelines have focused essentially on thoracic aorta graft infection, but no clear guidelines are available on the management of SVCGI, which may have potential consequences on adjuvant cancer treatment.

We report our experience on the management of synthetic SVCGI after surgery for thoracic tumours.

## METHODS AND PATIENTS

### Ethical statement

This study was approved by the Institutional Review Board of the French Society of Thoracic and Cardiovascular Surgery on 11 November 2018 (approval number: 2018-10-20-7-52-3-FILA). Individual informed consent was waived.

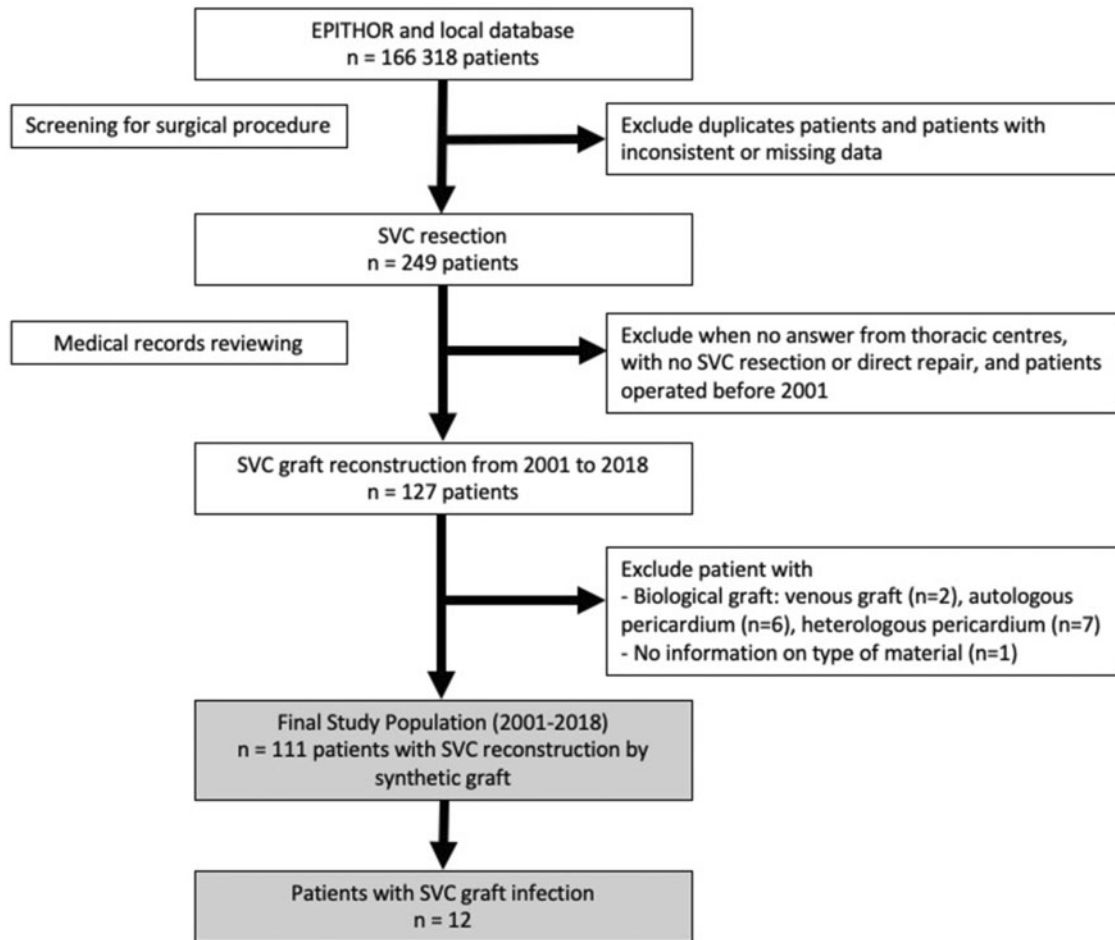
### Study population

Data entered prospectively in the French EPITHOR database and databases of participating centres between 2001 and 2018 were reviewed retrospectively. The EPITHOR process has been described previously [5]. Patients were first screened for surgical procedure. After eliminating duplicates patients, all patients with inconsistent (left side and SVC resection, right lower lobe lung resection or lower bilobectomy with SVC resection) or missing data, all participating centres were asked to review each medical record. Exclusion criteria were no response from thoracic centres, no SVC resection, patients operated before 2001 and SVC graft reconstruction with biological materials (venous or pericardial patches) (Fig. 1). Our final study population included patients with SVC synthetic graft or patch infection.

### Data collection

Baseline characteristics, comorbidities, treatment-related variables (neoadjuvant chemo- or radiotherapy, type of lung or mediastinal resection, extended resection, lymph node dissection, partial or total SVC reconstruction, SVC clamping time), disease-related variables (histological findings, stage, tumour margins) and follow-up variables (adjuvant therapy, infectious complications and their management) were collected.

Number of comorbidities was used as a categorical variable. The comorbidities described previously were recorded [5]. SVCGI diagnosis was made according to the MAGIC classification [6]. SVC synthetic grafts in an empyema or with mediastinitis were considered as a graft infection. SVCGI was classified as early-onset when occurring within 4 months post-surgery and



**Figure 1:** Flow chart of the study population. SVC: superior vena cava.

as late-onset when occurring >4 months post-surgery [7]. All patients received perioperative antibio-prophylaxis according to the guidelines of the French Society of Anaesthesia and Intensive Care [8].

## Outcome measures

Primary outcome was the management of SVCGI. Secondary outcomes were microbiological findings, 5-year survival, operative mortality and risk factors for graft infection.

## Statistical analysis

Statistical analysis was performed with R software (R-Project, version 3.6.1, GNU GPL). Results were presented with effect sizes (Cohen's *d*, odds ratio) with 95% confidence interval (CI). A competing risk analysis with mortality was performed to determine the incidence of SVCGI and the risk factors for SVCGI by including only pre- and intraoperative variables. As secondary analyses, the survival analysis was estimated by Kaplan-Meier method, the median follow-up was estimated by the reverse Kaplan-Meier method and the log-rank test was performed to compare survival between patients with or without SVCGI.

## RESULTS

Figure 1 shows the flow chart of this multicentre longitudinal retrospective study. Of 111 eligible patients, 98 patients underwent surgery for malignant thoracic disease (NSCLC, MT, neuroendocrine carcinoma, mesothelioma, metastasis of breast or rectal cancer, thyroid cancer) and 13 for benign SVC obstruction (secondary to indwelling catheters, fibrosis mediastinitis, SVC haemangioendothelioma).

## Study population

The baseline characteristics of the 12 patients compared to the uninfected patients are shown in Table 1. SVC reconstruction was performed using a PTFE patch in 1 patient and a graft in 11 patients. Reconstruction was truncal in 4 patients and single left or single right brachiocephalic vein in 7 patients.

## Primary outcome

Twelve patients were diagnosed with SVCGI. Incidence of SVCGI is around 11.9%. Early-onset and late-onset graft infection occurred in 11 (91.7%) and 1 (8.3%) patients, respectively. All SVCGIs were either due to empyema or due to mediastinitis (Table 2).

**Table 1:** Baseline characteristics of the study population

Characteristics	All patients (N = 111)	No SVCGI (N = 99)	SVCGI (N = 12)	OR/Cohen's d (95% CI)
Sex (M/F)	76/35	67/32	9/3	1.4 (0.3–8.8)
Age (years), median (min–max)	56 (15–82)	57 (15–82)	55.5 (17–73)	0.05 (–0.5–0.6)
BMI $\geq$ 30 kg/m <sup>2</sup>	11 (19.3)	10 (20.4)	1 (12.5)	0.6 (0.01–5.3)
Number of comorbidities $\geq$ 3	35 (31.5)	30 (30.3)	5 (41.7)	1.6 (0.3–6.6)
FEV <sub>1</sub> %, mean (SD)	77 (SD: 19)	79 (SD: 19)	64 (SD : 17)	0.8 (0.08–1.5)
COPD	37 (39.4)	27 (32.9)	10 (83.3)	9.9 (1.9–99)
Induction therapy	53 (47.7)	45 (45.5)	8 (66.7)	2.4 (0.5–11)
Type of resection				
Pneumonectomy	32 (28.8)	26 (26.3)	6 (50)	2.78 (0.6–11)
Lobectomy	35 (31.5)	34 (34.3)	1 (8.3)	0.18 (0–1.3)
Mediastinal tumour resection	40 (36)	36 (36.4)	4 (33.3)	0.88 (0.2–3.5)
Extend of resection				
Atypical lung resection	24 (21.6)	20 (20.2)	4 (33.3)	1.9 (0.4–8.3)
Carina	21 (18.9)	18 (18.2)	3 (25)	1.5 (0.2–6.8)
Left/right atrium	4/6 (3.6/5.4)	4/6 (4/6.1)	0/0	0 (0–13)/(0–7)
Oesophagus	1 (0.9)	0	1 (8.3)	
Chest wall	16 (14.4)	12 (12.1)	4 (33.3)	3.6 (0.7–16)
Brachio-cephalic artery	8 (7.2)	8 (8.1)	0	0 (0–5)
Manual bronchial closure	30 (28)	25(26)	5 (45.5)	2.3 (0.5–10)
Graft replacement				0 (0–45)
PTFE	109 (98.2)	97 (98)	12 (100)	
Dacron	2 (1.8)	2 (2)	0	
Flap coverage	26 (25.7)	20 (22.5)	6 (50)	3.4 (0.8–14)
Histology				
NSCLC	46 (41.4)	39 (39.4)	7 (58.3)	
MT	25 (22.5)	23 (23.2)	2 (16.7)	
NSGCT	13 (11.7)	12 (12.1)	1 (8.3)	
Others	22 (19.8)	20 (20.2)	2 (16.7)	

Values shown are n (%) unless stated otherwise.

BMI: body mass index; CI: confidence interval; COPD: chronic obstructive pulmonary disease; F: female; FEV<sub>1</sub>: force expiratory volume in 1 s; M: male; MT: mediastinal tumour; NSCLC: non-small cell lung cancer; NSGCT: non-seminomatous germinal cell tumour; OR: odds ratio; PTFE: polytetrafluorethylene; SD: standard deviation; SVCGI: superior vena cava graft infection.

Four patients (33.3%) had SVCGI secondary to empyema without bronchopleural fistula (BPF) treated by chest tube drainage or graft-sparing surgery, with a short-term success rate of 75%. However, failure occurred in 2 patients (1 with a persistent infection and 1 with a late recurrence) and 2 patients died 6 months later due to pneumonia or cancer progression. Four patients (33.3%) included the patient 4, had SVCGI secondary to empyema with BPF, all treated surgically with graft conservation [debridement, open window thoracostomy (OWT), negative pressure wound therapy (NPWT), thoracoplasty, omental flap]. Surgery failed in 75% of patients and succeeded in 1 patient after multi-step surgery included an endobronchial stent to exclude the BPF. Five patients (41.7%) had SVCGI secondary to mediastinitis following sternotomy for an MT or benign SVC obstruction. First-line treatment consisted of surgical debridement with graft conservation in all patients. Treatment was successful in 80% of patients, while 1 required graft excision.

## Secondary outcomes

The causative microorganism was identified in all patients. *Staphylococcus* species were the main causative microorganisms (58.3%), followed by *Streptococcus* species (33.3%), *Pseudomonas aeruginosa* and *Candida albicans* (16.7% each).

Operative mortality rate was 25% (n = 3) and 10.1% (n = 10) in patients with and without SVCGI, respectively. Five-year survival rate was 35.2% and 57.8% in patients with and without SVCGI,

respectively (P = 0.055). The median follow-up time was 74 months (95% CI: 62–93) (Fig. 2).

Empyema and mediastinitis were the two major risk factors for SVCGI after SVC surgery for intrathoracic tumours. In the univariable analysis, chronic obstructive pulmonary disease (COPD) (HR = 8.3, 95% CI: 1.8–37.6, P = 0.006) and FEV<sub>1</sub> (HR = 0.95, 95% CI: 0.92–0.99, P = 0.012) were found to be statistically significant risk factors for SVCGI. In the multivariable analysis, only COPD was found to be statistically significant (HR = 9.8; 95% CI: 1–90; P = 0.043).

## DISCUSSION

This study is the first to focus on SVCGI, its risk factors, microbiological aspects, outcomes and management. Our results confirm the rarity but potential life-threatening complication of SVCGI, as in other series [3, 4]. SVCGI often occurred in the early postoperative period and was caused by contiguous infection (empyema or mediastinitis), and management was challenging due to the poor general condition of the patients, difficulties of graft removal and reconstruction.

Our nation-wide study confirms the widespread use of PTFE and a rate of prosthetic SVCGI of 10.8%, similar to the 7% [9] and 10% [4] reported previously with a smaller number of patients. No case of Dacron graft infection occurred in the 2 patients of our 111 eligible patients. Some authors reported the use of

**Table 2:** Individual characteristic and outcomes for patients with superior vena cava graft infection

Case	Patient	Infection	Management of infection	Follow-up of graft infection	Graft management
1	M/58	Early empyema, no BPF <i>Streptococcus oralis</i> from pleural fluid	Chest tube drainage 4 weeks antibiotic therapy	No recurrence Died 6 months later due to pneumopathy	Conservation
2	F/55	Early empyema, no BPF <i>Streptococcus</i> , coagulase-negative <i>Staphylococcus</i> from pleural fluid and bronchial sampling	Chest tube drainage with vancomycin irrigation 6 weeks antibiotic therapy	No recurrence Died 6 months later due to cancer progression	Conservation
3	F/56	Early empyema, no BPF Coagulase-negative <i>Staphylococcus lugdunensis</i> from pleural sampling	Surgical lavage-debridement + OWT + NPWT + removal of osteosynthesis material 6 weeks antibiotic therapy Recurrence septicaemia Suppressive antibiotherapy	Persistent graft infection: suppressive antibiotherapy followed-up after 5 years Alive at 5 years	Conservation
4	M/61	Early empyema, no BPF <i>Streptococcus milleri</i> and Gram-negative <i>Bacillus</i> Late empyema with BPF (6 years later) <i>Candida albicans</i> , <i>Staphylococcus</i>	Chest tube drainage 4 weeks antibiotic therapy	Recurrence empyema with BPF <i>C. albicans</i> , <i>Staphylococcus</i> Multiple surgical step treatment: OWT + NPWT + omental flap 9 months later: recurrence <i>Prevotella melaninogenica</i> Pectoralis major flap 1 month later: Partial graft thrombosis + persistence BPF and septicaemia Thoracoplasty + body graft removal + serratus muscle flap Recurrence septicaemia involving SVC stump graft: Total excision of the graft. No revascularization No recurrence Alive 3 years after first recurrence of infection and 12 years after pneumonectomy	Removal
5	M/55	Early empyema with BPF MRSA, multiresistant <i>P. aeruginosa</i> from bronchial sampling	Surgical lavage-debridement + omental flap + thoracoplasty + OWT	Died 15 days later due to multi-organ failure	Conservation
6	M/65	Early empyema with BPF <i>C. albicans</i> from bronchial and pleural sampling	Chest tube drainage Surgical lavage-debridement + thoracoplasty + OWT + serratus anterior flap + NPWT Endobronchial stenting to exclude BPF + omental flap around the SVC graft in pleural space 6 weeks antimicrobial therapy	No recurrence 1-Year graft thrombosis Died to 3.5 years later due cancer progression	Conservation
7	M/64	Early empyema with BPF <i>Citrobacter koseri</i> and <i>Streptococcus anginosus</i> from perioperative sampling	Surgical lavage-debridement + closure of bronchial stump Recurrence infection and BPF: OWT	Died due to respiratory failure 1 month later	Conservation
8	M/20	Early mediastinitis Methicillin-resistant <i>Staphylococcus epidermidis</i> from perioperative sampling	Surgical lavage-debridement + irrigation with antiseptic solution Persistent infection with collection in contact with SVC patch Patch excision	Died 1 month later due to postoperative complications	Removal
9	F/17	Early mediastinitis MSSA from purulent discharge Perioperative sampling: negative	Surgical lavage-debridement 6 weeks antibiotic therapy	Died 24 months later due to altered general state	Conservation
10	M/49	Early mediastinitis MSSA from perioperative sampling	Surgical lavage-debridement 6 weeks antibiotic therapy	No recurrence Alive 4 years later	Conservation
11	M/73	Early mediastinitis <i>P. aeruginosa</i> from perioperative sampling	Surgical lavage-debridement, antibiotic therapy Persistence mediastinitis: Omental flap	No recurrence Alive 4 months later	Conservation
12	M/55	Early mediastinitis MSSA from blood cultures	Surgical lavage-debridement twice 8 weeks antibiotic therapy	No recurrence Died 7 years later	Conservation

BPF: bronchopleural fistula; F: female; M: male; MRSA: methicillin-resistant *Staphylococcus aureus*; MSSA: methicillin-sensitive *Staphylococcus aureus*; NPWT: negative pressure wound therapy; OWT: open window thoracostomy; SVC: superior vena cava.

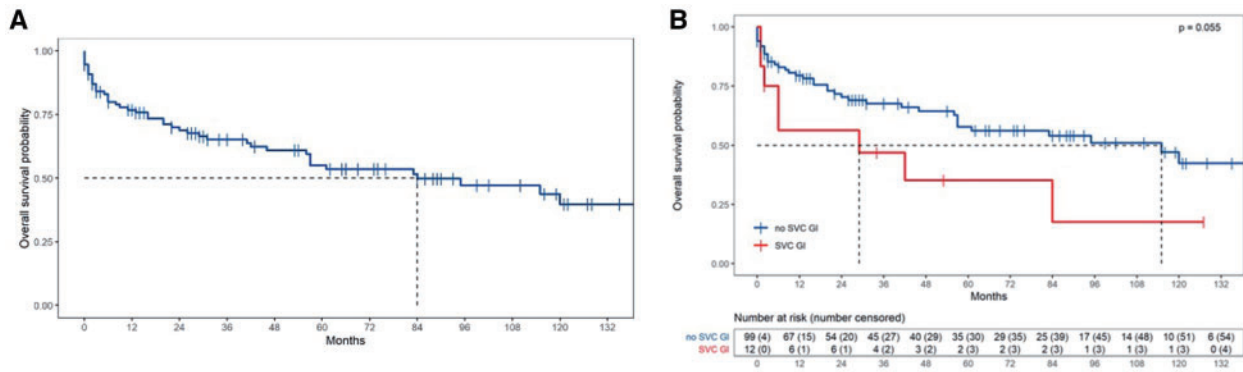


Figure 2: Kaplan-Meier curve showing overall survival rate for all patients (A) and for each group (B). Dotted line represents the median survival rate.

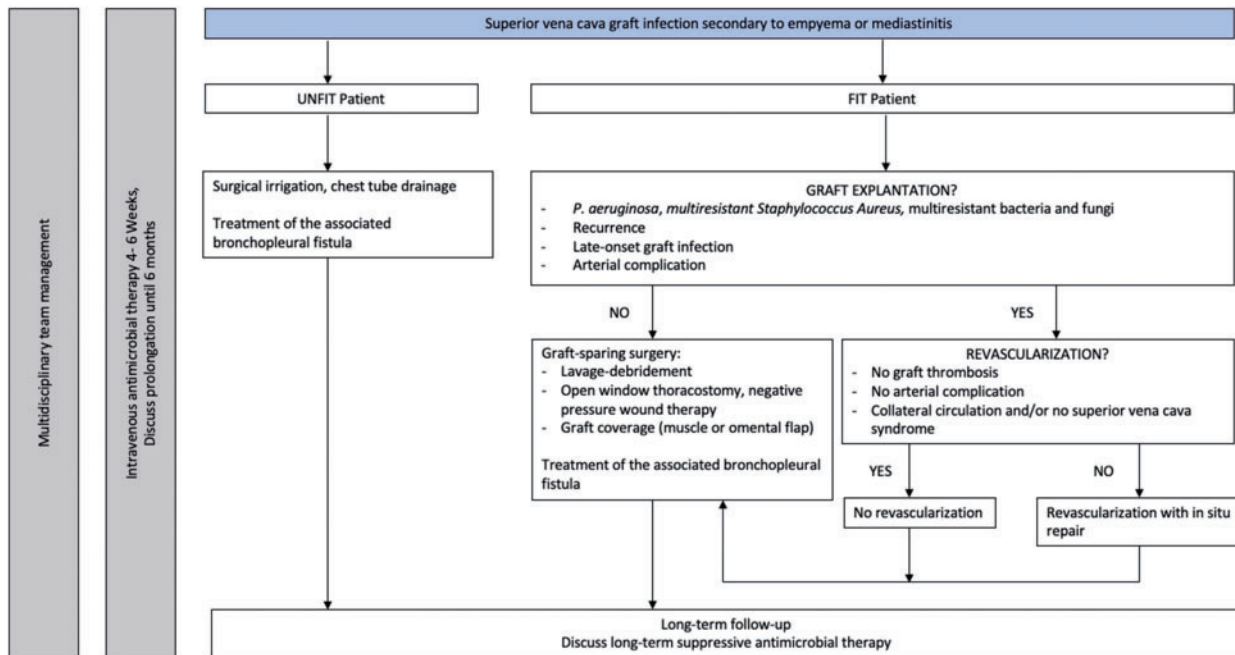


Figure 3: Proposed algorithm for the management of superior vena cava graft infection.

stapled bovine pericardial graft for SVC reconstruction after resection of lung or mediastinal malignancies with promising results. No case of infection has been reported [10–13] as for cryopreserved aortic allograft suggesting better tolerance in infected conditions [14]. These results suggest that a bovine pericardial conduit might be preferable to PTFE graft in first intent regarding to infection.

*Staphylococcus* species caused 80% of SVCGLs secondary to mediastinitis whereas the microbiological finding in SVCGL secondary to empyema was more heterogeneous. These data are consistent with the literature where *Staphylococcus* species [methicillin-sensitive *Staphylococcus aureus* (MSSA) and coagulase-negative *Staphylococcus*], methicillin-resistant *S. aureus* (MRSA), and Gram-negative bacteria (such as *P. aeruginosa*) were the main causative organisms of aortic graft infection [15, 16]. In our series, we saw no case of SVCGL secondary to haematogenous spread or pneumonia, in contrast to the findings of Spaggiari et al. [9]. All SVCGLs were secondary to 2 early postoperative complications (empyema and mediastinitis) by a

contiguous infectious process, which raises the question of surgical site infection. *Staphylococcus aureus* infection and surgical site infection are known to be decreased after prophylactic treatment of *S. aureus* in nasal carriers [17, 18] or systematic decontamination during lung surgery [19]. Unfortunately, these data were not available in our medical records.

To the best of our knowledge, only 9 papers including 11 cases of SVCGL or descending thoracic aorta graft infection after empyema or mediastinitis have been published in the literature. All except one [20] were early-onset graft infection as in our series (91.6%). Only 2 cases of SVCGL without BPF have been reported [9, 21], both treated with a surgical graft-sparing strategy without any long-term recurrence, in contrast to our patient 3 who was alive with chronic infection 5 years after OWT and NPWT. The literature on thoracoscopic debridement for post-pneumonectomy empyema reports good results [22]. Using this strategy, infection was controlled in 2 fragile patients who died 6 months later, whereas 1 patient developed recurrent empyema with BPF 6 years later leading to the challenging removal of the prosthesis.

Consequently, minimally invasive surgical debridement and long-term antimicrobial therapy might be a reasonable option in fragile patients. An open approach with large surgical lavage-debridement, muscle flap transposition and thoracoplasty should be considered for patients with a preserved general state. The addition of OWT and NPWT should be discussed in the absence of active cancer.

BPF has major consequences on the prognosis of post-pneumonectomy empyema and the presence of a SVC graft increases the difficulties in its management. In our series, 50% of patients were long-term survivors free of infection after surgical management. These patients were treated by OWT, muscle flap, omentoplasty, NPWT and endobronchial J-shape stenting in 1 and a challenging two-step graft removal in the other. Among the 2 patients who died in the early postoperative period, 1 did not have OWT as first intent and the second did not receive bronchial stenting and NPWT. Three cases are reported in the literature, all with early SVCGI and treated similarly to our patients [4, 9, 23]. Concerning descending thoracic aorta graft infection after early empyema, 3 cases have been reported. In 2, failure of endoscopic treatment led to a surgical graft-sparing strategy [24, 25] without any recurrence at close follow-up. Another patient was successfully treated after 2 surgeries with muscle-flap coverage and omentoplasty without OWT and did not develop any recurrence [26]. Recent guidelines advise multiple surgical lavage-debridement and graft excision with *in situ* repair whenever possible in infected thoracic vascular grafts concomitant with bronchial fistula closure if present [7, 27]. These results and ours suggest that SVCGI following post-pneumonectomy empyema with BPF should be treated as early as possible with at least a muscle/omental flap and OWT. BPF closure should be attempted either by re-suture in the case of early mechanical leakage or bronchial stenting in the case of ischaemic leakage. However, SVCGI secondary to empyema with BPF does not seem to increase the mortality rate compared to empyema with BPF without a vascular graft [28].

In our series, a surgical graft-sparing strategy was successful at treating 80% of SVCGI secondary to early MSSA mediastinitis. The literature is very scarce about SVCGI secondary to mediastinitis. To our knowledge, the success of surgical lavage-debridement has not been reported. Two case reports mentioned the success of omentoplasty with graft conservation [4] or graft removal [29] due to *P. aeruginosa* and MRSA graft infection complicated by a pseudoaneurysm of the ascending aorta. Oda *et al.* found decreased 1-year survival in MRSA thoracic aorta graft infection and an omental flap was found to be predictive of hospital mortality [16]. The guidelines on extracavitary vascular graft infection (e.g. in the mediastinum) recommend graft removal as the best option for major graft infection, especially due to MRSA, *P. aeruginosa* or multiple drug-resistant microorganisms [27]. This highlights the fact that treatment could be different depending on the microorganism, the time of onset of infection and possible associated arterial complications. Conservative surgical treatment with lavage-debridement may be attempted in early-onset MSSA SVCGI. In other cases of early-onset SVCGI, the addition of omentoplasty is probably the best option.

Graft removal is a major question after SVCGI and should be discussed for all patients. It is probably the best option if the SVC is obstructed with well-tolerated SVC syndrome. Moreover, removal will be easier in the early postoperative period but this situation is probably very rare [4]. In reality, the majority of patients

have a functional SVC and removal cannot be performed easily. In our series and in the literature, 63% of patients with early SVCGI [21, 23–26] had no recurrence of infection after omentoplasty and/or muscle flap and graft preservation, including 2 patients infected with aggressive microorganisms (*C. albicans* and *P. aeruginosa*). These results argue in favour of preservation of the SVC graft with omentoplasty in patients with early SVCGI as first-line treatment if graft removal cannot be performed. To our knowledge, no patients have been reported with late-onset SVCGI who recovered after preservation of the PTFE graft. Thus, graft removal should be reserved for late-onset SVCGI, SVCGI caused by aggressive microorganisms (MRSA, *P. aeruginosa* or fungi) and recurrence after a surgical graft-sparing strategy in a fit patient or in the presence of associated arterial complications [29]. If the patient is deemed inoperable, long-term suppressive antibiotherapy could control the infection. As a result of our findings, we propose an algorithm for the management of SVCGI in empyema or mediastinitis (Fig. 3).

Mediastinitis and empyema were the two major local risk factors for SVCGI confirming the results of a previous study [4]. Early diagnosis and prompt treatment of these complications may help to control the infection and improve the prognosis. The use of muscle flap coverage was not predictive, but our series probably had an insufficient number of patients to appreciate this criterion. Interestingly, we found that patients with SVCGI had more severe COPD status. Consequently, preoperative rehabilitation could improve the postoperative outcome of these patients.

## Limitations

Our study has several limitations. First, it was retrospective in nature, with a low number of patients. Second, data concerning adjuvant therapy were not always available in the medical records. Consequently, the impact of graft infection on adjuvant treatment was not evaluable. Third, accurate evaluation of known contributing factors (transfusion, duration of surgery, *S. aureus* carriers) on infectious complications, especially surgical site infection, was not possible. Fourth, no correction for possible confounders was carried out in the survival and long-term mortality analysis where SVCGI may act as an intermediate variable.

## CONCLUSION

In conclusion, SVCGI is a surgical site infection secondary to empyema or mediastinitis. Management is influenced by several factors [general state of the patient, microbiological findings, the presence of BPF or arterial complications, and the time of occurrence (early or late)]. Graft removal is not always mandatory but should be considered in late or recurrent graft infection or in infections caused by aggressive microorganisms (virulent or multidrug resistant bacteria or fungi).

## ACKNOWLEDGEMENTS

Xavier-Benoit D'Journo is acknowledged for critical revision of the manuscript. The authors thank all participants in each centre who replied and collected data.



**Conflict of interest:** Dr. Agathe Seguin-Givelet is a speaker for Medtronic and AstraZeneca. Dr. Olaf Mercier is a scientific board member for AstraZeneca. The other authors report no conflict of interest.

## Data Availability Statement

The data underlying this article will be shared on reasonable request to the corresponding author.

## Author contributions

**Laura Filaire:** Conceptualization; Data curation; Methodology; Validation; Writing—original draft; Writing—review & editing. **Olaf Mercier:** Data curation; Validation. **Agathe Seguin-Givelet:** Data curation; Validation. **Olivier Tiffet:** Data curation; Validation. **Pierre Emmanuel Falcoz:** Data curation; Validation. **Pierre Mordant:** Data curation; Validation. **Pierre-Yves Brichon:** Data curation; Validation. **Philippe Lacoste:** Data curation; Validation. **Axel Aubert:** Data curation; Validation. **Pascal Thomas:** Data curation; Validation. **Françoise Le Pimpec-Barthes:** Data curation; Validation. **Ioana Molnar:** Methodology; Validation; Statistics. **Magali Vidal:** Methodology; Validation. **Marc Filaire:** Conceptualization; Data curation; Supervision; Validation. **Géraud Galvaing:** Supervision; Validation.

## Reviewer information

Interactive CardioVascular and Thoracic Surgery thanks Tim Berger and the other, anonymous reviewer(s) for their contribution to the peer review process of this article.

## REFERENCES

- Dartevelle PG, Mitilian D, Fadel E. Extended surgery for T4 lung cancer: a 30 years' experience. *Gen Thorac Cardiovasc Surg* 2017;65:321–8.
- Sekine Y, Suzuki H, Saitoh Y, Wada H, Yoshida S. Prosthetic reconstruction of the superior vena cava for malignant disease: surgical techniques and outcomes. *Ann Thorac Surg* 2010;90:223–8.
- Spaggiari L, Magdeleinat P, Kondo H, Thomas P, Leon ME, Rollet G *et al.* Results of superior vena cava resection for lung cancer. Analysis of prognostic factors. *Lung Cancer* 2004;44:339–46.
- Dartevelle PG, Chapelier AR, Pastorino U, Corbi P, Lenot B, Cerrina J *et al.* Long-term follow-up after prosthetic replacement of the superior vena cava combined with resection of mediastinal-pulmonary malignant tumors. *J Thorac Cardiovasc Surg* 1991;102:259–65.
- Bernard A, Rivera C, Pages PB, Falcoz PE, Vicaut E, Dahan M. Risk model of in-hospital mortality after pulmonary resection for cancer: a national database of the French Society of Thoracic and Cardiovascular Surgery (Epithor). *J Thorac Cardiovasc Surg* 2011;141:449–58.
- Lyons OTA, Baguneid M, Barwick TD, Bell RE, Foster N, Homer-Vanniasinkam S *et al.* Diagnosis of aortic graft infection: a case definition by the Management of Aortic Graft Infection Collaboration (MAGIC). *Eur J Vasc Endovasc Surg* 2016;52:758–63.
- Chakfé N, Diener H, Lejay A, Assadian O, Berard X, Caillon J *et al.* Editor's Choice—European Society for Vascular Surgery (ESVS) 2020 clinical practice guidelines on the management of vascular graft and endograft infections. *Eur J Vasc Endovasc Surg* 2020;59:339–84.
- Martin C, Boisson M, Dupont H, Fletcher D, Gauzit R, Kitzis M *et al.* Antibioprophylaxie en chirurgie et médecine interventionnelle (patients adultes) 2018.
- Spaggiari L, Thomas P, Magdeleinat P, Kondo H, Rollet G, Regnard JF *et al.* Superior vena cava resection with prosthetic replacement for non-small cell lung cancer: long-term results of a multicentric study. *Eur J Cardiothorac Surg* 2002;21:1080–6.
- Maurizi G, Poggi C, D'Andrilli A, Vanni C, Ciccone AM, Ibrahim M *et al.* Superior vena cava replacement for thymic malignancies. *Ann Thorac Surg* 2019;107:386–92.
- Ciccone AM, Venuta F, D'Andrilli A, Andreotti C, Ibrahim M, De Giacomo T *et al.* Long-term patency of the stapled bovine pericardial conduit for replacement of the superior vena cava. *Eur J Cardiothorac Surg* 2011;40:1487–91.
- Spaggiari L, Leo F, Veronesi G, Solli P, Galetta D, Tatani B *et al.* Superior vena cava resection for lung and mediastinal malignancies: a single-center experience with 70 cases. *Ann Thorac Surg* 2007;83:223–9.
- D'Andrilli A, De Cecco CN, Maurizi G, Muscogiuri G, Baldini R, David V *et al.* Reconstruction of the superior vena cava by biologic conduit: assessment of long-term patency by magnetic resonance imaging. *Ann Thorac Surg* 2013;96:1039–45.
- Gómez-Caro A, Martínez E, Rodríguez A, Sanchez D, Martorell J, Gimferrer JM *et al.* Cryopreserved arterial allograft reconstruction after excision of thoracic malignancies. *Ann Thorac Surg* 2008;86:1753–61.
- Bianco V, Kilic A, Gleason TG, Arnaoutakis GJ, Sultan I. Management of thoracic aortic graft infections. *J Card Surg* 2018;33:658–65.
- Oda T, Minatoya K, Kobayashi J, Okita Y, Akashi H, Tanaka H *et al.* Prosthetic vascular graft infection through a median sternotomy: a multicentre review †. *Interact CardioVasc Thorac Surg* 2015;20:701–6.
- Bode LGM, Kluytmans JAJW, Wertheim HFL, Bogaers D, Vandembroucke-Grauls CMJE, Roosendaal R *et al.* Preventing surgical-site infections in nasal carriers of *Staphylococcus aureus*. *N Engl J Med* 2010;362:9–17.
- van Rijen M, Bonten M, Wenzel R, Kluytmans J. Mupirocin ointment for preventing *Staphylococcus aureus* infections in nasal carriers. *Cochrane Database Syst Rev* 2008;4:CD006216.
- D'Journo XB, Falcoz P-E, Alifano M, Le Rochais J-P, D'Annville T, Massard G *et al.* Oropharyngeal and nasopharyngeal decontamination with chlorhexidine gluconate in lung cancer surgery: a randomized clinical trial. *Intensive Care Med* 2018;44:578–87.
- Okubo K, Isobe J, Kitamura J, Ueno Y. Mediastinitis and pseudoaneurysm of brachiocephalic artery long after the resection of invasive thymoma and postoperative irradiation. *J Thorac Cardiovasc Surg* 2005;130:918–9.
- Alifano M, Puyo P, Magdeleinat P, Levasseur P, Regnard JF. Management of empyema complicating lobectomy with superior vena cava replacement. *Ann Thorac Surg* 2000;70:1720–1.
- Galetta D, Spaggiari L. Video-thoroscopic management of postpneumonectomy empyema. *Thorac Cardiovasc Surg* 2018;66:701–6.
- Spaggiari L, Solli P, Veronesi G, Pastorino U. Intrathoracic myoplasty for prosthesis infection after superior vena cava replacement for lung cancer. *Ann Thorac Surg* 2002;74:1231–3.
- Yuasa H, Onizuka M, Ijima H, Akaogi E, Mitsui K, Hori M. MRSA pyothorax due to bronchopleural fistula after grafting and pneumonectomy for traumatic aneurysm of the thoracic aorta—a successful treatment by open drainage and omentopexy. *Nihon Kyobu Geka Gakkai Zasshi* 1992;40:290–3.
- Nosotti M, Cioffi U, De Simone M, Mendogni P, Palleschi A, Rosso L *et al.* Omentoplasty and thoracoplasty for treating postpneumonectomy bronchopleural fistula in a patient previously submitted to aortic prosthesis implantation. *J Cardiothorac Surg* 2009;4:38.
- Uchibori A, Okada S, Takeda-Miyata N, Tsunozuka H, Kato D, Inoue M. Omental flap for bronchopleural fistula after pneumonectomy and aorta replacement. *Ann Thorac Surg* 2020;109:e349–51.
- Wilson WR, Bower TC, Creager MA, Amin-Hanjani S, O'Gara PT, Lockhart PB *et al.*; American Heart Association Committee on Rheumatic Fever, Endocarditis, and Kawasaki Disease of the Council on Cardiovascular Disease in the Young; Council on Cardiovascular and Stroke Nursing; Council on Cardiovascular Radiology and Intervention; Council on Cardiovascular Surgery and Anesthesia; Council on Peripheral Vascular Disease; and Stroke Council. Vascular graft infections, mycotic aneurysms, and endovascular infections: a scientific statement from the American Heart Association. *Circulation* 2016;134:e412–60.
- Hicham H, Ibrahim I, Rabiou S, Marouane L, Yassine O, Mohamed S. Postpneumonectomy empyema: risk factors, prevention, diagnosis, and management. *Asian Cardiovasc Thorac Ann* 2020;28:89–96.
- Itoda Y, Komae H, Yamamoto T, Takeda M. Aortic pseudoaneurysm due to graft infection after invasive thymoma resection. *Asian Cardiovasc Thorac Ann* 2012;20:584–6.