



HAL
open science

Pediatric methylation class HGNET-MN1: unresolved issues with terminology and grading

Arnault Tauziède-Espariat, Mélanie Pagès, Alexandre Roux, Aurore Siegfried, Emmanuelle Uro-Coste, Yvan Nicaise, Annick Sevely, Marion Gambart, Sergio Boetto, Martin Dupuy, et al.

► To cite this version:

Arnault Tauziède-Espariat, Mélanie Pagès, Alexandre Roux, Aurore Siegfried, Emmanuelle Uro-Coste, et al.. Pediatric methylation class HGNET-MN1: unresolved issues with terminology and grading. *Acta Neuropathologica Communications*, 2019, 7 (1), pp.176. 10.1186/s40478-019-0834-z . hal-04515758

HAL Id: hal-04515758

<https://hal.science/hal-04515758>

Submitted on 23 May 2024

HAL is a multi-disciplinary open access archive for the deposit and dissemination of scientific research documents, whether they are published or not. The documents may come from teaching and research institutions in France or abroad, or from public or private research centers.

L'archive ouverte pluridisciplinaire **HAL**, est destinée au dépôt et à la diffusion de documents scientifiques de niveau recherche, publiés ou non, émanant des établissements d'enseignement et de recherche français ou étrangers, des laboratoires publics ou privés.



Distributed under a Creative Commons Attribution 4.0 International License

LETTER TO THE EDITOR

Open Access



Pediatric methylation class HGNET-MN1: unresolved issues with terminology and grading

Arnault Tauziède-Espariat^{1,2*}, Mélanie Pagès^{1,2}, Alexandre Roux^{2,3}, Aurore Siegfried⁴, Emmanuelle Uro-Coste⁴, Yvan Nicaise⁴, Annick Sevely⁵, Marion Gambart⁶, Sergio Boetto⁷, Martin Dupuy⁸, Pomone Richard⁹, Romain Perbet¹⁰, Matthieu Vinchon¹¹, Sabine Caron¹², Felipe Andreiuolo^{1,2}, Albane Gareton^{1,2}, Emmanuèle Lechapt^{1,2}, Fabrice Chrétien^{1,2}, Stéphanie Puget^{2,13}, Jacques Grill^{2,14,15}, Nathalie Boddart^{2,16}, Pascale Varlet^{1,2} and on behalf of the RENOCLIP-LOC

Keywords: MN1, HGNET, Astroblastoma, Meta-analysis

High-grade neuroepithelial tumor with *MN1* alteration (HGNET-*MN1*) is a rare, recently described central nervous system (CNS) entity with a distinct methylation profile, which was formerly part of CNS-primary neuroepithelial tumors (PNET). HGNET-*MN1* affects children (77% of reported cases [1–5]) and are characterized by a recurrent fusion implicating the *MN1* (meningioma 1) gene [1]. Limited histopathological and clinical data are available on HGNET-*MN1* (44 cases proven by DNA methylation analysis) and a number of outstanding issues still exist [1–5].

Firstly, the histopathological diagnostic criteria are not well established. In Sturm's study, they were initially classified as astroblastomas (16/41, as 4 of our cases) but also as PNETs (12/41), ependymomas (9/41, as 6 of our cases), meningioma (1/41), glioblastoma (1/41), embryonal tumor with multilayered rosettes (1/41), and unclassified tumor (1/41) [1]. These data raise the question of an overlap between a histopathological entity (astroblastoma, considered as a glioma in the current World Health Organization –WHO– classification) and a molecular entity (HGNET-*MN1*). Secondly, the prognosis of HGNET-*MN1* remains unclear. The term “HG” was employed because they were initially described within a cohort of malignant tumors [1]. To explore these issues, we screened our local and the French

neuropathological network database ($n = 10$, five of them were briefly mentioned in [6]) and the literature ($n = 34$), for pediatric DNA-methylation proven HGNET-*MN1* [1–5]. Here, we describe the molecular, histopathological, clinical and imaging characteristics of pediatric HGNET-*MN1*.

Including our cases, HGNET-*MN1* predominantly concern girls (90.9%, 40/44 cases) and are mainly supratentorial (95.3%, 41/43 cases) [1, 3–5]. Radiologically, all our tumors were well-demarcated from adjacent parenchyma with a multi-nodular aspect. Perilesional edema was not constantly observed. None was calcified and one case was hemorrhagic. They consisted of very large lesions (size ranging from 4.5 to 11.0 cm, mean 7.1 cm) with prominent solid portions and multiple necrotic areas but a unique cystic component was not the main tumor feature (Additional file 1: Figure S1 A-D). Thus, the radiological analysis showed that HGNET-*MN1* differed from ependymoma, with *RELA*-fusion, the main pediatric differential diagnosis [6].

In the literature, HGNET-*MN1* has been identified in a portion of astroblastomas (39% in adults compared to 78% in children) and did not constantly harbour astroblastic features (one case of our series and 8.5% of reported pediatric cases) [1–5]. In our series, the only constant feature was tumoral fibrous or sclerous stroma (Additional file 1 Figure S1 E-F). They were often macro- and microcystic ($n = 7$) (Additional file 1 Figure S1 G-H). They showed a large variety of architectural patterns (Additional file 2 Figure S2 A-E). Cellular atypia was mild

* Correspondence: a.tauziede-espariat@ghu-paris.fr

¹Department of Neuropathology, GHU Paris Psychiatrie Neurosciences, Sainte-Anne Hospital, 1, rue Cabanis, 75014 Paris, France

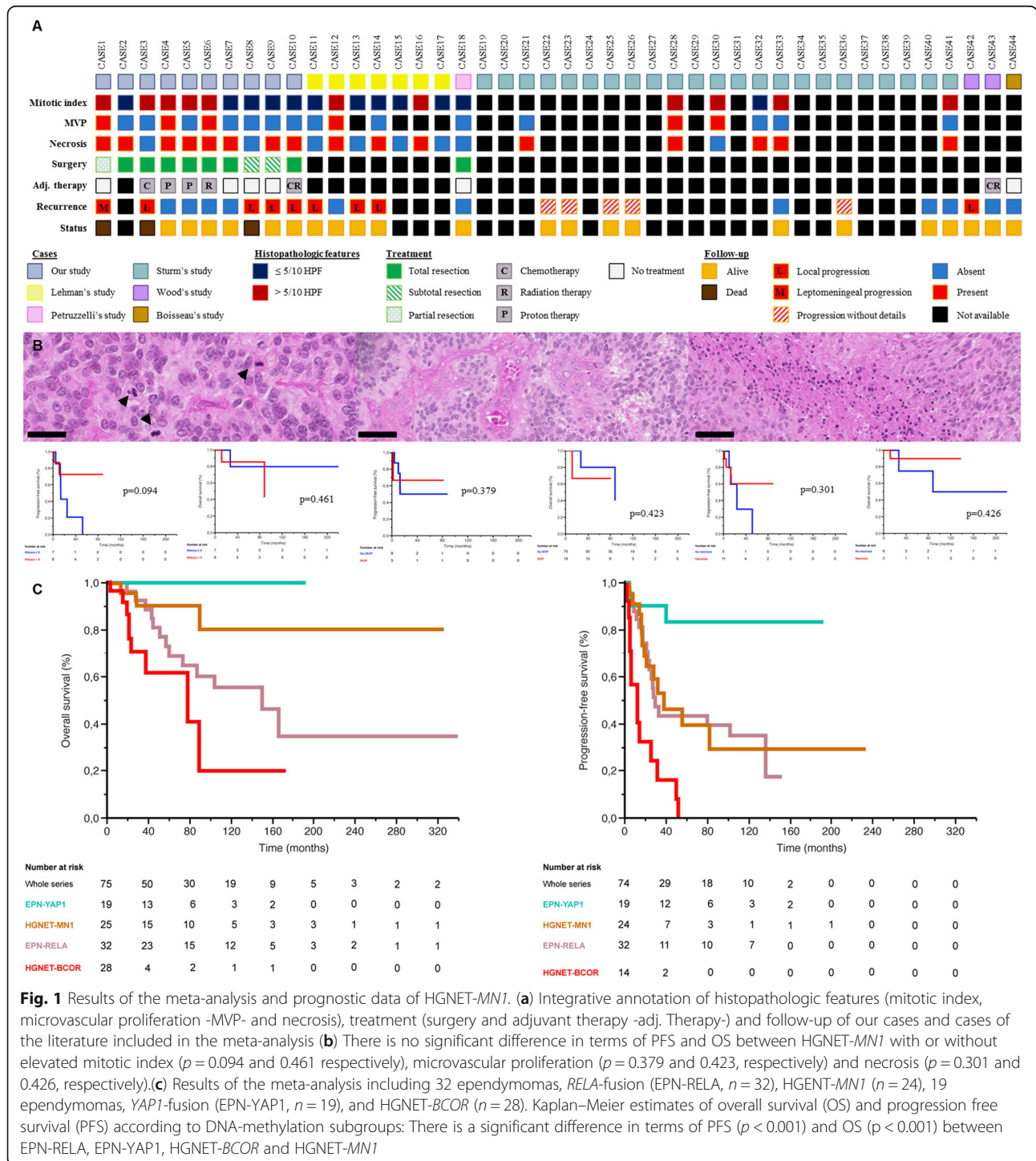
²Paris University France, 75006 Paris, France

Full list of author information is available at the end of the article



except in two cases (Additional file 2: Figure S2 F). True ependymal rosettes, lymphocytic infiltrates, eosinophilic granular bodies, and Rosenthal fibers were absent. Mitotic count ranged from 1 to 48 for 10 high-power fields (HPF) and the MIB1 ranged from 2 to 40% (Fig. 1). Microvascular proliferation and necrosis were observed in 3 and 8 cases, respectively (Fig. 1). The immunohistochemical

profile (summarized in Additional file 5 Table S1 and Additional file 3: Figure S3) is also heterogeneous. The literature review and our cases show that 72% of tumors express glial markers [1–5] and 58% express neuronal markers [1, 5]. Our analysis revealed that 50% of cases express CK18, and, surprisingly for a primary brain tumor, CD56 was focally or not expressed in 5/10 tumors.



Further fundamental studies and ultrastructural analyses are required to elucidate the cell of origin of HGNET-*MNI*. Thus, HGNET-*MNI* present variable morphological and immunophenotypical features.

Our meta-analysis (summarized in Fig. 1, with statistical methodology detailed in **Supplementary Data**), revealed that during follow-up (mean 81.4 months, range 2.6–324.0), 14/25 patients (56.0%) experienced tumor progression (8 local, 1 leptomeningeal, and 5 without details) and 3 patients (12.0%) died (Fig. 1). The mean/median progression-free survival (PFS) were 43.9/34 months. The mean overall survival (OS) was 81.6 months and the median OS was not reached. Children with HGNET-*MNI* present a favourable outcome with 88.0% survival (median follow-up of 65.5 months), although 48.0% presented with tumor progression. Three patients (cases 7, 18 and 44) treated only by surgery were alive without tumor progression: one with a long follow-up (229 months) and two with only a short follow-up period (20 and 21 months). Total resection was significantly associated with better OS ($p = 0.032$) and PFS ($p = 0.029$). In univariate analysis, we found significant differences in terms of OS ($p < 0.001$) and PFS ($p < 0.001$) between HGNET-*MNI* and ependymomas with *RELA*-fusion, ependymomas with *YAPI*-fusion and HGNET-*BCOR* from previous studies [1, 6–9]. Our study has several limitations inherent to its retrospective observational design, but the prognosis does not seem to be as dismal as the term “high-grade” could suggest. No grading criteria have been established for HGNET-*MNI*. However, the WHO classification mentions histopathologic criteria for malignant astroblastoma [10]: mitotic index $> 5/10$ HPF, microvascular proliferation and palisading necrosis. In univariate analysis, these criteria were not significantly, independently or in combination, associated with worse OS ($p = 0.461, 0.423, 0.426$ respectively and in combination $p = 0.461$) and PFS ($p = 0.094, 0.379, 0.301$ respectively and in combination $p = 0.426$) (Fig. 1, Additional file 4: Figure S4). Moreover, three patients (cases 4, 6 and 12) presenting tumors with these three criteria did not develop progression and are alive (median follow-up of 68.0 months) [5].

In summary, this is the largest series of pediatric HGNET-*MNI* with clinical, radiological and histopathological characterization. They present a homogeneous MRI aspect, but a heterogeneous morphology, with inconstant astroblastic pseudorosettes. *MNI* fusion must be confirmed to rule out the major differential diagnoses (pleiomorphic xanthoastrocytomas [2–4] and ependymomas [3]). Nevertheless when confronted to our metaanalysis results, naming these tumors has proven difficult. Indeed, both “HGNET” and “astroblastoma” do not completely correlate with grading and morphology. “HGNET” is not a proper designation because the

prognosis seems favourable in a subset of cases and further studies are needed to comfort this tendency. “Astroblastoma” is also not quite appropriate since astroblastic pseudorosettes are inconstant and not specific, and a frequent glioneuronal immunophenotype is observed. Our study showed that the two constant histopathological and molecular features of these tumors are the fibrous stroma and the *MNI* fusion. Consequently, we would like to suggest the terms “NET, *MNI* fusion-positive” or “Fibrous neuroepithelial tumors (FNET), *MNI* fusion-positive”.

Supplementary information

Supplementary information accompanies this paper at <https://doi.org/10.1186/s40478-019-0834-z>.

Additional file 1: Figure S1. Correlation of radiological and morphological features in HGNET-*MNI*. (A) Axial T1 weighted image; (B) Axial T1 post contrast weighted image; (C) Axial T2 weighted image; (D) Coronal T1 post contrast weighted image: they showed a large lesion with multinodular appearance and very important edema. It is a well-demarcated non-intraventricular multinodular tumor with a central solid portion (yellow star) surrounded by multiple cystic components (red asterisks). (E) Multilobular tumor with fibrous central scar delimiting tumor nodules (HPS, 60x). (F) Fibrous scar (yellow star) (HPS, 130x). (G) Macro- and microcystic components (red asterisks) (HPS, 100x). (H) Well-delimitation of the tumor from the brain parenchyma (arrows) (HPS, 200x).

Additional file 2: Figure S2. Variable histopathological patterns of HGNET-*MNI*. (A) Astroblastic pseudorosettes with variable hyalinization of vessels (HPS, 300x). (B) Ependymoma-like pattern with pseudorosettes (HPS, 400x). (C) Trabecular pattern of the tumor outside of the pseudorosettes (HPS, 400x). (D) Fibrous sclerosis with cordonal structures (HPS, 400x). (E) Myxoid changes with chordoid appearance (HPS, 400x). (F) Tumor cells with nuclear inclusions, atypias and giant cells (HPS, 400x).

Additional file 3: Figure S3. Variable immunohistochemical findings of HGNET-*MNI*. (A) Diffuse expression of GFAP by glial cells of the pseudorosettes (400x, and insert 400x). (B) Focal expression of GFAP (400x). (C) Diffuse expression of Olig2 in a part of the tumor (400x). (D) Very focal immunoreactivity for Olig2 (400x). (E) Expression of CD56 (400x). (F) Expression of synaptophysin in a part of tumor cells (400x). (G) NeuN immunopositivity (400x). (H) Extra-vascular cellular staining with CD34 in one case (400x). (I) Diffuse expression of cytokeratin 18 (400x).

Additional file 4: Figure S4. Analysis of correlation between malignant criteria defined in astroblastoma applied to HGNET-*MNI* with overall survival and progression-free survival. (A) There is no significant difference in terms of PFS between HGNET-*MNI* with or without the combination of the three features of anaplasia ($p = 0.426$). (B) There is no significant difference in terms of OS between HGNET-*MNI* with or without the combination of the three features of anaplasia ($p = 0.461$).

Additional file 5: Table S1. Immunoprofile of HGNET-*MNI* of our series

Acknowledgements

We would like to thank the laboratory technicians at the GHU Paris Neuro Sainte-Anne for their assistance, as well as the Integragen platform for their help with DNA-methylation analyses and the RENOCLIP. The RENOCLIP is the clinico-pathologic network that is instrumental for the central histopathologic review supported by Institut National du Cancer (INCa).

Authors' contributions

ATE, AR, ASe, MG, SB, MD, MV, SC, SP, JG and NB compiled the MRI and clinical records; ATE, MP, ASi, EUC, YN, PR, RP, FA, AG, EL, FC and PV conducted the neuropathological examinations; ATE, MP, EUC, YN and PV conducted the molecular studies; ATE, MP and PV drafted the manuscript; all authors reviewed the manuscript.

Funding

The authors declare that they have not received any funding.

Ethics approval and consent to participate

This study was approved by the GHU Paris Psychiatrie Neurosciences, Sainte-Anne Hospital's local ethic committee.

Competing interests

The authors declare that they have no conflicts of interest directly related to the topic of this article.

Author details

¹Department of Neuropathology, GHU Paris Psychiatrie Neurosciences, Sainte-Anne Hospital, 1, rue Cabanis, 75014 Paris, France. ²Paris University France, 75006 Paris, France. ³Department of Neurosurgery, GHU Paris Psychiatrie Neurosciences, Sainte-Anne Hospital, 75014 Paris, France. ⁴Department of Pathology, Toulouse University Hospital, 31300 Toulouse, France. ⁵Department of Radiology, Purpan University Hospital, 31300 Toulouse, France. ⁶Department of Pediatric Oncology, Toulouse University Hospital, 31300 Toulouse, France. ⁷Department of Neurosurgery, Toulouse University Hospital, 31300 Toulouse, France. ⁸Department of Neurosurgery, Clinique de l'Union, 31240 Saint-Jean, France. ⁹Laboratory of Pathology, Les Feuillants, 31023 Toulouse, France. ¹⁰Institute of Pathology, Centre de Biologie Pathologie, Lille University Hospital, 59000 Lille, France. ¹¹Neurology, Breast Cancer Department, Oscar Lambret Center, 59000 Lille, France. ¹²Department of Radiology, Centre de Biologie Pathologie, Lille University Hospital, 59000 Lille, France. ¹³Department of Pediatric Neurosurgery, Necker University Hospital, 75015 Paris, France. ¹⁴CNRS, Gustave Roussy, University Paris-Sud, Université Paris-Saclay, UMR8203 "Vectorologie et Thérapeutiques Anticancéreuses", 94805 Villejuif, France. ¹⁵Department of Pediatric Oncology, Gustave Roussy, University Paris-Sud, Université Paris-Saclay, 94805 Villejuif, France. ¹⁶Department of Radiology, Necker University Hospital, 75015 Paris, France.

Received: 7 October 2019 Accepted: 25 October 2019

Published online: 10 November 2019

References

1. Sturm D, Orr BA, Toprak UH, Hovestadt V, Jones DTW, Capper D et al (2016) New brain tumor entities emerge from molecular classification of CNS-PNETs. *Cell*. 164:1060–1072
2. Boisseau W, Euskirchen P, Mokhtari K, Dehais C, Touat M, Hoang-Xuan K et al (2019) Molecular Profiling Reclassifies Adult Astroblastoma into Known and Clinically Distinct Tumor Entities with Frequent Mitogen-Activated Protein Kinase Pathway Alterations. *The Oncologist*
3. Lehman NL, Usualieva A, Lin T, Allen SJ, Tran QT, Mobley BC et al (2019) Genomic analysis demonstrates that histologically-defined astroblastomas are molecularly heterogeneous and that tumors with MN1 rearrangement exhibit the most favorable prognosis. *Acta Neuropathol Commun* 7:42
4. Wood MD, Tihan T, Perry A, Chacko G, Turner C, Pu C et al (2018) Multimodal molecular analysis of astroblastoma enables reclassification of most cases into more specific molecular entities. *Brain Pathol Zurich Switz*. 28:192–202
5. Petruzzellis G, Alessi I, Colafati GS, Diomedei-Camassei F, Ciolfi A, Pedace L, et al. Role of DNA Methylation Profile in Diagnosing Astroblastoma: A Case Report and Literature Review. *Front Genet* [Internet]. 2019 [cited 2019 May 24];10. Available from: <https://www.ncbi.nlm.nih.gov/pmc/articles/PMC6502896/>
6. Pagès M, Pajtlér KW, Puget S, Castel D, Boddaert N, Tauziède-Espariat A et al (2019) Diagnostics of pediatric supratentorial RELA ependymomas: integration of information from histopathology, genetics, DNA methylation and imaging. *Brain Pathol Zurich Switz*. 29:325–335
7. Andreiuolo F, Varlet P, Tauziède-Espariat A, Jünger ST, Dörner E, Dreschmann V et al (2019) Childhood supratentorial ependymomas with YAP1-MAML1 fusion: an entity with characteristic clinical, radiological, cytogenetic and histopathological features. *Brain Pathol Zurich Switz*. 29: 205–216
8. Ferris SP, Velazquez Vega J, Aboian M, Lee JC, Van Ziffle J, Onodera C et al (2019) High-grade neuroepithelial tumor with BCOR exon 15 internal tandem duplication—a comprehensive clinical, radiographic, pathologic, and genomic analysis. *Brain Pathol Zurich Switz*
9. Al-Battashi A, Al Hajri Z, Perry A, Al-Kindi H, Al-Ghaithi I (2019) A cerebellar high-grade Neuroepithelial tumor with BCOR alteration in a five-year-old child: a case report. *Sultan Qaboos Univ Med J* 19:e153–e156
10. Louis DN, Perry A, Reifenberger G, von Deimling A, Figarella-Branger D, Cavenee WK, et al. The 2016 World Health Organization classification of tumors of the central nervous system: a summary. *Acta Neuropathol (Berl)*. 2016;131:803–20. <https://doi.org/10.1007/s00401-016-1545-1>

Publisher's Note

Springer Nature remains neutral with regard to jurisdictional claims in published maps and institutional affiliations.

Ready to submit your research? Choose BMC and benefit from:

- fast, convenient online submission
- thorough peer review by experienced researchers in your field
- rapid publication on acceptance
- support for research data, including large and complex data types
- gold Open Access which fosters wider collaboration and increased citations
- maximum visibility for your research: over 100M website views per year

At BMC, research is always in progress.

Learn more biomedcentral.com/submissions

