



HAL
open science

An unusual diagnosis of alpha-mannosidosis with ocular anomalies: Behind the scenes of a hidden copy number variation

Kevin Uguen, Sylvia Redon, Karen Rouault, Marine Pensec, Caroline Benech, Sacha Schutz, Xavier Zanlonghi, Yann Nadjjar, Cédric Le Maréchal, Claude Férec, et al.

► To cite this version:

Kevin Uguen, Sylvia Redon, Karen Rouault, Marine Pensec, Caroline Benech, et al.. An unusual diagnosis of alpha-mannosidosis with ocular anomalies: Behind the scenes of a hidden copy number variation. *American Journal of Medical Genetics Part A*, 2024, 10.1002/ajmg.a.63532 . hal-04503163

HAL Id: hal-04503163

<https://hal.science/hal-04503163v1>

Submitted on 13 Mar 2024

HAL is a multi-disciplinary open access archive for the deposit and dissemination of scientific research documents, whether they are published or not. The documents may come from teaching and research institutions in France or abroad, or from public or private research centers.


L'archive ouverte pluridisciplinaire **HAL**, est destinée au dépôt et à la diffusion de documents scientifiques de niveau recherche, publiés ou non, émanant des établissements d'enseignement et de recherche français ou étrangers, des laboratoires publics ou privés.



Distributed under a Creative Commons Attribution - NonCommercial - NoDerivatives 4.0 International License

CASE REPORT

An unusual diagnosis of alpha-mannosidosis with ocular anomalies: Behind the scenes of a hidden copy number variation

Kevin Uguen^{1,2}  | Sylvia Redon^{1,2} | Karen Rouault^{1,2} | Marine Pensec¹ |
Caroline Benech² | Sacha Schutz^{1,2} | Xavier Zanlonghi³ | Yann Nadjar⁴ |
Cédric Le Maréchal^{1,2} | Claude Férec^{1,2} | Séverine Audebert-Bellanger¹

¹Service de Génétique Médicale et Biologie de la Reproduction, CHU de Brest, Brest, France

²Université de Brest, Inserm, EFS, UMR 1078, GGB, Brest, France

³Centre de compétence maladie rare, Service d'Ophthalmologie, CHU Rennes, Rennes, France

⁴Département de Neurologie, Centre de Référence des Maladies Lysosomales, Hôpital Pitié-Salpêtrière, AP-HP, Sorbonne Université, Paris, France

Correspondence

Kevin Uguen, Service de Génétique Médicale et Biologie de la Reproduction, CHU de Brest, France.

Email: kevin.uguen@chu-brest.fr

Abstract

Alpha-mannosidosis is a rare autosomal recessive lysosomal storage disorder caused by biallelic mutations in the *MAN2B1* gene and characterized by a wide clinical heterogeneity. Diagnosis for this multisystemic disorder is confirmed by the presence of either a deficiency in the lysosomal enzyme acid alpha-mannosidase or biallelic mutations in the *MAN2B1* gene. This diagnosis confirmation is crucial for both clinical management and genetic counseling purposes. Here we describe a late diagnosis of alpha-mannosidosis in a patient presenting with syndromic intellectual disability, and a rare retinopathy, where reverse phenotyping played a pivotal role in interpreting the exome sequencing result. While a first missense variant was classified as a variant of uncertain significance, the phenotype-guided analysis helped us detect and interpret an *in-trans* apparent alu-element insertion, which appeared to be a copy number variant (CNV) not identified by the CNV caller. A biochemical analysis showing abnormal excretion of urinary mannosyloligosaccharide and an enzyme assay permitted the re-classification of the missense variant to likely pathogenic, establishing the diagnosis of alpha-mannosidosis. This work emphasizes the importance of reverse phenotyping in the context of exome sequencing.

KEYWORDS

alpha-mannosidosis, CNV, exome sequencing, *MAN2B1*, retinopathy

1 | INTRODUCTION

Alpha-mannosidosis (OMIM:248500) is a rare autosomal recessive lysosomal storage disorder caused by biallelic mutations in the *MAN2B1* gene. Many patients have been described so far in the literature and a large variability in the disease severity is observed between patients (Beck et al., 2013; Malm & Nilssen, 2008). Diagnosis is

suspected in patients with the following clinical findings: neurological anomalies (intellectual disability, psychiatric disturbances, ataxia, motor disorders), sensory defects (bilateral hearing impairment), immune deficiency, skeletal abnormalities (spine and vertebral deformities, scoliosis, pes planus, hip dysplasia...) and facial dysmorphism. Biochemical analyses can reveal serum accumulation or elevated urinary excretion of mannose-rich oligosaccharides. The diagnosis is

This is an open access article under the terms of the [Creative Commons Attribution-NonCommercial-NoDerivs](https://creativecommons.org/licenses/by-nc-nd/4.0/) License, which permits use and distribution in any medium, provided the original work is properly cited, the use is non-commercial and no modifications or adaptations are made.

© 2024 The Authors. *American Journal of Medical Genetics Part A* published by Wiley Periodicals LLC.

confirmed based on deficiency of lysosomal enzyme acid alpha-mannosidase (MAN2B1) in leukocytes or other nucleated cells, or by the identification of biallelic mutations in the *MAN2B1* gene (Malm & Nilsen, 1993). To date, more than 150 pathogenic variations have been reported (Riise Stensland et al., 2015). They include truncative and missense single nucleotide variations (SNVs) across the gene (Riise Stensland et al., 2012), with an apparent genotype–phenotype correlation for missense variants (Borgwardt et al., 2015). Treatment is based, alongside treatment of manifestations, on enzyme replacement therapy (ERT), which has proven highly effective when started early but is still not globally available (Antanasković et al., 2023; Borgwardt et al., 2018), and on hematopoietic stem cell transplantation (HSCT) (Mynarek et al., 2012).

Here, we describe an unusual case of alpha-mannosidosis diagnosis in a 30-year-old man, who presented with a rare ophthalmologic finding. This case also highlights some of the limitations of CNV detection in exome short-read sequencing and the importance of reverse phenotyping to interpret rare missense variations.

2 | METHODS

Patient was recruited in a clinical setting for syndromic intellectual disability. Trio-based exome sequencing (ES) was produced by IntegraGen (IntegraGen SA, Evry, France) using the Agilent CRE v2 enrichment kit (Agilent Technologies, Santa Clara, CA, USA) and an Illumina HiSeq 4000 (Illumina Inc., CA, USA) with paired-end 150 bp reads. Sequences were analyzed with the SeqOne platform (Montpellier, France). Sanger sequencing was performed for variant confirmation and familial segregation of SNV.

CNV analysis was performed by IntegraGen using the GATK4 gCNV algorithm (Babadi et al., 2022). For CNV confirmation and segregation, droplet digital PCR (ddPCR) was performed using the QX200 platform (Bio-Rad) in association with the 90 universal locked nucleic acid (LNA) hydrolysis probes from the Roche Universal ProbeLibrary (UPL, Roche Diagnostics) as described by Cassinari et al. (2019) with minor changes. Data analysis was performed using the 2D module of the QuantaSoft software (Bio-Rad). The copy number was calculated from the ratio of the amount of FAM-labeled target over HEX-labeled reference.

3 | RESULTS

3.1 | Case report

The case is a 30-year-old man presenting with syndromic intellectual disability. After an uneventful pregnancy and birth, early gross motor milestones were achieved within the normal range (sitting at 6 months, walking at 1 year old). His first words appeared at 18 months of age, followed by a stagnation in speech learning. Neurological findings include intellectual disability and, at 16 years of age, psychiatric disorders (depression, visual hallucinations, and

psychotic events). Symptoms of cerebellar ataxia are noticed, with dysarthria, wide-based and unstable gait, dysmetria and tremor. Facial dysmorphism include coarse facies, low-set hairline, thick eyebrows, thick lips, short philtrum and bifid uvula (Figure 1a). Limbs anomalies include right fourth finger brachymetacarpia. Additionally, he was diagnosed with bilateral deafness at the age of five.

At 28 years old, his vision reduced. Ophthalmologic exam highlighted a rapidly progressive cone-rod maculopathy and retinopathy, characterized by a hypoautofluorescent ring around the fovea and hyperautofluorescent ring in the vascular arch (Figure 1b).

A preliminary metabolic screening, consisting solely of urinary glycoaminoglycans and sialic acid, was normal, as well as the array-CGH. Brain MRI showed no pathological finding.

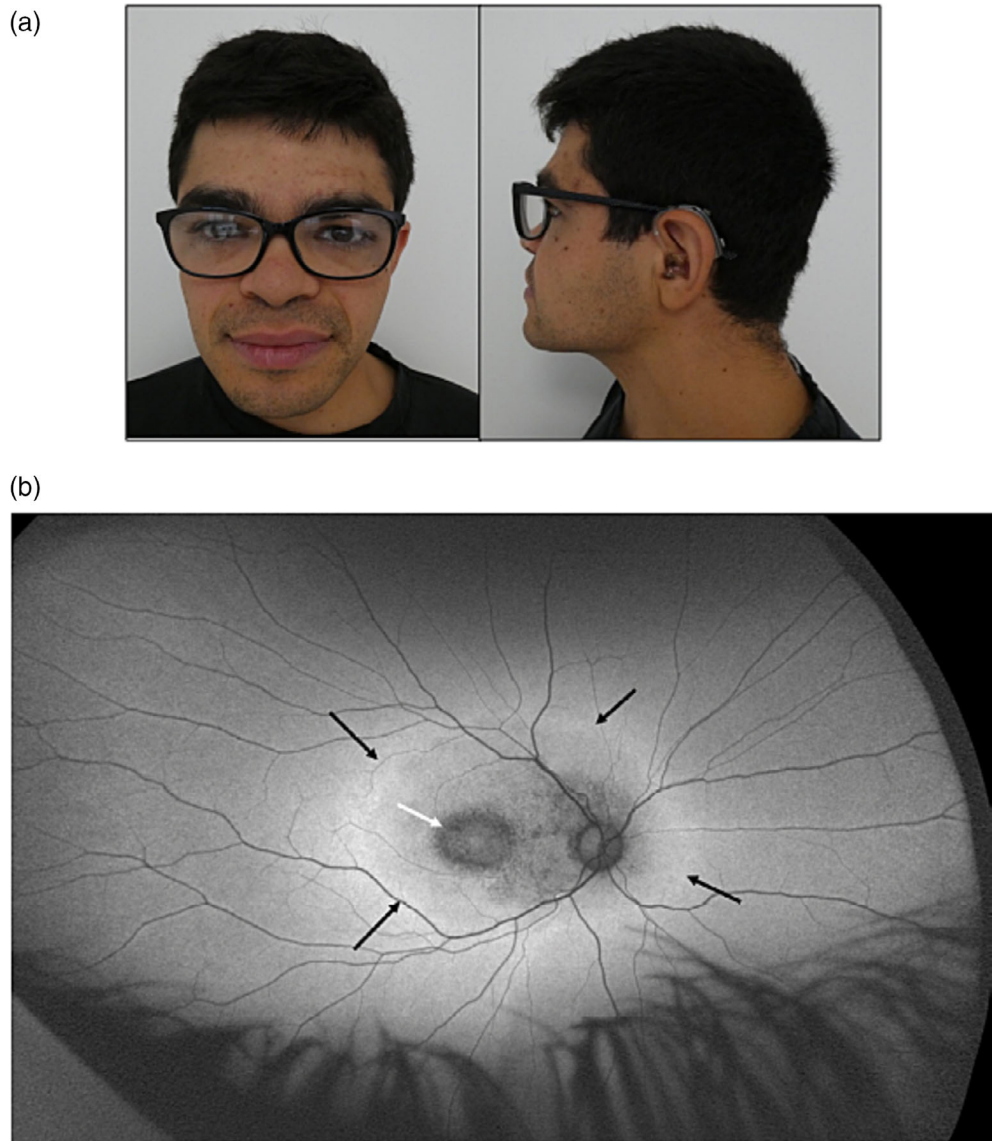
3.2 | Genetic results

In this context, a trio-based ES was performed. First, SNV analysis did not find any *de novo* pathogenic or likely pathogenic variant that could explain the phenotype of the patient. Nevertheless, a heterozygous paternally inherited missense variation in *MAN2B1* was identified: NM_000528.4(*MAN2B1*):c.2176G>A, p.(Gly726Arg) (Figure 2a). This variation was absent from population database (gnomAD v2.1), predicted as pathogenic by all the *in silico* prediction tools interrogated (CADD score: 25.9, REVEL score: 0.899, MetaSVM: 0.8865) and described once in Clinvar as a variant of uncertain significance (VUS) (Clinvar RCV002461775.1). These elements were insufficient to definitely conclude on the pathogenicity of the variation. As a result, it was classified as a VUS according to the American College of Medical Genetics and Genomics recommendations (PM2, PP3) (Richards et al., 2015). No pathogenic SNV or CNV was found *in-trans* in this gene.

Considering the presence of this variant, we revisited the patient's phenotype. Given the shared clinical features between the patient and those of alpha-mannosidosis, that is, facial dysmorphism, neurodevelopmental anomalies, deafness, and retinopathy, we conducted a more in-depth analysis of the *MAN2B1* gene. The SeqOne platform, used to perform the SNV analysis, proposes an algorithm, Alumei, to call for putative mobile element insertions (MEI) (<https://seqone.com/>). This tool identified a maternally inherited Alu element insertion in *MAN2B1*:NM_000528.4(*MAN2B1*):c.2717_2718insALU, p.(Trp906_Pro907insALU). Analysis of the bam files reveals that this insertion was actually a 1156 base pairs deletion encompassing the entire *MAN2B1* exon 21 and 52 base pairs of exon 22 (Figure 2b). This deletion was confirmed by a trio ddPCR (Figure S1) and classified as a loss-of-function pathogenic variation (PVS1, PM2). Despite the presence of a pathogenic variant *in-trans* (PM3), the missense variant remained classified as a VUS.

Therefore, we performed a biochemical analysis of urinary oligosaccharides (liquid chromatography and mass spectrometry), that revealed an important urinary mannosyloligosaccharide excretion, consistent with the diagnosis of alpha-mannosidosis. Enzyme assay was also performed on the patient's lymphocytes, revealing the total

FIGURE 1 Clinical features of the index case. (a) Facial dysmorphism, showing coarse features, thick eyebrows, low anterior hairline. (b) Right eye (FAF) showing three different types of autofluorescence: normal peripheral autofluorescence (area of preserved tissue), a fairly large ring of intense hyperautofluorescence in the vascular arches (black arrows) and a somewhat inhomogeneous internal ring of hypoautofluorescence (external retinal atrophy) (white fundus autofluorescence arrow) and in the center a well-preserved fluorescence of the fovea close to normal.



absence of alpha-mannosidase activity. These elements added new evidence for the interpretation of both variants (PP4: Patient's phenotype or family history is highly specific for a disease with a single genetic etiology) and permitted to classify the missense variant as likely pathogenic.

All these elements (clinical phenotype, biochemical analysis and genetic results) led to the diagnosis of alpha mannosidosis, ending the diagnostic odyssey of nearly 30 years for the patient and his parents.

4 | DISCUSSION

Here we describe an unusual diagnosis of alpha-mannosidosis in an adult proband. This rare autosomal recessive lysosomal storage condition is characterized by a wide phenotypic spectrum (Malm & Nilssen, 1993). Originally, different forms of this disorder have been described, based on the age of onset, that is, (i) a severe type with central nervous system anomalies, infections and early death, (ii) a

moderate form with a myopathy and skeletal anomalies occurring before 10 years old, and (iii) a mild form, with an onset after 10 years old and without skeletal anomalies (Malm & Nilssen, 2008). However other studies have suggested that patients should be placed within a continuum of symptoms and progression (Beck et al., 2013). Due to the variability of the clinical presentation during lifespan, a recent international working group published guidelines to discuss shortcomings in the diagnosis of alpha-mannosidosis in patients, based on their age (Guffon et al., 2019). They stated that, after 10 years old, hearing loss, ataxia and psychiatric disorder are the three most prominent signs found in patients. In our case, retrospectively, the patient presented with main clinical features of alpha-mannosidosis. He developed retinopathy at the age of 28. Although rare, it is important to note that late onset retinal degeneration has been described in a few cases, and a recent study estimated a frequency of 1.8% in this patient population (Courtney & Pennesi, 2011; Matlach et al., 2018; Springer et al., 2005; Zielonka et al., 2019). Biochemical analyses, including screening for urine oligosaccharides (which is not considered

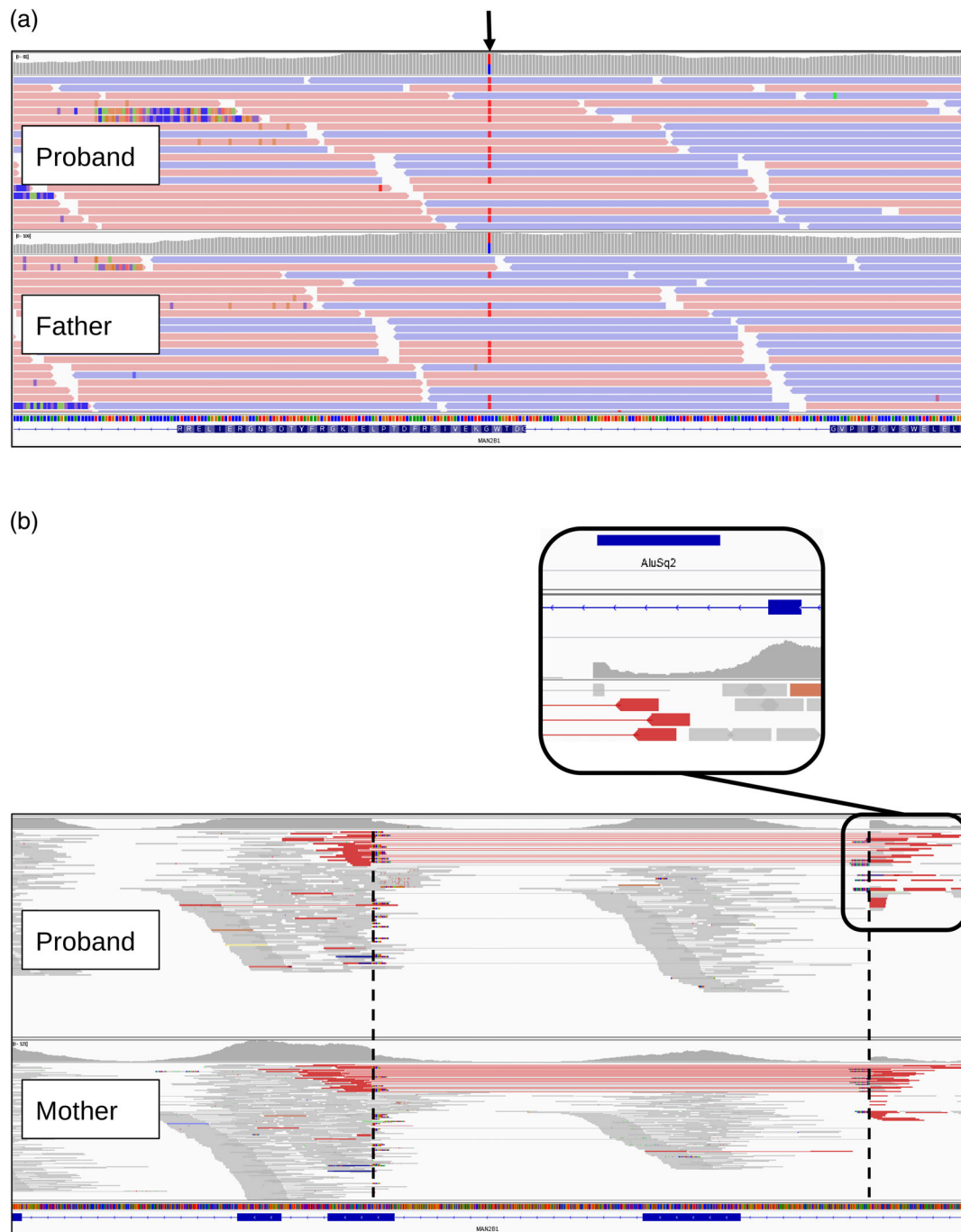


FIGURE 2 Genetic variants in *MAN2B1*. (a) IGV visualization of proband's and father's bam files showing the heterozygous missense variant in *MAN2B1* (black arrow). (b) IGV visualization of proband's and mother's bam files showing the 1556 base pairs deletion between the two vertical dashed lines. Red reads correspond to inferred insert size that is larger than expected, suggesting a deletion.

as a diagnostic test (Malm & Nilssen, 2008), and enzymatic activity assay, should be considered when retinopathy is present, especially if it is associated with intellectual disability, bilateral deafness, and facial dysmorphism. Our patient also presented with bifid uvula, which has not been described so far. More clinical descriptions are required to determine if this feature is part of the syndrome.

Our patient carried, *in-trans* with a missense variation, a 1.1 kilobases deletion within the *MAN2B1* gene. This deletion has not been

pointed out by the GATK4 gCNV algorithm, unlike the CNV caller Lumpy (Layer et al., 2014) (Table S1). CNV detection in short-read exome sequencing data is challenging, especially if based on read depth, with an over- and underrepresentation of target regions due to the capture step and PCR stages (Gordeeva et al., 2021). Several CNV detection tools are available, with various efficiency rates, and a common trend to produce false-positive results (Babadi et al., 2022; Gordeeva et al., 2021; Layer et al., 2014). In our pipeline, the presence of

the CNV was only raised by the Alumei algorithm from SeqOne, which called it as an Alu insertion. This, although lucky, miscalling is due to the presence of an Alu element at the intronic breakpoint of the deletion (Figure 2b). Originally, this algorithm has been developed to detect mobile element insertions, as they have been described in human diseases (Torene et al., 2020). Disease-causing mobile element insertions remain rare, and callers can produce large amounts of false positive results. It is crucial to visualize the alignment files, via genome viewers such as IGV, when a putative MEI is detected, moreover if it is in-trans with another variant in a recessive disease.

GATK4 gCNV uses read-depth information, while Lumpy combines read-depth information and split-reads, which was useful in our case as the deletion occurs within an exon and split-reads are present (Figure 2b). This outcome raises the importance of using different CNV detection algorithms, and preferentially algorithms based on read-depth and split-reads, especially for small CNVs.

In conclusion, this late diagnosis of alpha-mannosidosis in an adult proband enabled the patient and his family to end a 30-year diagnostic odyssey. We highlighted the importance of reverse phenotyping in the interpretation of VUS, especially when *in-trans* with a pathogenic variant, and described a novel case of particular retinopathy in this rare lysosomal storage disease. Despite the debate surrounding the treatment by ERT or HSCT in an adult patient (Borgwardt et al., 2018; Mynarek et al., 2012; Wall et al., 1998), this case report also illustrates the importance of biochemical analyses such as urinary oligosaccharides and enzymatic assay when a metabolic condition is clinically suspected.

AUTHOR CONTRIBUTIONS

Kevin Uguen and Séverine Audebert-Bellanger designed the study. Kevin Uguen, Séverine Audebert-Bellanger and Xavier Zanlonghi reviewed the clinical description. Kevin Uguen, Sylvia Redon, Karen Rouault, Sacha Schutz, Cédric Le Maréchal and Claude Férec analyzed the exome sequencing data. Marine Pensec and Caroline Benech conducted experiments (exome sequencing, digital droplet PCR). Yann Nadjar performed the biochemical analyses. Kevin Uguen wrote the manuscript. All authors discussed the results and contributed to the final manuscript.

CONFLICT OF INTEREST STATEMENT

The authors declare no conflicts of interest.

DATA AVAILABILITY STATEMENT

The data that support the findings of this study are available on request from the corresponding author. The data are not publicly available due to privacy or ethical restrictions.

ORCID

Kevin Uguen  <https://orcid.org/0000-0002-6744-2837>

REFERENCES

Antanasković, A., Stević, I., Gojak, R., Lakić, D., & Janković, S. (2023). Cost-effectiveness of velmanase alfa vs. bone marrow transplantation or no

- causal therapy in patients with mild to moderate alpha-mannosidosis. *Biotechnology and Biotechnological Equipment*, 37, 2271574.
- Babadi, M., Fu, J. M., Lee, S. K., Smirnov, A. N., Gauthier, L. D., Walker, M., Benjamin, D. I., Zhao, X., Karczewski, K. J., Wong, I., Collins, R. L., Sanchis-Juan, A., Brand, H., Banks, E., & Talkowski, M. E. (2022). GATK-gCNV: A Rare Copy Number Variant Discovery Algorithm and Its Application to Exome Sequencing in the UK Biobank. <https://doi.org/10.1101/2022.08.25.504851>
- Beck, M., Olsen, K. J., Wraith, J. E., Zeman, J., Michalski, J. C., Saftig, P., Fogh, J., & Malm, D. (2013). Natural history of alpha mannosidosis a longitudinal study. *Orphanet Journal of Rare Diseases*, 8, 88.
- Borgwardt, L., Guffon, N., Amraoui, Y., Dali, C. I., de Meirleir, L., Gil-Campos, M., Heron, B., Geraci, S., Ardigò, D., Cattaneo, F., Fogh, J., van den Hout, J. M. H., Beck, M., Jones, S. A., Tylki-Szymanska, A., Haugsted, U., & Lund, A. M. (2018). Efficacy and safety of Velmanase alfa in the treatment of patients with alpha-mannosidosis: Results from the core and extension phase analysis of a phase III multicentre, double-blind, randomised, placebo-controlled trial. *Journal of Inherited Metabolic Disease*, 41, 1215–1223.
- Borgwardt, L., Stensland, H. M. F. R., Olsen, K. J., Wibrand, F., Klenow, H. B., Beck, M., Amraoui, Y., Arash, L., Fogh, J., Nilssen, Ø., Dali, C. I., & Lund, A. M. (2015). Alpha-mannosidosis: Correlation between phenotype, genotype and mutant MAN2B1 subcellular localisation. *Orphanet Journal of Rare Diseases*, 10, 70.
- Cassinari, K., Quenez, O., Joly-Hélas, G., Beaussire, L., le Meur, N., Castelain, M., Goldenberg, A., Guerrot, A. M., Brehin, A. C., Deleuze, J. F., Boland, A., Rovelet-Lecrux, A., Campion, D., Saugier-Verber, P., Gruchy, N., Frebourg, T., Nicolas, G., Sarafan-Vasseur, N., & Chambon, P. (2019). A simple, universal, and cost-efficient digital PCR method for the targeted analysis of copy number variations. *Clinical Chemistry*, 65, 1153–1160.
- Courtney, R. J., & Pennesi, M. E. (2011). Retinal dystrophy in 2 brothers with α -mannosidosis. *Archives of Ophthalmology*, 129, 799–802.
- Gordeeva, V., Sharova, E., Babalyan, K., Sultanov, R., Govorun, V. M., & Arapidi, G. (2021). Benchmarking germline CNV calling tools from exome sequencing data. *Scientific Reports*, 11, 14416.
- Guffon, N., Tylki-Szymanska, A., Borgwardt, L., Lund, A. M., Gil-Campos, M., Parini, R., & Hennermann, J. B. (2019). Recognition of alpha-mannosidosis in paediatric and adult patients: Presentation of a diagnostic algorithm from an international working group. *Molecular Genetics and Metabolism*, 126, 470–474.
- Layer, R. M., Chiang, C., Quinlan, A. R., & Hall, I. M. (2014). LUMPY: A probabilistic framework for structural variant discovery. *Genome Biology*, 15, R84.
- Malm, D., & Nilssen, Ø. (1993). Alpha-mannosidosis. In M. P. Adam, et al. (Eds.), *GeneReviews*[®]. University of Washington.
- Malm, D., & Nilssen, Ø. (2008). Alpha-mannosidosis. *Orphanet Journal of Rare Diseases*, 3, 21.
- Matlach, J., Zindel, T., Amraoui, Y., Arash-Kaps, L., Hennermann, J. B., & Pitz, S. (2018). Retinal and optic nerve degeneration in α -mannosidosis. *Orphanet Journal of Rare Diseases*, 13, 88.
- Mynarek, M., Tolar, J., Albert, M. H., Escolar, M. L., Boelens, J. J., Cowan, M. J., Finnegan, N., Glomstein, A., Jacobsohn, D. A., Kühl, J. S., Yabe, H., Kurtzberg, J., Malm, D., Orchard, P. J., Klein, C., Lücke, T., & Sykora, K. W. (2012). Allogeneic hematopoietic SCT for alpha-mannosidosis: An analysis of 17 patients. *Bone Marrow Transplantation*, 47, 352–359.
- Richards, S., Aziz, N., Bale, S., Bick, D., Das, S., Gastier-Foster, J., Grody, W. W., Hegde, M., Lyon, E., Spector, E., Voelkerding, K., & Rehms, H. L. (2015). Standards and guidelines for the interpretation of sequence variants: A joint consensus recommendation of the American College of Medical Genetics and Genomics and the Association for Molecular Pathology. *Genetics in Medicine*, 17, 405–424.
- Riise Stensland, H. M. F., Frantzen, G., Kuokkanen, E., Buvang, E. K., Klenow, H. B., Heikinheimo, P., Malm, D., & Nilssen, Ø. (2015).

- Amamutdb.no: A relational database for MAN2B1 allelic variants that compiles genotypes, clinical phenotypes, and biochemical and structural data of mutant MAN2B1 in α -mannosidosis. *Human Mutation*, 36, 581–586.
- Riise Stensland, H. M. F., Klenow, H. B., Nguyen, L. V., Hansen, G. M., Malm, D., & Nilssen, Ø. (2012). Identification of 83 novel alpha-mannosidosis-associated sequence variants: Functional analysis of MAN2B1 missense mutations. *Human Mutation*, 33, 511–520.
- Springer, C., Gutschalk, A., Meinck, H., & Rohrschneider, K. (2005). Late-onset retinal dystrophy in alpha-mannosidosis. *Graefe's Archive for Clinical and Experimental Ophthalmology*, 243, 1277–1279.
- Torene, R. I., Galens, K., Liu, S., Arvai, K., Borroto, C., Scuffins, J., Zhang, Z., Friedman, B., Sroka, H., Heeley, J., Beaver, E., Clarke, L., Neil, S., Walia, J., Hull, D., Juusola, J., & Retterer, K. (2020). Mobile element insertion detection in 89,874 clinical exomes. *Genetics in Medicine*, 22, 974–978.
- Wall, D. A., Grange, D. K., Goulding, P., Daines, M., Luisiri, A., & Kotagal, S. (1998). Bone marrow transplantation for the treatment of α -mannosidosis. *The Journal of Pediatrics*, 133, 282–285.
- Zielonka, M., Garbade, S. F., Kölker, S., Hoffmann, G. F., & Ries, M. (2019). Ultra-orphan lysosomal storage diseases: A cross-sectional quantitative analysis of the natural history of alpha-mannosidosis. *Journal of Inherited Metabolic Disease*, 42, 975–983.

SUPPORTING INFORMATION

Additional supporting information can be found online in the Supporting Information section at the end of this article.

How to cite this article: Uguen, K., Redon, S., Rouault, K., Pensec, M., Benech, C., Schutz, S., Zanlonghi, X., Nadjar, Y., Le Maréchal, C., Férec, C., & Audebert-Bellanger, S. (2024). An unusual diagnosis of alpha-mannosidosis with ocular anomalies: Behind the scenes of a hidden copy number variation. *American Journal of Medical Genetics Part A*, 1–6. <https://doi.org/10.1002/ajmg.a.63532>