



HAL
open science

Double-clip traction endoscopic submucosal dissection: an interesting alternative method for the resection of pedunculated polyps

Jérémie Albouys, Sophie Geyl, Lambin Thomas, Thibault Kaighobadi,
Romain Legros, Mathieu Pioche, Jérémie Jacques

► To cite this version:

Jérémie Albouys, Sophie Geyl, Lambin Thomas, Thibault Kaighobadi, Romain Legros, et al.. Double-clip traction endoscopic submucosal dissection: an interesting alternative method for the resection of pedunculated polyps. *Endoscopy*, 2022, 54 (S 02), pp.E929-E930. 10.1055/a-1841-5513 . hal-04502607

HAL Id: hal-04502607

<https://hal.science/hal-04502607>

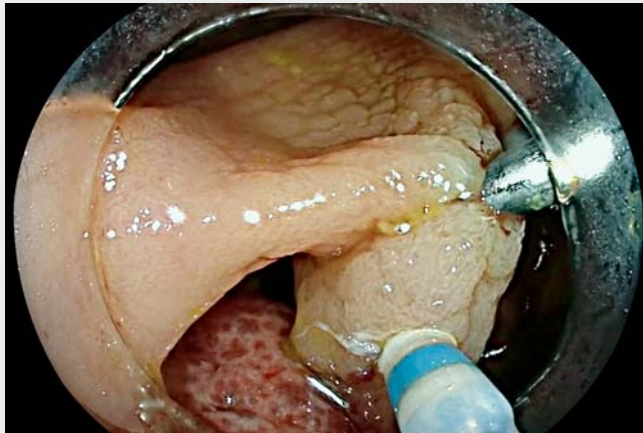
Submitted on 21 May 2024

HAL is a multi-disciplinary open access archive for the deposit and dissemination of scientific research documents, whether they are published or not. The documents may come from teaching and research institutions in France or abroad, or from public or private research centers.

L'archive ouverte pluridisciplinaire **HAL**, est destinée au dépôt et à la diffusion de documents scientifiques de niveau recherche, publiés ou non, émanant des établissements d'enseignement et de recherche français ou étrangers, des laboratoires publics ou privés.

Double-clip traction endoscopic submucosal dissection: an interesting alternative method for the resection of pedunculated polyps

OPEN
ACCESS



▶ **Video 1** Double-clip traction endoscopic submucosal dissection.

The management of pedunculated polyps can be challenging due to the bleeding risk and the technical difficulty in positioning the snare. In cases of a head diameter >20 mm and/or stalk width >10 mm, prevention of bleeding is necessary by injection of diluted adrenalin and/or mechanical hemostatic prevention, as recommended by the European Society of Gastrointestinal Endoscopy [1]. Mechanical prevention can hamper resection by causing difficulties in snare opening and placement. In addition to size, the nature of the polyp also influences the bleeding risk, and hamartomatous/juvenile polyps have a higher propensity to bleed [2].

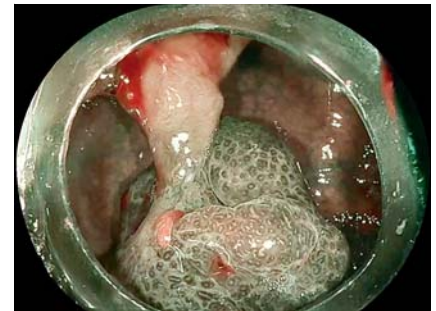
We report here the case of a 60-year-old patient, in whom a large pedunculated polyp of the right colon was discovered during a screening colonoscopy (▶ **Video 1**). During endoscopic characterization, the appearance did not indicate an adenomatous origin; rather, it suggested a hamartomatous/juvenile type (▶ **Fig. 1**). As snaring was difficult due to the large

size of the polyp head, we performed resection by endoscopic submucosal dissection (ESD).

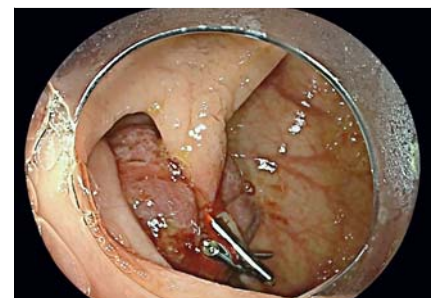
In the first step, a clip with a rubber band was placed under the head of the polyp to limit bleeding and to allow traction (▶ **Fig. 2**) [3]. Next, a second clip was placed at the base of the stalk. Dissection without injection was then performed between the two clips, which enabled safe resection, aided by traction, and minimized bleeding (▶ **Fig. 3**). Histological analysis confirmed that this was a nondysplastic juvenile polyp with complete resection.

ESD could be an interesting alternative for the resection of pedunculated polyps with a large head because the technique overcomes the difficulty in snare positioning following the application of preventive hemostasis methods (such as an endoloop) or caused by the large size of the polyp head.

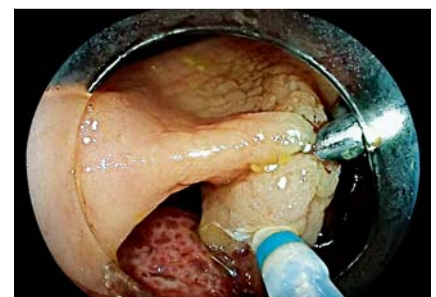Endoscopy_UCTN_Code_TTT_1AQ_2AD



▶ **Fig. 1** Right colon polyp with nonadenomatous origin.



▶ **Fig. 2** A clip with rubber band was placed under the head of the polyp to allow traction.



▶ **Fig. 3** Dissection between the two clips.

Competing interests

The authors declare that they have no conflict of interest.

The authors

Jérémie Albouys¹, Sophie Geyl¹, Lambin Thomas², Thibault Kaighobadi³, Romain Legros¹, Mathieu Pioche², Jérémie Jacques¹

- 1 Gastroentérologie et endoscopie digestive, CHU Dupuytren, Limoges, France
- 2 Unité d'endoscopie digestive, service de Gastroentérologie pavillon H, Hôpital Edouard Herriot, Hospices Civils de Lyon, Lyon, France
- 3 Gastroentérologie et endoscopie digestive, Clinique Croix du Sud, Toulouse, France

Corresponding author

Jérémie Albouys, MD

Service d'Hépatogastroentérologie, CHU Dupuytren, 2 avenue Martin Luther-king, 87042 Limoges, France
jeremie.albouys@gmail.com

References

- [1] Ferlitsch M, Moss A, Hassan C et al. Colorectal polypectomy and endoscopic mucosal resection (EMR): European Society of Gastrointestinal Endoscopy (ESGE) Clinical Guideline. *Endoscopy* 2017; 49: 270–297
- [2] Cauchin E, Touchefeu Y, Matysiak-Budnik T. Hamartomatous tumors in the gastrointestinal tract. *Gastrointest Tumors* 2015; 2: 65–74
- [3] Bordillon P, Pioche M, Wallenhorst T et al. Double-clip traction for colonic endoscopic submucosal dissection: a multicenter study of 599 consecutive cases (with video). *Gastrointest Endosc* 2021; 94: 333–343

Bibliography

Endoscopy 2022; 54: E929–E930

DOI 10.1055/a-1841-5513

ISSN 0013-726X

published online 5.7.2022

© 2022. The Author(s).

This is an open access article published by Thieme under the terms of the Creative Commons Attribution-NonDerivative-NonCommercial License, permitting copying and reproduction so long as the original work is given appropriate credit. Contents may not be used for commercial purposes, or adapted, remixed, transformed or built upon. (<https://creativecommons.org/licenses/by-nc-nd/4.0/>)

Georg Thieme Verlag KG, Rüdigerstraße 14, 70469 Stuttgart, Germany



ENDOSCOPY E-VIDEOS

<https://eref.thieme.de/e-videos>



Endoscopy E-Videos is an open access online section, reporting on interesting cases

and new techniques in gastroenterological endoscopy. All papers include a high quality video and all contributions are freely accessible online. Processing charges apply (currently EUR 375), discounts and waivers acc. to HINARI are available.

This section has its own submission website at

<https://mc.manuscriptcentral.com/e-videos>