



**HAL**  
open science

## **A novel fusion variant LSM14A :: NR4A3 in extraskelatal myxoid chondrosarcoma**

Carine Ngo, Benjamin Verret, Julien Vibert, Sophie Cotteret, Antonin Levy,  
Leila Haddag-Miliani, Charles Honore, Matthieu Faron, Fabien Quinquis,  
Axel Le Cesne, et al.

► **To cite this version:**

Carine Ngo, Benjamin Verret, Julien Vibert, Sophie Cotteret, Antonin Levy, et al.. A novel fusion variant LSM14A :: NR4A3 in extraskelatal myxoid chondrosarcoma. *Genes, Chromosomes & Cancer*, 2022, 62 (1), pp.52-56. 10.1002/gcc.23090 . hal-04500985

**HAL Id: hal-04500985**


**<https://hal.science/hal-04500985>**

Submitted on 24 May 2024

**HAL** is a multi-disciplinary open access archive for the deposit and dissemination of scientific research documents, whether they are published or not. The documents may come from teaching and research institutions in France or abroad, or from public or private research centers.

L'archive ouverte pluridisciplinaire **HAL**, est destinée au dépôt et à la diffusion de documents scientifiques de niveau recherche, publiés ou non, émanant des établissements d'enseignement et de recherche français ou étrangers, des laboratoires publics ou privés.

# A novel fusion variant *LSM14A::NR4A3* in extraskeletal myxoid chondrosarcoma

Carine Ngo<sup>1</sup>  | Benjamin Verret<sup>2</sup> | Julien Vibert<sup>2</sup> | Sophie Cotteret<sup>1</sup> | Antonin Levy<sup>3</sup> | Cécile Le Pechoux<sup>3</sup> | Leila Haddag-Miliani<sup>4</sup> | Charles Honore<sup>5</sup> | Matthieu Faron<sup>5</sup> | Fabien Quinquis<sup>6</sup> | Axel Le Cesne<sup>2</sup> | Jean-Yves Scoazec<sup>1</sup> | Gaëlle Pierron<sup>6</sup>

<sup>1</sup>Department of Pathology and Biology, Gustave Roussy, Villejuif, France

<sup>2</sup>Department of Medicine, Gustave Roussy, Villejuif, France

<sup>3</sup>Department of Radiation Oncology, Gustave Roussy, Villejuif, France

<sup>4</sup>Department of Radiology, Gustave Roussy, Villejuif, France

<sup>5</sup>Department of Surgery, Gustave Roussy, Villejuif, France

<sup>6</sup>Department of Genetics, Institut Curie, Paris, France

## Correspondence

Carine Ngo, Department of Pathology and Biology, Gustave Roussy, Villejuif, France, 114 Rue Edouard Vaillant, 94900 Villejuif, France.

Email: [carine.ngo@gustaveroussy.fr](mailto:carine.ngo@gustaveroussy.fr)

## Abstract

Extraskeletal myxoid chondrosarcoma (EMC) is a rare soft tissue neoplasm of uncertain lineage characterized by the pathognomonic rearrangement of the *NR4A3* gene, which in most cases is fused with *EWSR1*. Other *NR4A3* fusion partners have been described, namely *TAF15*, *FUS*, *TCF12*, and *TGF*. Some studies suggest that EMCs with non-*EWSR1* variant fusion are associated with high-grade morphology and worst clinical behavior compared to *EWSR1::NR4A3* tumors, supporting the potential significance of particular fusion variant in EMC. We report a case of a 34-year-old male who presented with calf EMC and subsequently developed a slowly progressive metastatic disease 3 years after diagnosis. Whole-transcriptome analysis with total RNA sequencing enabled identification of a novel fusion transcript *LSM14A::NR4A3*, expanding the molecular spectrum of EMC.

## KEYWORDS

extraskeletal myxoid chondrosarcoma, gene fusion, *LSM14A::NR4A3*

## 1 | INTRODUCTION

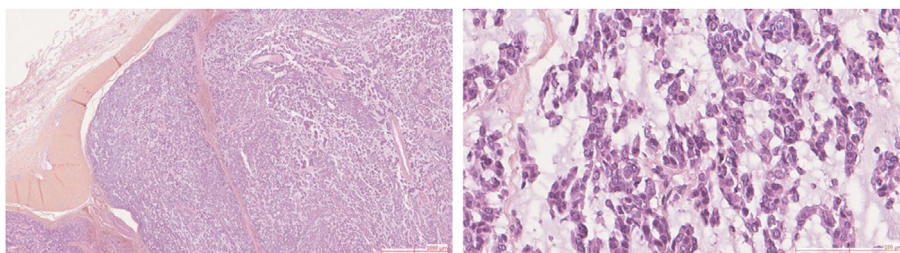
Extraskeletal myxoid chondrosarcoma (EMC) is defined by the World Health Organization (WHO) as a sarcoma of uncertain differentiation characterized by *NR4A3* gene rearrangement.<sup>1</sup> The *NR4A3* gene encodes an orphan nuclear receptor of the steroid/thyroid receptor gene family, which is involved in multiple biological functions associated with oncogenesis, including proliferation, apoptosis, and DNA repair.<sup>2</sup> *NR4A3* rearrangements are present in more than 90% of EMCs and have not been described so far in other sarcomas, which make them hallmarks of the disease.

Despite its extreme rarity, EMC shows a degree of molecular heterogeneity. The two most frequent rearrangements observed are: a t(9;22) variant translocation that results in a *EWSR1::NR4A3* fusion gene and a t(9;17) translocation resulting in a *TAF15::NR4A3* fusion gene.<sup>3,4</sup> In addition, alternative partner genes including *TCF12*,<sup>4,5</sup>

*TFG*,<sup>6</sup> *FUS*,<sup>7</sup> *HSPA8*,<sup>8</sup> and *SMARCA2*<sup>9</sup> have also been identified in occasional cases.

EMC commonly displays indolent behavior with prolonged survival despite a high rate of metastases.<sup>10</sup> Agaram et al. suggested that non-*EWSR1::NR4A3* EMCs (namely *TAF15* and *TCF12*-fused) were associated with high-grade morphology, rhabdoid phenotype, and a more aggressive outcome compared to *EWSR1::NR4A3* tumors,<sup>4</sup> but clinical data were limited. In line with this finding, a recent study with transcriptomic analysis of *EWSR1::NR4A3* and *TAF15::NR4A3* subtypes highlighted distinct transcriptional profiles, with a differential involvement of axon guidance pathway and neurogenesis.<sup>11</sup> Interestingly, *TAF15::NR4A3* cell models featured higher tumorigenic potential than *EWSR1::NR4A3* cells, suggesting that the type of *NR4A3* fusion protein may impact clinical behavior.<sup>11</sup> In addition, in one of the largest reported series of patients affected by EMC with a molecularly confirmed diagnosis, patients carrying the *EWS::NR4A3* translocation

**FIGURE 1** Histological findings in EMC. Surgical specimen shows an encapsulated highly cellular tumor (H&E, 40 $\times$ ); higher magnification showing cords of epithelioid cells, without rhabdoid feature and marked atypia, deposited in a myxoid stroma (H&E, 200 $\times$ )



had a trend in favor of a better outcome compared with the patients with *TAF15::NR4A3*.<sup>12</sup>

Here we report a novel fusion variant *LSM14A::NR4A3* in a patient with EMC.

## 2 | MATERIALS AND METHODS

### 2.1 | Clinical and pathological findings

In May 2012, a 34-year-old male with a past history of embryonal carcinoma of the testis treated in 2008 by orchiectomy and adjuvant chemotherapy, presented with a 2-month history of painless swelling in the left calf. The MRI scan showed a 10  $\times$  9 cm circumscribed intramuscular lesion located in the posterior compartment of the leg. The lesion was hypointense on T1-weighted imaging and showed a centrally hyperintense signal in T2-weighted imaging.

The histopathological examination of a core biopsy of the mass showed cords of epithelioid cells separated by a hypovascular myxoid stroma. Immunohistochemical analysis showed negativity for cytokeratins, epithelial membrane antigen (EMA), S100 protein, muscular and vascular markers. A diagnosis of EMC was suspected but, at this date, quantitative reverse transcription PCR (RT-qPCR) failed to detect either *EWSR1::NR4A3* or *TAF15::NR4A3* fusions previously described in these tumors.

The patient received neoadjuvant doxorubicin and ifosfamide (2 cycles of doxorubicin 60 mg/m<sup>2</sup> and ifosfamide 3 g/m<sup>2</sup>) without objective response, followed by radical surgery in September 2012. *TP53* genetic testing for Li-Fraumeni syndrome was negative.

Examination of the surgical specimen showed a well-circumscribed highly cellular tumor with scant myxoid stroma (Figure 1). The proliferation was composed of epithelioid cells characterized by a thin rim of eosinophilic cytoplasm with mild atypia and without rhabdoid features. The mitotic rate was low, equal to 3 per 10 high power fields. Immunohistochemically, the tumor cells were positive for NSE and synaptophysin, with retained nuclear SMARCB1 expression. The favored diagnosis remained EMC, despite the lack of molecular proof. The deep resection margin was involved.

The patient received adjuvant radiation therapy at a total dose of 50 Gy with a 10 Gy boost on the R1 area. At 29 months follow-up, the whole-body CT scan revealed several lung micronodules with no evidence of local recurrence. A lung biopsy confirmed the diagnosis of metastatic EMC. Given slow lung disease progression, a

systemic treatment was initially postponed and pazopanib was later initiated in April 2018. Subsequent CT scans confirmed stable lung disease according to RECIST v1.1, except for one para-esophageal lesion that was treated by stereotactic radiation therapy at a total dose of 45 Gy in 10 fractions in August 2019. In July 2020, the patient developed a subcutaneous nodule on the thoracic wall. The resection of the lesion confirmed the metastasis of the previously described tumor. Pazopanib was continued until July 2021, at which time the patient experienced multifocal disease progression. He subsequently received oral cyclophosphamide during 6 months with stable disease as best response, followed by oral vinorelbine. To date, the patient is still on vinorelbine after 6 months of treatment, with stable disease.

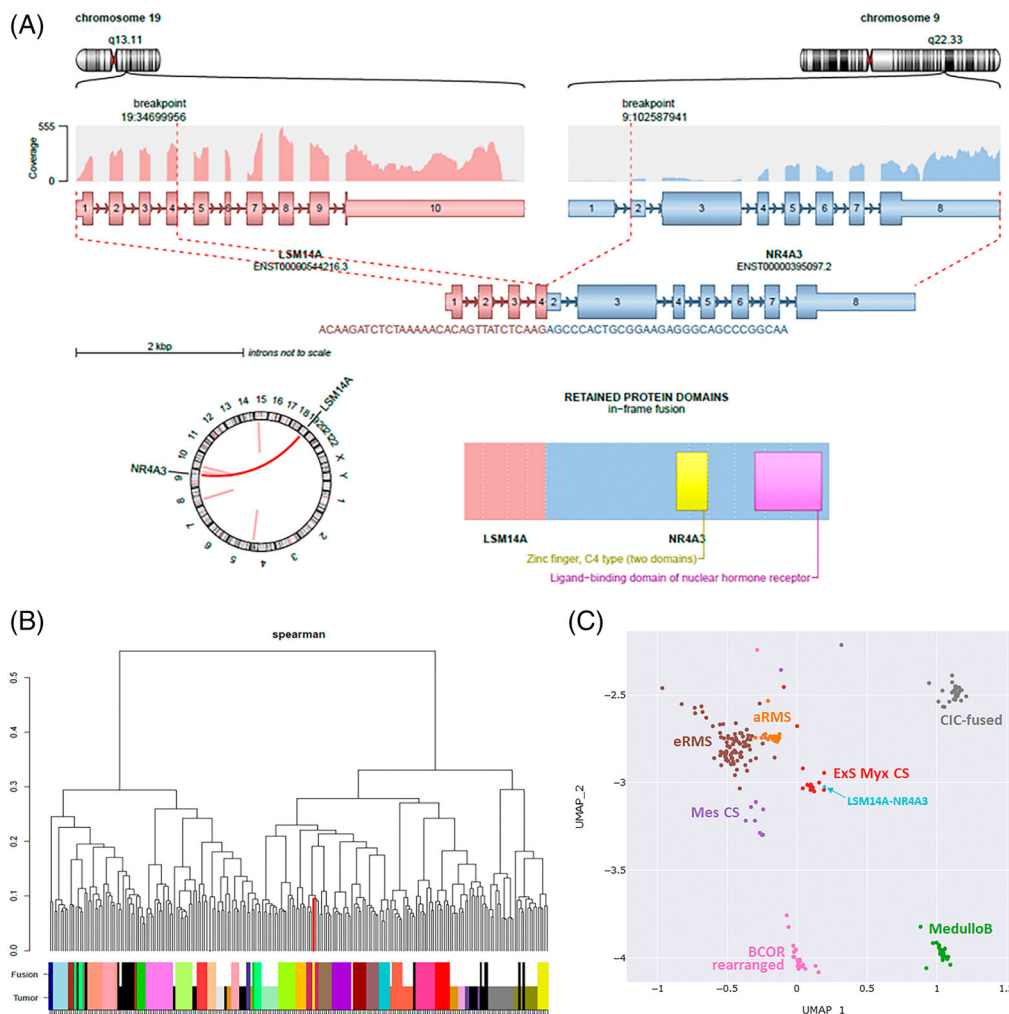
In order to definitely assess the diagnosis of EMC, it was decided to perform total RNA sequencing from available fresh frozen tissue specimens in order to search for alternative *NR4A3* rearrangements not detected by previous RT-qPCR.

### 2.2 | Total RNA sequencing

To analyze gene expression, RNA sequencing was performed on total mRNA isolated from fresh-frozen primary tumor sample, using Trizol reagent (Life Technologies). Libraries were prepared with TruSeq mRNA-stranded library kits (Illumina, Inc., San Diego, CA). Libraries were sequenced over 2  $\times$  150 bp with a 500 High Output v2 on NextSeq500 (Illumina, Inc., San Diego, CA). Atropos (v1.1.21) was used to trim adapters from fastq files.

The fusion analysis was performed from fastq using two complementary approaches. Firstly, a targeted analysis, using an in-house tool designed to search for well-characterized fusion sequences. The second approach is an exploratory analysis based on 5 tools for fusion transcript detection: Defuse V0.6.2, StarFusion v1.2.0 (STAR v 2.5.4a), Fusion Catcher v1.00, FusionMap (Oshell toolkit v10.0.1.50), and ARRIBA v1.2.0. The final fusion results were obtained by combining the results of the two approaches.

Expression data were generated with SALMON (v0.13.1) on Ensembl 96 (hg19) and the count matrix was normalized to TPM using tximport (R library). The data were then used for hierarchical clustering analysis (Ward method and Spearman or Pearson correlation with or without interquartile range) and for boxplot generation. In parallel, a supervised classification of the sample into known cancer subtypes was inferred using a variational autoencoder (VAE) model as described



**FIGURE 2** Representative graphical output of RNAseq Analysis. (A) Arriba illustration of the rearrangement and fusion transcript. For each partner, chromosomal localization and gene scheme with its own coverage are represented. The resulting fusion transcript and the predicted chimeric protein are figured below. (B) Hierarchical clustering composed of 250 well-characterized sarcomas (clinically, histologically, and molecularly validated). The *LSM14A::NR4A3* case (red branch of the cluster and sample highlight in yellow) clearly clustered within the Extraskeletal Myxoid Chondrosarcoma (burgundy color code). (C) Classifier, based on UMAP and VAE model, which inferred tumor subtype for tested samples. Here, the *LSM14A::NR4A3* sample (in light blue) clustered again within Extraskeletal Myxoid Chondrosarcoma group (ExS Myx CS, Burgundy) and apart from Mesenchymal Chondrosarcoma (Mes Cs, Purple) and other nearby groups (e/aRMS: embryonal/alveolar Rhabdomyosarcoma; CIC-fused: Tumor with CIC fusion event; BCOR-rearranged: BCOR-ITD and BCOR-Fused tumors; MedulloB: Medulloblastoma)

in Vibert et al.<sup>13</sup> This model includes expression data (generated with STAR v2.7.0e) of 21 916 cases already categorized.

### 3 | RESULTS

#### 3.1 | Fusion variant detection

Fusion transcript analysis highlighted the presence of a novel chimeric RNA involving *LSM14A*, mapping to 19q13.11, and *NR4A3*. This fusion gene was found by RNA sequencing with a bioinformatic pipeline using 5 different tools (Arriba, Fusioncatcher, FusionMap, StarFusion, and Defuse) and was detected in each of them. The fusion point

involved exon 4 of *LSM14A* and exon 2 of *NR4A3* (Figure 2A). The *LSM14A::NR4A3* fusion corresponded to the entire *NR4A3* protein from exon 2 and exon 1–4 of *LSM14A* (Figure 2A). No other fusion involving *NR4A3* was detected. The signal was highly specific.

#### 3.2 | Fusion variant validation

Additional analyses using clustering were also performed. The first one was based on hierarchical clustering analysis (Ward method and Spearman or Pearson correlation with or without interquartile range). Our sample was tested versus a set of 250 well-characterized sarcomas (around 10 cases of each tumoral entity) and it clearly clustered

within the Extraskeletal Myxoid Chondrosarcoma group (Figure 2B). The second analysis used Uniform Manifold Approximation and Projection (UMAP) and a VAE model to infer classification of the tested sample into tumoral subtypes. Here again, the *LSM14::NR4A3* sample clustered within the EMC group and apart from Mesenchymal Chondrosarcoma and other control groups (Figure 2C). These analyses based on expression data show that the *LMS14::NR4A3* tumor belongs to the EMC group and shares their transcriptomic signature.

## 4 | DISCUSSION

This is the first report of a *LSM14A::NR4A3* fusion gene identified by whole-transcriptome sequencing in EMC. In our case, the histologic and immunohistochemical features of the tumor were consistent with a diagnosis of EMC. The overall architecture, myxoid stroma, and cellular features were highly suggestive. The immunophenotype was consistent with the diagnosis. As usual, most differentiation markers were undetectable, except for S100 protein, present in 20% of cases, and neuroendocrine markers, already described in previous studies.<sup>14,15</sup> However, the diagnosis was not definitively confirmed in the absence of *NR4A3* rearrangements detected in a first attempt by RT-qPCR, which prompted us to use a new technical approach.

Rearrangement of *NR4A3* has been found exclusively in EMC and is considered a hallmark of EMC according to the WHO.<sup>1</sup> Our findings, based on RNA sequencing, expand the molecular heterogeneity of EMC. In EMC, the major fusion partners of *NR4A3* described so far belong to *TET* family genes: *EWSR1* (over 70%), *TAF15* (about 20% of cases), and *FUS*.<sup>16</sup> Rarer *NR4A3* fusion partners (<5%) include transcription factors *TCF12* and *TFG*.<sup>16</sup> Recently, non-transcription factors such as *HSPA8* and *SMARCA2* have also been reported.<sup>8,9</sup>

The functional consequences and biological significance of variant fusions of EMC are still poorly defined. Recurrent t(9;22) or t(9;17) translocations result in fusions of the amino-terminal transactivation domains of *EWS* or *TAF15* to the entire *NR4A3* protein, which encode a more potent transcriptional activator than *NR4A3*.<sup>17,18</sup> Non-*TET* gene partners in EMC, such as *TCF12*, encoding a basic helix-loop-helix transcription factor; and *TFG*, encoding an RNA binding protein homologous to *EWSR1*, have N-terminal regions similar to *TET* genes and undergo similar N-terminal transposition and *NR4A3* activation.<sup>3,6</sup>

*LSM14A* (also called *RAP55*), a member of the *LSm* family of proteins, is a mRNA Processing Body Assembly Factor, involved in RNA processing in the processing bodies (P-bodies), which acts as a sensor for both viral RNA and DNA and mediates IRF3 activation and IFN- $\beta$  induction.<sup>19,20</sup> The *LSM14A::NR4A3* fusion identified in our case encoded for a chimeric protein with the whole coding sequence of *NR4A3* from exon 2 and exon 1–4 of *LSM14A* which includes the conserved N-terminal helix *LSM* domain (amino acids 1–76). This N-terminal domain does not mediate RNA binding but protein–protein interactions.<sup>21</sup> Like *EWS::NR4A3* or *TAF15::NR4A3*, the breakpoint location of *LSM14A::NR4A3* maintained reading frame and conserved the entire *NR4A3* protein including the DNA-binding domain. Recently, *LSM14A* has been identified as a novel partner of *RET* in a patient with

lung adenocarcinoma.<sup>22</sup> This fusion of *LSM14A::RET* included exons 1–9 of *LSM14A* and exons 12–20 of *RET* with the complete *RET* kinase domain, which might drive oncogenesis.<sup>22</sup> Similarities in translocation breakpoint in *LSM14A::NR4A3* with *TET* gene fusion variants in EMC and reported *LSM14A::RET* in lung adenocarcinoma might suggest that this novel fusion might encode a more potent transcriptional activator than *NR4A3* which might contribute to tumorigenesis.

Clinically, the patient with EMC harboring *LSM14A::NR4A3* fusion developed distant relapse, mainly in the lung, as usual in EMC, 29 months after the primary surgical R1 resection. The metastatic disease was rather indolent for 6 years. This contrasts with some histological features, such as increased cellularity, a feature described in high-grade tumors<sup>4</sup>; however, mitotic activity was low and there was no marked atypia or rhabdoid cell. The patient benefited from pazopanib with prolonged stable disease (>1 year), which reinforces the interest of this drug, as suggested in a recent prospective European phase II clinical trial.<sup>23</sup>

In conclusion, our findings expand the molecular spectrum of EMC, a very rare tumor characterized by diverse *NR4A3* fusion variants that might influence the clinical behavior of the tumor. Our case suggests that the newly described *LSM14A::NR4A3* fusion is associated with a rather indolent course; this contrasts with the fact that EMCs with variant non-*EWSR1* gene fusions are supposed to be associated with a more aggressive outcome than the *EWSR1-NR4A3*-positive tumors. Additional cases are needed to fully evaluate the frequency and the significance of this novel *LSM14A::NR4A3* rearrangement in EMC.

## CONFLICT OF INTEREST

The authors declare no potential conflict of interest.

## DATA AVAILABILITY STATEMENT

The data that support the findings of this study are available from the corresponding author upon reasonable request." cd\_value\_code="text

## ORCID

Carine Ngo  <https://orcid.org/0000-0002-8172-5876>

## REFERENCES

- International Agency for Research on Cancer. Soft Tissue and Bone Tumours. *WHO Classification of Tumours Editorial Board*. 5th ed. International Agency for Research on Cancer; 2020.
- Mohan HM, Aherne CM, Rogers AC, Baird AW, Winter DC, Murphy EP. Molecular pathways: the role of *NR4A* orphan nuclear receptors in cancer. *Clin Cancer Res*. 2012;18(12):3223–3228.
- Sjögren H, Meis-Kindblom J, Kindblom LG, Aman P, Stenman G. Fusion of the *EWS*-related gene *TAF2N* to *TEC* in extraskeletal myxoid chondrosarcoma. *Cancer Res*. 1999;59(20):5064–5067.
- Agaram NP, Zhang L, Sung YS, Singer S, Antonescu CR. Extraskeletal myxoid chondrosarcoma with non-*EWSR1-NR4A3* variant fusions correlate with rhabdoid phenotype and high-grade morphology. *Hum Pathol*. 2014;45(5):1084–1091.
- Sjögren H, Wedell B, Meis-Kindblom JM, Kindblom LG, Stenman G, Kindblom JM. Fusion of the NH2-terminal domain of the basic helix-loop-helix protein *TCF12* to *TEC* in extraskeletal myxoid chondrosarcoma with translocation t(9;15)(q22;q21). *Cancer Res*. 2000;60(24):6832–6835.

6. Hisaoka M, Ishida T, Imamura T, Hashimoto H. TFG is a novel fusion partner of NOR1 in extraskeletal myxoid chondrosarcoma. *Genes Chromosomes Cancer*. 2004;40(4):325-328.
7. Broehm CJ, Wu J, Gullapalli RR, Bocklage T. Extraskeletal myxoid chondrosarcoma with a t(9;16)(q22;p11.2) resulting in a NR4A3-FUS fusion. *Cancer Genet*. 2014;207(6):276-280.
8. Urbini M, Astolfi A, Pantaleo MA, et al. HSPA8 as a novel fusion partner of NR4A3 in extraskeletal myxoid chondrosarcoma: URBINI et al. *Genes Chromosomes Cancer*. 2017;56(7):582-586.
9. Wei S, Pei J, von Mehren M, Abraham JA, Patchefsky AS, Cooper HS. SMARCA2-NR4A3 is a novel fusion gene of extraskeletal myxoid chondrosarcoma identified by RNA next-generation sequencing. *Genes Chromosomes Cancer*. 2021;60(10):709-712.
10. Chiusole B, Le Cesne A, Rastrelli M, et al. Extraskeletal Myxoid chondrosarcoma: clinical and molecular characteristics and outcomes of patients treated at two institutions. *Front Oncol*. 2020;16(10):828.
11. Brenca M, Stacchiotti S, Fassetta K, et al. NR4A3 fusion proteins trigger an axon guidance switch that marks the difference between EWSR1 and TAF15 translocated extraskeletal myxoid chondrosarcomas. *J Pathol*. 2019;249(1):90-101.
12. Paioli A, Stacchiotti S, Campanacci D, et al. Extraskeletal Myxoid chondrosarcoma with molecularly confirmed diagnosis: a multicenter retrospective study within the Italian sarcoma group. *Ann Surg Oncol*. 2021;28(2):1142-1150.
13. Vibert J, Pierron G, Benoist C, et al. Identification of tissue of origin and guided therapeutic applications in cancers of unknown primary using deep learning and RNA sequencing (TransCUPtomics). *J Mol Diagn*. 2021;23(10):1380-1392.
14. Harris M, Coyne J, Tariq M, et al. Extraskeletal Myxoid chondrosarcoma with neuroendocrine differentiation: a pathologic, cytogenetic, and molecular study of a case with a novel translocation t(9;17)(q22;q11.2). *Am J Surg Pathol*. 2000;24(7):1020-1026.
15. Yoshida A, Makise N, Wakai S, Kawai A, Hiraoka N. INSM1 expression and its diagnostic significance in extraskeletal myxoid chondrosarcoma. *Mod Pathol*. 2018;31(5):744-752.
16. Stacchiotti S, Baldi GG, Morosi C, Gronchi A, Maestro R. Extraskeletal myxoid chondrosarcoma: state of the art and current research on biology and clinical management. *Cancer*. 2020;12(9):2703.
17. Labelle Y, Bussi eres J, Courjal F, Goldring MB. The EWS/TEC fusion protein encoded by the t(9;22) chromosomal translocation in human chondrosarcomas is a highly potent transcriptional activator. *Oncogene*. 1999;18(21):3303-3308.
18. Kim S, Lee HJ, Jun HJ, Kim J. The hTAFII68-TEC fusion protein functions as a strong transcriptional activator. *Int J Cancer*. 2008;122(11):2446-2453.
19. Yang WH, Yu JH, Gulick T, Bloch KD, Bloch DB. RNA-associated protein 55 (RAP55) localizes to mRNA processing bodies and stress granules. *RNA*. 2006;12(4):547-554.
20. Li Y, Chen R, Zhou Q, et al. LSM14A is a processing body-associated sensor of viral nucleic acids that initiates cellular antiviral response in the early phase of viral infection. *Proc Natl Acad Sci USA*. 2012;109(29):11770-11775.
21. Brandmann T, Fakim H, Padamsi Z, et al. Molecular architecture of LSM14 interactions involved in the assembly of mRNA silencing complexes. *EMBO J*. 2018;37(7):e97869.
22. Lv Y, Ling F, Zhang J, Xiao M, Mao W. A novel intergenic LSM14A-RET fusion variant in a patient with lung adenocarcinoma. *J Thorac Oncol*. 2020;15(4):e52-e53.
23. Stacchiotti S, Ferrari S, Redondo A, et al. Pazopanib for treatment of advanced extraskeletal myxoid chondrosarcoma: a multicentre, single-arm, phase 2 trial. *Lancet Oncol*. 2019;20(9):1252-1262.

**How to cite this article:** Ngo C, Verret B, Vibert J, et al. A novel fusion variant LSM14A::NR4A3 in extraskeletal myxoid chondrosarcoma. *Genes Chromosomes Cancer*. 2023;62(1):52-56. doi:10.1002/gcc.23090