



HAL
open science

Disseminated diffuse midline gliomas, H3K27-altered mimicking diffuse leptomeningeal glioneuronal tumors: a diagnostical challenge!

Arnault Tauziède-Espariat, Aurore Siegfried, Emmanuelle Uro-Coste, Yvan Nicaise, David Castel, Annick Sevely, Marion Gambart, Sergio Boetto, Lauren Hasty, Alice Métais, et al.

► To cite this version:

Arnault Tauziède-Espariat, Aurore Siegfried, Emmanuelle Uro-Coste, Yvan Nicaise, David Castel, et al.. Disseminated diffuse midline gliomas, H3K27-altered mimicking diffuse leptomeningeal glioneuronal tumors: a diagnostical challenge!. *Acta Neuropathologica Communications*, 2022, 10 (1), pp.119. 10.1186/s40478-022-01419-3 . hal-04493144

HAL Id: hal-04493144

<https://hal.science/hal-04493144v1>

Submitted on 7 Feb 2025

HAL is a multi-disciplinary open access archive for the deposit and dissemination of scientific research documents, whether they are published or not. The documents may come from teaching and research institutions in France or abroad, or from public or private research centers.

L'archive ouverte pluridisciplinaire **HAL**, est destinée au dépôt et à la diffusion de documents scientifiques de niveau recherche, publiés ou non, émanant des établissements d'enseignement et de recherche français ou étrangers, des laboratoires publics ou privés.



Distributed under a Creative Commons Attribution 4.0 International License

LETTER TO THE EDITOR

Open Access



Disseminated diffuse midline gliomas, H3K27-altered mimicking diffuse leptomeningeal glioneuronal tumors: a diagnostical challenge!

Arnault Tauziède-Espariat^{1,2*}, Aurore Siegfried^{3,4}, Emmanuelle Uro-Coste^{3,4}, Yvan Nicaise⁴, David Castel^{5,6}, Annick Sevely⁷, Marion Gambart⁸, Sergio Boetto⁹, Lauren Hasty¹, Alice Métais^{1,2}, Fabrice Chrétien^{1,2}, Joseph Benzakoun^{2,10}, Stéphanie Puget^{11,12}, Jacques Grill^{2,13}, Volodia Dangouloff-Ros¹⁴, Nathalie Boddaert¹⁴, Azadeh Ebrahimi¹⁵ and Pascale Varlet^{1,2} on behalf of the RENOCLIP-LOC Network

Diffuse midline gliomas (DMG) are divided into four subtypes depending on their molecular characteristics, and/or location: DMG, H3.3 K27-mutant; DMG, H3.1 or H3.2 K27—mutant; DMG, H3-wildtype, with EZHIP overexpression and DMG, *EGFR*-altered [1]. Leptomeningeal dissemination at diagnosis has been variably reported depending on the series (up to 42%) [2]. Very little genetic and epigenetic data is available for those disseminated cases, with one case harboring a concomitant *FGFR1* mutation [3] and another a 1p deletion [4]. Consequently, their relationship with diffuse leptomeningeal glioneuronal tumors (DLGNT), remains unclarified.

Herein, we describe the histopathological, neuro-radiological and molecular (including DNA-methylation profiling) features of three initially disseminated H3K27-altered tumors with glioneuronal features including two cases with an associated MAPK pathway alteration.

The cases concerned three females, aged 14, 13 and 40-year-old (see Additional file 1: Table S1). At the initial diagnosis, in all cases, the tumors were disseminated with supra-tentorial and infra-tentorial leptomeningeal

infiltration. An intraparenchymal mono-thalamic involvement was observed in cases 1 and 2; case 3 did not present any intraparenchymal involvement, until the end of the follow-up (Fig. 1). A leptomeningeal biopsy was performed in all cases. Histopathologically, all tumors presented a glioneuronal immunophenotype, and, one of them also had numerous microcalcifications (Fig. 2 and Additional file 2: Table S2). A 1p deletion was evidenced in case 1 and therefore a diagnosis of DLGNT was suggested (Fig. 2D). NGS sequencing showed a *FGFR1* N546K mutation (case 1), a *BRAF* V600E mutation (case 2) and a *H3F3A* K27M mutation (case 3). The DNA-methylation profiling classified cases 1 and 3 as DMG, H3K27-altered, subtype H3K27M/EZHIP overexpressing (calibrated scores 0.99 and 0.82 respectively) and case 2 as DMG H27K27-altered, subtype *EGFR*-altered (calibrated score 0.95) (Additional file 3: Fig. S1). Complementary analyses found a loss of H3K27me3 (in all cases), an EZHIP overexpression (cases 1 and 2) (Fig. 2), but no *EGFR* alteration (all exons were tested by whole exome sequencing, and an amplification was ruled out by FISH analyses) was evidenced. Case 1 received several lines of chemotherapy and craniospinal radiation therapy but passed away 16 months after the initial diagnosis, whereas the case 2, treated by chemotherapy and targeted anti-BRAF therapy, is still alive with a stable disease, 7 months after the initial diagnosis. The patient 3 received chemotherapy

*Correspondence: a.tauziede-espariat@ghu-paris.fr

¹ Department of Neuropathology, GHU Paris Psychiatrie Neurosciences, Sainte-Anne Hospital, 1, rue Cabanis, 75014 Paris, France
Full list of author information is available at the end of the article



© The Author(s) 2022. **Open Access** This article is licensed under a Creative Commons Attribution 4.0 International License, which permits use, sharing, adaptation, distribution and reproduction in any medium or format, as long as you give appropriate credit to the original author(s) and the source, provide a link to the Creative Commons licence, and indicate if changes were made. The images or other third party material in this article are included in the article's Creative Commons licence, unless indicated otherwise in a credit line to the material. If material is not included in the article's Creative Commons licence and your intended use is not permitted by statutory regulation or exceeds the permitted use, you will need to obtain permission directly from the copyright holder. To view a copy of this licence, visit <http://creativecommons.org/licenses/by/4.0/>. The Creative Commons Public Domain Dedication waiver (<http://creativecommons.org/publicdomain/zero/1.0/>) applies to the data made available in this article, unless otherwise stated in a credit line to the data.

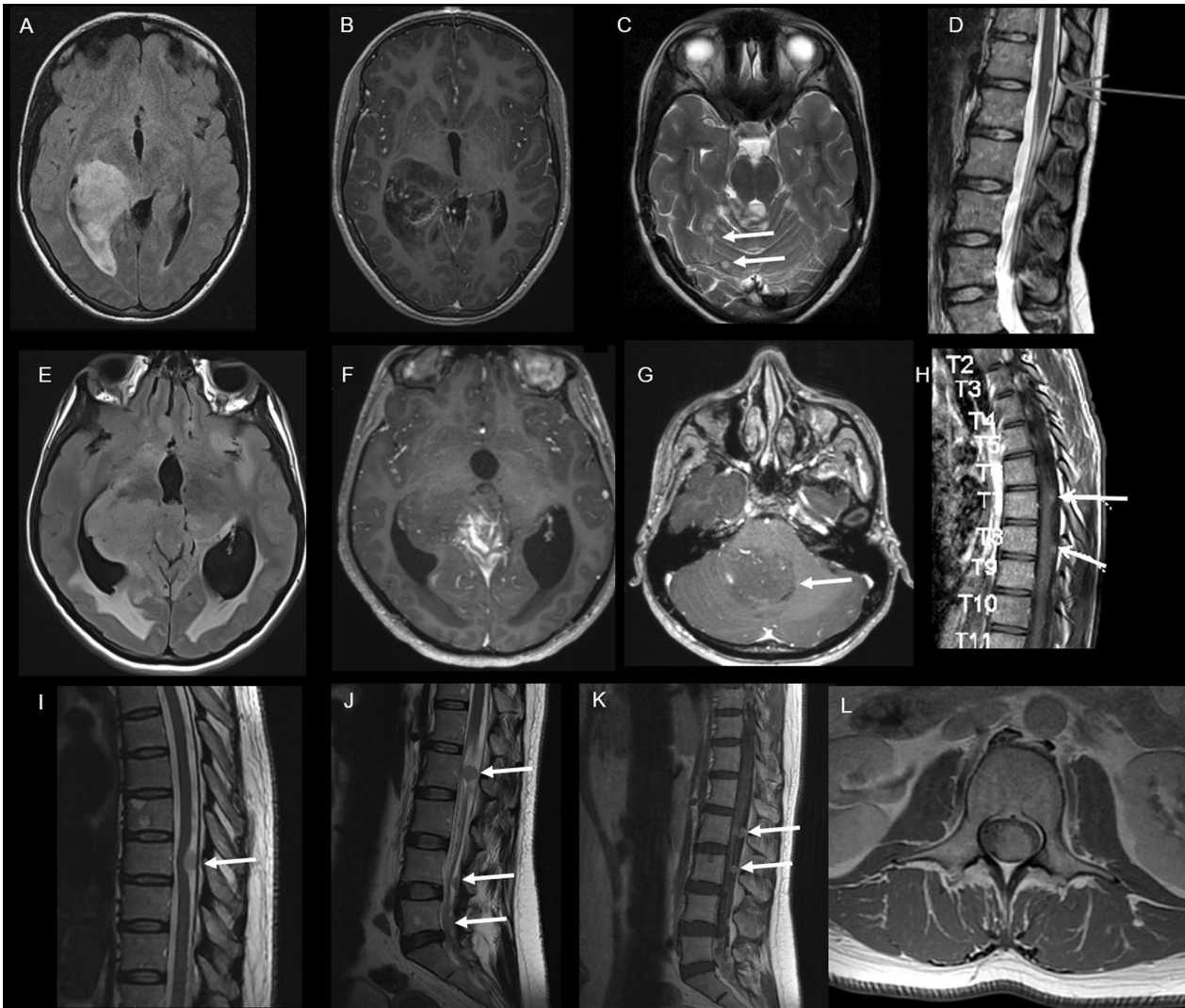


Fig. 1 Radiological features. Case #1 **A** Axial FLAIR brain MRI shows a hyperintense infiltrative lesion of the right thalamus extended to the right lateral ventricle. **B** Axial contrast-enhanced T1-weighted brain MRI shows a heterogeneous enhancement after gadolinium injection. **C** Axial T2-weighted brain MRI shows other nodular FLAIR hyperintensities of the cerebellum (arrows). **D** Sagittal T2-weighted spine MRI shows a hyperintense peripheral lesion of the spinal cord (arrow). Case #2 **E** Axial FLAIR-weighted brain MRI shows a hyperintense lesion of the right thalamus extended to the third ventricle and the right hippocampus. **F** Axial contrast-enhanced T1-weighted brain MRI shows a heterogeneous enhancement of this lesion. **G** Axial contrast-enhanced T1-weighted brain MRI shows an intraventricular localization in the fourth ventricle (arrow). **H** Sagittal contrast-enhanced T1-weighted spine MRI shows multiple spinal leptomeningeal lesions. Case #3 **I** Sagittal T2-weighted spine MRI shows a thoracic hyperintense leptomeningeal lesion. **J** Sagittal T2-weighted lumbar MRI shows multiple lumbar intradural lesions, attached to nerve roots and in the lower end of the dural sac. **K** Sagittal and **L** Axial contrast-enhanced T1-weighted lumbar MRI show an enhancement of these lesions. FLAIR: Fluid Attenuated Inversion Recovery

and craniospinal irradiation but died 4 months after the diagnosis.

DLGNTs are glioneuronal tumors molecularly defined by a chromosome arm 1p deletion and a MAPK pathway alterations [1]. Contrary to what their name suggest, they can present a parenchymal component, which can include a thalamic location, with or without leptomeningeal involvement [5]. The already published H3K27M-mutant cases

with a disseminated radiological presentation (including a case with a 1p deletion) raises the question of a potential overlap between DLGNT and DMG [3, 4, 6]. However, those cases did not have DNA-methylation analysis, and their relationship to DMG, H3 K27–altered remains open in the last version of the World Health Organization classification [1]. Herein, we present three initially disseminated leptomeningeal tumors, including one case with a 1p deletion

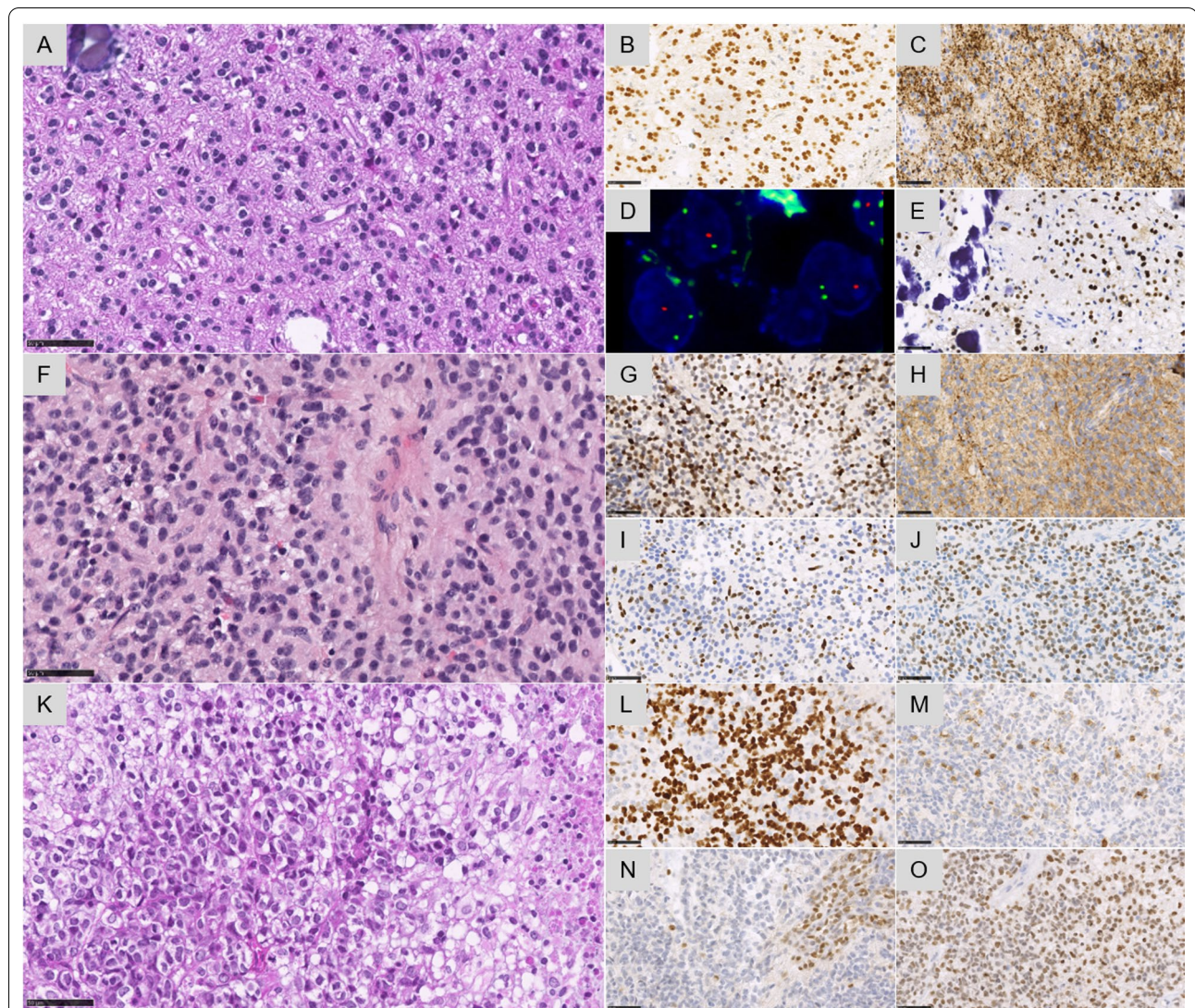


Fig. 2 Histopathological and molecular features. Case #1 **A** A glial proliferation with oligo-like features and one microcalcification (HPS, magnification $\times 400$). **B** Diffuse expression of Olig2 (magnification $\times 400$). **C** Diffuse synaptophysin immunoreactivity without true neuropil islands (magnification $\times 400$). **D** 1p deletion by FISH analysis (green signal for 1q25 and orange signal for 1p36, magnification $\times 400$). **E** EZHIP overexpression in all tumor cells (magnification $\times 400$). Case #2 **F** A glial proliferation with astrocytic features (magnification $\times 400$). **G** Diffuse expression of Olig2 (magnification $\times 400$). **H** Diffuse synaptophysin immunoreactivity without true neuropil islands (magnification $\times 400$). **I** Loss of the trimethylation H3K27me3 in tumor cells (magnification $\times 400$). **J** EZHIP overexpression in all tumor cells (magnification $\times 400$). Case #3 **K** A high-grade glial proliferation with several mitoses and necrosis (magnification $\times 400$). **L** Immunoreactivity for neurofilament in a subset of tumor cells (magnification $\times 400$). **N** Loss of the trimethylation H3K27me3 in tumor cells (magnification $\times 400$). **O** H3K27M immunopositivity in all tumor cells (magnification $\times 400$). Black scale bars represent 50 μm

and two with *BRAF/FGFR1* mutations, classified as DMG using DNA-methylation profiling. Like patients with DMG-H3K27 mutant with concomitant *BRAF* or *FGFR1* mutation, the two current disseminated cases H3K27-altered (one with EZHIP overexpression) with a MAPK mutation were older than classical DMG and histologically presented a glioneuronal immunophenotype and /or microcalcifications [7, 8]. The case 2, classified as DMG, H3K27-altered (*EGFR*-mutant) proven by DNA-methylation analysis,

represents the first example of a disseminated presentation of this typically bithalamic tumor type [9]. Another particularity of this case was its having a *BRAF* V600E mutation without an *EGFR* alteration (as 20%, 8/40 of all published cases), representing the second example of this discrepancy between genetic and epigenetic results (the first being reported as unilateral thalamic) [9]. Gliomas with concomitant mutations of H3K27M and *BRAF/FGFR1* are supposed to be associated with a better prognosis than other DMG,

H3K27-altered according to some publications [7, 8]. As a result, it can be suggested that these molecular alterations (MAPK and H3K27M/EZHIP alterations) confer a different biological behavior, with a metastatic phenotype and/ or a slower local progression ultimately allowing the development of disseminated lesions. Arguing for this hypothesis, a previously published monothalamic tumor classified as ganglioglioma, H3K27M- and *BRAF* V600E-mutant presented secondary leptomeningeal dissemination 7 years after the initial diagnosis [10]. Further data is needed to understand this disseminated phenotype in detail.

In summary, we showed that despite the histopathological and molecular overlaps with DLGNT, DMG, H3K27-altered may be found to have, in exceptional cases, an initial disseminated radiological presentation.

Supplementary Information

The online version contains supplementary material available at <https://doi.org/10.1186/s40478-022-01419-3>.

Additional file 1. Table S1: Summary of clinical data of cases from current series.

Additional file 2. Table S2: Summary of histopathological and molecular data of cases from current series.

Additional file 3: Fig. S1. Methylation-based t-SNE distribution. t-distributed stochastic neighbor embedding (t-SNE) analysis of DNA methylation profiles from the investigated tumors alongside selected reference samples. Reference DNA methylation classes: diffuse midline glioma H3 K27M mutant/EZHIP overexpressing (DMG_K27), diffuse midline glioma *EGFR* altered (DMG_EGFR), glioblastoma, *IDH* wildtype, H3.3 G34 mutant (GBM_G34), pediatric glioblastoma, *IDH* wildtype, subclass *MYCN* (GBM_pedMYCN), glioblastoma, *IDH* wildtype, subclass RTK1 (GBM_RTK1), glioblastoma, *IDH* wildtype, subclass RTK2 (GBM_RTK2), pediatric glioblastoma, *IDH* wildtype, subclass RTK1 (GBM_pedRTK1), pediatric glioblastoma, *IDH* wildtype, subclass RTK2 (GBM_pedRTK2), glioblastoma, *IDH* wildtype, subclass mesenchymal (GBM_MES), diffuse leptomeningeal glioneuronal tumor, subtype 1 (DLGNT_1), and diffuse leptomeningeal glioneuronal tumor, subtype 2 (DLGNT_2).

Acknowledgements

We would like to thank the laboratory technicians at the GHU Paris Neuro Sainte-Anne for their assistance, as well as the Integragen platform for their help with DNA-methylation analyses and the RENOCLIP-LOC Network. RENOCLIP-LOC is the clinico-pathological network instrumental in the central histopathological review supported by the Institut National du Cancer (INCa). We would like to Philipp Sievers from Heidelberg to perform the t-SNE analysis.

Author contributions

ATE, AS, MG, SB, JB, P, JG, VDR and NB compiled the MRI and clinical records; ATE, AS, EUC, AM, FC, AE and PV conducted the neuropathological examinations; ATE, AS, EUC, YN, DC and PV conducted the molecular studies; ATE, AE, LH and PV drafted the manuscript; all authors reviewed the manuscript.

Funding

The authors declare that they have not received any funding.

Declarations

Competing interests

The authors declare that they have no conflict of interest directly related to the topic of this article.

Author details

¹Department of Neuropathology, GHU Paris Psychiatrie Neurosciences, Sainte-Anne Hospital, 1, rue Cabanis, 75014 Paris, France. ²Paris University France, 75006 Paris, France. ³Department of Pathology, Toulouse University Hospital, 31300 Toulouse, France. ⁴Cancer Research Center of Toulouse (CRCT), INSERM U1037, Toulouse, France. ⁵U981, Molecular Predictors and New Targets in Oncology, INSERM, Gustave Roussy, Université Paris-Saclay, 94805 Villejuif, France. ⁶Univ. Evry, Université Paris-Saclay, 91000 Evry, France. ⁷Department of Radiology, Purpan University Hospital, 31300 Toulouse, France. ⁸Department of Pediatric Oncology, Toulouse University Hospital, 31300 Toulouse, France. ⁹Department of Neurosurgery, Toulouse University Hospital, 31300 Toulouse, France. ¹⁰Department of Radiology, GHU Paris-Psychiatrie et Neurosciences, Sainte-Anne Hospital, Paris, France. ¹¹Department of Pediatric Neurosurgery, Necker Hospital, APHP, Université Paris Descartes, Sorbonne Paris Cité, 75015 Paris, France. ¹²Department of Neurosurgery, CHU de Fort de France, Université Des Antilles, Paris, France. ¹³Department of Pediatric Oncology, Gustave Roussy, Université Paris-Saclay, 94805 Villejuif, France. ¹⁴Pediatric Radiology Department, Hôpital Necker Enfants Malades, AP-HP, Institut Imagine INSERM U1163 and U1299, 75015, Université Paris Cité, Paris, France. ¹⁵Institute of Neuropathology, University of Bonn, Venusberg Campus 1, 53127 Bonn, Germany.

Received: 4 July 2022 Accepted: 4 August 2022

Published online: 19 August 2022

References

- Louis DN, Perry A, Wesseling P, Brat DJ, Cree IA, Figarella-Branger D et al (2021) The 2021 WHO Classification of Tumors of the Central Nervous System: a summary. *Neuro Oncol* 23:1231–1251
- Rodriguez D, Calmon R, Aliaga ES, Warren D, Warmuth-Metz M, Jones C et al (2022) MRI and molecular characterization of pediatric high-grade midline thalamic gliomas: the HERBY phase II trial. *Radiology* 304:174–182
- Dyson K, Rivera-Zengotita M, Kresak J, Weaver K, Stover B, Fort J et al (2016) FGFR1 N546K and H3F3A K27M mutations in a diffuse leptomeningeal tumour with glial and neuronal markers. *Histopathology* 69:704–707
- Nambirajan A, Suri V, Kedia S, Goyal K, Malgulkar PB, Khanna G et al (2018) Paediatric diffuse leptomeningeal tumor with glial and neuronal differentiation harbouring chromosome 1p/19q co-deletion and H3.3 K27M mutation: unusual molecular profile and its therapeutic implications. *Brain Tumor Pathol* 35:186–191
- Deng MY, Sill M, Chiang J, Schittenhelm J, Ebinger M, Schuhmann MU et al (2018) Molecularly defined diffuse leptomeningeal glioneuronal tumor (DLGNT) comprises two subgroups with distinct clinical and genetic features. *Acta Neuropathol (Berl)* 136:239–253
- Navarro RE, Golub D, Hill T, McQuinn MW, William C, Zagzag D et al (2021) Pediatric midline H3K27M-mutant tumor with disseminated leptomeningeal disease and glioneuronal features: case report and literature review. *Childs Nerv Syst ChNS Off J Int Soc Pediatr Neurosurg* 37:2347–2356
- Schüller U, Iglauer P, Dorostkar MM, Mawrin C, Herms J, Giese A et al (2021) Mutations within FGFR1 are associated with superior outcome in a series of 83 diffuse midline gliomas with H3F3A K27M mutations. *Acta Neuropathol (Berl)* 141:323–325
- Nakano Y, Yamasaki K, Sakamoto H, Matsusaka Y, Kunihiro N, Fukushima H et al (2019) A long-term survivor of pediatric midline glioma with H3F3A K27M and BRAF V600E double mutations. *Brain Tumor Pathol* 36:162–168
- Sievers P, Sill M, Schimpf D, Stichel D, Reuss DE, Sturm D et al (2021) A subset of pediatric-type thalamic gliomas share a distinct DNA methylation profile, H3K27me3 loss and frequent alteration of EGFR. *Neuro Oncol* 23:34–43
- Joyon N, Tauziède-Espariat A, Alentorn A, Giry M, Castel D, Capelle L et al (2017) K27M mutation in H3F3A in ganglioglioma grade I with spontaneous malignant transformation extends the histopathological spectrum of the histone H3 oncogenic pathway. *Neuropathol Appl Neurobiol* 43:271–276

Publisher's Note

Springer Nature remains neutral with regard to jurisdictional claims in published maps and institutional affiliations.