



HAL
open science

Post Partum Necrotizing Fasciitis: A Cases Study

M Benkhaldoun, A. Elyoussfi, M Habla, H Benaguida, S Karti, S Sabur, A El
Harti, M Diouri

► **To cite this version:**

M Benkhaldoun, A. Elyoussfi, M Habla, H Benaguida, S Karti, et al.. Post Partum Necrotizing Fasciitis: A Cases Study. Asian journal of case reports in surgery, 2024, 7 (1), pp.120-125. hal-04491186

HAL Id: hal-04491186

<https://hal.science/hal-04491186>

Submitted on 5 Mar 2024

HAL is a multi-disciplinary open access archive for the deposit and dissemination of scientific research documents, whether they are published or not. The documents may come from teaching and research institutions in France or abroad, or from public or private research centers.

L'archive ouverte pluridisciplinaire **HAL**, est destinée au dépôt et à la diffusion de documents scientifiques de niveau recherche, publiés ou non, émanant des établissements d'enseignement et de recherche français ou étrangers, des laboratoires publics ou privés.



Post Partum Necrotizing Fasciitis: A Cases Study

M. Benkhaldoun ^{a*}, M. Habla ^a, H. Benaguida ^b,
A. Elyoussfi ^a, S. Karti ^a, S. Sabur ^a, A. El Harti ^a
and M. Diouri ^a

^a Plastic Surgery Department, National Burn Center, Morocco.

^b Maternity and Gyneco-Obstetrics Service, El Harrouchi Hospital, CHU Ibn Rochd,
Casablanca Hassan II University, Morocco.

Authors' contributions

This work was carried out in collaboration among all authors. All authors read and approved the final manuscript.

Article Information

Open Peer Review History:

This journal follows the Advanced Open Peer Review policy. Identity of the Reviewers, Editor(s) and additional Reviewers, peer review comments, different versions of the manuscript, comments of the editors, etc are available here: <https://www.sdiarticle5.com/review-history/113899>

Case Study

Received: 22/12/2023

Accepted: 29/02/2024

Published: 04/03/2024

ABSTRACT

Necrotizing fasciitis is an uncommon and life-threatening soft tissue infection caused by pathogenic bacteria that spread rapidly along the fascia and produce enzymes and toxins that destroy soft tissues, the absence of pathognomonic symptoms makes its diagnosis difficult. Rapidly progressive, it is a life-threatening emergency with a fatal prognosis in 30% of cases. The treatment is mixed and combines aggressive surgical debridement with medical treatment based on antibiotics. This article covers three cases of women who developed necrotizing fasciitis of the abdominal wall, two following a cesarean section and one having a vaginal delivery with disjunction of the pubic symphysis. Surgical treatment took place before septic shock in all three patients; one death occurred in this case study.

Keywords: Septic shock; hypodermatitis; necrotizing fasciitis; life-threatening.

*Corresponding author: E-mail: Docmedbenkhaldoun@gmail.com;

1. INTRODUCTION

Necrotizing fasciitis is an uncommon and life-threatening soft tissue infection caused by pathogenic bacteria that spread rapidly along the fascia and produce enzymes and toxins that destroy soft tissues [1], surgery and trauma are common etiologies and are not no matter what anatomical area can be affected. Predisposing factors include diabetes, malnutrition, renal failure and immunosuppression [2]

2. PATIENTS AND METHODS

2.1 Patients

We report over a period of two years from the beginning of 2022 to the end of 2023 the cases of three patients, of young age, two patients having given birth by cesarean section and one by vaginal delivery with disjunction of the pubic symphysis, having developed a few days later an infectious syndrome with skin signs at the level of the abdominal wall for which our plastic surgery opinion was requested, so we intervened urgently for the diagnosis which was clinically obvious in the face of necrosis and skin ulceration due to the delay in consultation.

- The first patient is a 38 year old obese woman (BMI 34kg/m²) second procedure second parity, type 2 diabetic under treatment for 10 years and operated for appendicitis at the age of 14, was readmitted eight days after her cesarean section for infection of the abdominal wall (Fig. 1a) declared 5 days after the cesarean section, the examination found a conscious patient in clinical sepsis, general condition was maintained, she presented a leukocytosis of 15,000 e/ml and a CRP of 405 mg/L a fasting blood sugar level of 1.9g/dL, the abdominal CT performed in the absence of the MRI reveals a significant infiltration of the subcutaneous cellulose-fatty tissue of the rectus and oblique muscles of the anterior abdominal wall with the presence of gas bubbles and extensive infiltration up to the suprapubic fossa, imaging very suggestive of necrotizing fasciitis (Fig. 1b)
- The second patient, aged 35, known to be type 2 diabetic on insulin for 5 years, presented 7 days postpartum after a cesarean section for infection of the abdominal wall and disunion of the approach. The clinical examination found a

conscious, febrile patient with 39C stable on the hemodynamic and respiratory level, presenting septic necrosis of the suprapubic abdominal wall

and disunity of the pfananstiel incision (Fig. 2a) with the release of pus and exudate, gynaecological examination with speculum reveals fetid leukorrhoea which was taken, the assessment showed leukocytosis at 13,200 e/mL, CRP at 360 mg/L normal renal function and transaminases, the CT scan showed necrotizing fasciitis with pelvic peritonitis, laparotomy, debridement and debridement were carried out with abundant peritoneal washing. (Fig. 2b and 2c)

- The third patient, aged 40, primiparous primigravida, neither diabetic nor hypertensive, having given birth vaginally at home in difficult conditions with abdominal expression, leading to pubic disjunction, the patient consulted later for skin necrosis at the pubic level with extreme pain, The clinical examination found a conscious patient febrile at 38.5 C and presented necrosis and ulceration of the pubic skin with a dirty and exudative base with pus and necrotic flow (Fig. 3a), the speculum examination noted a wound on the level of the small right lower lip communicating with the pubic ulcerations, in the assessment we noted a leukocytosis at 28960 e/mL a CRP at 252 mg/L the abdominopelvic scanner strongly suspected a FN on hematoma of the rectus abdominis with disjunction of the pubic symphysis (Fig. 3b) whose opinion from the traumatologist had indicated strict rest with analgesics and thromboprophylaxis

2.2 Methods

On admission, the patients were examined by the gynaecologist, the intensivist and the plastic surgeon then they had biological assessments based on blood count and platelets CRP, blood sugar and renal function, bacteriological samples of pus and setosity with an abdominopelvic scanner.

Probabilistic antibiotic therapy based on triaxon gentamycin and metronidazole was immediately started on admission given the clinical sepsis and the clinical appearance of necrosis very suggestive of necrotizing fasciitis at this stage in the three patients.

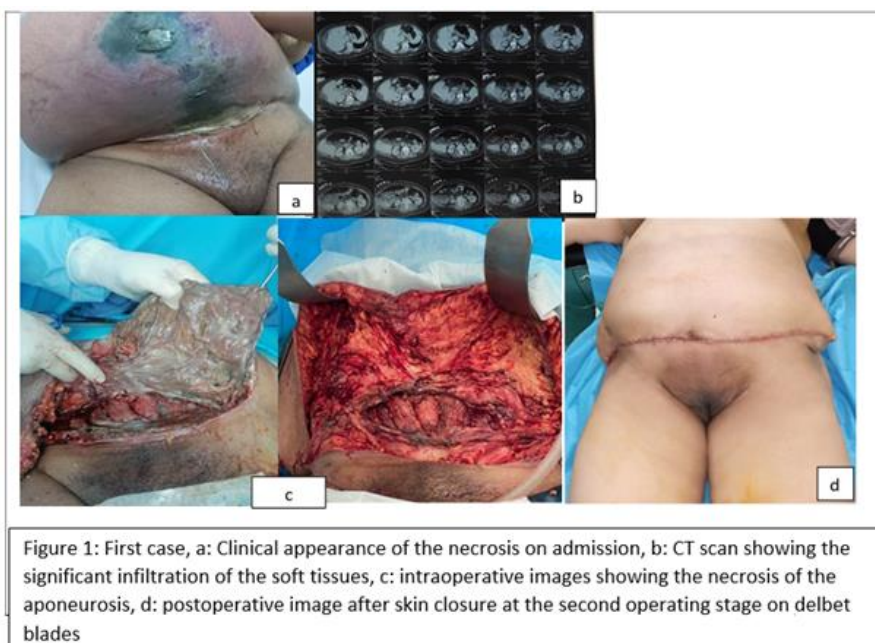
Then the patients were urgently admitted to the operating room after the abdominopelvic scan, the surgical procedure consisted of carrying out an aggressive debridement of the necrotic and infected tissue by starting the incision around the skin necrosis then dissection up to the healthy tissue and excision of all the necrosis at this level, in the three cases the aponeurosis was necrotic and therefore removed by debridement, the procedure is completed by abundant washing with a mixture of physiological serum, povidone-iodine solution and hydrogen peroxide.

Additional operations were carried out on the patients in the following days with care most often daily until the infection and necrosis were controlled and then finally the repair or closure on a Delbet blade or Redon drain of the airway. first is carried out depending on the cases.

3. RESULTS

During surgical exploration in the first patient, we noted a significant subcutaneous detachment filled with flows of necrosis and pus reaching the aponeurosis of the two rectus abdominis which was necrotic and had to be resected (Fig. 1c), Postoperatively, the general condition in intensive care was good. She then undergoes two other debridement operations before we proceed to close the skin with an abdominoplasty (Fig. 1d), the reconstruction by prosthesis could not be done at the same time as the closure because of the septic terrain so another time of parietal reconstruction by prosthesis is planned. The bacteriological samples were polymicrobial

- In the second patient we noted cutaneous and subcutaneous necrosis at the sub umbilical level also taking the aponeurosis at this level under the arcuate line (Fig. 2c), after laparotomy and pelvic peritoneal washing and good cutaneous and aponeurotic debridement (Fig. 2c) we performed a mini-abdominoplasty to close the wall (Fig. 2d), the postoperative aftermath was without problems except for exudates through the stitches, the responsible germ isolated was a hemolytic streptococcus b from group A
- In the third patient, the pubic lesions reached the rectus abdominis and pyramidal muscles with total lysis of the aponeurosis at this level, leaving a 2cm hole (Fig. 3c) between the two rectus abdominis muscles, exposing the peritoneum; debridement took place. to the subcutaneous tissue at the level of the labia majora and the mons pubis, two other operating stages were necessary before controlling the infection and the cutaneous and subcutaneous necrosis and being able to close in two planes on a Redon drain (Fig. 3d), the evolution was correct then the patient was declared discharged from the service after two weeks under antibiotic therapy and thromboprophylaxis and analgesia, but she was readmitted a few days later to intensive care for pulmonary embolism and unfortunately died as a result.



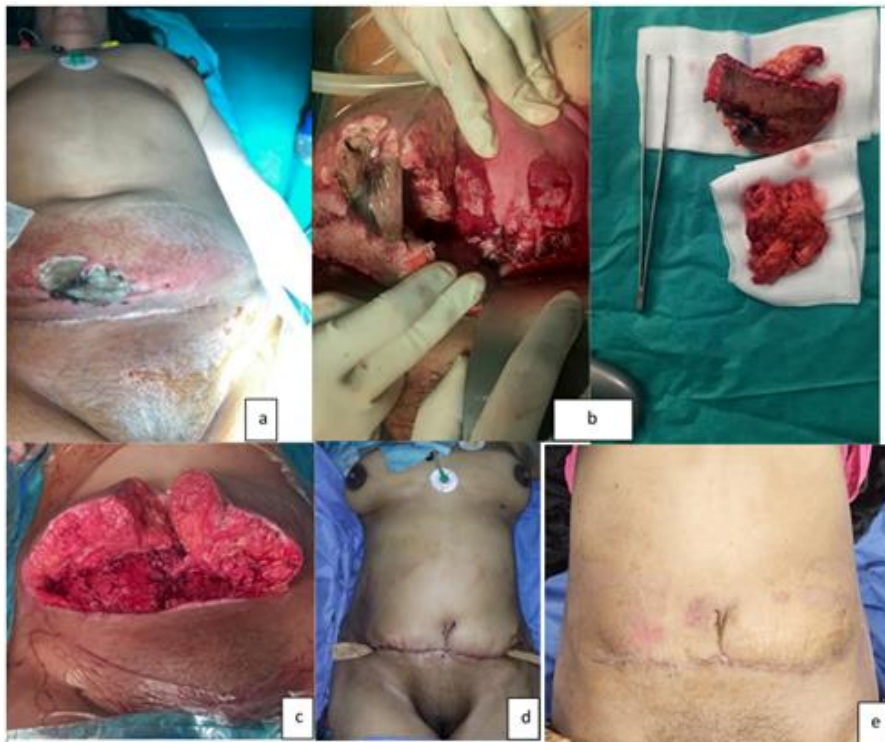


Figure 2: second case of necrotizing fasciitis associated with pelviperitonitis, a: clinical appearance on admission, b: after laparotomy we note the uterus and necrosis of the abdominal wall on both sides, and debridement product, c: after trimming the subcutaneous skin tissues and aponeurosis. d: skin closure on delbet blade. e: result after 2 months

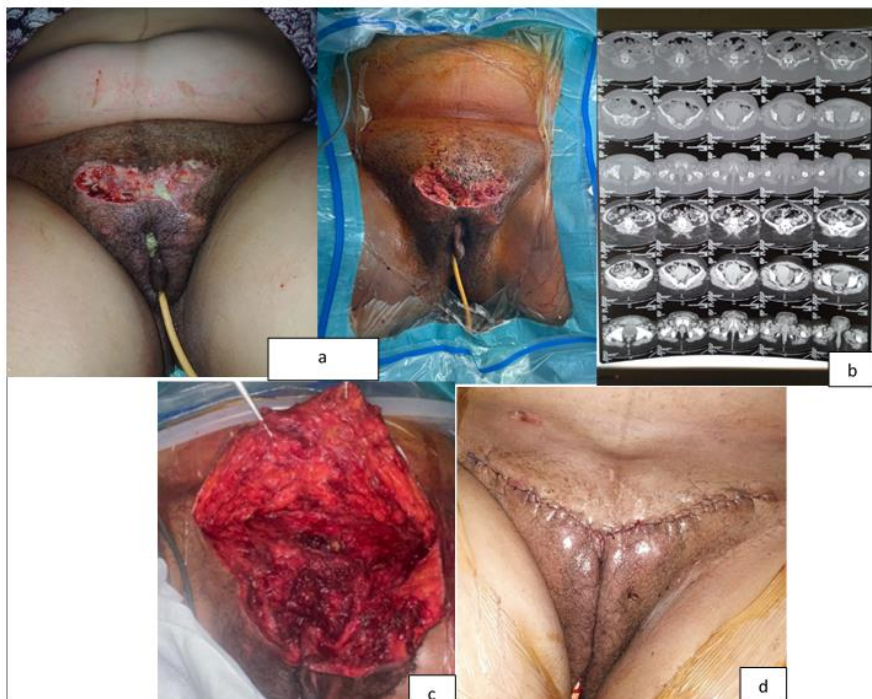


Figure 3: Third patient. a: Preoperative images. b: abdominopelvic scan. c: image after trimming, note the suprapubic opening between the two rectus major muscles. d: skin closure in the third operating stage

4. DISCUSSION

Necrotizing fasciitis (NF), commonly referred to by laypeople as “flesh-eating disease” or “flesh-eating bacteria,” is a rare, rapidly progressing, and often fatal infection that requires early and aggressive surgical debridement. Surgery and trauma are common etiologies and any anatomical area can be affected. Predisposing factors include diabetes mellitus, malnutrition, renal failure and immunosuppression [2]

Rapidly progressive and fatal, mortality can be up to 30%[3].

Necrotizing fasciitis is classified according to the causative microbial agent: type 1, polymicrobial (80% of cases), type 2, mono bacterial (mainly group A hemolytic streptococcus, 20% of cases) and types 3 and 4 (respectively gram bacilli negative and fungal germs)[4]

The most common local signs include extremely painful swelling, redness and heat. The skin appears indurated and cardboard. A discrepancy between the less worrying appearance of the lesion and the extreme pain felt by the patient can be a warning sign [4], a high fever is present in 80 to 90% of cases [5]

The infection spreads along the deep fascia via the vascular and lymphatic networks, causing thrombosis of the vessels. Skin cyanosis then develops rapidly, followed by the appearance of bubbles and ulcerations, evidence of necrosis [6]. Septic shock sets in suddenly in 50% of cases [4]

Due to its rarity, few epidemiological data are available to evaluate the number of necrotizing fasciitis associated with pregnancy. Goepfert reports 1.8 cases of necrotizing fasciitis per 1,000 cesarean sections [7]. Furthermore, Out et al. reported an increase of 1 to 4 cases of necrotizing fasciitis per 100,000 pregnant patients hospitalized in Texas between 2001 and 2010 [8]. This increase in incidence could be explained by an overdiagnosis of necrotizing fasciitis in cases of severe soft tissue infections and by contributing comorbidity factors such as obesity and diabetes, in addition to these, Hormonal changes of pregnancy affect the maternal immune system (decreased activity of Natural Killer cells, inflammatory response of macrophages and T lymphocytes, production of inflammatory cytokines, etc.) in such a way that

the development of infections and severe sepsis is favored [9],[10].

The clinical diagnosis is often difficult, which is observed in other series [2],[4] unlike ours, the diagnosis was already strongly suspected in the clinic given the necrosis immediately present at the consultation in the three patients of because of the delayed deadline

The main etiologies of necrotizing fasciitis are either surgery, in this case in this series, a cesarean section in our first two patients, several other series have reported this fact [2],[4] or traumatic etiologies which is the case for the third patient whose cause was a superinfected rectus muscular hematoma caused by childbirth in difficult conditions at home with expression maneuvers resulting in a disjunction of the pubic symphysis rarely reported associated with necrotizing fasciitis, in fact, a only case of necrotizing fasciitis associated with a disjunction of the pubic symphysis was reported by Athanassopoulos et al in their series[2]

Diabetes and obesity present in our first two patients are recognized as contributing factors and poor prognosis in terms of progression and survival found at high prevalence in the series by Donald G et al. [11] in 97.1% and 86.9% respectively

The mortality rate reported in the series by Donald et al [10] was 13% and can be up to 30% according to Roujeau [3], in our series death occurred in only one case and n It was not directly linked to necrotizing fasciitis but rather to pulmonary embolism.

5. CONCLUSION

Necrotizing fasciitis, a serious infection of the skin and subcutaneous tissues remains rare but formidable on the one hand because of the lesions it causes and on the other hand, especially because of the sepsis and septic shock for which it is responsible, with a mortality rate which remains high. , hence the interest in early diagnosis at the slightest clinical doubt of synergistic bactericidal antibiotic therapy, appropriate resuscitation measures in the event of septic shock and the most extensive debridement and debridement possible, without forgetting the aspect of prevention through good control of surgical asepsis, monitoring and control of contributing factors such as diabetes, obesity, and postoperative care.

CONSENT

As per international standards or university standards, patient(s) written consent has been collected and preserved by the author(s).

ETHICAL APPROVAL

As per international standards or university standards written ethical approval has been collected and preserved by the author(s).

COMPETING INTERESTS

Authors have declared that no competing interests exist.

REFERENCES

1. Rami A Eleiba, Mohamed Ali Eleiba. A Combined approach of surgery and negative pressure wound therapy in post intramuscular injection necrotizing fasciitis: A case report. Atlantic J Med Sci Res. 2023;3(3).
2. Anastasios Athanassopoulos, Terry Creagh, William McMillan Necrotizing fasciitis after the postpartum diastasis of the symphysis pubis. The New Zealand Medical Journal. 2006;119(1247). ISSN 1175 8716 February
3. Roujeau JC. Hypodermatitis and necrotizing fasciitis: Clinical reviews and risk factors. Medicine and Infectious Diseases. 2000;30:399-405.
4. Barant S, Radbata D, Oberweis D, Jacobs D, Marecaux G, Zielonka E, Maréchal M. Abdominal necrotizing fasciitis after caesarean delivery¹ Gynecology Department, Erasmus Hospital, 2Gynecology Department, 3Anesthesia and Intensive Care Department , 4Intensive Care Department, 5Plastic Surgery Department, André Vésale Hospital, 6Gynecology Department, Marie Curie Hospital of Charleroi, Rev Med Brux; 2016.
5. Krieg A, Röhrborn A, Schulte J et al. Necrotizing fasciitis: Microbiological characteristics and predictors of postoperative outcome. Eur J Med Res. 2009;14:30-6.
6. Dennis L, Eugene B, Anthony F et al. Harrison's principles of internal medicine 16th edition. 2009;740-5.
7. Goepfert A, Guinn D, Andrews W et al. Necrotizing fasciitis after cesarean delivery. Obstet Gynecol. 1997;89:409-12.
8. Out L, Watkins P. Necrotizing Fasciitis Associated with Pregnancy. A Population-Based Cohort Study. Infectious diseases and therapy. 2014;3:307-20.
9. Robinson DP, Klein SL. Pregnancy and pregnancy-associated hormones alter immune responses and disease pathogenesis. Horm Behav. 2012;62:263-71.
10. Robin M, Suditi R, Arpana D et al. Necrotizing fasciitis. A rare complication following common obstetric operative procedures: report of two cases. Int J Womens Health. 2015;7:357-60.
11. Donald G Gallup MD, a Murray A Freedman, MD, b Ramon V Meguiar, MD a Sandra N Freedman, MD b, Thomas E Nolan, MD b. Necrotizing fasciitis in gynecologic and obstetric patients: A surgical emergency . Savannah and Augusta, Ga. August Am J Obstet Gynecol; 2002.

© Copyright (2024): Author(s). The licensee is the journal publisher. This is an Open Access article distributed under the terms of the Creative Commons Attribution License (<http://creativecommons.org/licenses/by/4.0>), which permits unrestricted use, distribution, and reproduction in any medium, provided the original work is properly cited.

Peer-review history:

The peer review history for this paper can be accessed here:
<https://www.sdiarticle5.com/review-history/113899>