



HAL
open science

Transosseous Fixation with Suspensory Fixation System on Medial Meniscus Root Tears

Ahmet Emre Paksoy, Gunes Sarikaya, Mehmet Kose, Matthieu Ollivier, Baris
Kocaoglu

► **To cite this version:**

Ahmet Emre Paksoy, Gunes Sarikaya, Mehmet Kose, Matthieu Ollivier, Baris Kocaoglu. Transosseous Fixation with Suspensory Fixation System on Medial Meniscus Root Tears. *Arthroscopy Techniques*, 2023, 12 (11), pp.e1979-e1984. 10.1016/j.eats.2023.07.016 . hal-04490689

HAL Id: hal-04490689

<https://hal.science/hal-04490689>

Submitted on 5 Mar 2024

HAL is a multi-disciplinary open access archive for the deposit and dissemination of scientific research documents, whether they are published or not. The documents may come from teaching and research institutions in France or abroad, or from public or private research centers.

L'archive ouverte pluridisciplinaire **HAL**, est destinée au dépôt et à la diffusion de documents scientifiques de niveau recherche, publiés ou non, émanant des établissements d'enseignement et de recherche français ou étrangers, des laboratoires publics ou privés.

Transosseous Fixation with Suspensory Fixation System on Medial Meniscus Root Tears

Ahmet Emre Paksoy, M.D., Gunes Sarikaya, M.D., Mehmet Kose, M.D.,
Matthieu Ollivier, M.D., and Baris Kocaoglu, M.D.

Abstract: Medial meniscal root injury is known to cause an increase in the tibiofemoral contact pressure and results in early osteoarthritis. Several techniques have been described for transosseous suture repair. Typically, the sutures are passed through the meniscus, pulled out through a transtibial tunnel, and tied over a bone bridge, a suture button, or a screw at the anterior tibial cortex. Desired meniscus root tension may not be achieved in transosseous fixation with a suture button. The suspensory fixation technique is aimed to prevent secondary looseness in the knot attached to the button implant in the tibia and to provide the desired tension in the fixation of the button implant in different degrees of flexion of the knee.

Meniscal root tear (MRT) is defined as an avulsion of the meniscus root from where it attaches to the bone or a tear at a distance of 1 cm from the attachment site.^{1,2} With root tears, meniscal extrusion often occurs, and the transmission of circumferential hoop stresses is impaired. This alters knee biomechanics and kinematics and significantly increases tibiofemoral contact pressure.³ This event leads to a biomechanically similar situation to total meniscectomy.¹

When root tears develop, the menisci are extruded. It is considered significant that this extrusion is more than

3 mm in coronal section MRI.^{4,5} Various surgical treatment modalities have been described in the literature for medial meniscus posterior root tears. These are known as the transosseous suture and suture anchor methods.

The transtibial pullout method, which is one of the most commonly used methods, has its shortcomings that need improvement.^{6,7} These are the increase in meniscus extrusion in the MRI taken during the post-operative follow-ups, the difficulties in tying the knot at the desired tension on the button implant after the locked loop sutures placed on the meniscus root during the surgery, which are taken out from the tibial tunnel, and so in reaching the desired tension when it is seen that sufficient tension cannot be achieved in the arthroscopic control after the knotting of the button implant. The suspensory fixation technique aims to prevent secondary looseness in the knot attached to the suture button in the tibia and to adjust the desired tension in fixing the knee to the suture button at different degrees of flexion.

Pearls and pitfalls and advantages and limitations of the procedure are further described in [Tables 1](#) and [2](#).

Surgical Technique

Surgical Setup and Preoperative Evaluation

The patient is placed in the supine position with a nonsterile tourniquet on the operative thigh. A lateral post is used to allow for valgus stress. The lower extremity is prepped and draped in standard fashion.

Table 1. Summary of Pearls and Pitfalls

Pearls	Pitfalls
Semiextended knee positioning with an assistant controlling the valgus force in order to open the medial joint compartment.	Not enough medial joint compartment working space
Using a needle pie-crusting technique to release some part of the medial collateral ligament in the tight medial compartment knee.	Patient needs to understand reasons for cautious rehabilitation.
The suspensory fixation system should be adjusted 2 cm more than the calculated tibial tunnel length.	If the suspensory fixation system is set longer than calculated, the meniscus root cannot be brought to proper tension.
Free ends of meniscus loop stitches should be knotted into the suspensory fixation system loop.	

Table 2. Advantages and Limitations of the Presented Technique

Advantages	Limitations
Stable refixation of meniscal root at the footprint	Potential interference of tibial tunnel with concomitant procedures
No additional posterior portal needed	Additional costs of the suspensory fixation system
Prevent secondary looseness in the knot attached to the button implant in the tibia	Fixation might loosen if suture button gets in the tibial tunnel.
Provide the desired tension in the fixation of the button implant in different degrees of flexion of the knee	

Surgical Approach

A standard 2-portal approach via anterolateral viewing portal and anteromedial instrumentation portal area is created and a diagnostic arthroscopy is performed. The joint is insufflated with normal saline, and a 30° arthroscope (Stryker, Kalamazoo, MI) is used. Following diagnostic arthroscopy and identification of the posterior horn medial meniscal root tear, the knee is placed in ~30° flexion with valgus force, and the anteromedial portal is created under direct visualization to optimize the trajectory for meniscal instrumentation. If it is determined that even under valgus stress the

MCL remains too tight to safely instrument the compartment, then we proceed pie-crusting method to releasing the medial collateral ligament (MCL).⁸

Meniscal Root Repair

After the optimal view is obtained from the portals, preparations are made for the defined technique. The meniscus root is revived with by the punch. The attachment area is prepared by cleaning the cartilage from the tissue (Fig 1) Afterward, loop stitches are tied to the meniscus root (Fig 2) with 2 nonabsorbable sutures (Suturemaxx, Ankara, Turkey) using the Fast Pass Mini self-retrieving device (Smith & Nephew, Hamburg, Germany). After determining the center of the attachment area, the tibial guide used in anterior cruciate ligament surgeries is placed on the prepared place. After the guide is placed on the center of the attachment area from the anteromedial portal, the drill location is determined by adjusting it to 55° on the proximal tibia medial to the crest, the skin is opened with a 2-cm incision, and the subcutaneous tissue is dissected up to the bone. The Kirshner wire used as a guide is sent from the tibia medial cortex, and it is checked whether it comes out of the attachment area with an arthroscope. After exiting the attachment area, the pointed end of the Kirshner wire is protected with the curette so as not to damage the cartilage, while a tibial tunnel is created from the tibia over the guide the Kirshner wire with a 4.5-mm drill toward the attachment area. The tibial tunnel length is measured with an arthroscopic ruler, and the suspensory fixation system is installed at least 2 cm beyond the tunnel length. No:1 PDS (Polydioxanone Suture) is connected to the lifted system by using it as a carrier suture and sent to the

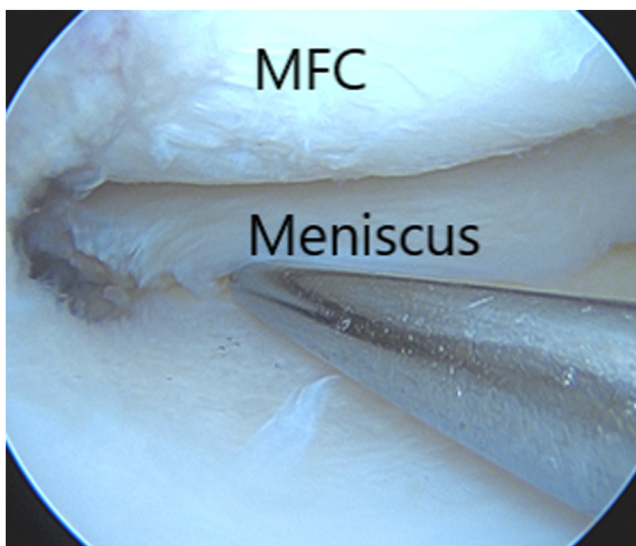


Fig 1. MMRT is examined with the hook. MFC, medial femoral condyle; MMRT, medial meniscal root tear.

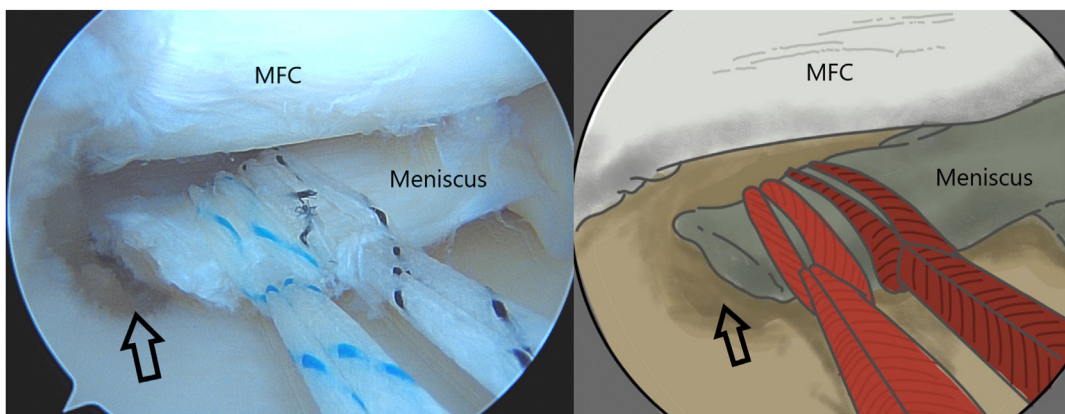


Fig 2. Locked-loop stitching to MMRT with 2 fiber stitches from anteromedial portal. Tunnel placement viewed through anterolateral portal is centered in posterior medial meniscal root insertion marked by open arrows.

joint. When the loop of the suspensory fixation system comes out of the tunnel, the carrier thread is cut. One limb of the loop stitches put into the meniscus is taken with a thread holder, in turn, and taken out from the cannula through the anteromedial portal. The other limb of the same knot is passed through the loop of suspensory fixation system and taken out of the cannula (Fig 3). The sutures on the loop are tied with 4 arthroscopic knots, so that they do not fully contact the meniscus (Fig 4). Then the same process is done for the thread of the other color. After the knots are tied, the threads are cut. The desired tension in the meniscus root is adjusted using suspensory fixation system, while the knee is in 45° of flexion (Fig 5). Afterward, 4 knots

are tied on the suture button with suspensory fixation system threads, and it is confirmed that the suture button does not fall into the canal and sits on the cortex (Fig 6). The schematic drawing of root repair made with the suspensory fixation system is shown in Fig 7. A detailed step-by-step description of the surgical technique is demonstrated in Video 1.

Postoperative Rehabilitation

Patients are walked non-weight bearing for 6 weeks after surgery. But joint movements are started immediately, and 90° flexion is allowed for 3-4 weeks starting on day 1. Return to sports is allowed 4 months after the operation.

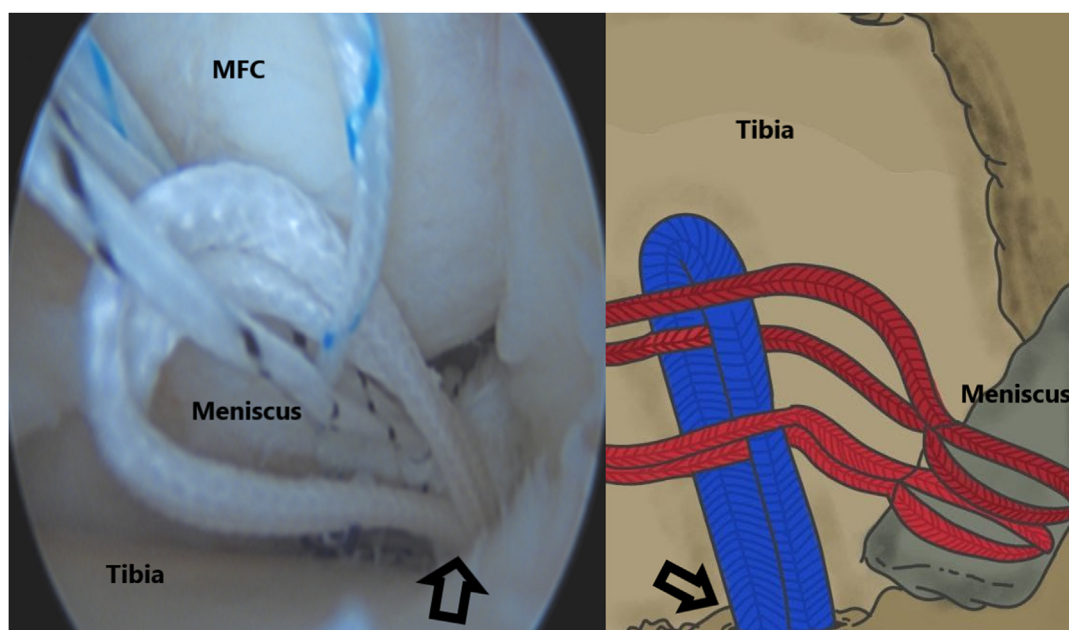


Fig 3. Passing one of the threads of the stitching at the root through the loop of the suspensory fixation system. Open arrows show the tunnel placement.

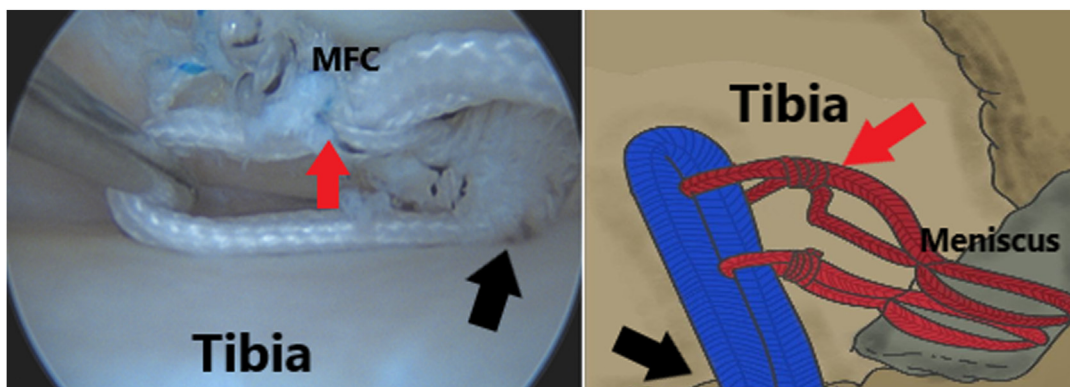


Fig 4. It is seen that the sutures, one limb of which is passed through the suspensory fixation system loop, are fixed to that loop by tying 4 knots (showed by black arrows). Red arrows show the tunnel placement.

Discussion

Clinical and biomechanical studies show that the knee's functional scores increase, and the degenerative process of the joint is delayed in anatomically repaired posterior root tears of the medial meniscus. In a retrospective study by Kaplan et al., the MRI and functional scores of the patients who were repaired with transtibial pull-out in the 2-year follow-up were examined. It was found that although the functional scores of the patients increased, the amount of meniscal extrusion also increased.⁹ In a biomechanical study by Anthony et al. on pig cadavers, the transtibial pull-out method detected medial meniscus posterior roots. Loosening of the meniscus-suture interface, bone-button interface, and suture elongation was recorded after 1,000 cyclic cycles. It was found that the loosening at the meniscus-suture interface was higher than the others.¹⁰ In a biomechanical study by Brett et al. on sheep cadavers, posteromedial root repair was performed with a transtibial pull-out method using a single tunnel in one group and a double tunnel in the other group. There

was no significant difference in loosening between the two groups after 10,000 cyclic cycles. It has been shown that there is a potential risk for relaxation in cyclic movements performed until adequate healing of the meniscus, and the importance of rehabilitation in the postoperative recovery process has been emphasized.¹¹ In a biomechanical study conducted by Richard et al. on cadavers, meniscal root tears were identified in 4 different groups with simple sutures, simple double sutures, loop sutures, and locked loop sutures, their durability was compared with biomechanical tests. It was observed that the locked loop seam to loosen less and was more tense compared to the others.¹²

The suture anchor technique is an all-inside technique in medial meniscal root tear. This technique needs a high posteromedial portal and eliminates the need for tibial tunnel drilling. Micromotion of meniscus-suture construct is minimized in the suture anchor technique because the suture repair construct is short and less prone to micromotion. Placing a suture anchor in a small arthroscopic space, while ensuring accurate anatomic placement, is technically demanding, particularly in cases without concurrent medial collateral ligament injury. Another disadvantage after anchor placement is that it may be difficult to perform shuttle stitches between portals in patients with wide hips or high body mass index.¹³ Jung et al. reported that the suture anchor may loosen and protrude into the joint over time.¹⁴ Feucht et al. reported that the suture anchor technique allowed displacement under cyclic loading in a porcine model; however, the displacement ($1.3 \text{ mm} \pm 0.3 \text{ mm}$) was less than that associated with the transtibial pullout technique ($2.2 \text{ mm} \pm 0.5 \text{ mm}$).¹⁵

Several techniques have been described for transosseus suture repair.¹⁶⁻¹⁹ Typically, the sutures are passed through the meniscus, pulled out through a transtibial tunnel, and tied over a bone bridge, a suture button, or a screw at the anterior tibial cortex. During the fixation of the threads to the tibia, undesirable loosening may occur at the bone interface.

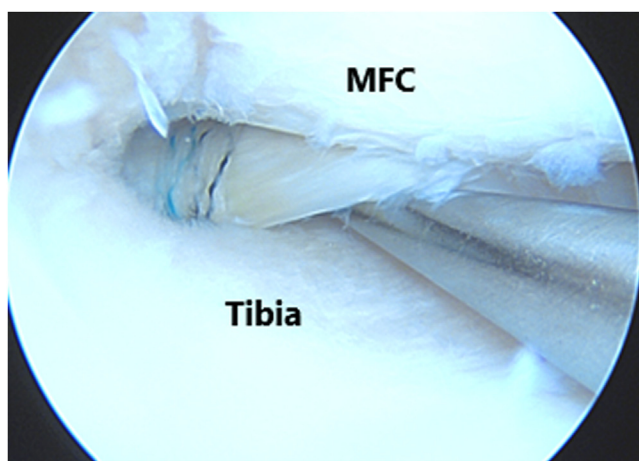


Fig 5. Adjustment of the root detected by the suspensory fixation system at the desired tension.

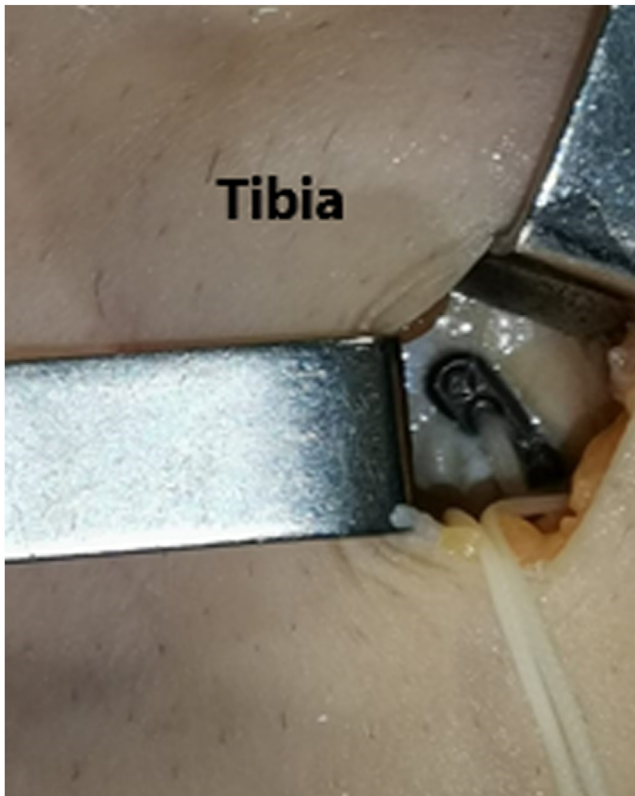


Fig 6. Confirmation that the button implant, which was detected using the suspensory fixation system, remains on the surface of the cortex.

This suspensory technique aims to prevent secondary looseness in the knot attached to the button implant in the tibia and provide the desired tension in the fixation

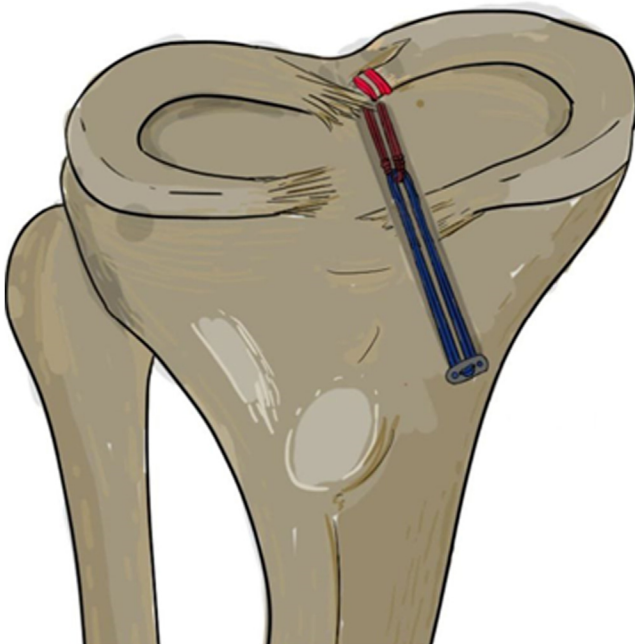


Fig 7. Transosseous fixation with suspensory fixation system schematic drawing.

of the button implant in different degrees of knee flexion. Although this method does not prevent loosening at the meniscal-suture interface, it can avoid loosening at the bone-button interface that may occur during surgery.

References

1. Allaire R, Muriuki M, Gilbertson L, Harner CD. Biomechanical consequences of a tear of the posterior root of the medial meniscus. Similar to total meniscectomy. *J. Bone Joint Surg Am* 2008;90:1922-1931.
2. Marzo JM, Gurske-DePerio J. Effects of medial meniscus posterior horn avulsion and repair on tibiofemoral contact area and peak contact pressure with clinical implications. *Am J Sports Med* 2009;37:124-129.
3. Bhatia S, LaPrade CM, Ellman MB, LaPrade RF. Meniscal root tears: significance, diagnosis, and treatment. *Am J Sports Med* 2014;42:3016-3030.
4. Lerer DB, Umans HR, Hu MX, Jones MH. The role of meniscal root pathology and radial meniscal tear in medial meniscal extrusion. *Skeletal Radiol* 2004;33:569-574.
5. Chahla J, LaPrade RF. Meniscal root tears. *Arthroscopy* 2019;35:1304-1305.
6. Moon HK, Koh YG, Kim YC, Park YS, Jo SB, Kwon SK. Prognostic factors of arthroscopic pull-out repair for a posterior root tear of the medial meniscus. *Am J Sports Med* 2012;40:1138-1143.
7. Forkel P, Petersen W. Posterior root tear fixation of the lateral meniscus combined with arthroscopic ACL double-bundle reconstruction: Technical note of a transosseous fixation using the tibial PL tunnel. *Arch Orthop Trauma Surg* 2012;132:387-391.
8. Atoun E, Debbi R, Lubovsky O, Weiler A, Debbi E, Rath E. Arthroscopic trans-portal deep medial collateral ligament pie-crusting release. *Arthrosc Tech* 2013;2:e41-43.
9. Kaplan DJ, Alaia EF, Dold AP, et al. Increased extrusion and ICRS grades at 2-year follow-up following transtibial medial meniscal root repair evaluated by MRI. *Knee Surg Sports Traumatol Arthrosc* 2018;26:2826-2834.
10. Cerminara AJ, LaPrade CM, Smith SD, Ellman MB, Wijdicks CA, LaPrade RF. Biomechanical evaluation of a transtibial pull-out meniscal root repair: challenging the bungee effect. *Am J Sports Med* 2014;42:2988-2995.
11. Steineman BD, LaPrade RF, Haut Donahue TL. Loosening of transtibial pullout meniscal root repairs due to simulated rehabilitation is unrecoverable: A biomechanical study. *Arthroscopy* 2019;35:1232-1239.
12. Mitchell R, Pitts R, Kim YM, Matava MJ. Medial meniscal root avulsion: A biomechanical comparison of 4 different repair constructs. *Arthroscopy* 2016;32:111-119.
13. Mitchell RF, LaPrade CM, James EW. Recent advances in posterior meniscal root repair techniques. *J Am Acad Orthop Surg* 2015;23:71-76.
14. Jung YH, Choi NH, Oh JS, Victoroff BN. All-inside repair for a root tear of the medial meniscus using a suture anchor. *Am J Sports Med* 2012;40:1406-1411.
15. Feucht MJ, Grande E, Brunhuber J, et al. Biomechanical comparison between suture anchor and transtibial pull-

- out repair for posterior medial meniscus root tears. *Am J Sports Med* 2014;42:187-193.
16. Kim YM, Rhee KJ, Lee JK, Hwang DS, Yang JY, Kim SJ. Arthroscopic pullout repair of a complete radial tear of the tibial attachment site of the medial meniscus posterior horn. *Arthroscopy* 2006;22, 795.e791-794.
 17. Holmes SW Jr, Huff LW, Montoya KJ, Durkin MW, Baier AJ. Arthroscopic medial meniscal root reconstruction with gracilis autograft is safe and improves 2-year postoperative patient-reported outcomes. *Arthrosc Sports Med Rehabil* 2022;4:e1339-e1346.
 18. DeFroda SF, Singh H, Cohn MR, Vadhera AS, Verma NN. Meniscal root repair with mini-open medial collateral ligament release. *Arthrosc Tech* 2021;10: e2571-e2575.
 19. Yang W, Wang H, Shao Z, Huang W. Application of continuous sewing machine-like suture technique in meniscus injury. *Arthrosc Tech* 2023;12:e715-e721.