



HAL
open science

Double level osteotomy for genu varum: Is a return to sport possible?

Alexandre Caubère, Olivier Barbier, Kristian Kley, Lukas Hanak, Christophe Jacquet, Matthieu Ollivier

► To cite this version:

Alexandre Caubère, Olivier Barbier, Kristian Kley, Lukas Hanak, Christophe Jacquet, et al.. Double level osteotomy for genu varum: Is a return to sport possible?. *Orthopaedics & Traumatology: Surgery & Research*, 2023, 109 (4), pp.103397. 10.1016/j.otsr.2022.103397 . hal-04490638

HAL Id: hal-04490638

<https://hal.science/hal-04490638>

Submitted on 5 Mar 2024

HAL is a multi-disciplinary open access archive for the deposit and dissemination of scientific research documents, whether they are published or not. The documents may come from teaching and research institutions in France or abroad, or from public or private research centers.

L'archive ouverte pluridisciplinaire **HAL**, est destinée au dépôt et à la diffusion de documents scientifiques de niveau recherche, publiés ou non, émanant des établissements d'enseignement et de recherche français ou étrangers, des laboratoires publics ou privés.

Double level osteotomy for genu varum: Is a return to sport possible?

Alexandre Caubère^{a,*}, Olivier Barbier^a, Kristian Kley^b, Lukas Hanak^c, Christophe Jacquet^{d,e}, Matthieu Ollivier^{d,e}

^a Service de Chirurgie Orthopédique et Traumatologie, Hôpital d'Instruction des Armées Sainte-Anne, 2, boulevard Sainte-Anne, BP 600, 83800 Toulon, France

^b Harley Street Specialist Hospital, 18-22, Queen Anne Street, London, W1G8HU, United Kingdom

^c Orthopädie Maximilium, Donauwörth, Germany

^d Service de Chirurgie Orthopédique et Traumatologie, Université Aix-Marseille, APHM, CNRS, ISM, Hôpital Sainte-Marguerite, Institut du Mouvement et de l'appareil Locomoteur, Marseille, France

^e Service de Chirurgie Orthopédique et Traumatologie, Hôpital Sainte-Marguerite, Institut du Mouvement et de l'appareil Locomoteur, 270, boulevard Sainte-Marguerite, BP 29, 13274 Marseille, France

A B S T R A C T

Introduction: A double level osteotomy (DLO) may be indicated in patients with genu varum when the deformity involves both the tibia and femur. These patients, who are often young and active, have a high functional demand and hope for a rapid return to sport. The purpose of our study was to assess return to sport and functional outcomes following DLO for symptomatic genu varum.

Materials and methods: A total of 40 patients (mean age 45.5 ± 2 years) who underwent a DLO between 2018 and 2020, performed in 2 different hospitals, were reviewed after a minimum follow-up of 1-year. The mean initial varus was $11 \pm 2^\circ$. The type of sport and frequency of participation (UCLA activity score) as well as time to return to sport and level of activity recovered were defined as the primary endpoints. Functional scores were also assessed with the knee injury and osteoarthritis outcome score (KOOS).

Results: At the last follow-up, 87.5% ($n=35$) of patients reported that they had returned to sport. The mean time to return to sport was 6 ± 1 months with a significant difference ($p < 0.001$) between the pre- and postoperative UCLA activity scores. There was a strong correlation between the presence of a joint line obliquity $>3^\circ$ and decreased functional outcomes ($p < 0.0001$). The overall KOOS score improved ($p < 0.001$) by a mean of 38.6 points after the correction. The 8 lateral cortical fractures (Takeuchi type I and II) and the 2 medial cortical fractures (Nakayama type 1) that were found had no impact on functional outcomes ($p > 0.05$).

Conclusion: Our findings demonstrated that DLO provided rapid return to sport, thus making it possible to meet the functional demands and expectations of patients.

Level of evidence: IV; Retrospective study.

1. Introduction

Osteotomies around the knee remain the preferred surgical treatment for early-onset medial compartment osteoarthritis (OA) in young individuals [1]. For these patients, pain relief is important, but being able to return to their sports and recreational activities is even more vital [2]. Therefore, this treatment must meet the postoperative expectations and demands of these young and active patients.

Several studies on postoperative outcomes in patients who underwent a valgus high tibial osteotomy (HTO), reported return to sport and work rates of 85% [2,3]. However, few studies have reported the outcomes of other osteotomies around the knee, especially those that combine medial opening wedge high tibial osteotomy (MOWHTO) and closing wedge distal femoral osteotomy (CWDFO) to treat medial compartment OA in genu varum.

The purpose of our study was to assess time to return to sport and level of activity recovered following a double level osteotomy (DLO) for medial compartment OA in young patients. Our hypothesis was that DLOs allow a rapid return to sport at the same level of activity as before the onset of symptoms.

2. Materials and methods

2.1. Patients

This two-center retrospective study included all patients who underwent a DLO, between January 2018 and January 2020, for symptomatic medial compartment OA with constitutional genu varum. Patients were either operated on by Professor MO at the Sainte-Marguerite Hospital in Marseille (France) or by Doctor LH at the Maximilium Orthopädie Hospital in Donauwörth (Germany).

The indications for DLO were:

- isolated primary medial compartment OA (Ahlbäck grade ≤ 3 [4]) with preserved lateral and patellofemoral compartments;
- constitutional varus bone deformity involving both the tibia and femur were defined as a hip-knee-ankle angle (HKA) $< 178^\circ$, a mechanical medial proximal tibial angle (mMPTA) $< 87^\circ$ and a mechanical lateral distal femoral angle (mLDFA) $> 90^\circ$;
- knee stability in both the sagittal and frontal planes;
- failure of a well-conducted conservative treatment.

The exclusion criteria were:

- previous surgery on the affected knee;
- OA secondary to an injury or inflammatory rheumatism;
- isolated primary medial compartment OA (Ahlbäck grade > 3);
- obesity defined by a body mass index (BMI) ≥ 30 kg/m²;
- minimum follow-up < 12 months.

2.2. Surgical technique

The desired correction was calculated by the surgeon using standard X-rays (full length standing X-ray in the anteroposterior [AP] view and weight-bearing knee X-rays in AP and lateral views) according to the Miniaci method [5].

Both surgeons performed the procedure previously described by Ollivier et al. [6], which combined CWDFO and MOWHTO. All osteotomies were stabilized with the same locking plate and screw system (Newclip Technics, Haute-Goulaine, France). The target angles were a HKA = 181° and mLDFA = mMPTA = 87° (Fig. 1).

The same intra-operative and postoperative protocols were used in both groups, including full weight-bearing as tolerated starting 3 weeks after surgery and heparin thromboprophylaxis for 30 days. A knee extension brace was worn for about one week after the procedure to protect the surgical site (mean recovery time for muscle activation).

2.3. Clinical assessment and return to sport

A patient questionnaire was sent to collect the following data:

- demographic parameters: medical history, age, weight, height, sex, side operated and occupation;
- type of sport, intensity of training, activity level before and after the onset of symptoms, as well as during the different postoperative follow-up visits, indicating the time to return to sport and level of activity recovered. The University of California and Los Angeles (UCLA) activity score was used to define the type of sport and frequency of participation. Before the onset of symptoms, all patients regularly practiced a sport with a UCLA activity score > 6 and 12.5% of them participated in a high-impact sport (downhill skiing, tennis/squash, jogging, soccer/football and martial arts). All of these patients were proficient in the sport they practiced in their free time and none of them were professional athletes;

- clinical assessment was based on the knee injury and osteoarthritis outcome score (KOOS) which was performed during each visit;
- level of patient satisfaction after the procedure and at the last follow-up: disappointed, not satisfied, moderately satisfied, satisfied, very satisfied and enthusiastic.

The recorded intra-operative complications included:

- lateral cortical fractures (tibia) according to the Takeuchi classification [7] (type I: extension of the osteotomy line just proximal to the tibiofibular joint; type II: secondary fracture line on the distal part of the proximal tibiofibular joint; and type III: lateral tibial plateau fracture);
- medial cortical fractures (femur) according to the Nakayama classification [8] (type 1: fracture involves an extension of the osteotomy line; type 2: fracture extending proximally; type 3: fracture extending distally).

2.4. Radiographic assessment

The radiographic assessment included weight-bearing knee X-rays (AP and lateral views), as well as pre- and postoperative full length standing X-rays (AP view) taken at the last follow-up with the calculation of the following mechanical angles: overall HKA, mLDFA, mMPTA, joint line obliquity (JLO) and joint line convergence angle (JLCA).

Most of these patients had either an Ahlbäck grade 1, 2 or 3 OA. However, 2 patients with an Ahlbäck grade 0 OA were also treated because of their young age, significant overall varus and persistent post-meniscectomy syndrome. Moreover, cartilage lesions were visible on their magnetic resonance imaging (MRI).

2.5. Statistical analysis

Patient demographics, functional scores, return to sport and the radiographic findings were expressed as mean or median \pm standard deviation for continuous quantitative variables. A Kolmogorov-Smirnov test was used to verify that the quantitative variables were normally distributed, thus enabling the internal validation of the statistical tests.

A *t* test was used to compare normally distributed quantitative variables, whereas a Wilcoxon rank sum test was used to compare non-normally distributed quantitative variables.

The correlation analysis between clinical and radiographic findings was studied using a simple linear regression with estimated correlation coefficients. All statistical tests were two-tailed. *p*-values less than 0.05 were considered statistically significant to confirm whether a type I error occurred while testing the hypotheses. All statistical analyses were performed using version 18 of the SPSS software (SPSS Inc., Chicago, IL, USA).

3. Results

3.1. Return to sport

A total of 45 patients were enrolled in this series, with 5 lost to follow-up at the time of the review. Thirty-five patients (87.5%) reported that they had returned to sport at the last follow-up. The mean time to return to sport was 6 months (5.15–6.85). There was a significant difference between post- and preoperative UCLA activity scores ($p < 0.0001$). Thirty-two patients had a UCLA activity score > 6 , with 25% practicing a high-impact sport after surgery. Five patients (12.5%) did not return to their previous level of activity. Thirty-seven patients (92.5%) were able to return to work. The

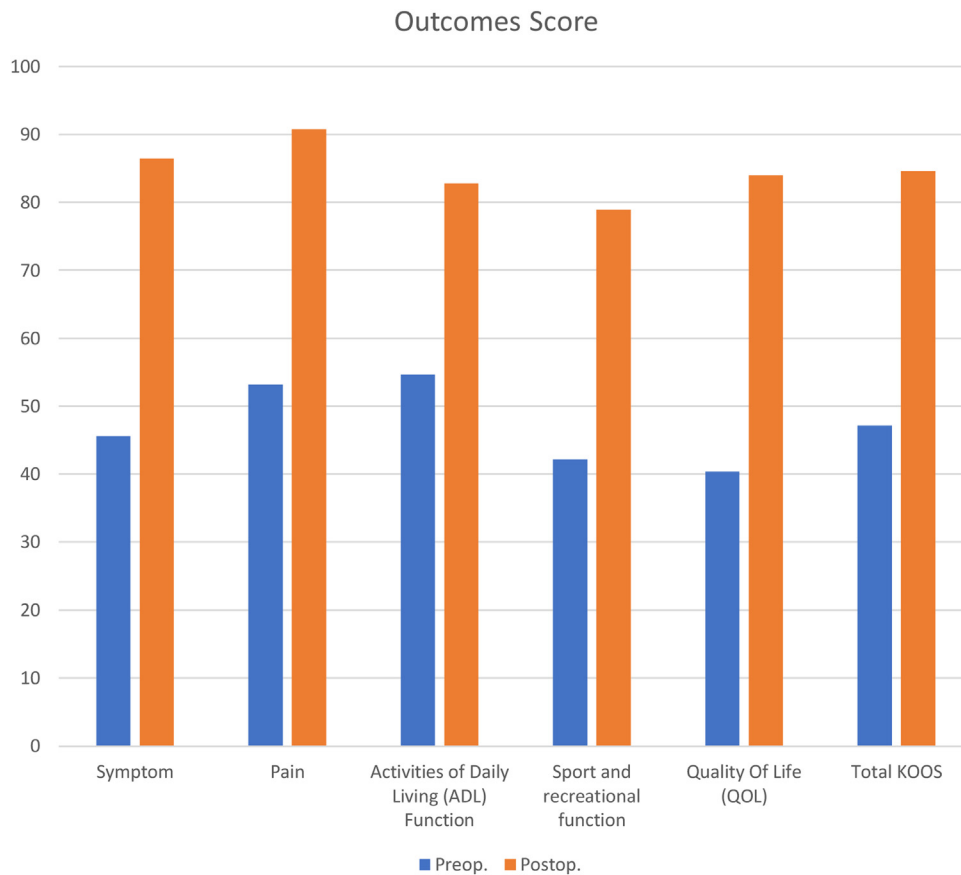


Fig. 2. Pre- and postoperative Symptoms, Pain, Activities of Daily Living (ADL) Function, sport and recreational function, Quality of Life (QOL), Total KOOS.

mean time to return to work was also 6 months (5.2–6.8), which was concomitant with the return to sport.

3.2. Demographics (Table 1)

The mean follow-up was 24 months (22–27). The series consisted of mainly male patients (85%), with a mean age of 45.5 years (43.1–47.1). The mean BMI was 25.8 ± 5.5 kg/m². The UCLA activity score deteriorated with the onset of symptoms ($p = 0.03$), with more than half of the patients (55.5%) having a UCLA activity score <5.

3.3. Functional scores

There were significant improvements in all KOOS subcategories after surgery ($p < 0.0001$) (Fig. 2). The KOOS “function in sport and recreation” subscore increased by a mean of 38.6 points (30.8–46.3) after DLO ($p < 0.0001$).

The multiple linear regression showed no significant correlation between symptom severity and age, BMI, sex, side operated and initial stage of OA ($p > 0.05$).

There was a strong statistical correlation between the functional outcomes and the JLO ($p < 0.001$). A JLO angle $>3^\circ$ resulted in poorer functional outcomes, with a more difficult return to sport. No correlation was found with the other calculated angles (HKA, mMPTA and mL DFA).

3.4. Radiographic assessment

The mean overall varus before correction was 11° (HKA = 169° [168.7–170.5]). The mean preoperative tibial varus was an mMPTA

Table 1
Cohort presentation.

Parameters	DLO Group
Mean age (years)	45.5 (43.1–47.9)
Mean BMI (kg/m ²)	25.8
Sex, Male (%)	34 (85)
Side, Left (%)	23 (57.5)
Ahlbäck Classification, n (%)	
0	2 (5)
1	15 (42.5)
2	10 (25)
3	13 (32.5)
UCLA activity score before symptoms, n (%)	
7	4 (10)
8	31 (75.5)
9	5 (12.5)
UCLA activity score preoperatively, n (%)	
3	1 (2.5)
4	9 (22.5)
5	22 (55)
6	5 (12.5)
8	3 (7.5)

DLO: double level osteotomy; UCLA: University of California and Los Angeles.

of 83.9° (79–88.4) and the mean preoperative femoral varus was an mL DFA of 92.5° (90–101).

Our postoperative measurements showed that the limb alignment was restored with a mean HKA of 182° (178–184), a mean mL DFA of $86.4 \pm 1.4^\circ$, and a mean mMPTA of $90.7 \pm 2^\circ$. The mean JLO was 2.7° (2.3–3.2) preoperatively and 2.8° (2.5–3.4) postoperatively (Table 2).

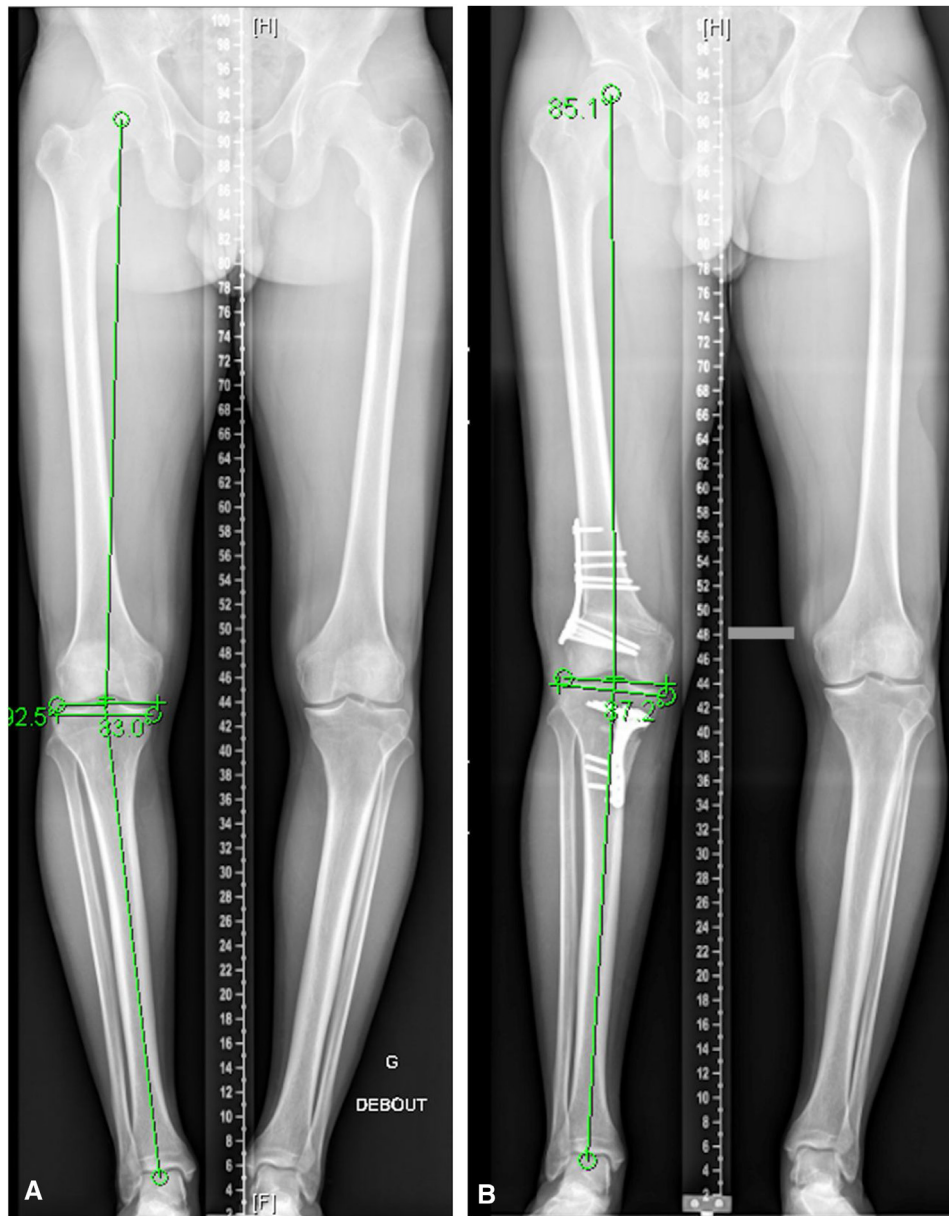


Fig. 1. A 40 year-old male with symptomatic genu varum. Full length standing X-rays in the AP view before (A) and after (B) corrective DFO. A. HKA = 172°; mLDFA = 92.5°; mMPTA = 83°. B. HKA = 181°; mLDFA = 85.1°; mMPTA = 87.2°.

3.5. Complications

Weight-bearing was deferred to 6 weeks postoperatively for the 8 lateral cortical fractures (Takeuchi type I and II) and the 2 medial cortical fractures (Nayekama type 1). A CT scan performed during the follow-up visit checked whether the fracture had healed properly so as to allow the resumption of weight-bearing on the operated limb. There did not appear to be any correlation between the presence of a cortical fracture and return to sport ($p > 0.05$).

Eight other complications were recorded: 1 osteolysis of the bone graft, 2 postoperative hematomas and 3 scar dehiscences. All these complications were unremarkable at the last follow-up. The hematomas and scar dehiscences did not require revision surgery because patients had a good degree of tolerance and responded well to the conservative treatment.

Finally, 15 patients (37.5%) had to have their bone plates removed because of discomfort caused by the hardware around 1 year after surgery. The option to remove these plates was not

systematically proposed and was only performed upon patient request. There was also no correlation between hardware removal and return to sport ($p > 0.005$).

4. Discussion

The primary purpose of this study was to assess return to sport after double level knee osteotomies in young and active patients. Our findings showed that 87.5% of patients were able to return to sport with their functional demands and expectations satisfied after a DFO. On average, patients returned to sport less than 1 year after surgery, with the vast majority being very satisfied.

The patient's functional demand and willingness to return to sport should enable surgeons to choose the best indication for the management of early-onset OA in young individuals. The study by Noble et al. [9] on total knee arthroplasties and the study by Saier et al. [10] on valgus HTOs, both showed that patient expectations expressed during the initial consultation were a key factor for the

Table 2

Pre- and postoperative mean radiographic measurements.

	Preoperative	Postoperative
HKA	169.6 (168.7–170.5)	182 (181.4–182.2)
mLDFA	92.5 (91.8–93.2)	86.4 (85.9–86.8)
mMPTA	83.9 (83.2–84.7)	90.8 (90.1–91.4)
JLCA	3.3 (2.9–3.8)	1.7 (1.3–2)
JLO	2.7 (2.3–3.2)	2.8 (2.5–3.4)

HKA: hip-knee-ankle angle; mLDFA: mechanical lateral distal femoral angle; mMPTA: mechanical medial proximal tibial angle; JLCA: joint line convergence angle; JLO: joint line obliquity.

success of these procedures. Over the past 2 decades, osteotomies have made a comeback in the surgeon's OA armamentarium, thanks to a better understanding of indications and planning and the development of recent innovations facilitating its execution. The aim of double level osteotomies of the knee is to correct limb deformity by obtaining angles close to normal with a horizontal joint line [11]. Feucht et al. [12] studied 303 full-leg X-rays of patients with varus malalignment and reported that 4% of these patients had deformities involving both the tibia and femur. In these cases, combined osteotomies need to be performed to correct both the femoral and tibial deformities. The indication is therefore for femoral (mLDFA) and tibial (mMPTA) angles $> 3^\circ$ of the normal values [13]. Therefore, a DLO should be considered for varus deformities when mLDFA $< 87^\circ$ and mMPTA $> 90^\circ$ [14].

Return to sport and functional outcomes have been well documented in the literature on valgus HTOs [2,3,15,16]. Ekhtiari et al. [2] showed in their literature review that on average 87.2% of patients returned to sport within 1 year of the valgus HTO, with 78.6% of them returning to a level of activity that was the same as before the onset of symptoms. The meta-analysis conducted by Hoorntje [3], comparing outcomes after osteotomies performed around the knee, reported that 94% of patients returned to sport with 85% of them returning to their previous level of activity. A recent study [17] confirmed the possibility of a faster return to sport and even a return to high-impact sports with valgus HTOs compared to unicompartamental knee arthroplasties in medial compartment OA at the 2-year follow-up.

To our knowledge, no studies in the literature have yet examined return to sport and recreation following a DLO. This is therefore the first study to do so, with 40 cases of genu varum managed by DLO in patients who regularly practiced a sport before the onset of symptoms. Our findings confirmed similar results to those previously reported for more commonly used osteotomies.

Several studies [14,18–20] have shown significant functional impacts when the JLO was $\geq 4^\circ$. These findings seem to confirm that JLO is an unfavorable factor in the return to sport due to poorer functional outcomes. A postoperative JLO angle $> 3^\circ$ was significantly correlated with poorer functional outcomes and a later return to sport that was not at the same level.

It is therefore important to check the changes in JLO and JLCA angles after correction when planning a corrective osteotomy preoperatively [21]. Saragaglia et al. [22–28] already reported in numerous publications, the importance of using computer-assisted navigation systems to obtain the desired correction angles so as to guarantee functional outcomes. According to the study by Micicoi et al. [29], the planned anatomical angles were obtained in less than half the cases after corrective osteotomies to correct the mechanical axis, with the persistence of a bone deformity. The development of patient-specific cutting guides would make it even easier for surgeons to obtain the desired correction [30–32]. However, the optimal angles for lower limb alignment have yet to be defined.

The overall incidence of hinge fractures in this series was 20%: 8 lateral cortical fractures and 2 medial cortical fractures. These were mainly Takeuchi type I fractures. Takeuchi et al. [7], who developed

a new classification system for lateral cortical fractures, reported that they occurred in 25% of the 104 valgus HTOs they studied. The incidence of medial cortical fractures in femoral osteotomies varied between 18% and 50% depending on the series [33–37]. Ollivier et al. [6] proposed using a so-called protective pin, which was positioned before the osteotomy, to prevent the propagation of the osteotomy line into the medial cortex of the femur. The occurrence of this complication was not correlated with a worse outcome in any of these series.

This study had several limitations. For instance, the retrospective nature of this study yielded low statistical power. The short follow-up period prevented us from concluding on long-term maintenance of good functional outcomes and return to sport. Furthermore, the small sample size, in comparison to series studying the outcomes of valgus HTOs, compelled us to express some reservations about the significance of our findings even though the statistical trends were in line with those previously reported. It is also important to consider the preoperative workup when measuring angles. Our initial radiographic assessment was based on full length standing X-rays in the AP view. However, the angle measurements on these types of X-rays may vary according to the rotation of the hip or the leg, or if there are lower limb deviations in the sagittal plane (flexion deformity or recurvatum) [38,39]. Other imaging (EOS, CT scan, MRI) and/or surgical techniques (navigation and computer-assisted navigation) should be taken into account to ensure more accurate measurements [40,41].

5. Conclusion

The results of our study demonstrated a rapid return to sport, with good functional outcomes, after DLOs were performed in young patients with symptomatic genu varum and high functional demands. It adds to the armamentarium available to surgeons treating this disorder. Postoperative outcomes are more successful if patients are informed and aware of the recovery process and if their initial expectations are met.

Ethical approval

Our study protocol was approved by the local institutional review board before being initiated.

Disclosure of interest

KK and MO are consultants for Stryker®, Arthrex® and Newclip®. The other authors declare that they have no competing interest.

Sources of funding

None.

Author contributions

Alexandre Caubère: analyzed the data, drafted the manuscript and implemented the corrections after critical revision; Olivier Barbier: reviewed the manuscript and implemented the corrections after critical revision; Kristian Kley: collected data and reviewed the manuscript; Lukas Hanak: reviewed the manuscript; Christophe Jacquet: collected data; Matthieu Ollivier: conceptualization of study, collected data, performed the statistical analysis and implemented the corrections after critical revision.

References

- [1] Brinkman J-M, Lobenhoffer P, Agneskirchner JD, Staubli AE, Wymenga AB, Heerwaarden RJvan. Osteotomies around the knee. *Bone Joint J* 2008;1:1548–57 [90-B].
- [2] Ekhtiari S, Haldane CE, de SAD, Simunovic N, Musahl V, Ayeni OR. Return to work and sport following high tibial osteotomy. *J Bone Surg Am* 2016;98:1568–77.
- [3] Hoorntje A, Witjes S, Kuijer PPFM, Koenraadt KLM, Geenen RCIvan, Daams JG, et al. High rates of return to sports activities and work after osteotomies around the knee: a systematic review and meta-analysis. *Sports Med* 2017;47:2219–44.
- [4] Ahlback S. Osteoarthritis of the knee. A radiographic investigation. *Acta Radiol Diagn (Stockh)* 1968;1:7–72.
- [5] Elson DW, Petheram TG, Dawson MJ. High reliability in digital planning of medial opening wedge high tibial osteotomy, using Miniaci's method. *Knee Surg Sports Traumatol Arthrosc* 2015;23:2041–8.
- [6] Ollivier M, Fabre-Aubrespy M, Micicoi G, Ehlinger M, Hanak L, Kley K. Lateral femoral closing wedge osteotomy in genu varum. *Orthop Traumatology Surg Res* 2021;1.
- [7] Takeuchi R, Ishikawa H, Kumagai K, Yamaguchi Y, Chiba N, Akamatsu Y, et al. Fractures around the lateral cortical hinge after a medial opening-wedge high tibial osteotomy: a new classification of lateral hinge fracture. *Arthroscopy* 2012;28:85–94.
- [8] Nakayama H, Kanto R, Onishi S, Kambara S, Amai K, Yoshiya S, et al. Hinge fracture in lateral closed-wedge distal femoral osteotomy in knees undergoing double-level osteotomy: assessment of postoperative change in rotational alignment using CT evaluation. *Knee Surg Sports Traumatol Arthrosc* 2020;1:1–9.
- [9] Noble PC, Conditt MA, Cook KF, Mathis KB. Patient expectations affect satisfaction with total knee arthroplasty. *Clin Orthop Relat Res* 2006;452:35–43.
- [10] Saier T, Minzlaff P, Feucht MJ, Lämmle L, Burghoff M, Ihle C, et al. Health-related quality of life after open-wedge high tibial osteotomy. *Knee Surg Sports Traumatol Arthrosc* 2017;25:934–42.
- [11] Babis GC, An K-N, Chao EY, Rand JA, Sim FH. Double level osteotomy of the knee: a method to retain joint-line obliquity. Clinical results. *J Bone Joint Surg Am* 2002;84:1380–8.
- [12] Feucht MJ, Winkler PW, Mehl J, Bode G, Forkel P, Imhoff AB, et al. Isolated high tibial osteotomy is appropriate in less than two-thirds of varus knees if excessive overcorrection of the medial proximal tibial angle should be avoided. *Knee Surg Sports Traumatol Arthrosc* 2021;29:3299–309.
- [13] Babis GC, An KN, Chao EYS, Larson DR, Rand JA, Sim FH. Upper tibia osteotomy: long term results- realignment analysis using OASIS computer software. *J Orthop* 2008;13:328.
- [14] Schröter S, Nakayama H, Yoshiya S, Stöckle U, Ateschrang A, Gruhn J. Development of the double level osteotomy in severe varus osteoarthritis showed good outcome by preventing oblique joint line. *Arch Orthop Traum Surg* 2019;139:519–27.
- [15] Hoorntje A, Kuijer PP, Koenraadt K, Waterval-Witjes S, Kerckhoffs G, Mastbergen S, et al. Return to sport and work after randomization for knee distraction versus high tibial osteotomy: is there a difference? *J Knee Surg* 2020;1.
- [16] Saragaglia D, Rouchy R-C, Krayan A, Refaie R. Return to sports after valgus osteotomy of the knee joint in patients with medial unicompartmental osteoarthritis. *Int Orthop* 2014;38:2109–14.
- [17] Jacquet C, Gulagaci F, Schmidt A, Pendse A, Parratte S, Argenson J-N, et al. Opening wedge high tibial osteotomy allows better outcomes than unicompartmental knee arthroplasty in patients expecting to return to impact sports. *Knee Surg Sports Traumatol Arthrosc* 2020;28:3849–57.
- [18] Nakayama H, Iseki T, Kanto R, Kambara S, Kanto M, Yoshiya S, et al. Physiologic knee joint alignment and orientation can be restored by the minimally invasive double level osteotomy for osteoarthritic knees with severe varus deformity. *Knee Surg Sports Traumatol Arthrosc* 2020;28:742–50.
- [19] Akamatsu Y, Nejima S, Tsuji M, Kobayashi H, Muramatsu S. Joint line obliquity was maintained after double-level osteotomy, but was increased after open-wedge high tibial osteotomy. *Knee Surg Sports Traumatol Arthrosc* 2021;1:1–10.
- [20] Song J-H, Bin S-I, Kim J-M, Lee B-S. What is an acceptable limit of joint-line obliquity after medial open wedge high tibial osteotomy? Analysis based on midterm results. *Am J Sports Med* 2020;48:3028–35.
- [21] Micicoi G, Khakha R, Kley K, Wilson A, Cerciello S, Ollivier M. Managing intra-articular deformity in high Tibial osteotomy: a narrative review. *J Exp Orthop* 2020;7:65.
- [22] Saragaglia D, Nemer C, Colle P-E. Computer-assisted double level osteotomy for severe genu varum. *Sports Med Arthrosc* 2008;16:91–6.
- [23] Saragaglia D, Mercier N, Colle P-E. Computer-assisted osteotomies for genu varum deformity: which osteotomy for which varus? *Int Orthop* 2010;34:185–90.
- [24] Saragaglia D, Rubens-Duval B, Chaussard C. Doubles ostéotomies assistées par ordinateur dans les grands genu varum Résultats préliminaires à propos de 16 cas. *Rev Chir Orthop Rep Appar Mot* 2007;93:351–6.
- [25] Saragaglia D, Roberts J. Navigated osteotomies around the knee in 170 patients with osteoarthritis secondary to genu varum. *Orthopedics* 2005;28:1 [s1296–74].
- [26] Saragaglia D, Blaysat M, Mercier N, Grimaldi M. Results of forty two computer-assisted double level osteotomies for severe genu varum deformity. *Int Orthop* 2012;36:999–1003.
- [27] Saragaglia D, Chedal-Bornu B, Rouchy RC, Rubens-Duval B, Mader R, Pailhé R. Role of computer-assisted surgery in osteotomies around the knee. *Knee Surg Sports Traumatol Arthrosc* 2016;24:3387–95.
- [28] Saragaglia D, Chedal-Bornu B. Computer-assisted osteotomy for valgus knees: medium-term results of 29 cases. *Orthop Traumatol Surg Res* 2014;100:527–30.
- [29] Micicoi G, Grasso F, Kley K, Favreau H, Khakha R, Ehlinger M, et al. Osteotomy around the knee is planned toward an anatomical bone correction in less than half of patients. *Orthop Traumatol Surg Res* 2021;1.
- [30] Micicoi G, Favreau H, Jacquet C, Ehlinger M, Ollivier M. Comments on: "Is patient-specific instrumentation more precise than conventional techniques and navigation in achieving planned correction in high tibial osteotomy?". *Orthop Traumatol Surg Res* 2021;107:102841.
- [31] Munier M, Donnez M, Ollivier M, Flecher X, Chabrand P, Argenson J-N, et al. Can three-dimensional patient-specific cutting guides be used to achieve optimal correction for high tibial osteotomy? Pilot study. *Orthop Traumatol Surg Res* 2017;103:245–50.
- [32] Tardy N, Steltzlen C, Bouguennec N, Cartier J-L, Merti P, Batailler C, et al. Is patient-specific instrumentation more precise than conventional techniques and navigation in achieving planned correction in high tibial osteotomy? *Orthop Traumatol Surg Res* 2020;106:S231–6.
- [33] Lee O-S, Lee YS. Diagnostic value of computed tomography and risk factors for lateral hinge fracture in the open wedge high tibial osteotomy. *Arthroscopy* 2018;34:1032–43.
- [34] Lee S-S, Celik H, Lee D-H. Predictive factors for and detection of lateral hinge fractures following open wedge high tibial osteotomy: plain radiography versus computed tomography. *Arthroscopy* 2018;34:3073–9.
- [35] Ogawa H, Matsumoto K, Akiyama H. The prevention of a lateral hinge fracture as a complication of a medial opening wedge high tibial osteotomy: a case control study. *Bone Joint J* 2017;887–93 [99-B].
- [36] Nakamura R, Komatsu N, Murao T, Okamoto Y, Nakamura S, Fujita K, et al. The validity of the classification for lateral hinge fractures in open wedge high tibial osteotomy. *Bone Joint J* 2015;1:1226–31 [97-B].
- [37] Winkler PW, Rupp MC, Lutz PM, Geyer S, Forkel P, Imhoff AB, et al. A hinge position distal to the adductor tubercle minimizes the risk of hinge fractures in lateral open wedge distal femoral osteotomy. *Knee Surg Sports Traumatol Arthrosc* 2021;29:3382–91.
- [38] Jamali AA, Meehan JP, Moroski NM, Anderson MJ, Lamba R, Parise C. Do small changes in rotation affect measurements of lower extremity limb alignment? *J Orthop Surg Res* 2017;12:77.
- [39] Kannan A, Hawdon G, McMahon S. Effect of flexion and rotation on measures of coronal alignment after TKA. *J Knee Surg* 2012;25:407–10.
- [40] Hsu RW-W, Hsu W-H, Shen W-J, Hsu W-B, Chang S-H. Comparison of computer-assisted navigation and conventional instrumentation for bilateral total knee arthroplasty. *Medicine* 2019;98:1 [e18083].
- [41] Barbotte F, Delord M, Pujol N. Coronal knee alignment measurements differ on long-standing radiographs vs. by navigation. *Orthop Traumatol Surg Res* 2021;1:1 [103112].