



HAL
open science

Inaugural dropped head syndrome and camptocormia in inflammatory myopathies: a retrospective study

Marie Robert, Lola E R Lessard, Françoise Bouhour, Philippe Petiot, Tanguy Fenouil, Juliette Svahn, Julie Fiscus, Nicole Fabien, Laurent Perard, Philip Robinson, et al.

► To cite this version:

Marie Robert, Lola E R Lessard, Françoise Bouhour, Philippe Petiot, Tanguy Fenouil, et al.. Inaugural dropped head syndrome and camptocormia in inflammatory myopathies: a retrospective study. *Rheumatology*, 2023, 63, pp.506 - 515. <10.1093/rheumatology/kead347>. <hal-04490558>

HAL Id: hal-04490558

<https://hal.science/hal-04490558v1>

Submitted on 5 Mar 2024

HAL is a multi-disciplinary open access archive for the deposit and dissemination of scientific research documents, whether they are published or not. The documents may come from teaching and research institutions in France or abroad, or from public or private research centers.



L'archive ouverte pluridisciplinaire **HAL**, est destinée au dépôt et à la diffusion de documents scientifiques de niveau recherche, publiés ou non, émanant des établissements d'enseignement et de recherche français ou étrangers, des laboratoires publics ou privés.



HAL Authorization

Clinical science

Inaugural dropped head syndrome and camptocormia in inflammatory myopathies: a retrospective study

Marie Robert ^{1,*}, Lola E. R. Lessard^{2,3}, Françoise Bouhour², Philippe Petiot², Tanguy Fenouil^{4,5}, Juliette Svahn², Julie Fiscus⁶, Nicole Fabien⁶, Laurent Perard⁷, Philip Robinson⁸, Isabelle Durieu⁹, Fabienne Coury^{10,11}, Nathalie Streichenberger^{3,4}, Arnaud Hot^{1,‡}, Laure Gallay ^{1,12,‡}

¹Service de Médecine Interne et Immunologie Clinique, Centre Hospitalier Universitaire Edouard Herriot, Hospices Civils de Lyon, Lyon, France

²Service d'Electroneuromyographie et Pathologies Neuromusculaires, Hôpital Neurologique Pierre Wertheimer, Hospices Civils de Lyon, Lyon, France

³Laboratoire Physiopathologie et Génétique du Neurone et du Muscle (PGNM), CNRS UMR5261—INSERM U1315, Institut NeuroMyoGène—Université Claude Bernard Lyon 1, Lyon, France

⁴Service de Cytologie et d'Anatomie Pathologique, Département de Neuropathologie, Groupement Hospitalier Est, Hospices Civils de Lyon, Lyon, France

⁵Equipe Ribosome Traduction et Cancer, UMR Inserm 1052 CNRS 5286, Centre de Recherche en Cancérologie de Lyon, Lyon, France

⁶Service d'Immunologie, UF Autoimmunité, Centre Hospitalier Lyon-Sud, Hospices Civils de Lyon, Pierre-Bénite, France

⁷Service de Médecine Interne, Centre Hospitalier Saint Joseph Saint Luc, Lyon, France

⁸Direction de la Recherche en Santé, Hospices Civils de Lyon, Lyon, France

⁹Service de Médecine interne, Hôpital Lyon Sud, Hospices Civils de Lyon, Pierre-Bénite, France

¹⁰Département de Rhumatologie, Hôpital Lyon Sud, Hospices civils de Lyon, Pierre-Bénite, France

¹¹Inserm UMR1033, Université Claude Bernard Lyon 1, Lyon, France

¹²Laboratoire Cell Therapy & Musculoskeletal Disorders, Université de Genève, Genève, Switzerland

*Correspondence to: Marie Robert, Service de Médecine interne du Pr Arnaud Hot, Hôpital Edouard Herriot, 5 Place d'Arsonval, F-69003 Lyon, France. E-mail: marie.robert07@outlook.com

‡A.H. and L.G. contributed equally.

Abstract

Objectives: Inaugural axial muscle involvement, defined as dropped head syndrome (DHS) and/or camptocormia (CC), is poorly described in inflammatory myopathies (IM). This study aimed to further characterize IM patients with inaugural DHS/CC, their outcome and care management.

Methods: This retrospective study included IM patients diagnosed between 2000 and 2021. The main inclusion criterion was IM revealed by axial muscle deficit (DHS/CC).

Results: Twenty-seven patients were included; median (IQR) age at first symptoms was 66.0 years (55.5–75.0); 21 were female (77.8%). There were nine IBM, 33.3%, nine overlap myositis (OM, 33.3%), five DM, 18.5%, two immune checkpoint inhibitor-related myositis (7.4%), one focal myositis (3.7%) and one myositis with anti-Hu antibodies (3.7%). Age at first symptoms was ≤ 70 years in 16 patients (59.3%), including all DM patients and 8/9 OM patients (88.9%). In this group, partial remission of the disease was obtained in 9/16 (56.3%) and complete remission in 1/16 patients (6.3%); regression of DHS/CC was achieved in 3/16 patients (18.8%). Conversely, in the group of 11 patients aged >70 years at first symptoms, there were eight IBM (72.7%). Partial remission was obtained in 5/11 patients (45.5%), the disease was stable in 6/11 patients (54.5%); no complete remission was obtained nor regression of DHS/CC.

Conclusion: The analysis of IM patients with inaugural DHS/CC delineates two groups of patients according to the age at first symptoms in terms of clinical and outcome specificities, and proposes an adapted diagnostic and care management approach to prevent long-term complications.

Keywords: dropped head syndrome, camptocormia, inflammatory myopathies, myositis

Rheumatology key messages

- Few data are available on inaugural axial involvement in patients with inflammatory myopathies.
- The present findings identify two groups of patients according to the age at first symptoms.
- This subgroup delineation should help to adapt diagnosis and care management.

Received: 15 December 2022. Accepted: 27 June 2023

© The Author(s) 2023. Published by Oxford University Press on behalf of the British Society for Rheumatology.

This is an Open Access article distributed under the terms of the Creative Commons Attribution-NonCommercial License (<https://creativecommons.org/licenses/by-nc/4.0/>), which permits non-commercial re-use, distribution, and reproduction in any medium, provided the original work is properly cited. For commercial re-use, please contact journals.permissions@oup.com

Introduction

Inflammatory myopathies (IM) are a heterogeneous group of acquired diseases either idiopathic or drug-induced that can affect muscles, skin, lungs, heart and joints. Increased knowledge about clinical manifestations, histopathological findings [1], and auto-antibodies identification have led to a new classification of four main idiopathic IM entities: DM, IBM, immune-mediated necrotizing myopathy (IMNM) and anti-synthetase syndrome (ASyS) [2]. Three more entities can be added to the IM spectrum: overlap myopathies (OM) that combine myositis and other autoimmune diseases as illustrated by scleromyositis [3]; immune checkpoint inhibitor-related myositis (irMyositis) that has recently emerged with the increasing use of these anti-cancer drugs [4]; and focal myositis (FM), a very rare disease [5]. In all types of IM, muscle weakness is generally symmetric and affects primarily proximal muscles, except for IBM that affects distal muscles [2] and FM that only affects a single muscle group [5]. However, axial muscle weakness is possible in each IM entity [2], and despite its major functional impact, its involvement in the course of IM is poorly described [6, 7]. Axial muscle weakness presents as either dropped head syndrome (DHS) that is characterized by a marked weakness of the neck extensors (Fig. 1A) [8], or as camptocormia (CC) that is characterized by a marked weakness of the thoracolumbar paraspinal muscles (Fig. 1B), and these may be associated with one another [9, 10]. Axial muscle weakness can be the presenting feature in inflammatory and non-inflammatory myopathies as well as in a broad spectrum of diseases affecting the central nervous system (dystonic, neurodegenerative disorders), the motoneurons, or the neuromuscular transmission [11–13]. For example, in a cohort study that included 107 patients

with predominant DHS from various causes, 8.4% of the patients had IM including 1.9% of IBM [12], while another study that included 276 patients with CC found that for 3.6% had IM with 1.4% of IBM [11], suggesting that IM is a rare cause of DHS/CC. However, IM represents one of the rare treatable causes of axial muscle weakness, and, as an inaugural DHS and/or CC is a highly atypical presentation of IM [12, 14], this may delay the IM diagnosis and the treatment of these patients. No published study has investigated inaugural axial involvement in IM.

We therefore aimed to describe IM revealed by DHS and/or CC and their clinical, laboratory and histopathological characteristics, as well as the treatments and outcomes.

Methods

Study design and participants

A retrospective study was conducted in a tertiary care centre. Patients were selected for the study through an exhaustive screening of the MYOLYON registry that includes all IM followed at the University Hospital of Lyon (France). Inclusion criteria were a diagnosis of IM between 2000 and 2021 in accordance with the current international criteria [5, 15–18] and inaugural axial involvement (DHS and/or CC; Fig. 1). The deficit was objectified by manual testing, using the 5-point Medical Research Council (MRC) scale [19]. Data were collected from medical records using an anonymous and standardized form. To exclude other causes of DHS and/or CC, as neurological disorder [e.g. Parkinson's disease, myasthenia gravis, and amyotrophic lateral sclerosis (ALS)], clinical examination, laboratory analyses, imaging, muscle biopsy and electroneuromyography (ENMG) data were gathered.

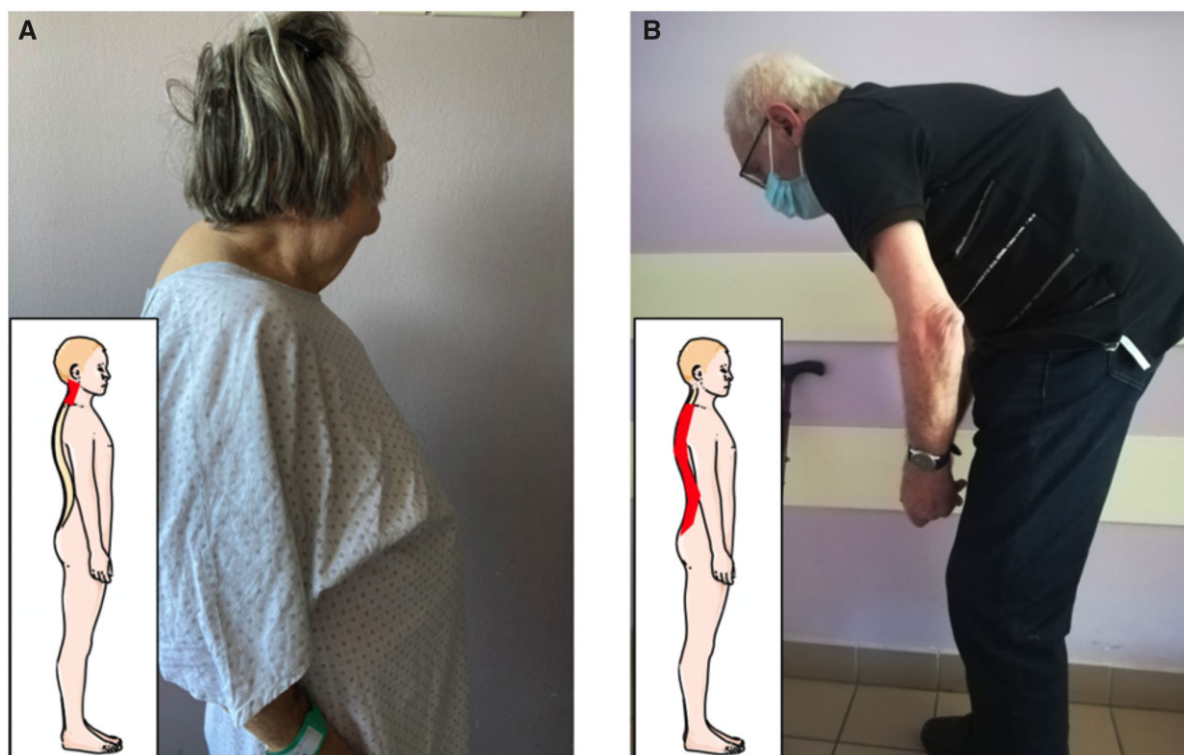


Figure 1. Dropped head syndrome (DHS) and camptocormia (CC) definitions. (A) Illustration of a patient with a DHS. DHS is defined as the limited ability to maintain erect neck posture leading to head dropping, corrected by passive extension of the neck or in recumbent position [12]. (B) Illustration of a patient with a CC. Consensual definition for CC was a 45° or greater forward flexion of the spine with resolution on assuming a supine posture [43]

Patients with a lack of diagnosis workup were excluded. Treatments used were recorded and classified into three categories: (i) first-line treatments included corticosteroids, MTX, MMF and AZA; (ii) second-line treatments included intravenous immunoglobulin (IVIG) and rituximab (RTX); and (iii) third-line treatments included CYC and/or plasma exchanges (PE). Treatment response was assessed by manual strength examination at the end of each line of treatment, and was classified into four categories: (i) active disease, defined as a continuous worsening of whole muscle involvement despite treatment (manual testing worsening); (ii) stable disease, defined as neither improvement nor progression of muscle weakness (stable manual testing); (iii) partial remission, defined as a mild improvement of symptoms (improvement of manual testing but persistent muscle weakness); and (iv) complete remission, defined as the resolution of clinical manifestations (no muscle weakness). When extra-muscular symptoms were associated, their course under treatment was considered.

Detection of antinuclear, anti-extractable nuclear antigen and myositis-specific antibodies

ANA were detected by indirect immunofluorescence on HEp2 cells (Kallestadt/Bio-Rad, Marnes La coquette, France) specifying the pattern of fluorescence as previously described [20]. Anti-extractable nuclear antigen (ENA) antibodies were measured using a multiplex flow immunoassay (MFA) (BioPlex™ 2200, Bio-Rad). Anti-cytosolic 5'-nucleotidase 1A autoantibodies (anti-cN1A) were detected using ELISA technique. The presence of other myositis-specific antibodies (MSA) and of myositis-associated antibodies was identified by dot immunoassays (Euroimmun, Lübeck, Germany; D-tek, Mons, Belgium) [20].

Pathological analysis

A centralized, standardized and blind analysis of muscle biopsies was performed according to the last European NeuroMuscular Centre (ENMC) recommendations [1] by experts in neuropathology (N.S., T.F.). Muscle biopsies were processed following a standardized protocol [21]. Morphological analysis was performed on haematoxylin-phloxine-saffron stained sections. Immune cell infiltrate within the muscle was phenotyped using anti-CD3 (2GV6 CC1 Std, prediluted; Ventana Medical Systems, Inc., Tucson, AZ, USA), anti-CD4 (SP35, CC1 Std, prediluted, Ventana), anti-CD8 (SP57 CC1 Std, prediluted, Ventana), anti-CD20 (L26 CC1 Short, prediluted, Ventana) and anti-CD68 (KP1, CC1 Std, prediluted, Ventana) antibody. All staining was performed with an immunohistochemistry automated instrument (Ultra Benchmark, Ventana). Major histocompatibility complex class (MHC) I and II (Dako, Agilent Santa Clara, CA, USA) expressions, and C5b9 (aE11 1/50, Dako) deposits were scored on immunohistochemistry. A diagnosis accuracy score (from 0: poorly evocative of the suspected diagnosis, to 10: highly evocative of the suspected diagnosis) was defined in accordance with current knowledge [22].

Statistical analyses

Descriptive analysis and frequency calculations were performed using Microsoft Excel (Microsoft Corporation©, Redmond, WA, USA). Medians are reported with interquartile ranges, (IQR).

Ethics statement

Written informed consent was not required according to the legislation in place at the time of the study. Nonetheless, for ethical consideration, patients were informed that their medical records might be used for research in accordance with the privacy rule. The study was approved by the local ethics committee of the *Hospices Civils de Lyon* (Lyon, France—Approval #22_5351) and conforms to the ethical guidelines of the 1975 Declaration of Helsinki. Written informed consent for publication of images was obtained from patients.

Results

Characteristics of patients at IM diagnosis

Twenty-seven patients with IM and inaugural axial involvement were included, 21 of whom (77.8%) were female (Table 1). Nine patients (33.3%) had one or multiple associated autoimmune diseases including Hashimoto's thyroiditis in five patients, Graves' disease in two patients, Crohn's disease in two patients, and autoimmune atrophic gastritis, primary biliary cholangitis, rheumatoid arthritis, cutaneous lupus were found in one patient, respectively. Nine patients (33.3%) had cancer. The median (IQR) age at first symptoms was 66.0 years (55.5–75.0); 16 patients (59.3%) were aged ≤ 70 years at IM onset. The median (IQR) interval between first symptoms and diagnosis was 1.5 years (0.0–3.5). Ten patients (37.0%) had an acute disease onset (< 3 months; Table 1). All included patients, except the patient with FM, presented both axial and extra-axial muscle weakness at baseline. DHS and CC were associated in 16 patients (59.3%), DHS occurred alone in seven patients (25.9%), and CC alone in four patients (14.8%). Clinical manifestations also included myalgia in 11 patients (40.7%), dysphagia in 13 patients (48.1%) and extra-muscular manifestations in 16 patients (59.3%). Extra-muscular manifestations included cutaneous lesions in 14 patients (e.g. hand oedema, systemic sclerosis or DM lesions), Raynaud's phenomenon in 11 patients, pulmonary involvement in six patients (i.e. interstitial lung disease), rheumatological manifestations in five patients (i.e. synovitis, arthritis), and heart involvement in three patients (i.e. pulmonary hypertension and/or right heart failure). Axial muscle impairment-related complications, defined as malnutrition, aspiration pneumonia and/or intensive care unit (ICU) admission, concerned 10 patients (37.0%). Four patients (14.8%) died during follow-up; for two this was related to infectious disease and for the remaining two the cause of death was not known. Laboratory analyses found elevated creatine kinase (CK) in 25 patients (92.6%), in whom the median \times upper normal limit (UNL) was 3.4 (2.0–8.1). C-reactive protein (CRP) was elevated in seven patients (25.9%). ANA were found in 21 patients (77.8%); the pattern of fluorescence, available in 15 patients, was nucleolar in six of them, mixed (nucleolar and homogeneous or speckled) in six patients, speckled in one patient, and proliferating cell nuclear antigen (PCNA) or PCNA-like in two patients. ENMG was performed in 26 patients (96.3%; Table 1), 10 of whom (38.5%) had an ENMG of axial muscles. ENMG was abnormal in all but three cases ($n = 23/26$, 88.5%), identifying either a myogenic pattern ($n = 16/26$, 61.5%), a neurogenic pattern ($n = 1/26$, 3.8%), or both ($n = 6/26$, 23.1%). Imaging (computed tomography or magnetic resonance imaging) of axial muscles was performed in nine patients (33.3%; Table 1);

Table 1. Characteristics of patients

	Total <i>n</i> = 27	IBM <i>n</i> = 9 (33.3%)	OM <i>n</i> = 9 (33.3%)	DM <i>n</i> = 5 (18.5%)	irMyositis <i>n</i> = 2 (7.4%)	FM <i>n</i> = 1 (3.7%)	Other ^a <i>n</i> = 1 (3.7%)
General characteristics							
Female, <i>n</i> (%)	21 (77.8)	8 (88.9)	8 (88.9)	5 (100.0)	0	0	0
Age at 1st symptoms, years, median (IQR)	66.0 (55.5–75.0)	76.0 (75.0–78.0)	56.0 (33.0–65.0)	61.0 (57.0–68.0)	76.5 (75.3–77.8)	48.0	41.0
Age at 1st symptoms ≤70 years, <i>n</i> (%)	16 (59.3)	1 (11.1)	8 (88.9)	5 (100.0)	0	1	1
Interval between first symptoms and diagnosis, years, median (IQR)	1.5 (0.0–3.5)	3.0 (2.0–4.0)	2.0 (0.8–5.0)	0.0 (0.0–0.5)	0 (0.0–0.0)	0.0	1.0
Acute disease onset (<3 months), <i>n</i> (%)	10 (37.0)	1 (11.1)	3 (33.3)	4 (80.0)	2 (100.0)	0	0
Length of follow-up, years, median (IQR)	6.0 (1.5–10.0)	4.0 (3.0–7.0)	8.0 (4.0–11.0)	10.0 (6.0–13.0)	1.0 (1.0–1.0)	1.0	12.0
Muscular manifestations							
Pattern of axial muscle involvement							
DHS + CC, <i>n</i> (%)	16 (59.3)	4 (44.4)	8 (88.9)	3 (60.0)	0	0	1
DHS alone, <i>n</i> (%)	7 (25.9)	2 (22.2)	1 (11.1)	1 (20.0)	2 (100.0)	1	0
CC alone, <i>n</i> (%)	4 (14.8)	3 (33.3)	0	1 (20.0)	0	0	0
Myalgia, <i>n</i> (%)	11 (40.7)	0	6 (66.7)	3 (60.0)	0	1	1
Distal muscle weakness, <i>n</i> (%)	11 (40.7)	8 (88.9)	0	2 (40.0)	0	0	1
Dysphagia, <i>n</i> (%)	13 (48.1)	3 (33.3)	6 (66.7)	3 (60.0)	1 (50.0)	0	0
Extra-muscular manifestations, <i>n</i> (%)	16 (59.3)	2 (22.2)	9 (100.0)	5 (100.0)	0	0	0
Axial muscle impairment-related complications, <i>n</i> (%)							
Malnutrition, <i>n</i> (%)	9 (33.3)	3 (33.3)	2 (22.2)	2 (40.0)	2 (100.0)	0	0
Aspiration pneumonia, <i>n</i> (%)	5 (18.5)	1 (11.1)	0	2 (40.0)	2 (100.0)	0	0
ICU, <i>n</i> (%)	3 (11.1)	0	1 (11.1)	2 (40.0)	0	0	0
Death, <i>n</i> (%)	4 (14.8)	0	3 (33.3)	0	1 (50.0)	0	0
Laboratory features							
Elevated CK level (>N), <i>n</i> (%)	25 (92.6)	8 (88.9)	8 (88.9)	5 (100.0)	2 (100.0)	1	1
CK values (xUNL), median (IQR)	3.4 (2.0–8.1)	1.9 (1.6–2.6)	3.7 (2.5–5.1)	8.0 (5.0–10.0)	26.0 (18.0–34.0)	2.0	8.4
Elevated CRP (>N), <i>n</i> (%)	7 (25.9)	1 (11.1)	1 (11.1)	3 (60.0)	1 (50.0)	1	0
ANA positivity, <i>n</i> (%)	21 (77.8)	7 (77.8)	9 (100.0)	4 (80.0)	0	1	0
ENMG performed, <i>n</i> (%)							
Myopathic pattern, <i>n</i> (%)	16 (61.5)	4 (50.0)	8 (88.9)	3 (60.0)	0	0	1
Neurogenic pattern, <i>n</i> (%)	1 (3.8)	1 (12.5)	0	0	0	0	0
Both, <i>n</i> (%)	6 (23.1)	2 (25.0)	1 (11.1)	1 (20.0)	2 (100.0)	0	0
Imaging performed, ^b <i>n</i> (%)	9 (33.3)	2 (22.2)	3 (33.3)	2 (40.0)	0	1	1
Muscle biopsy performed, <i>n</i> (%)							
Treatment at biopsy, <i>n</i> (%)	6 (22.2)	0	2 (22.2)	3 (60.0)	1 (50.0)	0	0
Diagnosis accuracy score, median (IQR)	7.0 (3.0–8.0)	5.0 (2.0–9.0)	7.0 (7.0–7.8)	4.0 (2.5–5.3)	8.0 (8.0–8.0)	N/A	N/A

^a Other refers to the patient with anti-Hu antibodies.

^b Imaging included either imaging of head and neck muscles or of thoracolumbar muscles.

CC: camptocormia; CK: creatine kinase; DHS: dropped head syndrome; ENMG: electroneuromyography; ICU: intensive care unit; IQR: interquartile range; irMyositis: myositis induced by immune checkpoint inhibitors; N/A: not applicable; OM: overlap myositis; ULN: upper limit of the normal range.

inflammation was found in two patients (22.2%), atrophy in four patients (44.4%) and fat replacement in six patients (66.7%). Muscle biopsy was performed for all patients; for six of these (22.2%) this was taken while the patient was under immunosuppressive/immunomodulatory treatments (Table 1). Muscle biopsy was performed in various muscles: semi-spinalis ($n=1$, 3.7%), deltoid ($n=12$, 44.4%), biceps ($n=4$, 14.8%), quadriceps ($n=6$, 22.2%), gastrocnemius ($n=1$, 3.7%) or tibialis anterior ($n=1$, 3.7%); the biopsy site was unknown for two patients (7.4%). Eighteen of these muscle biopsies were available for blind analysis. Myofibres were atrophic in 16 patients, fibrotic in five patients, and necrotic in 12 patients. Inflammation was found in 10 muscle biopsies with various topographies and compositions. MHC-I was overexpressed in all but one biopsy tested (Supplementary Table S1, available at *Rheumatology* online). The median diagnosis accuracy score established on each muscle biopsy was 7.0/10 (3.0–8.0) (Table 1).

Diagnosis of IM subgroups

The six IM subgroups found in the cohort were: IBM in nine (33.3%), OM in nine (33.3%), DM in five (18.5%), irMyositis in two (7.4%), FM in one (3.7%, semi-spinalis), and myositis with anti-Hu antibodies in one patient (3.7%). Three of the nine patients (33.3%) finally diagnosed with IBM were first diagnosed as having ALS. Cases of irMyositis were consecutive to anti-PD1 or anti-PDL1 therapy, prescribed for metastatic lung adenocarcinoma. The median (IQR) age at first symptoms ranged from 56.0 years (33.0–65.0) in OM to 76.0 years (75.0–78.0) in IBM and 76.5 years (75.3–77.8) in irMyositis. Age at first symptoms was ≤ 70 years in 16 patients (59.3%), including all DM patients and 8/9 OM patients (88.9%), whereas this was the case in 1/9 IBM patients (11.1%; Table 1). The median (IQR) interval between first symptoms and IM diagnosis was 0.0 years (0.0–0.5) in DM and reached 3.0 years (2.0–4.0) in IBM. Physical examination found diffuse axial involvement (DHS+CC) in 8/9 OM patients (88.9%), 3/5 DM patients (60.0%), 4/9 IBM patients (44.4%). The two patients with irMyositis and the FM patient had a DHS without CC. Axial muscle impairment-related complications concerned both patients with irMyositis, 2/5 DM patients (40.0%), 3/9 IBM and 3/9 OM patients (both 33.3%). ANA were found in all nine OM patients, in 4/5 DM patients (80.0%), and in 7/9 IBM patients (77.8%; Table 1). Among the nine OM, anti-U1RNP was found in two patients; among the seven IBM patients, anti-SSA were found in two patients (52 kDa in one, 60 kDa in one), anti-Scl70 in one patient, anti-PCNA in one patient, and anti-PCNA-like in one patient. Anti-MSA were found in four patients; anti-MDA5 in one DM patient, anti-NXP2 in one DM patient, anti-cN1a in two IBM patients. Three OM patients had anti-PM/Scl auto-antibodies, one OM patient had anti-NOR90 auto-antibodies, and one anti-Hu auto-antibodies. ENMG found a myopathic pattern in 8/9 OM patients (88.9%), in 3/5 DM patients (60.0%), and in 4/8 IBM patients (50.0%). Blinded review of muscle biopsies revealed that the diagnosis accuracy score ranged from a median score of 4.0/10 (2.5–5.3) for DM to 8.0/10 for irMyositis (Table 1). Of note, among the four DM biopsies available, three were performed under treatment.

Treatments

All but four IBM patients (14.8%) were treated during follow-up. Twenty-one patients (77.8%) received first-line treatments; all of these patients received corticosteroids, 10/

21 MTX (47.6%), 7/21 MMF (33.3%) and 5/21 AZA (23.8%). Twenty patients (74.1%) received second-line treatments; all of these patients received IVIG, and three RTX (15.0%). Second-line treatments were used in 8/9 OM patients (88.9%), in 4/5 DM patients (80.0%) and in 5/9 IBM patients (55.6%; Table 2). Among the total population, two (7.4%) patients received third-line treatments; these were both DM patients: CYC in both of them, and PE in one. The median (IQR) number of treatments received during follow-up was 3.0 (1.5–4.0) and ranged from 1.0 (0.0–2.0) in IBM to 3.0 (3.0–4.0) in DM and OM patients. Fifteen patients (55.6%) remained treated at last visit, including 8/9 OM patients (88.9%) and 3/5 DM patients (60.0%). Treatments were discontinued in 7/9 IBM patients (77.8%; Table 2). All 16 patients who were aged ≤ 70 years at first symptoms were treated, except one IBM patient; 13/16 patients (81.3%) received second-line treatments and 2/16 patients (12.5%) third-line treatments; 13/16 patients (81.3%) remained treated at last visit. All but three patients aged >70 years at first symptoms were treated; 7/11 patients (63.6%) received second-line treatments, and none third-line treatment; 2/11 patients (18.2%) remained treated at last visit.

Outcomes

At last visit, IM remained active in three patients (11.1%), including 2/9 OM patients (22.2%) and the patient with anti-Hu antibodies. IM was stable in nine patients (33.3%), including 6/9 IBM patients (66.7%) and 3/9 OM patients (33.3%). Partial remission was obtained in 14 patients (51.9%) and complete remission in one patient (3.7%); all those with DM or irMyositis had either partial or complete remission (Table 2). The use of second- or third-line treatments *vs* first-line treatments was not significantly associated with partial/complete improvement ($P=0.73$, Fisher's exact test). Regarding DHS/CC, complete regression of axial muscle involvement was observed in three patients (11.1%), including 2/5 patients with DM (40.0%) and 1/9 with OM (11.1%). No DHS/CC remission was obtained in other patients (Table 2). In the 16 patients aged ≤ 70 years at first symptoms, partial remission was obtained in 9/16 (56.3%) and complete remission in 1/16 patient (6.3%); complete regression of DHS/CC was achieved in 3/16 patients (18.8%). Conversely, in the 11 patients aged >70 years at first symptoms, partial remission was obtained in 5/11 patients (45.5%), and the disease was stable in 6/11 patients (54.5%); no complete remission was obtained nor regression of DHS/CC at last visit. Individual data are presented in Supplementary Table S2, available at *Rheumatology* online.

Discussion

Inaugural axial involvement is an atypical presentation of IM, poorly described so far. In the present study, the main diagnoses for inaugural DHS/CC were OM and IBM, followed by DM. The overwhelming majority of patients with OM and DM had first symptoms ≤ 70 years of age, required aggressive immunosuppression with potential for improvement, while those aged >70 years at first symptoms had most frequently IBM, without effective treatment. Taken together, these results suggest that the age at first symptoms was an effective parameter to delineate two groups.

IM diagnosis remains challenging when the disease is revealed by inaugural axial involvement. In the present study,

Table 2. Treatments and outcomes

	Total <i>n</i> = 27	IBM <i>n</i> = 9 (33.3%)	OM <i>n</i> = 9 (33.3%)	DM <i>n</i> = 5 (18.5%)	irMyositis <i>n</i> = 2 (7.4%)	FM <i>n</i> = 1 (3.7%)	Other ^a <i>n</i> = 1 (3.7%)
Treatment received, <i>n</i> (%)	23 (85.2)	5 (55.6)	9 (100.0)	5 (100.0)	2 (100.0)	1	1
1st line, <i>n</i> (%)	21 (77.8)	3 (33.3)	9 (100.0)	5 (100.0)	2 (100.0)	1	1
Corticosteroids, <i>n</i> (%)	21 (100.0)	3 (100.0)	9 (100.0)	5 (100.0)	2 (100.0)	1	1
MTX, <i>n</i> (%)	10 (47.6)	1 (33.3)	5 (55.6)	2 (40.0)	0	1	1
MMF, <i>n</i> (%)	7 (33.3)	0	4 (44.4)	2 (40.0)	0	0	1
AZA, <i>n</i> (%)	5 (23.8)	0	4 (44.4)	1 (20.0)	0	0	0
2nd line, <i>n</i> (%)	20 (74.1)	5 (55.6)	8 (88.9)	4 (80.0)	1 (50.0)	1	1
IVIg, <i>n</i> (%)	20 (100.0)	5 (100.0)	8 (100.0)	4 (100.0)	1 (100.0)	1	1
RTX, <i>n</i> (%)	3 (15.0)	1 (20.0)	1 (12.5)	0	0	0	1
3rd line, <i>n</i> (%)	2 (7.4)	0	0	2 (40.0)	0	0	0
CYC, <i>n</i> (%)	2 (100.0)	0	0	2 (100.0)	0	0	0
PE, <i>n</i> (%)	1 (50.0)	0	0	1 (50.0)	0	0	0
Number of treatments received, median (IQR)	3.0 (1.5-4.0)	1.0 (0.0-2.0)	3.0 (3.0-4.0)	3.0 (3.0-4.0)	1.5 (1.3-1.8)	3.0	7.0
Treatment at last visit, <i>n</i> (%)	15 (55.6)	2 (22.2)	8 (88.9)	3 (60.0)	0	1	1
Outcomes							
Disease activity							
Active disease, <i>n</i> (%)	3 (11.1)	0	2 (22.2)	0	0	0	1
Stable disease, <i>n</i> (%)	9 (33.3)	6 (66.7)	3 (33.3)	0	0	0	0
Partial remission, <i>n</i> (%)	14 (51.9)	3 (33.3)	4 (44.4)	4 (80.0)	2 (100.0)	1	0
Complete remission, <i>n</i> (%)	1 (3.7)	0	0	1 (20.0)	0	0	0
DHS/CC at last visit							
Persistent, <i>n</i> (%)	24 (88.9)	9 (100.0)	8 (88.9)	3 (60.0)	2 (100.0)	1	1
Complete regression, <i>n</i> (%)	3 (11.1)	0	1 (11.1)	2 (40.0)	0	0	0

^a Other refers to the patient with anti-Hu antibodies.

CC: camptocormia; DHS: dropped head syndrome; IQR: interquartile range; irMyositis: myositis induced by immune checkpoint inhibitors; OM: overlap myositis; PE: plasma exchanges; RTX: rituximab.

Table 3. Summary of the main published studies on axial muscle deficit

References	Type of study (number of patients)	Axial muscle weakness	Diagnoses
Ali <i>et al.</i> [11]	Retrospective cohort of all adult patients evaluated at Mayo Clinic Rochester with a diagnosis of camptocormia (CC) (276 patients)	CC	<ol style="list-style-type: none"> 1. Neuromuscular and musculoskeletal disorders ($n = 133$, 48.2%)^a: idiopathic axial myopathy ($n = 39$, 14.1%), degenerative joint disease ($n = 36$, 13.0%), amyotrophic lateral sclerosis ($n = 26$, 9.4%), facioscapulohumeral muscular dystrophy ($n = 7$, 2.5%), inflammatory myopathy (IM) ($n = 6$, 2.2%), myasthenia gravis ($n = 5$, 1.8%), inclusion body myositis (IBM) ($n = 4$, 1.5%). 2. Central nervous system and neurodegenerative diseases ($n = 114$, 41.3%)^a: idiopathic Parkinson's disease ($n = 62$, 22.5%), dystonia ($n = 20$, 7.3%), multiple system atrophy ($n = 16$, 5.8%), Lewy body disease ($n = 9$, 3.3%). 3. Miscellaneous/rare diseases ($n = 17$, 6.2%). 4. Immune-mediated diseases ($n = 7$, 2.5%). 5. Drug-induced diseases ($n = 5$, 1.8%). <p>Of note, 40/276 patients (14.5%) also had dropped head syndrome (DHS).</p>
Drain <i>et al.</i> [13]	Systematic review of the literature reporting underlying pathology for DHS and applied a specific treatment regimen with outcome data (129 patients, 74 studies)	DHS	<ol style="list-style-type: none"> 1. Isolated neck extensor myopathy ($n = 41$, 31.8%). 2. Parkinson's disease ($n = 26$, 20.2%). 3. Myasthenia gravis ($n = 16$, 12.4%). 4. Amyotrophic lateral sclerosis ($n = 9$, 7.0%). 5. Drug-induced, endocrine/electrolyte abnormality, radiation-induced ($n = 5$, 3.9% respectively). 6. Scleroderma ($n = 4$, 3.1%). 7. Polymyositis ($n = 3$, 2.3%). 8. Other ($n = 15$, 11.6%).
Alhammad <i>et al.</i> [12]	Retrospective cohort of adult patients with a myopathy presenting with DHS at the Mayo Clinic (107 patients)	Inaugural DHS	<ol style="list-style-type: none"> 1. IM ($n = 16$, 15.0%). 2. Myopathy with rimmed vacuoles ($n = 10$, 9.3%). 3. Radiation-induced myopathy ($n = 8$, 7.5%). 4. Sporadic late onset nemaline myopathy ($n = 7$, 6.5%). 5. Myofibrillar myopathy ($n = 4$, 3.7%). 6. Facioscapulohumeral muscular dystrophy ($n = 3$, 2.8%). 7. IBM, mitochondrial myopathy, scleroderma-myopathy ($n = 2$, 1.9%, respectively). 8. Myopathy not otherwise specified ($n = 50$, 46.7%) <p>Of note, 15/107 patients (14.0%) also had CC.</p>
Ghosh <i>et al.</i> [14]	Retrospective cohort of patients with myopathy presenting with CC at the Mayo Clinic (52 patients)	CC	<ol style="list-style-type: none"> 1. Acquired myopathy ($n = 11$, 21.2%): sporadic IBM ($n = 5$), IM ($n = 2$), necrotizing auto-immune myopathy ($n = 2$), sporadic late onset nemaline myopathy ($n = 2$). 2. Genetically proven myopathy ($n = 9$, 17.3%): facioscapulohumeral muscular dystrophy 1 ($n = 7$), myotonic dystrophy 1 ($n = 1$), Pompe disease ($n = 1$). 3. Other ($n = 3$, 5.8%): vacuolar myopathy ($n = 2$), mitochondrial myopathy ($n = 1$). 4. Myopathy not otherwise specified ($n = 29$, 55.8%). <p>Of note, 15/52 patients (28.8%) also had DHS.</p>

(continued)

Table 3. (continued)

References	Type of study (number of patients)	Axial muscle weakness	Diagnoses
Watanabe <i>et al.</i> [40] Noguchi <i>et al.</i> [41]	Prospective cohort of IM patients in Japan (460 patients)	DHS ^b	1. IM patients with anti-single recognition particle (anti-SRP) ($n = 48/68$, 70.6%). 2. IM patients with anti-3-hydroxy-3-methylglutaryl-coenzyme A reductase (anti-HMGCR) ($n = 20/45$, 44.4%). 3. IM patients with antisynthetase syndrome ($n = 17/51$, 33.3%): patients with anti-OJ ($n = 8/14$, 57.1%), patients with anti-Jo-1 or anti-PL-7 or anti-PL-12 ($n = 9/37$, 24.3%).
Mariampillai <i>et al.</i> [2]	Retrospective cohort based on the French myositis network (361 patients)	DHS±CC ^b	1. Dermatomyositis ($n = 46/70$, 65.7%). 2. IBM ($n = 65/106$, 62.5%). 3. Polymyositis ($n = 106/185$, 57.6%).
Leclair <i>et al.</i> [32]	Prospective cohort of patients with scleromyositis based on the Canadian Inflammatory Myopathy Study group (42 patients)	DHS±CC ^b	Scleromyositis ($n = 12/42$, 28.6%); including 4/8 patients (50.0%) with systemic sclerosis (SSc) specific antibodies (i.e. anti-centromere, anti-topoisomerase 1, anti-RNA polymerase III, anti-Th/To, anti-fibrillarin), 1/14 patients (7.0%) with SSc-overlap antibodies (i.e. anti-PM/Scl, anti-Ku, anti-U1RNP), 7/20 patients (35.0%) without SSc-related antibodies.
Gallay <i>et al.</i> [5]	Retrospective cohort of patients with focal myositis (FM) (34 patients)	DHS±CC ^b	FM of head or neck muscles ($n = 3/34$, 8.8%).
Rigolet <i>et al.</i> [42]	Retrospective cohort of patients with anti-Ku antibodies (30 patients)	DHS±CC ^b	IM with anti-Ku antibodies ($n = 5/11$, 45.5%).
Touat <i>et al.</i> [33]	Retrospective cohort of patients with immune-checkpoint inhibitor-related myositis (irMyositis) (10 patients)	DHS ^b	IrMyositis ($n = 7$, 70.0%).

^a Diagnoses with a frequency $\geq 1.5\%$ are indicated.

^b The study of the axial deficit was not the main objective of the study but we extracted the number of patients with such muscle involvement to illustrate axial muscle weakness frequency in IM. The bold text corresponds to inflammatory myopathy subtypes.

CC: camptocormia; DHS: dropped head syndrome; FM: focal myositis; HMGCR: 3-hydroxy-3-methylglutaryl-coenzyme A reductase; IM: inflammatory myopathy; irMyositis: myositis induced by immune checkpoint inhibitors; SRP: single recognition particle.

the initial DHS/CC presentation led to a delay between IM onset and diagnosis compared with the expected in IM as the median interval is reported to be 3 [23] or 6 months [24]. This could be explained by inaugural axial presentation being very infrequent in IM and no dedicated study on this topic has been reported. In particular, axial muscle weakness can also be the presenting feature of a broad range of diseases, foremost among which are Parkinson's disease, hereditary myopathy, myasthenia gravis and ALS [11, 13] as summarized in Table 3. Herein, a third of cases of IBM had initially been misdiagnosed as ALS, a very common cause of CC and DHS, responsible for delayed diagnosis and care, not to mention the psychological consequences, illustrating the diagnostic challenge in such patients.

The present study suggests that when axial muscle involvement is inaugural in a patient suspected of IM, the main diagnoses to consider are first and foremost IBM, OM and DM. This modifies the spectrum of diagnoses to investigate; in particular, it is of note that no case of ASyS or INMN was found although they account for, respectively, 15.0% and 21.9% of IM cases [2]. This is of importance for clinicians as DHS/CC is an atypical presentation of IBM (only 0.84% of patients with this disease have axial weakness at diagnosis [6]) and has been reported as the inaugural muscular manifestation in only a few case reports of both OM [25–29] and DM patients [30, 31]; however, there are reports of axial deficit occurring in 62.5% of IBM patients [2], 28.6% of OM patients and 65.7% of DM patients during follow-up [2, 32], which could suggest a certain level of underdiagnosis. The frequency of axial muscle weakness in each IM subtype during follow-up is presented in Table 3.

The present study identified patient characteristics that can help clinicians to diagnose patients presenting with DHS/CC. First, age at first IM symptoms delineated two groups of patients; those aged ≤ 70 years had mostly OM and DM, and older patients had mostly IBM and irMyositis, which is in accordance with the expected age of symptom onset for the respective IM [2, 32, 33]. The second useful parameter for diagnosis was the diffuse or selective involvement of axial muscles: OM and DM patients had frequently a diffuse involvement of axial muscles (i.e. DHS+CC) while irMyositis presented DHS alone as previously reported [33]. These findings call for a standardized clinical assessment of axial muscles which has recently been proposed [34]. In addition, ENMG may help confirm a myogenic process and exclude myasthenia gravis and ALS [35]. However, ENMG of axial muscles is particularly difficult to interpret [34], and this may explain the low number of patients who underwent axial muscle ENMG in the present study. Similarly, only a few patients had imaging of axial muscles; most patients had atrophy and fat replacement but direct signs of myositis were scarce, indicating that IM diagnosis should not be eliminated based only on these findings. However, a recent study proposed features that can help to identify subclinical muscle inflammation and to evaluate muscle damage [36], which may lead to better accuracy of imaging interpretation for the diagnosis of IM in the future. Muscle histology was found to be more valuable than ENMG or imaging; it facilitated the diagnosis of IM but also that of the IM subgroup, except for DM patients herein who had been treated before the biopsy and for whom the diagnosis accuracy score was low. In addition, all OM patients of the present study were found to have ANA but for only a quarter of these the auto-antibody was

identified, suggesting that there are auto-antibodies remain to be discovered.

Another point to note is that most patients included herein received second-line treatments and infrequently complete DHS/CC regression; in addition, axial muscle impairment-related complications (i.e. malnutrition, aspiration pneumonia, ICU admission) concerned almost half of the patients, and these are associated with further disease progression and mortality [37]. Thus, reducing diagnosis delay and improving care management are key factors to prevent the occurrence of these complications. To this aim, the age at first symptoms may help the clinician to identify patients for whom medication has to be promptly started with a possible improvement of axial muscle weakness, as illustrated by OM and DM patients in this retrospective study. Conversely, the results emphasize the poor effectiveness of treatments in IBM; none of the IBM patients presented a regression of DHS/CC nor a remission of the disease, questioning the use of immunosuppressive treatments in such patients [38]. In any case, medical treatments must be accompanied by specific rehabilitation as soon as the axial deficit appears [39].

The present study is limited by its retrospective design. For instance, some muscle biopsies were not available for review, and the heterogeneity of the management of IM patients with inaugural axial muscle weakness limited some conclusions. In addition, the small number of patients illustrated the rarity of this condition and did not allow us to investigate clinical improvement according to therapeutic strategy. Nevertheless, this is the first study to specifically address the inaugural axial involvement in IM so far.

In conclusion, the analysis of IM patients with inaugural DHS/CC delineates two groups of patients according to the age at first symptoms in terms of clinical and outcome specificities, and proposes an adapted diagnostic and care management approach to prevent long-term complications.

Supplementary material

Supplementary material is available at *Rheumatology* online.

Data availability

Data are available within the article or its [supplementary materials](#), or at request to the corresponding author.

Funding

M.R. is supported by the Ecole de l'Inserm Liliane Bettencourt Programme and L.E.R.L. by the Fondation pour la Recherche Médicale.

Disclosure statement: The authors have declared no conflicts of interest.

References

1. De Bleecker JL, De Paepe B, Aronica E *et al.*; 205th ENMC International Workshop: pathology diagnosis of idiopathic inflammatory myopathies part II 28–30 March 2014, Naarden, The Netherlands. *Neuromuscul Disord* 2015;25:268–72.
2. Mariampillai K, Granger B, Amelin D *et al.* Development of a new classification system for idiopathic inflammatory myopathies based

- on clinical manifestations and myositis-specific autoantibodies. *JAMA Neurol* 2018;75:1528–37.
3. Lundberg IE, Fujimoto M, Vencovsky J *et al*. Idiopathic inflammatory myopathies. *Nat Rev Dis Primers* 2021;7:86.
 4. Allenbach Y, Anquetil C, Manouchehri A *et al*. Immune checkpoint inhibitor-induced myositis, the earliest and most lethal complication among rheumatic and musculoskeletal toxicities. *Autoimmun Rev* 2020;19:102586.
 5. Gallay L, Hor A, Petiot P *et al*. Focal myositis: new insights on diagnosis and pathology. *Neurology* 2018;90:e1013–e20.
 6. Alamr M, Pinto MV, Naddaf E. Atypical presentations of inclusion body myositis: clinical characteristics and long-term outcomes. *Muscle Nerve* 2022;66:686–93.
 7. Harris-Love MO, Shrader JA, Koziol D *et al*. Distribution and severity of weakness among patients with polymyositis, dermatomyositis and juvenile dermatomyositis. *Rheumatology (Oxford)* 2009;48:134–9.
 8. Suarez GA, Kelly JJ Jr. The dropped head syndrome. *Neurology* 1992;42:1625–7.
 9. Kocaaga Z, Bal S, Turan Y *et al*. Camptocormia and dropped head syndrome as a clinic picture of myotonic myopathy. *Joint Bone Spine* 2008;75:730–3.
 10. Oerlemans WG, de Visser M. Dropped head syndrome and bent spine syndrome: two separate clinical entities or different manifestations of axial myopathy? *J Neurol Neurosurg Psychiatry* 1998;65:258–9.
 11. Ali F, Matsumoto JY, Hassan A. Camptocormia: etiology, diagnosis, and treatment response. *Neurol Clin Pract* 2018;8:240–8.
 12. Alhammad RM, Naddaf E. Myopathies presenting with head drop: clinical spectrum and treatment outcomes. *Neuromuscul Disord* 2020;30:128–36.
 13. Drain JP, Virk SS, Jain N *et al*. Dropped head syndrome: a systematic review. *Clin Spine Surg* 2019;32:423–9.
 14. Ghosh PS, Milone M. Camptocormia as presenting manifestation of a spectrum of myopathic disorders. *Muscle Nerve* 2015;52:1008–12.
 15. Lundberg IE, Tjärnlund A, Bottai M *et al*. 2017 European League Against Rheumatism/American College of Rheumatology classification criteria for adult and juvenile idiopathic inflammatory myopathies and their major subgroups. *Ann Rheum Dis* 2017;76:1955–64.
 16. Lloyd TE, Mammen AL, Amato AA *et al*. Evaluation and construction of diagnostic criteria for inclusion body myositis. *Neurology* 2014;83:426–33.
 17. Mammen AL, Allenbach Y, Stenzel W *et al*. 239th ENMC International Workshop: classification of dermatomyositis, Amsterdam, the Netherlands, 14–16 December 2018. *Neuromuscul Disord* 2020;30:70–92.
 18. Allenbach Y, Mammen AL, Benveniste O *et al*. 224th ENMC International Workshop: clinico-sero-pathological classification of immune-mediated necrotizing myopathies Zandvoort, The Netherlands, 14–16 October 2016. *Neuromuscul Disord* 2018;28:87–99.
 19. Landon-Cardinal O, Devilliers H, Chavarot N *et al*. Responsiveness to change of 5-point MRC scale, endurance and functional evaluation for assessing myositis in daily clinical practice. *J Neuromuscul Dis* 2019;6:99–107.
 20. Picard C, Vincent T, Lega JC *et al*. Heterogeneous clinical spectrum of anti-SRP myositis and importance of the methods of detection of anti-SRP autoantibodies: a multicentric study. *Immunol Res* 2016;64:677–86.
 21. Uro-Soste E, Fernandez C, Authier FJ *et al*. Management of muscle and nerve biopsies: expert guidelines from two French professional societies, Societe francaise de myologie et de l'Association francaise contre les myopathies. *Rev Neurol (Paris)* 2010;166:477–85.
 22. Uruha A, Goebel HH, Stenzel W. Updates on the immunopathology in idiopathic inflammatory myopathies. *Curr Rheumatol Rep* 2021;23:56.
 23. Oddis CV, Conte CG, Steen VD *et al*. Incidence of polymyositis-dermatomyositis: a 20-year study of hospital diagnosed cases in Allegheny County, PA 1963–1982. *J Rheumatol* 1990;17:1329–34.
 24. Weitof T. Occurrence of polymyositis in the county of Gavleborg, Sweden. *Scand J Rheumatol* 1997;26:104–6.
 25. Kono M, Komai T, Yuki H *et al*. Anti-Ku antibody-positive myositis presenting as a wide range of axial myopathies and myocarditis: a case report and review of the literature. *Mod Rheumatol Case Rep* 2022;6:64–8.
 26. Zenone T, Streichenberger N, Puget M. Camptocormia as a clinical manifestation of polymyositis/systemic sclerosis overlap myositis associated with anti-Ku. *Rheumatol Int* 2013;33:2411–5.
 27. Yoshida T, Yoshida M, Mitsuyo K *et al*. Dropped head syndrome and the presence of rimmed vacuoles in a muscle biopsy in scleroderma-polymyositis overlap syndrome associated with anti-ku antibody. *Intern Med* 2018;57:887–91.
 28. De Almeida Chaves S, Moulis G, Pugnet G *et al*. Camptocormia with trigeminal involvement revealing myositis with anti-Ku antibodies. *Joint Bone Spine* 2019;86:111–2.
 29. Garcin B, Lenglet T, Dubourg O *et al*. Dropped head syndrome as a presenting sign of scleromyositis. *J Neurol Sci* 2010;292:101–3.
 30. Slobodin G, Rozenbaum M, Weller B *et al*. Dropped head: an unusual presentation of dermatomyositis. *J Rheumatol* 2005;32:1174–5.
 31. Koh ET, Seow A, Ong B *et al*. Adult onset polymyositis/dermatomyositis: clinical and laboratory features and treatment response in 75 patients. *Ann Rheum Dis* 1993;52:857–61.
 32. Leclair V, D'Aoust J, Gyger G *et al*. Autoantibody profiles delineate distinct subsets of scleromyositis. *Rheumatology (Oxford)* 2022;61:1148–57.
 33. Touat M, Maisonobe T, Knauss S *et al*. Immune checkpoint inhibitor-related myositis and myocarditis in patients with cancer. *Neurology* 2018;91:e985–94.
 34. Waheed W, Allison JB, Dewitt J *et al*. Axial muscle weakness. *Pract Neurol* 2021;21:92–100.
 35. Sener U, Martinez-Thompson J, Laughlin RS *et al*. Needle electromyography and histopathologic correlation in myopathies. *Muscle Nerve* 2019;59:315–20.
 36. Matsuda N, Kobayashi S, Hasegawa O *et al*. Subclinical involvement of the trunk muscles in idiopathic inflammatory myopathies. *Acta Radiol Open* 2022;11:20584601221075796.
 37. Marie I, Hachulla E, Hatron PY *et al*. Polymyositis and dermatomyositis: short term and longterm outcome, and predictive factors of prognosis. *J Rheumatol* 2001;28:2230–7.
 38. Naddaf E. Inclusion body myositis: update on the diagnostic and therapeutic landscape. *Front Neurol* 2022;13:1020113.
 39. Suzuki A, Ishii K, Igawa T *et al*. Effect of the short and intensive rehabilitation (SHAiR) program on dynamic alignment in patients with dropped head syndrome during level walking. *J Clin Neurosci* 2021;91:93–8.
 40. Watanabe Y, Uruha A, Suzuki S *et al*. Clinical features and prognosis in anti-SRP and anti-HMGCR necrotising myopathy. *J Neurol Neurosurg Psychiatry* 2016;87:1038–44.
 41. Noguchi E, Uruha A, Suzuki S *et al*. Skeletal muscle involvement in antisynthetase syndrome. *JAMA Neurol* 2017;74:992–9.
 42. Rigolet A, Musset L, Dubourg O *et al*. Inflammatory myopathies with anti-Ku antibodies: a prognosis dependent on associated lung disease. *Medicine (Baltimore)* 2012;91:95–102.
 43. Fasano A, Geroi C, Berardelli A *et al*. Diagnostic criteria for camptocormia in Parkinson's disease: a consensus-based proposal. *Parkinsonism Relat Disord* 2018;53:53–7.