



**HAL**  
open science

## Impact of the diaphyseal femoral deformity on the lower limb alignment in osteoarthritic varus knees

Cécile Batailler, Alexandre Naaim, Jeremy Daxhelet, Sébastien Lustig,  
Matthieu Ollivier, Sebastien Parratte

### ► To cite this version:

Cécile Batailler, Alexandre Naaim, Jeremy Daxhelet, Sébastien Lustig, Matthieu Ollivier, et al.. Impact of the diaphyseal femoral deformity on the lower limb alignment in osteoarthritic varus knees. *Bone & Joint Open*, 2023, 4 (4), pp.262-272. 10.1302/2633-1462.44.BJO-2023-0024.R1 . hal-04480939

**HAL Id: hal-04480939**

**<https://hal.science/hal-04480939>**

Submitted on 27 Feb 2024

**HAL** is a multi-disciplinary open access archive for the deposit and dissemination of scientific research documents, whether they are published or not. The documents may come from teaching and research institutions in France or abroad, or from public or private research centers.

L'archive ouverte pluridisciplinaire **HAL**, est destinée au dépôt et à la diffusion de documents scientifiques de niveau recherche, publiés ou non, émanant des établissements d'enseignement et de recherche français ou étrangers, des laboratoires publics ou privés.

## ■ KNEE

# Impact of the diaphyseal femoral deformity on the lower limb alignment in osteoarthritic varus knees

**C. Batailler,  
A. Naaim,  
J. Daxhelet,  
S. Lustig,  
M. Ollivier,  
S. Parratte**

*From International Knee  
and Joint Centre, Abu  
Dhabi, United Arab  
Emirates*

### Aims

The impact of a diaphyseal femoral deformity on knee alignment varies according to its severity and localization. The aims of this study were to determine a method of assessing the impact of diaphyseal femoral deformities on knee alignment for the varus knee, and to evaluate the reliability and the reproducibility of this method in a large cohort of osteoarthritic patients.

### Methods

All patients who underwent a knee arthroplasty from 2019 to 2021 were included. Exclusion criteria were genu valgus, flexion contracture ( $> 5^\circ$ ), previous femoral osteotomy or fracture, total hip arthroplasty, and femoral rotational disorder. A total of 205 patients met the inclusion criteria. The mean age was 62.2 years (SD 8.4). The mean BMI was 33.1 kg/m<sup>2</sup> (SD 5.5). The radiological measurements were performed twice by two independent reviewers, and included hip knee ankle (HKA) angle, mechanical medial distal femoral angle (mMDFA), anatomical medial distal femoral angle (aMDFA), femoral neck shaft angle (NSA), femoral bowing angle (FBow), the distance between the knee centre and the top of the FBow (DK), and the angle representing the FBow impact on the knee (C'KS angle).

### Results

The FBow impact on the mMDFA can be measured by the C'KS angle. The C'KS angle took the localization (length DK) and the importance (FBow angle) of the FBow into consideration. The mean FBow angle was 4.4° (SD 2.4; 0 to 12.5). The mean C'KS angle was 1.8° (SD 1.1; 0 to 5.8). Overall, 84 knees (41%) had a severe FBow ( $> 5^\circ$ ). The radiological measurements showed very good to excellent intraobserver and interobserver agreements. The C'KS increased significantly when the length DK decreased and the FBow angle increased ( $p < 0.001$ ).

### Conclusion

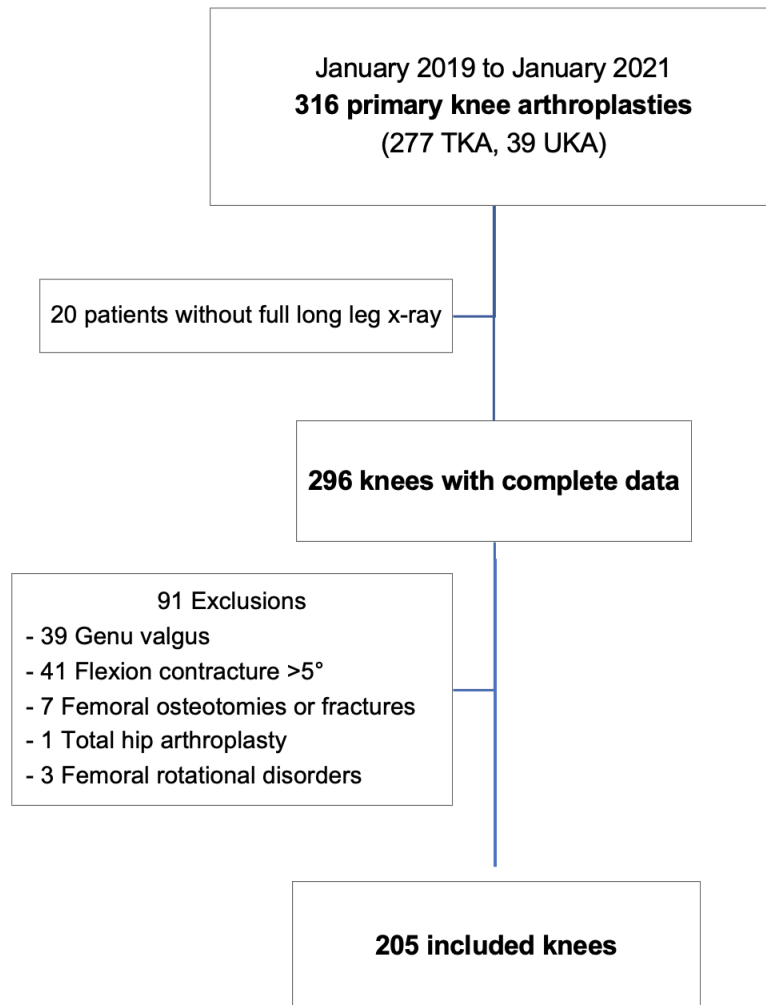
The impact of the diaphyseal femoral deformity on the mechanical femoral axis is measured by the C'KS angle, a reliable and reproducible measurement.

**Keywords:** Knee arthroplasty, Femoral bowing, Lower limb alignment, Mechanical distal femoral angle, Extra-articular deformity

### Introduction

Personalized medicine has been brought to the fore over the last few years. Knee surgery also tends to be adjusted to each patient, such as with the personalized alignment in knee arthroplasty,<sup>1,2</sup> or the double-level osteotomy in conservative knee surgery.<sup>3</sup> Several recent classifications have been published to describe limb alignment, and femoral and tibial axis in non-osteoarthritic and

osteoarthritic populations.<sup>4</sup> A new classification for the lower limb alignment based on phenotypes was introduced<sup>5</sup> to identify the localization of the deformity (tibial, femoral, or both).<sup>6,7</sup> Thanks to these analyses, several authors have reported that the varus deformity is mainly due to the femoral axis in the osteoarthritic knee.<sup>8,9</sup> Indeed, the tibial coronal alignment was similar between osteoarthritic and non-osteoarthritic populations.<sup>8</sup>



**Fig. 1**

Patient flowchart. TKA, total knee arthroplasty; UKA, unicompartmental knee arthroplasty.

By contrast, there was a broader and more varus distribution of the femoral coronal alignment in the osteoarthritic population compared to the non-osteoarthritic population.<sup>8,9</sup> Thienpont and Parvizi<sup>10</sup> have also clarified the type of deformity with a new classification for the varus knee, describing intra-articular, metaphyseal, or diaphyseal deformities.

These classifications are interesting, but their clinical application might be limited. Indeed, to our knowledge, no study has precisely assessed the impact of each deformity (intra-articular, metaphyseal, or diaphyseal) on lower limb alignment and therefore what should or not be corrected, and where, during knee surgery. The impact of each extra-articular (metaphyseal or diaphyseal) deformity on the final alignment is not yet precisely understood. In 1991, Wolff et al<sup>11</sup> described that the impact of a deformity on the knee alignment varies according to the

level and severity of the deformity. For example, a deformity of 10° close to the knee will have a more significant impact than the same amount of deformity far from the knee.<sup>12</sup> This seems even more crucial for patients with severe femoral bowing in the coronal plane, which is the most common constitutional diaphyseal femoral deformity, mainly in Middle Eastern or Asian populations.<sup>13-15</sup>

Therefore, this radiological study aimed to 1) determine a method assessing the impact of the diaphyseal femoral deformity on lower limb alignment for the varus knee (on full-leg radiograph), 2) to evaluate the reliability and the reproducibility of this method in a large cohort of patients, and 3) to determine the main anatomical factors influencing the lower limb alignment and the mechanical femoral axis. We hypothesized that the impact of the diaphyseal femoral deformity (according to its localization and severity) on the knee alignment could be determined

**Table I.** Preoperative demographic and clinical data in the whole cohort, in the group with a mild femoral bowing (< 5°) and in the group with a severe femoral bowing (> 5°).

Variable	Whole cohort	Cohort with FBow < 5°	Cohort with FBow > 5°	p-value
Knees, n	205	121	84	
Mean age, yrs (SD; range)	62.2 (8.4; 41 to 87)	61.7 (8.7; 41 to 87)	62.8 (8.1; 47 to 84)	0.382*
Mean BMI, kg/m <sup>2</sup> (SD; range)	33.1 (5.5; 20.9 to 51.3)	32.4 (4.9; 20.9 to 45.3)	34.0 (6.3; 25.1 to 51.3)	0.051*
Side (right), n (%)	101 (49.3)	59 (48.8)	42 (50)	0.861†
Sex (male), n (%)	74 (36.1)	43 (35.5)	26 (31)	0.494†
<b>Ethnicity, n (%)</b>				0.031†
Middle Eastern	164 (80)	97 (80.2)	67 (79.8)	
Asian	20 (9.8)	7 (5.8)	13 (15.5)	
Caucasian	12 (5.9)	10 (8.3)	2 (2.4)	
African	9 (4.4)	7 (5.8)	2 (2.4)	
Mean flexion, ° (SD; range)	119 (9.7; 90 to 135)	121 (7.8; 100 to 135)	115 (11; 90 to 130)	< 0.001*
Mean flexion contracture, ° (SD; range)	2.6 (2.5; 0 to 5)	2.3 (2.5; 0 to 5)	2.9 (2.5; 0 to 5)	0.132*
<b>Osteoarthritis stage (Ahlback), n (%)</b>				0.045†
2	1 (0.4)	1 (0.8)	0	
3	63 (30.7)	44 (36.4)	19 (22.6)	
4	141 (68.9)	76 (62.8)	65 (77.4)	

\*Independent-samples *t*-test.

†Chi-squared test.

FBow, femoral bowing angle; SD, standard deviation.

**Table II.** Measurements performed during this study with the normal range described in the literature.

Measurements	Description	Normal range
HKA	Angle between the hip centre, the knee centre, and the ankle centre.	177° to 183°
MPTA	Angle between a line down the shaft of the tibia and a line across the top of the tibial condyles.	85° to 90°
mMDFA	Medial angle formed between the mechanical axis line of the femur (HK) and the knee joint line of the femur in the frontal plane. <sup>12,18,19</sup>	90° to 95°
aMDFA	Medial angle formed between the distal femoral shaft axis and the knee joint line of the femur in the frontal plane. <sup>20</sup>	97° to 101°
JLCA	Angle between the knee joint lines of the distal femur and proximal tibia. <sup>4</sup>	0° to 2°
HKS angle	Angle between the mechanical axis line of the femur (between the hip centre and the knee centre) and the distal femoral shaft axis. <sup>21</sup>	5° to 8°
NSA	Angle of intersection between the femoral neck axis and the proximal femoral shaft axis.	125° to 135°
FBow angle	Angle between the line connecting the points bisecting the femur at 0 and 5 cm below the lowest portion of the lesser trochanter and the line connecting the points bisecting the femur at 5 cm and 10 cm above the lowest portion of the lateral femoral condyle. <sup>13</sup> A FBow angle superior to 5° was considered as a severe deformity. <sup>22</sup>	0° to 5°
C'KS angle	Angle between the distal femoral shaft axis and the line joining C' and the knee centre K.	-
HKC' angle	Angle between the mechanical axis line of the femur (between the hip centre and the knee centre) and the line joining C' and the knee centre K.	-
Length DK	Distance between the knee centre (K) and the top of the femoral bowing (Cora) (D).	-
Length DC'	Distance between the top of the femoral bowing and the top of the NSA angle (C').	-
Length HC'	Length of the femoral neck.	-

with a simple, reliable, and reproducible method for each patient on standard full-length radiographs.

## Methods

**Patients.** We retrospectively included all patients who underwent a primary knee arthroplasty (total knee arthroplasty (TKA) or unicompartmental arthroplasty (UKA)) at a single institution from January 2019 to January 2021. The choice of this population was dictated by the need to have an osteoarthritic population (needing knee surgery) and to have all demographic, clinical, and radiological data. Exclusion criteria were preoperative genu

valgus defined as hip knee ankle (HKA) angle superior to 180°; preoperative flexion contracture superior to 5° (which can introduce a bias in the measurement of the femoral bowing);<sup>16</sup> previous femoral osteotomy or fracture (with the risk of rotation disorder); previous total hip arthroplasty in the operated side; or a known clinical or radiological femoral rotational disorder. Among the 316 candidates for knee arthroplasties performed between January 2019 and January 2021 (277 TKAs, 39 UKAs), 205 patients met the inclusion criteria (Figure 1). The mean age was 62.2 years (standard deviation (SD) 8.4), the mean BMI was 33.1 kg/m<sup>2</sup> (SD 5.5), 36.1% were male

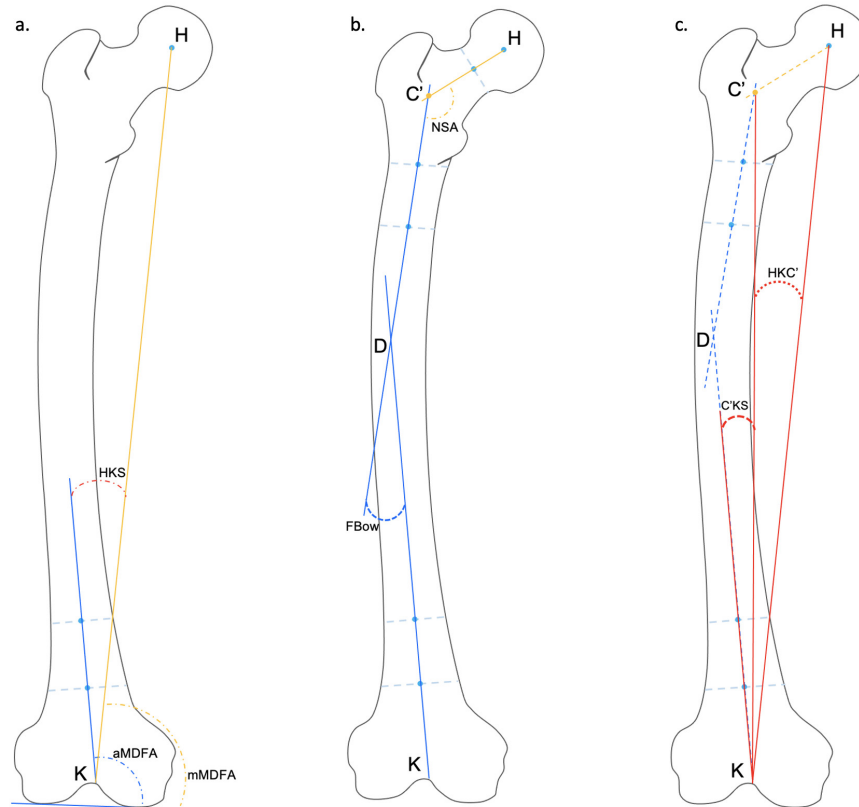


Fig. 2

Femoral radiological measurements performed on the preoperative full long-leg radiograph for each patient. aMDFA, anatomical medial distal femoral angle; C'KS angle (angle between the distal femoral shaft axis and the line joining C' and the knee centre K); FBow, femoral bowing angle; HKC' angle (angle between the mechanical axis line of the femur and the line joining C' and the knee centre K); HKS, hip knee shaft angle; mMDFA, mechanical medial distal femoral angle; NSA, femoral neck shaft angle.

Table III. Calculated and measured values of the mechanical femoral axis and the impact of the femoral bowing on the femoral axis.

Variable	Measured	Calculated	Mean difference (measured – calculated) (SD; range)	p-value*
Mean mMDFA, ° (SD)	91.4 (2.2)	91.4 (2.3)	0.04 (0.84; -2.4 to 9.6)	0.497
Mean C'KS, ° (SD)	1.8 (1.1)	1.8 (1.1)	0.03 (0.15; -0.6 to 0.5)	0.221

\*Independent-samples *t*-test.

mMDFA, mechanical medial distal femoral angle; SD, standard deviation.

( $n = 74$ ), and 49.3% were operated on the right knee ( $n = 101$ ) (Table I).

**Radiological assessment.** The radiographs were performed preoperatively as a part of the standard radiograph protocol prior to knee surgery in the same centre according to the same protocol and included: anteroposterior view, lateral view, and full long-leg radiograph. Briefly, full weightbearing long-leg standing radiographs were performed barefoot with feet placed together and the patella oriented forward to avoid rotational variation.<sup>12</sup> The following radiological measurements were performed only on the preoperative radiographs (Figures 2a and 2b): HKA angle, medial proximal tibial angle (MPTA),

mechanical medial distal femoral angle (mMDFA),<sup>17</sup> anatomical medial distal femoral angle (aMDFA), joint line convergence angle (JLCA),<sup>4</sup> hip knee shaft angle (HKS), femoral neck shaft angle (NSA), femoral bowing (FBow) angle, angle between the distal femoral shaft axis and the line joining C' and the knee centre K (C'KS angle), HKC' angle, the distance between the knee centre and the top of the femoral bowing (DK), the distance between the top of the femoral bowing and the top of the NSA angle (DC'), and the length of the femoral neck (HC'), C' being the top of the femoral NSA. The definitions of the different measurements are summarized in Table II. The diaphyseal deformity was defined by the femoral deformity localized

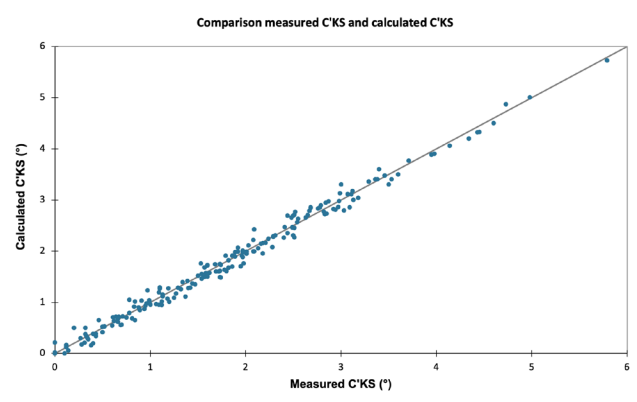


Fig. 3

Comparison of the measured and calculated values of the C'KS angle (angle between the distal femoral shaft axis and the line joining C' and the knee centre K).

between 5 cm below the lesser trochanter proximally and 10 cm above the transepicondylar axis distally.

All measurements were performed using PaxeraUltima v. 5.0.4.3 (PaxeraHealth, USA). Measurement accuracy was to one decimal place. A calibrated scale in millimetres allowed accurate and reliable measurements. The radiological measurements were performed by two independent reviewers (CB, JD) for all measurements to assess the reliability of each measurement. Discrepancies were settled by discussion between the reviewers or by a new measurement with a third reviewer (SP). To determine intraobserver variability, 40 patients were measured twice by the first observer (CB), separated by a six-week interval.

**Impact of the femoral bowing.** The FBow impact on the mechanical femoral axis (mMDFA) has been established with analytic geometry and the Al-Kashi theorem. The entire demonstration is described in the Supplementary Material. The mMDFA ('calculated mMDFA') and the FBow impact ('calculated C'KS') were calculated with this method. The FBow impact on the knee alignment can be measured by the C'KS angle (Figure 2c). The 'measured' C'KS angle took the localization (length DK) and the severity (FBow angle) of the FBow into consideration.

**Statistical analysis.** Statistical analysis was performed using the XL STAT software v. 2021.2.1 (Addinsoft, France). A p-value < 0.05 was considered statistically significant for all analyses. Patient demographics were described using means, SDs, and ranges for continuous variables, and counts (percent) for categorical variables. The cohort was separated into two groups with a mild femoral bowing (< 5°) or with a severe femoral bowing (> 5°), as described in the literature.<sup>22</sup> The categorical outcomes of the groups FBow angle < 5° and FBow angle > 5° were compared using the chi-squared test. The normally distributed continuous variables of both groups were compared using the independent-samples *t*-test. The calculated and

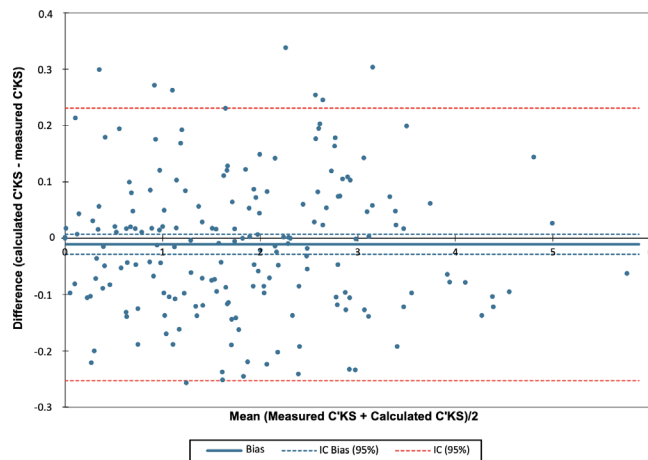


Fig. 4

Bland Altman graph for the measured C'KS angle (angle between the distal femoral shaft axis and the line joining C' and the knee centre K) and the calculated C'KS.

measured values of mMDFA and C'KS were compared by the Bland Altman method and an independent-samples *t*-test.

The inter- and intraobserver reliabilities of the radiological measurements were evaluated by an intraclass correlation coefficient. Strength of agreement for the kappa coefficient was interpreted as follows: < 0.20 = unacceptable, 0.20 to 0.39 = questionable, 0.40 to 0.59 = good, 0.60 to 0.79 = very good, and 0.80 to 1 = excellent.<sup>23</sup>

Correlations between HKA, then mMDFA, and anatomical features (aMDFA, HKC', C'KS, JLCA MPTA, FBow, DK, HC', NSA) were analyzed using the Pearson correlation coefficient, as was the correlation between C'KS and the other parameters of the femoral anatomy (NSA, HKC', FBow, DK, HC'). Simple and multiple linear regression analyses were conducted to evaluate the factors that can influence HKA and mMDFA. HKA, then mMDFA were used as dependent variables and MPTA, JLCA, aMDFA, C'KS, HKC' were used as independent variables.

## Results

**Impact of the femoral bowing on the varus deformity.** The calculated and the measured values of the C'KS angle were comparable, with a strong correlation (95% confidence interval (CI) (-0.25 to 0.23)) (Table III). According to the accuracy of the measured values (0.1°), the C'KS angle was a reliable measurement of the FBow impact on the knee (Figures 3 and 4).

The mean FBow angle was 4.4° (SD 2.4; 0° to 12.5°) in the whole cohort (Table I). A total of 84 knees (41%) had a severe FBow angle. The mean C'KS angle was 1.8° (SD 1.1; 0° to 5.8°) in the whole cohort, 1.1° (SD 0.6°) in the mild FBow group and 2.9° (SD 0.8°) in the severe FBow group (p < 0.001, independent-samples *t*-test). The HKA

**Table IV.** Radiological measurements in the whole cohort, in the group with a mild femoral bowing (< 5°) and in the group with a severe femoral bowing (> 5°).

Variable	Whole cohort	Cohort with FBow < 5°	Cohort with FBow > 5°	p-value*
Knees, n	205	121	84	
Mean HKA, ° (SD; range)	169.9 (4.2; 153 to 179.7)	170.8 (4.3; 153 to 179.7)	168.6 (3.7; 158.4 to 177.3)	< 0.001
Mean JLCA, ° (SD; range)	5.9 (2.7; 0 to 17)	5.7 (2.7; 1 to 17)	6.3 (2.6; 0 to 14)	0.149
Mean MPTA, ° (SD; range)	85.3 (2.4; 78 to 90)	85.4 (2.0; 79 to 89)	85.1 (2.8; 78 to 90)	0.314
Mean mMDFA, ° (SD; range)	91.4 (2.2; 84 to 96)	91.9 (2.1; 86 to 96)	90.7 (2.1; 84 to 96)	< 0.001
Mean aMDFA, ° (SD; range)	98.5 (2.1; 92 to 104)	98.4 (2.1; 93 to 104)	98.7 (2.2; 92 to 103)	0.226
Mean NSA, ° (SD; range)	128.9 (5.3; 116 to 141)	128.4 (5.3; 116 to 141)	129.6 (5.1; 118 to 140)	0.129
Mean HC', mm (SD; range)	49.8 (5.6; 36.3 to 67.3)	50.3 (5.3; 36.3 to 67.3)	49.2 (6.0; 37.1 to 63.9)	0.142
Mean femoral bowing, ° (SD; range)	4.4 (2.4; 0 to 12.5)	2.8 (1.3; 0 to 4.8)	6.7 (1.8; 5 to 12.5)	-
Mean DK, mm (SD; range)	244.8 (55.9; 90 to 436)	254.9 (66.2; 90 to 436)	231.3 (33.9; 166 to 332)	0.082
Mean C'D, mm (SD; range)	156.7 (51.0; 7 to 281)	145.4 (57.1; 7 to 281)	171.7 (36.9; 79 to 269)	0.035
Mean HKC', ° (SD; range)	5.3 (0.66; 3.7 to 7.0)	5.3 (0.66; 3.9 to 7.0)	5.3 (0.66; 3.7 to 6.5)	0.627
Mean C'KS, ° (SD; range)	1.8 (1.1; 0 to 5.8)	1.1 (0.6; 0 to 2.5)	2.9 (0.84; 1.1 to 5.8)	< 0.001

\*Independent-samples t-test.

aMDFA, anatomical medial distal femoral angle; C'D, length between the intersection of the femoral neck and the femoral proximal metaphyseal axis (C') and the top of the femoral bowing (D); C'KS, angle between C', the knee centre (K) and the middle of the distal femoral shaft (S); DK, length between the top of the femoral bowing (D) and the knee centre; FBow, femoral bowing; HKA, hip knee ankle angle; HKC', angle between the hip centre (H), the knee centre (K) and C'; JLCA, joint line convergence angle; mMDFA, mechanical medial distal femoral angle; MPTA, medial proximal tibial angle; NSA, neck shaft angle; SD, standard deviation.

**Table V.** Inter- and intraobserver coefficient for the radiological measurements.

Variable	Interobserver ICC	Intraobserver ICC	Agreement
HKA angle	0.81	0.89	Excellent
mMDFA	0.83	0.91	Excellent
MPTA	0.86	0.92	Excellent
aMDFA	0.65	0.80	Excellent
HKS	0.72	0.71	Very good
FBow	0.79	0.80	Excellent
NSA	0.75	0.77	Very good
HKC'	0.83	0.88	Excellent
C'KS	0.78	0.85	Excellent

Strength of agreement for the kappa coefficient was interpreted as follows: < 0.20 = unacceptable, 0.20 to 0.39 = questionable, 0.40 to 0.59 = good, 0.60 to 0.79 = very good, and 0.80 to 1 = excellent.

aMDFA, anatomical medial distal femoral angle; FBow, femoral bowing; HKA, hip knee ankle; HKS, hip knee shaft angle; ICC, intraclass correlation coefficient; mMDFA, mechanical medial distal femoral angle; MPTA, medial proximal tibial angle; NSA, neck shaft angle.

and the mMDFA were significantly lower in the severe FBow group. Other radiological measurements were similar in both groups (Table IV).

**Reliability and reproducibility of the measurements.** The radiological measurements showed very good to excellent intraobserver and interobserver agreements (Table V). The C'KS angle was a reproducible measurement of the FBow impact on the mMDFA.

**Anatomical factors impacting the knee alignment.** The mechanical femoral axis (mMDFA) can be described as the result of three femoral deformities. The metaphyseal deformity corresponds to the aMDFA. The diaphyseal deformity corresponds to the C'KS angle. The proximal deformity (femoral head and neck) corresponds to the HKC'

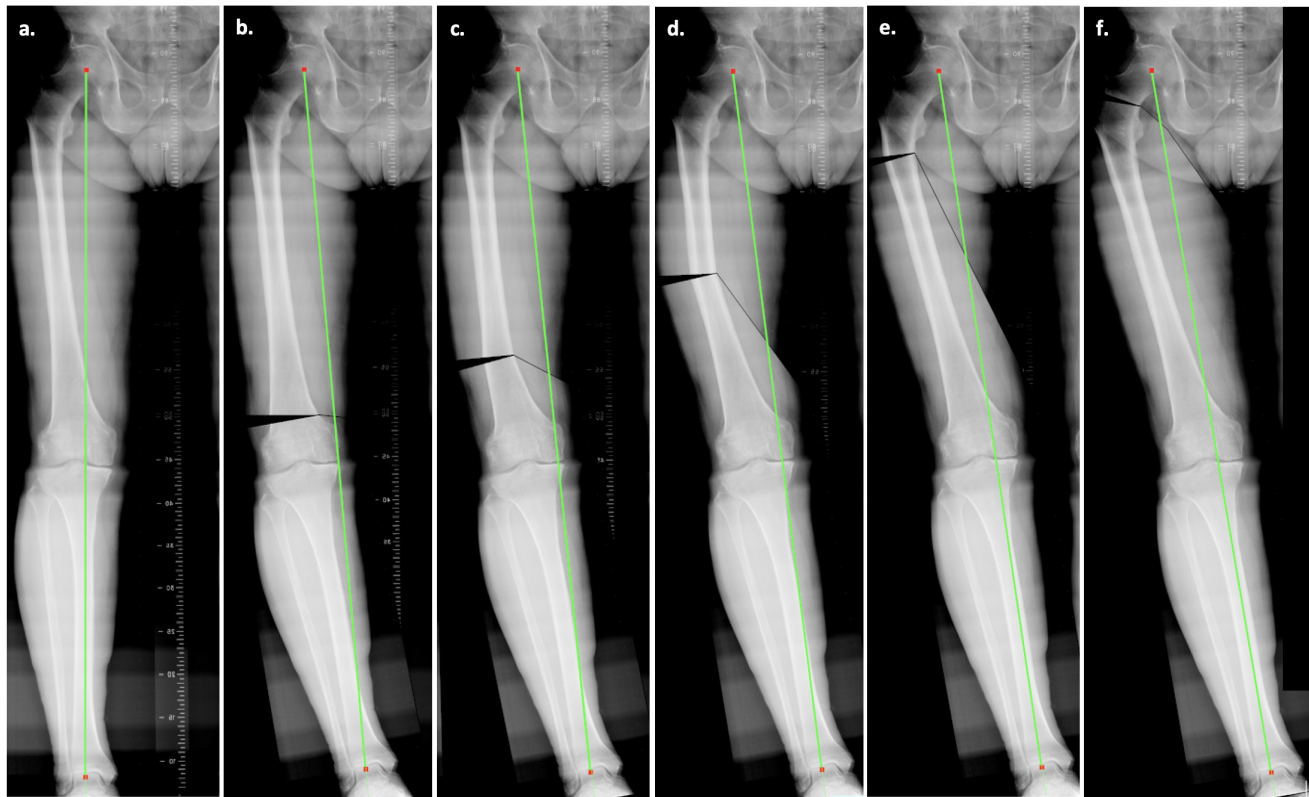
angle (Figure 5). The intra-articular deformity should be considered separately and corresponds to the femoral and tibial wear. It was quantified by the JLCA.

The C'KS angle (the FBow impact on the knee) increased significantly when the length DK decreased and the FBow angle increased ( $p < 0.001$ , Pearson correlation coefficient) (Figure 6). The mMDFA were correlated to C'KS angle and aMDFA ( $p < 0.001$ , Pearson correlation coefficient) (Table VI). Table VII and Figure 7 summarize the results of the linear regression analyses. The main contributor to mMDFA was aMDFA, then the C'KS angle. The main contributor to HKA angle was JLCA. Other contributors to HKA angle were MPTA, C'KS angle, then aMDFA.

## Discussion

The main finding of this study was the description of a reliable measurement (C'KS angle) of the impact of the diaphyseal femoral deformity on knee alignment, related to the localization and the severity of the deformity. This measurement could be used as an additional tool to understand the femoral bone deformity when planning for knee surgery (knee arthroplasty or osteotomy).

Several limitations should be outlined: first, the femoral bowing was measured only on the radiographs, without CT scan measurement. However, we have excluded patients who were at risk of measurement errors (flexion contracture, rotational disorders), and all the full length radiographs were performed based on the same protocol. Furthermore, in current practice, a CT scan was not justified for primary knee arthroplasty or osteotomy. Second, this study did not report clinical outcomes after knee surgeries according to the anatomy



**Fig. 5**

Radiological models of the modifications of the weightbearing line (Mikulicz line) according to the level of the femoral deformity. a) No deformity; b) 10° of distal metaphyseal deformity; c) 10° of distal diaphyseal deformity; d) 10° of middle third diaphyseal deformity; e) 10° of proximal diaphyseal deformity; and f) 10° of proximal deformity.

**Table VI.** Correlation analysis on the anatomical features and lower limb alignment. Values are presented as Pearson correlation coefficient.

Variable	C'KS	p-value	mMDFA	p-value	HKA	p-value
mMDFA	N/A	N/A	N/A	N/A	0.37	< 0.001
aMDFA	N/A	N/A	0.76	< 0.001	0.23	0.001
FBow	0.91	< 0.001	-0.31	< 0.001	-0.25	< 0.001
DK	-0.31	< 0.001	0.15	0.028	0.23	0.001
C'KS	N/A	N/A	-0.36	< 0.001	-0.30	< 0.001
NSA	0.099	0.157	0.031	0.660	0.054	0.442
HC'	-0.093	0.194	-0.092	0.193	0.14	0.041
HKC'	-0.019	0.786	-0.134	0.056	-0.037	0.600
JLCA	N/A	N/A	N/A	N/A	-0.73	< 0.001
MPTA	N/A	N/A	N/A	N/A	0.59	< 0.001

aMDFA, anatomical medial distal femoral angle; FBow, femoral bowing; HKA, hip knee ankle angle; JLCA, joint line convergence angle; mMDFA, mechanical medial distal femoral angle; MPTA, medial proximal tibial angle; N/A, not applicable; NSA, neck shaft angle; SD, standard deviation.

restoration; rather, the assessment of FBow was radiological in order to describe a new measurement and assess its reliability. A clinical study would be necessary in the future to assess this radiological tool in clinical practice for knee arthroplasty or osteotomy. Third, this study has been performed in a Middle Eastern population of patients; the prevalence and severity of FBow cannot be extrapolated to the worldwide population. Nevertheless, the measurement and the understanding of the FBow

impact on the knee alignment can be used in the worldwide population. This new measurement could be also assessed in post-traumatic femoral diaphyseal deformity.

The FBow impact was frequently moderate (between 0° and 2.5° for 59% (121/205) of the patients in this cohort). In this Middle East population with constitutional deformity (no post-traumatic deformity), the mean FBow angle is only 4°, and most cases of FBow were not close to the joint. Nevertheless, the diaphyseal deformity can



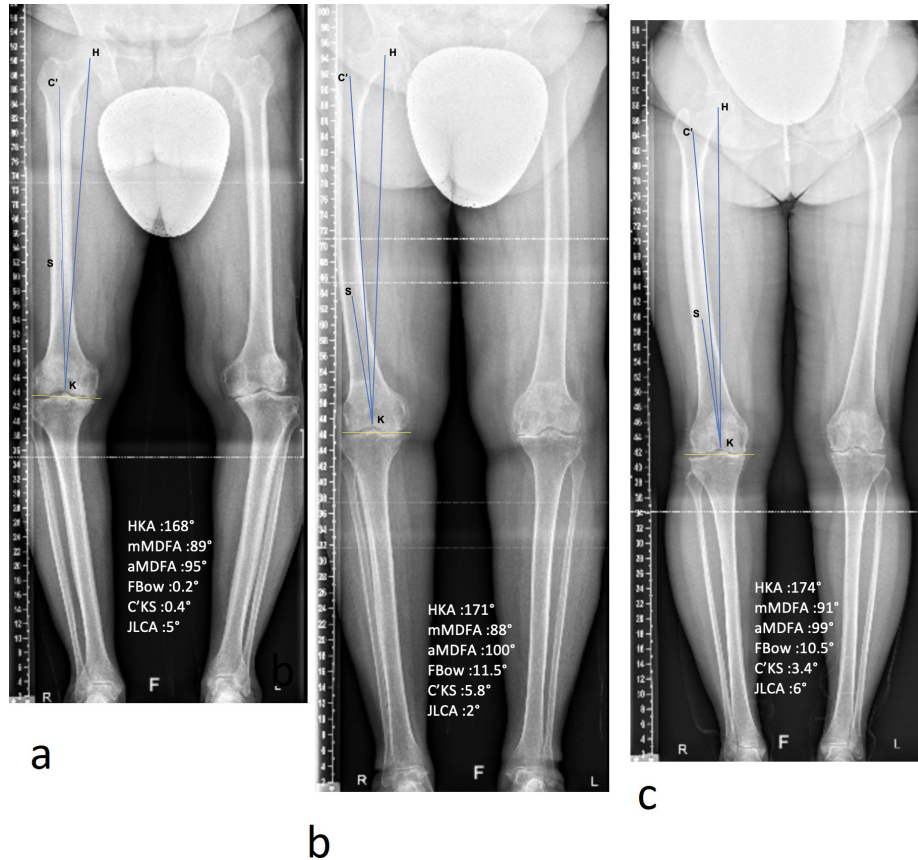


Fig. 6

Three full long-leg radiograph showing examples of femoral deformity. a) Right knee with a distal metaphyseal varus deformity and without diaphyseal deformity. b) Right knee with a diaphyseal varus deformity (middle of the shaft) and a high FBow impact on the knee alignment (5.8°). c) Right knee with a diaphyseal varus deformity (proximal part of the shaft). While the FBow angle was similar to the Figure 5b, the FBow impact on the knee was low because the deformity was far away from the knee. aMDFA, anatomical medial distal femoral angle; FBow, femoral bowing angle; HKA, hip-knee-ankle angle; JLCA, joint line convergence angle; mMDFA, mechanical medial distal femoral angle; MPTA, medial proximal tibial angle.

**Table VII.** Evaluation of the radiological measurements that influence hip knee ankle angle and mechanical medial distal femoral angle by multiple linear regression analyses. All p-values were < 0.001.

Dependent variable	Independent variable	R2	Unstandardized coefficients (SD)	Standardized coefficients (SD)
HKA	MPTA	0.92	0.92 (0.04)	0.51 (0.02)
	JLCA		-0.99 (0.03)	-0.62 (0.02)
	aMDFA		0.74 (0.04)	0.38 (0.02)
	C'KS		-0.95 (0.08)	-0.25 (0.02)
	HKC'		-0.90 (0.13)	-0.14 (0.02)
mMDFA	aMDFA	0.88	0.89 (0.03)	0.88 (0.025)
	C'KS		-0.94 (0.05)	-0.48 (0.025)
	HKC'		-0.97 (0.08)	-0.29 (0.025)

aMDFA, anatomical medial distal femoral angle; HKA, hip knee ankle angle; JLCA, joint line convergence angle; mMDFA, mechanical medial distal femoral angle; MPTA, medial proximal tibial angle; SD, standard deviation.

sometimes have a strong impact on knee alignment. The C'KS reached 6° for the most severe FBow in this study. In this case, the impact of the diaphyseal deformity on the knee must be known in order to adjust the surgical planning. Severe FBow is uncommon, although it is predominant in some ethnic populations, such as Asian and Middle Eastern populations (mean FBow angle varying

between 1.8° and 5.3°),<sup>13–15,24,25</sup> where the FBow angle can reach 88% of the patients in an osteoarthritic population. Interest in the impact of the FBow measurement remains crucial in a worldwide population to manage constitutional diaphyseal deformity and post-traumatic deformity. Indeed, a diaphyseal femoral deformity due to a malunion of a diaphyseal fracture must be quantified

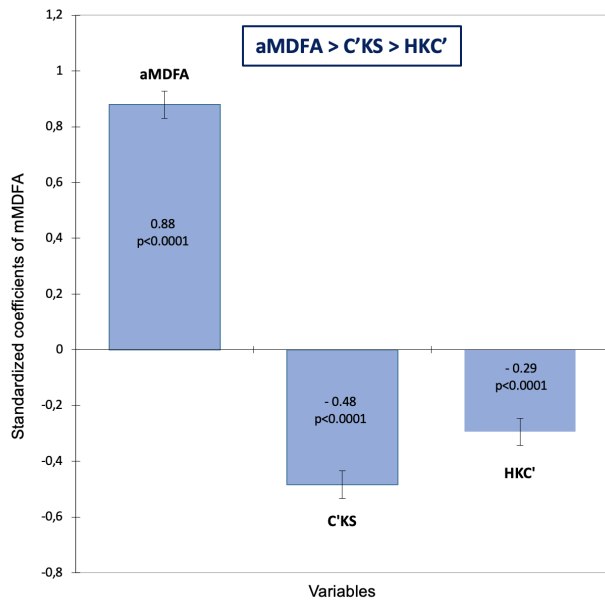


Fig. 7

Standardized coefficients of the radiological measurements that influence mechanical medial distal femoral angle (mMDFA). aMDFA, anatomical medial distal femoral angle; C'KS angle (angle between the distal femoral shaft axis and the line joining C' and the knee centre K); HKC' angle (angle between the mechanical axis line of the femur and the line joining C' and the knee centre K).

to discuss if it is acceptable or needs a realignment osteotomy.<sup>26,27</sup> This is why a straightforward measurement of the FBow impact on knee alignment can be helpful in the surgeon's practice.

While this measurement is reliable and useable in daily practice, it cannot be performed in specific cases. The flexion contracture is a major factor that affects the FBow angle:<sup>16</sup> the larger the flexion contracture angle, the larger the FBow angle. A femoral rotational disorder can also modify the FBow angle.<sup>16</sup> In this case, the radiological FBow angle combines the true FBow deformity and the sagittal femoral deformity. With an internal rotation disorder, the radiological FBow is underestimated, and with an external rotational disorder, the radiological FBow is overestimated. Therefore, the femoral bowing is more accurate with a CT scan,<sup>16,28</sup> which avoids these measurement errors of a standard full long-leg radiograph. Nevertheless, these two causes of mistakes can be easily identified clinically, and an additional CT scan can be performed if needed. The most common imaging exam performed for knee arthroplasty remains radiographs. A radiological assessment of the diaphyseal deformity is thus essential, while remaining wary of the risk of error. The full long-leg radiograph must also be accurate with a knee strictly in a frontal position. Several criteria can help to confirm the radiograph's quality, such as a centred patella, a symmetrical femoral notch, and the fibular head position. A strict radiological protocol is

necessary; a monopodal full long-leg radiograph could decrease the risk of errors.

This study has demonstrated that one of the main anatomical factors influencing the mechanical femoral axis was the C'KS angle. Indeed, several studies have reported some difficulties and risk of errors during a TKA procedure when a significant FBow was present.<sup>22,25,29</sup> The risk of misalignment in these cases was dependent on the surgical technique of alignment. There were more femoral components in varus (between 2° and 4° of mean varus) in the patients with a FBow angle superior to 5° when a fixed value of the distal femoral cut axis compared to the intramedullary guide is used (e.g. 7°).<sup>22,30</sup> Navigation can reduce the risk of misalignment in varus in the femoral bowing population, mainly the risk of outliers.<sup>22</sup> However, navigation can also completely correct the femoral deformity, including the diaphyseal deformity, which should not be corrected by the implant positioning,<sup>13</sup> as the residual lateral laxity in extension would be substantial in this case. The use of patient-specific instrumentation (PSI) did not improve the lower limb alignment and the implant positioning in the FBow population either.<sup>30</sup> Computer-assisted systems or PSI, without integrating the localization of the deformity, would not be helpful in managing these diaphyseal deformities. For kinematic alignment techniques when a significant FBow is present, there is a risk of keeping too much residual varus in the lower limb at the end of the procedure. Therefore, it seems essential to understand the impact of femoral bowing on the knee in order to adjust surgical planning accordingly.

Several knee surgeries could benefit from this measurement of the FBow impact, particularly TKA with severe femoral bowing, or post-traumatic malunion of a diaphyseal fracture with severe varus deformity. Knowing the proportion of the varus alignment due to the diaphyseal deformity could help to determine if an osteotomy is needed, if the deformity can be compensated in the joint, or if the deformity should not be corrected. A clinical study is the next step to assess the consequences of surgical planning (for TKA or osteotomy) using this new measurement (C'KS angle) of the FBow impact on the knee alignment.

In conclusion, the results of this study showed that the impact of the diaphyseal femoral deformity on knee alignment can be measured by the C'KS angle, which considers the localization and importance of the FBow, with good reliability and reproducibility. This new radiological tool improves the understanding of the femoral bone deformity and its impact on the knee.

## Take home message

- The impact of the diaphyseal femoral deformity on the knee alignment can be measured by a radiological angle on a full long leg radiograph with a good reliability and a good reproducibility.
- The impact of the diaphyseal femoral deformity was frequently moderate, nevertheless it can reach 6° for the most important femoral bowing in this study.
- This measurement could be used as an additional tool to understand the femoral bone deformity when planning for knee surgery (knee arthroplasty or osteotomy).

## References

1. Lustig S, Sappey-Marinié E, Fary C, Servien E, Parratte S, Batailler C. Personalized alignment in total knee arthroplasty: current concepts. *SICOT J*. 2021;7:19.
2. Chang JS, Kayani B, Wallace C, Haddad FS. Functional alignment achieves soft-tissue balance in total knee arthroplasty as measured with quantitative sensor-guided technology. *Bone Joint J*. 2021;103-B(3):507–514.
3. Grasso F, Martz P, Micicoi G, et al. Double level knee osteotomy using patient-specific cutting guides is accurate and provides satisfactory clinical results: a prospective analysis of a cohort of twenty-two continuous patients. *Int Orthop*. 2022;46(3):473–479.
4. Bellemans J, Colyn W, Vandenneucker H, Victor J. The Chitranjan Ranawat award: is neutral mechanical alignment normal for all patients? The concept of constitutional varus. *Clin Orthop Relat Res*. 2012;470(1):45–53.
5. Hirschmann MT, Moser LB, Amsler F, Behrend H, Leclercq V, Hess S. Functional knee phenotypes: a novel classification for phenotyping the coronal lower limb alignment based on the native alignment in young non-osteoarthritic patients. *Knee Surg Sports Traumatol Arthrosc*. 2019;27(5):1394–1402.
6. Hirschmann MT, Hess S, Behrend H, Amsler F, Leclercq V, Moser LB. Phenotyping of hip-knee-ankle angle in young non-osteoarthritic knees provides better understanding of native alignment variability. *Knee Surg Sports Traumatol Arthrosc*. 2019;27(5):1378–1384.
7. Hirschmann MT, Moser LB, Amsler F, Behrend H, Leclercq V, Hess S. Phenotyping the knee in young non-osteoarthritic knees shows a wide distribution of femoral and tibial coronal alignment. *Knee Surg Sports Traumatol Arthrosc*. 2019;27(5):1385–1393.
8. Razak HRBA, Micicoi G, Khakha RS, et al. Patients with varus knee osteoarthritis undergoing high tibial osteotomy exhibit more femoral varus but similar tibial morphology compared to non-arthritic varus knees. *Knee Surg Sports Traumatol Arthrosc*. 2022;30(2):680–687.
9. Sappey-Marinié E, Batailler C, Swan J, et al. Primary osteoarthritic knees have more varus coronal alignment of the femur compared to young non-arthritic knees in a large cohort study. *Knee Surg Sports Traumatol Arthrosc*. 2022;30(2):428–436.
10. Thienpont E, Parvizi J. A new classification for the varus knee. *J Arthroplasty*. 2016;31(10):2156–2160.
11. Wolff AM, Hungerford DS, Pepe CL. The effect of extraarticular varus and valgus deformity on total knee arthroplasty. *Clin Orthop Relat Res*. 1991;271:35–51.
12. Paley D, Tetsworth K. Mechanical axis deviation of the lower limbs. Preoperative planning of multiapical frontal plane angular and bowing deformities of the femur and tibia. *Clin Orthop Relat Res*. 1992;280:65–71.
13. Lasam MPG, Lee KJ, Chang CB, Kang YG, Kim TK. Femoral lateral bowing and varus condylar orientation are prevalent and affect axial alignment of TKA in Koreans. *Clin Orthop Relat Res*. 2013;471(5):1472–1483.
14. Mullaji AB, Marawar SV, Mittal V. A comparison of coronal plane axial femoral relationships in Asian patients with varus osteoarthritic knees and healthy knees. *J Arthroplasty*. 2009;24(6):861–867.
15. Nayak M, Kumar V, Kanojiya G, et al. A radiographic analysis of alignment in 966 lower extremities with knee pain and its association with osteoarthritis in Indian population. *J Orthop*. 2020;20:207–212.
16. Li Y-R, Gao Y-H, Qi X, et al. Analysis of factors that affect the precision of the radiographic lateral femoral bowing angle using a three-dimensional computed tomography-based modelling technique. *J Orthop Surg Res*. 2017;12(1):92.
17. Paley D, Tetsworth K. Mechanical axis deviation of the lower limbs. Preoperative planning of uniapical angular deformities of the tibia or femur. *Clin Orthop Relat Res*. 1992;280:48–64.
18. Cooke TDV. Definition of axial alignment of the lower extremity. *J Bone Joint Surg Am*. 2002;84-A(1):146–147.
19. Cooke TD, Scudamore RA, Bryant JT, Sorbie C, Siu D, Fisher B. A quantitative approach to radiography of the lower limb: principles and applications. *J Bone Joint Surg Br*. 1991;73-B(5):715–720.
20. Lu Y, Zheng Z, Chen W, Lv H, Lv J, Zhang Y. Dynamic deformation of femur during medial compartment knee osteoarthritis. *PLoS One*. 2019;14(12):e0226795.
21. McGrory JE, Trousdale RT, Pagnano MW, Nigbur M. Preoperative hip to ankle radiographs in total knee arthroplasty. *Clin Orthop Relat Res*. 2002;404:196–202.
22. Kim CW, Lee CR. Effects of femoral lateral bowing on coronal alignment and component position after total knee arthroplasty: A comparison of conventional and navigation-assisted surgery. *Knee Surg Relat Res*. 2018;30(1):64–73.
23. Regier DA, Narrow WE, Clarke DE, et al. DSM-5 field trials in the United States and Canada, Part II: test-retest reliability of selected categorical diagnoses. *Am J Psychiatry*. 2013;170(1):59–70.
24. Song MH, Yoo SH, Kang SW, Kim YJ, Park GT, Pyeon YS. Coronal alignment of the lower limb and the incidence of constitutional varus knee in Korean females. *Knee Surg Relat Res*. 2015;27(1):49–55.
25. Yau WP, Chiu KY, Tang WM, Ng TP. Coronal bowing of the femur and tibia in Chinese: its incidence and effects on total knee arthroplasty planning. *J Orthop Surg (Hong Kong)*. 2007;15(1):32–36.
26. Deschamps G, Khiami F, Catonné Y, et al. Total knee arthroplasty for osteoarthritis secondary to extra-articular malunions. *Orthop Traumatol Surg Res*. 2010;96(8):849–855.
27. Wilson AJ, Nandi S, Robbins CE, Bono JV. TKA after clamshell osteotomy for femoral diaphyseal malunion. *Orthopedics*. 2012;35(6):e969–72.
28. Akamatsu Y, Kobayashi H, Kusayama Y, Kumagai K, Saito T. Femoral shaft bowing in the coronal and sagittal planes on reconstructed computed tomography in women with medial compartment knee osteoarthritis: a comparison with radiograph and its predictive factors. *Arch Orthop Trauma Surg*. 2016;136(9):1227–1232.
29. Cho MR, Lee YS, Choi WK. Relationship between lateral femoral bowing and varus knee deformity based on two-dimensional assessment of side-to-side differences. *Knee Surg Relat Res*. 2018;30(1):58–63.
30. ALShammari SA, Choi KY, Koh IJ, Kim MS, In Y. Total knee arthroplasty in femoral bowing: does patient specific instrumentation have something to add? A randomized controlled trial. *BMC Musculoskelet Disord*. 2021;22(1):321.

### Author information:

- C. Batailler, MD, PhD, Orthopaedic Surgeon
- S. Lustig, PhD, MD, Orthopaedic Surgeon  
Department of Orthopaedic Surgery, Croix-Rousse Hospital, Lyon University Hospital, Lyon, France; Claude Bernard Lyon 1 University, Villeurbanne, France.
- A. Naaim, PhD, Engineer, Claude Bernard Lyon 1 University, Villeurbanne, France.
- J. Daxhelet, MD, Orthopaedic Surgeon, Department of Orthopaedic Surgery, Clinique Saint-Luc Bouge, Namur, Belgium.
- M. Ollivier, PhD, MD, Orthopaedic Surgeon, Institute of Movement and Locomotion, Department of Orthopedics and Traumatology, St. Marguerite Hospital, Marseille, France.
- S. Parratte, PhD, MD, Orthopaedic Surgeon, Institute of Movement and Locomotion, Department of Orthopedics and Traumatology, St. Marguerite Hospital, Marseille, France; Department of Orthopaedic Surgery, International Knee and Joint Centre, Abu Dhabi, United Arab Emirates.

### Author contributions:

- C. Batailler: Conceptualization, Data curation, Formal analysis, Investigation, Methodology, Writing – original draft.
- A. Naaim: Formal analysis, Investigation, Methodology, Writing – review & editing.
- J. Daxhelet: Data curation, Investigation, Writing – review & editing.
- S. Lustig: Methodology, Validation, Writing – review & editing.
- M. Ollivier: Methodology, Validation, Writing – review & editing.
- S. Parratte: Conceptualization, Investigation, Methodology, Supervision, Validation, Writing – review & editing.

### Funding statement:

- The authors received no financial or material support for the research, authorship, and/or publication of this article.