



HAL
open science

A significant rate of tibial overcorrection with an increased JLO occurred after isolated high tibial osteotomy without considering international consensus

Matthieu Ollivier, Jae-sung An, Kristian Kley, Raghbir Khakha, Levi Reina Fernandes, Grégoire Micicoi

► To cite this version:

Matthieu Ollivier, Jae-sung An, Kristian Kley, Raghbir Khakha, Levi Reina Fernandes, et al.. A significant rate of tibial overcorrection with an increased JLO occurred after isolated high tibial osteotomy without considering international consensus. *Knee Surgery, Sports Traumatology, Arthroscopy*, 2023, 31 (11), pp.4927 - 4934. 10.1007/s00167-023-07518-5 . hal-04480909

HAL Id: hal-04480909

<https://hal.science/hal-04480909>

Submitted on 27 Feb 2024

HAL is a multi-disciplinary open access archive for the deposit and dissemination of scientific research documents, whether they are published or not. The documents may come from teaching and research institutions in France or abroad, or from public or private research centers.

L'archive ouverte pluridisciplinaire **HAL**, est destinée au dépôt et à la diffusion de documents scientifiques de niveau recherche, publiés ou non, émanant des établissements d'enseignement et de recherche français ou étrangers, des laboratoires publics ou privés.

See discussions, stats, and author profiles for this publication at: <https://www.researchgate.net/publication/373236519>

A significant rate of tibial overcorrection with an increased JLO occurred after isolated high tibial osteotomy without considering international consensus

Article in *Knee Surgery Sports Traumatology Arthroscopy* · August 2023

DOI: 10.1007/s00167-023-07518-5

CITATION

1

READS

113

6 authors, including:



Matthieu Ollivier

Aix-Marseille Université

364 PUBLICATIONS 5,474 CITATIONS

[SEE PROFILE](#)



Raghbir Khakha

Guy's and St Thomas' NHS Foundation Trust

62 PUBLICATIONS 445 CITATIONS

[SEE PROFILE](#)



Grégoire Micicoi

University of Nice Sophia Antipolis

45 PUBLICATIONS 266 CITATIONS

[SEE PROFILE](#)

A significant rate of tibial overcorrection with an increased JLO occurred after isolated high tibial osteotomy without considering international consensus

Matthieu Ollivier¹  · Jae-Sung An¹ · Kristian Kley² · Raghbir Khakha³ · Levi Reina Fernandes⁴ · Grégoire Micicoi⁵

Abstract

Purpose The recent ESSKA consensus recommendations defined indications and outlined parameters for osteotomies around a degenerative varus knee. The consensus collated these guidelines based on the published literature available to answer commonly asked questions including the importance of identifying the site and degree of the lower limb deformity. In the consensus, the authors suggest that a knee joint line obliquity (JLO) greater than 5° or a planned medial proximal tibial angle (MPTA) > 94° preferentially indicates a double level osteotomy (DLO) compared to an isolated opening wedge high tibial osteotomy (OWHTO). This study aimed to analyze the corrections performed on a cohort of isolated opening wedge high tibial osteotomies (OWHTOs) prior to the recent ESSKA recommendations, with a focus on the impact of knee joint line obliquity (JLO) and medial proximal tibial angle (MPTA) on the choice of osteotomy procedure.

Methods This monocentric, retrospective study included 129 patients undergoing medial OWHTO for symptomatic isolated medial knee osteoarthritis (Ahlbäck grade I or II) and a global varus malalignment (hip–knee–ankle angle ≤ 177°). An automated software trained to automatically detect lower limb deformity was implemented using patients preoperative long leg alignment X-rays to identify suitability for an isolated HTO in knee varus deformity. Based on the ESSKA recommendations, the site of the osteotomy was identified as well as the degree of correction required. The ESSKA consensus considers avoiding an isolated high tibial osteotomy if the planned resultant knee joint line orientation exceeds 5° or MPTA exceeds 94°. A preoperative abnormal MPTA was defined by a value lower than 85° and a preoperative abnormal LDFA by a value greater than 90°. The cases of DLO or DFO suggested by the software and the number of extra-tibial anomalies were collected. Multiple linear regression models were developed to establish a relationship between preoperative values and the risk of being outside of ESSKA recommendations postoperatively.

Results Based on ESSKA recommendations and on threshold values considered abnormal, the software suggested a DLO in 17.8% ($n = 23/129$) of cases, a distal femoral osteotomy in 27.9% ($n = 36/129$) of cases and advised against an osteotomy procedure in 24% ($n = 31/129$) of cases. The software detected a femoral anomaly in 34.9% ($n = 45/129$) of cases and an JLCA > 6° in 9.3% ($n = 12/129$). Postoperatively, the MPTA exceeds 94° in 41.1% ($n = 53/129$) and the JLO exceeds 5° in 29.4% ($n = 38/129$).

On multivariate analysis, a high preoperative MPTA was associated with higher risk of postoperative MPTA > 94° ($R^2 = 0.36$; $p < 0.001$). Similarly, the probability of the software advising a DLO or DFO was associated with the presence of an “normal” preoperative MPTA ($R^2 = 0.42$; $p < 0.001$) or an abnormal preoperative LDFA ($R^2 = 0.48$; $p < 0.001$) or a planned JLO > 5° ($R^2 = 0.27$; $p < 0.001$).

Conclusions Analysis of patients who underwent an isolated OWHTO prior to the ESSKA guidelines, demonstrated a significant rate of post-operative tibial overcorrection and a resultant increased JLO. Pre-operative planning that considers the ESSKA guidelines, allows for better identification of those patients requiring a DFO or DLO and avoidance of resultant post-operative deformities.

Level of evidence IV, case-series.

Keywords Knee · Open-wedge high tibial osteotomy · Osteoarthritis · Varus deformity · Joint line obliquity · Anatomical correction

Introduction

Open-wedge high tibial osteotomy (OWHTO) is commonly performed for young active patients with medial knee osteoarthritis (OA) associated with metaphyseal tibial varus [13]. Historically, a postoperative mechanical valgus between 2° and 7° was advocated to provide favourable clinical outcomes following medial OWHTO [6–8]. However, this ideal correction can inadvertently lead to an overcorrection of the medial proximal tibial angle (MPTA), resulting in an excessive joint line obliquity (JLO). An increased JLO is associated with increased shear stress on the articular cartilage and potential adverse clinical outcomes [3, 18]. As a rule, an $MPTA > 95^\circ$ was generally associated with a JLO greater than 4° [1].

There are few studies considering the influence of excessive JLO on the long-term results following OWHTO surgery. Babis *et al.* [3] reported excellent survivorship following DLO surgery with a survival rate at 96% at around 10 year follow-up, where a JLO within normal parameters was retained for all patients. The same authors demonstrated a 100% survival at 10 years for patients with postoperative femorotibial angle of 174°–180° and postoperative joint line obliquity $< 4^\circ$ [2]. More recent studies reported lower KOOS scores or lateral compartment pain for patients with an increased postoperative JLO [9, 11]. Song *et al.* demonstrated poor outcomes in cases, where there was a resultant post-operative of $JLO \geq 4^\circ$ [27]. To restore a physiological mechanical alignment and joint line obliquity in cases of severe varus malalignment, double level osteotomy (DLO) based on both tibial and femoral anatomical restoration may be considered to avoid postoperative excessive JLO [22–25].

Recent ESSKA consensus recommendations were produced in 2022 for osteotomies around the degenerative varus knee [4]. The consensus experts suggested a more personalized approach taking into account the site and degree of the deformity. Utilising high quality published literature, the experts recommend that in case of a resultant knee joint line orientation greater than 5° or a planned $MPTA > 94^\circ$, the surgeon should preferably opt for a DLO rather than an isolated HTO. However, no publication has evaluated the actual correction made after isolated OWHTO and whether the targets achieved postoperatively were outside from the ESSKA consensus.

This study aimed to analyze the corrections performed on a cohort of isolated opening wedge high tibial osteotomies (OWHTOs) prior to the recent ESSKA

recommendations, with a focus on the impact of knee joint line obliquity (JLO) and medial proximal tibial angle (MPTA) following the choice of osteotomy procedure. The secondary aims of this study were to analyze the suitability of isolated OWHTO and the incidence of postoperative angular values after OWHTO that deviate from the expert consensus recommendations.

The hypothesis of this study was that a significant number of patients operated by isolated OWHTO in a high-volume osteotomy center should have preferably undergone DLO according to the ESSKA consensus recommendations.

Materials and methods

Patients

A monocentric retrospective study was performed between January 2015 and December 2020 including patients undergoing isolated medial open-wedge high tibial osteotomy (OWHTO) surgery. Osteotomies were performed for patients with symptomatic isolated medial knee osteoarthritis (Ahlbäck grade I or II) and a global varus malalignment (hip–knee–ankle angle $\leq 177^\circ$). Post-traumatic arthritis, previous knee surgery, symptomatic excessive torsional malalignment, patients younger than 18 years, associated ACL injury or those planned for sagittal correction were excluded from the study. Out of 251 patients identified, only 129 were selected based on the inclusion criteria. The preoperative demographics are shown in Table 1. To perform this study, all radiographs were obtained by legal and regulatory requirements which included ethics board approval and informed patient consent.

Table 1 Preoperative Demographics and Clinical Status

	Value
No. of cases	129
No. of patients	121
Age, years, mean \pm SD (range)	40.7 \pm 12.6 (16–67)
Sex, female/male, <i>n</i>	30/99
Body mass index, kg/m ² , mean \pm SD (range)	25.3 \pm 5.3 (16.7–49)
Side, right/left, <i>n</i>	69/60

Radiological evaluation

Radiographic measurements were taken twice by a single independent observer who carried out all measurements. A strict radiological protocol to acquire long leg alignment views was applied. The images were acquired using weight-bearing anteroposterior radiographs. The limb was positioned to achieve a true antero-posterior image in a forward knee position, with the patella centred on the femoral condyle and the patients were requested to maintain knee extension.

The hip–knee–ankle angle (HKA), the medial proximal tibial angle (MPTA) and the lateral distal femoral angle (LDFA) were measured manually as well as with semi-automated measures for the software analysis (Fig. 1). The HKA angle was defined by the lines connecting the centre of the femoral head to the knee joint and a line between the centre of the knee joint to the ankle joint. A value less than 180° indicated varus alignment. The MPTA was defined as the medial angle formed between the line of the mechanical tibial axis and a line tangent to the joint surface of the proximal tibial plateau. The LDFA defined as the lateral angle formed between the mechanical axis line of the femur and a line tangent to the articular surface of the distal femur. An MPTA $<90^\circ$ corresponded to tibial vara, while an

LDFA $<90^\circ$ corresponded to femoral valga. The Joint Line Convergence Angle (JLCA) defined by the angle between the tangent to the subchondral plates of the femoral condyles and the tibial plateau was also measured.

Deformity analysis

Angular value measurements were performed postoperatively using preoperative radiographs with PeekMed software (Braga, Portugal). This semi-automated software, trained to detect lower limb deformity, was challenged using patients' preoperative X-rays to indicate or contra-indicate an isolated HTO in knee varus deformity. This planning tool for orthopedic surgery analyses overall alignment using reference points placed on bony landmarks (femoral head, greater trochanter, distal femur, proximal tibia as well as the medial and lateral malleoli). The purpose of the software is to allow accurate and reproducible angular values measurements [17].

Software simulation and OWHTO procedure test

The software is programmed to plan the ideal correction without introducing an excessive joint line obliquity. The radiographs were incorporated into the planning software

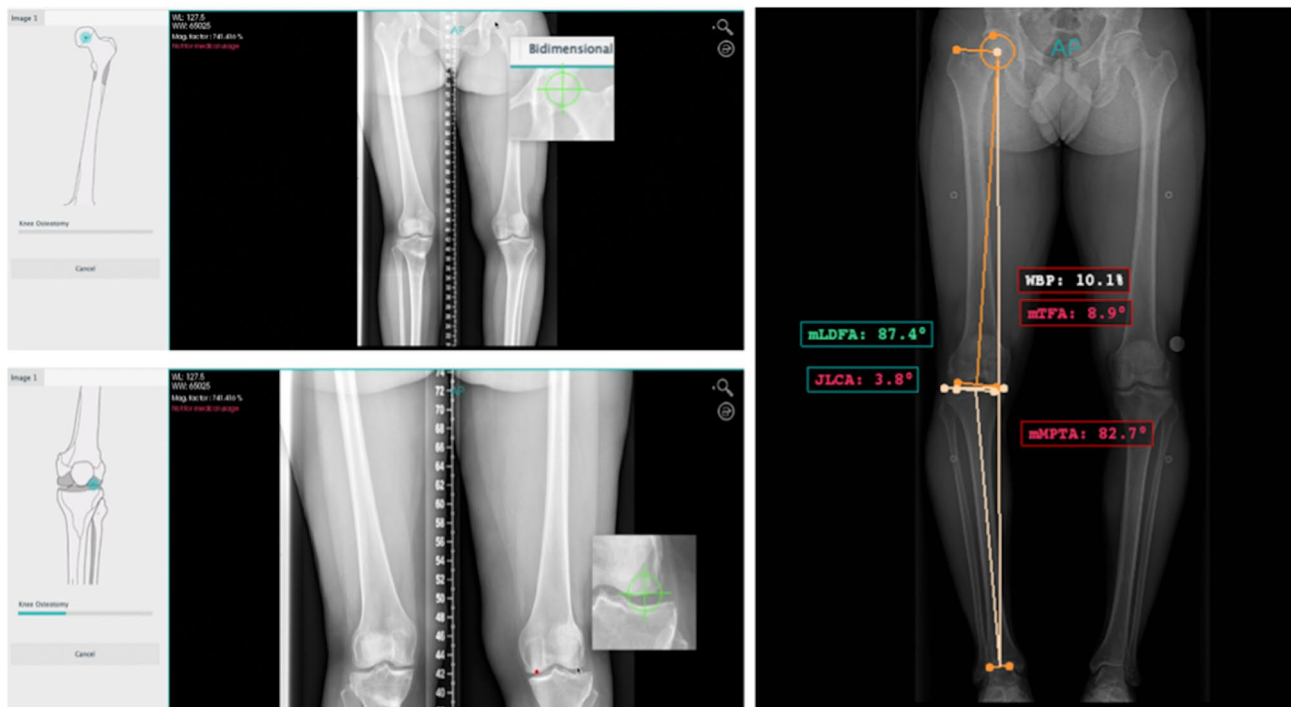


Fig. 1 Semi-automated angular values measured by the software. The medial proximal tibial angle (MPTA), lateral distal femoral angle (LDFA) and joint line convergence angle (JLCA) are obtained by placing bony landmarks (femoral head, greater trochanter, distal femur,

proximal tibia as well as the medial and lateral malleoli) on the anteroposterior radiographs. The weight-bearing line ratio is measured here at 3.5% indicating a global varus deformity

and the desired post-operative WBL% was defined at 50–55% of the mechanical axis crossing the tibial plateau (Fig. 2). Based on the ESSKA recommendations [4] informed to the software, the site of the osteotomy was proposed as well as the degree of correction required. The ESSKA consensus recommends avoiding an isolated high tibial osteotomy if the planned resultant knee joint line obliquity exceeds 5° or if MPTA exceeds 94° [4].

The software also allowed semi-automated analysis of tibial and femoral segmental deformations with integrated reference values. Thus, a preoperative abnormal MPTA was defined as a value less than 85°, and a preoperative abnormal LDFA was defined as a value greater than 90°, both corresponding, respectively, to tibial varus and femoral varus [15].

An excessive intra-articular varus defined by a JLCA > 6° was also considered in the preoperative planning by subtracting from the final correction the value of (JLCA-2)/2 as previously described [16].

If the simulation of the planned osteotomy led to a correction outside the ESSKA values to obtain the targeted WBL%, a distal femoral osteotomy (DFO) or a double level osteotomy was proposed by the software. This was possible in cases of femoral or intra-articular deformity corrected only in the tibia.

In some cases the software advised against performing an osteotomy at all, either femoral or tibial, because the pre-operative angular values were normal. This was possible in case of isolated intra-articular deformity or small preoperative bone deformity that has still been corrected by an OWHO.

Surgical technique

A 5-cm longitudinal incision was performed, and the medial aspect of the tibia was exposed. A periosteal elevator was run along the posterior tibial cortex to create a safe passage for the neurovascular protector after performing a window posterior to the superficial medial collateral ligament [10]. Two guide pins were placed at the metaphyseal tibial flare parallel to the tibial slope to mark the upper border of the osteotomy toward the fibular head. A hinge wire was used to protect the hinge point at the lateral part. This is positioned midway between Gerdy's tubercle and the fibula head in a direction that crosses the hinge point in an antero-lateral to medial–distal direction. Following the saw cuts for the osteotomy under fluoroscopic control, a biplanar cut was made and the osteotomy opened according to the pre-operative planning. This opening was maintained with an osteotomy spreader and an active motion HTO plate (Newclip Technics®, Haute-Goulaine, France) was used.

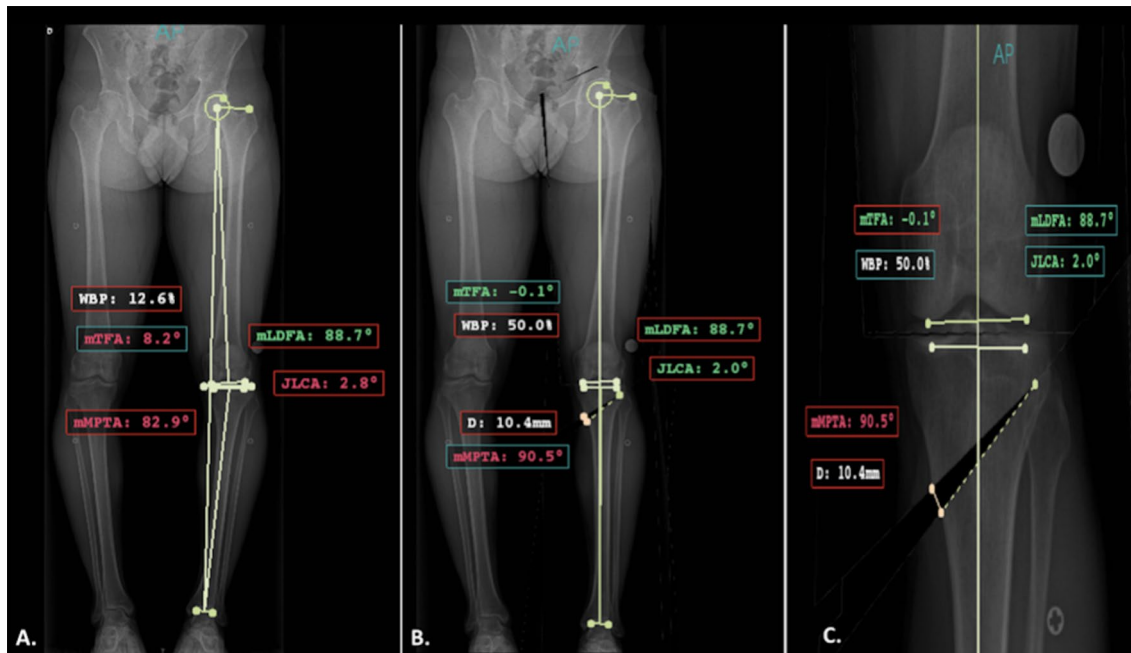


Fig. 2 The proposed correction according to the ESSKA recommendations and the values proposed by the software. A. Preoperative varus deformity with a tibia vara (MPTA=82.9°) without femoral varus deformity (LDFA=88.7°), The preoperative weight-bearing line ratio is at 12.6% B. The ideal correction is proposed by the soft-

ware to obtain a postoperative weight-bearing line ratio at 50% in this case with an isolated proximal tibial osteotomy C. If the planned correction is validated, the software proposes the opening height; 10.4 mm in this case for a 7.6° tibial correction (MPTA 90.5–82.9)

Rehabilitation postoperative assessment

Postoperatively, passive, and active progressive range of motion recovery and quadriceps reactivation were started. Full weightbearing was allowed after 1 week of surgery in the absence of hinge fracture depending on the patient's pain. Patients were allowed to return to sport activities at 6 months. All patients received thromboprophylaxis for 45 days.

Postoperative assessment

Double leg weight-bearing radiographs were analysed at 6 months after the osteotomy. The rate of patients who postoperatively had an MPTA greater than 94° or an oblique line spacing greater than 5° outside the ESSKA recommendations was analysed.

Statistical Analysis

Mean values and standard deviations (SDs) were determined for each of the measured and desired anatomic parameters. Normal (Gaussian) distributions were verified to determine adequate statistical testing method (either parametric or non-parametric) to estimate the difference between groups in a univariate analysis. Multiple linear regression models were developed to establish the determinants for each of the variables. For each model, variables with a *p* value less than 0.1 were kept in the final model. Statistical analyses were performed with use of SPSS software (IBM; Armonk, New York).

Results

The mean pre- and postoperative angular values are demonstrated in Table 2. Based on the ESSKA recommendations and the threshold values considered abnormal, the software suggested a double level osteotomy (DLO) in 17.8% (*n* = 23/129) of cases, a distal femoral osteotomy (DFO) in 27.9% (*n* = 36/129) of cases, and advised against an osteotomy procedure in 24% (*n* = 31/129) of cases. The software detected a femoral anomaly in 34.9% (*n* = 45/129) of cases and a joint line convergence angle (JLCA) > 6° in 9.3% (*n* = 12/129) of cases.

Postoperatively, the MPTA exceeded 94° in 41.1% (*n* = 53/129) of cases, and the JLO exceeded 5° in 29.4% (*n* = 38/129) of cases.

On multivariate analysis, a high preoperative MPTA (indicating less varus) was associated with a higher risk of postoperative MPTA > 94° ($R^2 = 0.36$; $p < 0.001$). Similarly, the probability of the software advising a DLO or DFO was associated with the presence of a "normal"

Table 2 Pre- and postoperative angular values

Anatomic parameters	129 OWHTO	
	Mean ± SD	Range (min–max)
Preoperative HKA angle (°)	173.4 ± 3.2	160.0–177.0
Postoperative HKA angle (°)	182.1 ± 1.9	175.9–188.0
Desired correction for HKA angle (°)	8.5 ± 2.7	3.5–16.0
Preoperative MPTA (°)	84.1 ± 2.4	77.6–90.0
Postoperative MPTA (°)	92.8 ± 2.1	85.1–96.4
Preoperative LDFA (°)	88.5 ± 3.2	74.6–98.8
Postoperative JLO (°)	2.8 ± 2.1	0–8.7
Preoperative JLCA (°)	2.8 ± 1.2	0–7.2
Postoperative JLCA (°)	1.2 ± 0.8	0–2.9

HKA hip–knee–ankle angle, *MPTA* medial proximal tibial angle, *LDFA* lateral distal femoral angle, *JLO* joint line obliquity, *OWHTO* open-wedge high tibial osteotomy

preoperative MPTA ($R^2 = 0.42$; $p < 0.001$), an abnormal preoperative LDFA ($R^2 = 0.48$; $p < 0.001$), or a planned JLO > 5° ($R^2 = 0.27$; $p < 0.001$).

Discussion

The most important finding from this study was that had the ESSKA consensus guidelines been followed, approximately half the patients undergoing correction of a global varus deformity did not benefit from an isolated OWHTO.

The automated software analysis based on the ESSKA consensus values indicated that 45.7% of patients would have benefited from a double-level osteotomy (DLO) or a distal femoral osteotomy (DFO). The main errors were related to incorrect indications for patients with significant varus deformity but without significant tibial extra-articular deformity, which may have resulted in abnormal JLO postoperatively.

Previous studies have shown that a postoperative MPTA greater than 95° is associated with lower clinical scores at 2 years and inferior subjective IKDC scores at 10 years postoperatively [1, 26].

This may be attributed, in part, to an increased joint line obliquity (JLO) associated with an elevated MPTA, leading to greater lateral compartment knee joint pain and/or worse clinical outcomes based on the KOOS score [9, 11].

Abnormal postoperative tibial morphology was most frequently observed in patients with a lower preoperative tibial deformity or a global lower limb deformity. These findings suggest that in these situations, the preoperative deformity was more likely to be located in the distal femur or a combination of the distal femur and proximal tibia rather than the proximal tibia alone (Fig. 3). This observation is

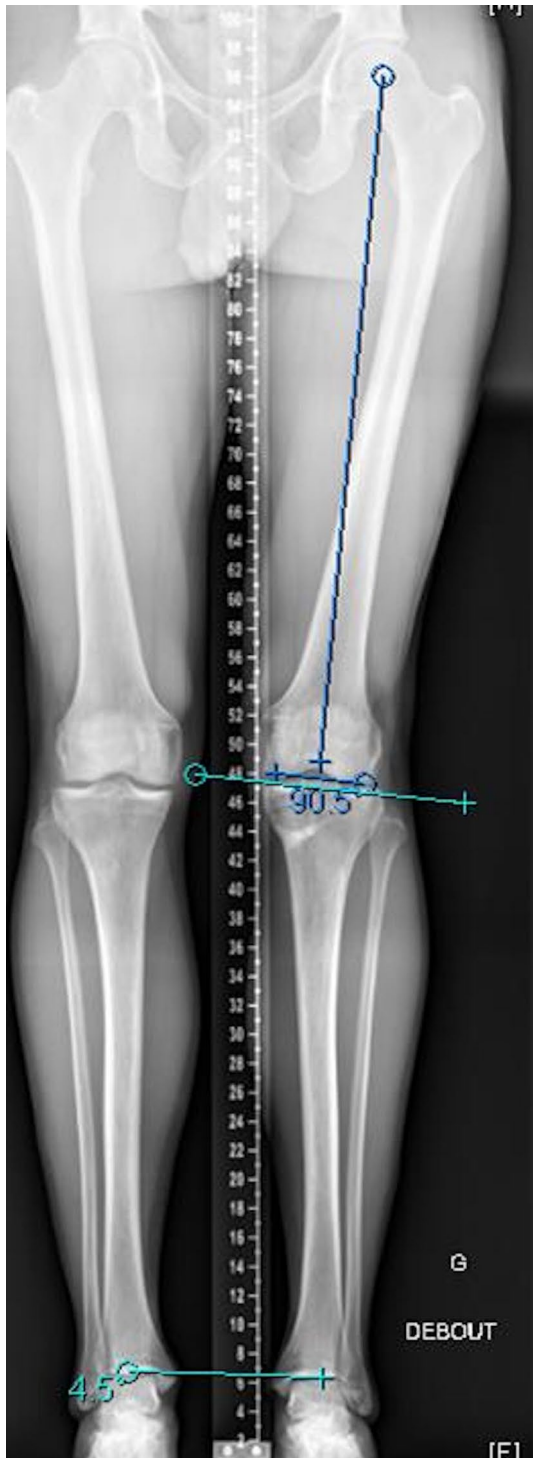

Fig. 3 Case of a patient who underwent surgery for isolated OWHO. The postoperative long leg alignment X-rays shows excessive joint line obliquity due to isolated tibial over-correction without considering the associated femoral deformity

supported by the results of Razak et al., which demonstrated a higher degree of femoral varus in patients planned for a high tibial osteotomy (HTO) with medial knee osteoarthritis

compared to non-arthritic patients, while the MPTA was similar between the groups [21].

Feucht et al. Recently demonstrated in a study based on osteotomy simulations, that only 57% of patients could achieve the desired correction without introducing a secondary abnormality following an isolated HTO, and 33% would require a DLO when slight tibial "overcorrection" was planned ($90^\circ \leq \text{MPTA} \leq 95^\circ$). Similarly, Micicoi et al. found that more than half of the patients who underwent an osteotomy around the knee had a persistent abnormal deformity, irrespective of the preoperative global malalignment [14].

The integration of consensus values based on ESSKA recommendations into deformity analysis and preoperative planning software is essential, since it allows for a more accurate identification of patients who would benefit from DFO or DLO procedures in this study. The software identified femoral deformity in 34.9% of cases and intra-articular deformity in 9.3% of cases. Furthermore, the software recommended against performing any osteotomy procedure in 24% of cases. This finding can be attributed to the deformity not being significant enough, as indicated by tibial and femoral angular values within the normal range. In such cases, an overcorrection resulting in a $\text{MPTA} > 94^\circ$ was performed, as confirmed by the multivariate analysis, which revealed a correlation between a high preoperative MPTA and the risk of $\text{MPTA} > 94^\circ$. The importance of accurate planning based on the analysis of lower limb deformities has already been well-demonstrated by the numerous works of P. Lobenhoffer and D. Paley [12, 19]. Nevertheless, the ESSKA consensus has made it possible to establish threshold values that should not be exceeded. These remain debated in the literature and some surgeons will target a threshold value of 90° after tibial correction and others recommend a value of 94° not to be exceeded [4], suggesting that a slight pre-existing femoral deformity can be accepted without being corrected by a double level osteotomy.

Finally, the risk of changing only the mechanical axis with a conventionally accepted valgus correction without considering the segmental deformity may lead to postoperative abnormalities at the proximal tibia or distal femur and potentially introduce an excessive JLO [5]. Digital software analysis which is able to analyse preoperative MPTA and LDFA may help the surgeon to simulate the postoperative effective correction. To give the ideal indication, analysis is essential to define whether a DLO is required to avoid an excessive JLO.

There are several limitations to this study. First, this was a retrospective study without control group; however, the goal was to compare the real postoperative correction with the software simulation. Second, no clinical information was available, making it impossible to assess the correlation between the postoperative correction, especially for JLO changes and the clinical outcomes. Third, this study was

monocentric; therefore, these results cannot be extrapolated to all surgeons, and a multicentre study of the correction targets obtained before the ESSKA consensus would enable these results to be confirmed.

Conclusion

Analysis of patients who underwent an isolated OWHTO prior to the ESSKA guidelines, demonstrated a significant rate of post-operative tibial overcorrection and a resultant increased JLO. Pre-operative planning that considers the ESSKA guidelines, allows for better identification of those patients requiring a DFO or DLO and avoidance of resultant post-operative deformities.

Authors' contribution MO designed the protocol and performed statistical analysis. JA and LFR collected the Data. GM and MO wrote the initial draft and performed revisions of subsequent drafts. MO, KK and RK corrected the different versions of the draft. All the authors approved the submitted version.

Funding No funding was needed for this study.

Data availability Radiographic measurements were analysed with long leg alignment X-rays obtained for each patients.

Declarations

Conflict of interest GM, JA, RK and LRF have nothing to disclose. KK and MO are educational consultant for Newclip.

Ethical approval The local ethics committee approved our study protocol prior to investigation.

Consent to participate N/A.

Consent to publish N/A.

References

1. Akamatsu Y, Kumagai K, Kobayashi H, Tsuji M, Saito T (2018) Effect of Increased Coronal Inclination of the Tibial Plateau After Opening-Wedge High Tibial Osteotomy. *Arthroscopy* 34(7):2158–2169.e2
2. Babis GC, An K-N, Chao EYS, Larson DR, Rand JA, Sim FH (2008) Upper tibia osteotomy: long term results realignment analysis using OASIS computer software. *J Orthop Sci* 13(4):328–334
3. Babis GC, An K-N, Chao EYS, Rand JA, Sim FH (2002) Double level osteotomy of the knee: a method to retain joint-line obliquity. Clinical results. *J Bone Jt Surg Am* 84(8):1380–1388
4. Dawson MJ, Ollivier M, Menetrey J, Beaufils P (2022) Osteotomy around the painful degenerative varus knee: a 2022 ESSKA formal consensus. *Knee Surg Sports Traumatol Arthrosc.* <https://doi.org/10.1007/s00167-022-07024-0>
5. Feucht MJ, Winkler PW, Mehl J, Bode G, Forkel P, Imhoff AB, Lutz PM (2020) Isolated high tibial osteotomy is appropriate in less than two-thirds of varus knees if excessive overcorrection of the medial proximal tibial angle should be avoided. *Knee Surg Sports Traumatol Arthrosc* 29(10):3299–3309
6. Fujisawa Y, Masuhara K, Shiomi S (1979) The effect of high tibial osteotomy on osteoarthritis of the knee. An arthroscopic study of 54 knee joints. *Orthop Clin North Am* 10(3):585–608
7. Hernigou P, Medevielle D, Debeyre J, Goutallier D (1987) Proximal tibial osteotomy for osteoarthritis with varus deformity. A ten to thirteen-year follow-up study. *J Bone Jt Surg Am* 69(3):332–354
8. Jung W-H, Takeuchi R, Chun C-W, Lee J-S, Ha J-H, Kim J-H, Jeong J-H (2014) Second-look arthroscopic assessment of cartilage regeneration after medial opening-wedge high tibial osteotomy. *Arthroscopy* 30(1):72–79
9. Kim GW, Kang JK, Song EK, Seon JK (2020) Increased joint obliquity after open-wedge high tibial osteotomy induces pain in the lateral compartment: a comparative analysis of the minimum 4-year follow-up outcomes using propensity score matching. *Knee Surg Sports Traumatol Arthrosc* 29(10):3495–3502
10. Kley K, Bin Abd Razak HR, Khakha RS, Wilson AJ, van Heerwaarden R, Ollivier M (2021) Soft-Tissue Management and Neurovascular Protection During Opening-Wedge High Tibial Osteotomy. *Arthrosc Tech* 10(2):e419–e422
11. Kubota M, Kim Y, Sato T, Yamaguchi J, Ohno R, Kaneko K, Ishijima M (2020) The actual knee function was not influenced by joint line obliquity after open-wedge high tibial osteotomy. *SICOT-J* 6:4
12. Lobenhoffer PP, Van Heerwaarden RJ, Staubli AE, Jakob RP, Galla M, Agneskirchner JD (Eds.) (2013) Osteotomies around the Knee: Indications–Planning–Surgical techniques using plate fixators. Georg Thieme Verlag, Stuttgart, p b-002–10327
13. Loia MC, Vanni S, Rosso F, Bonasia DE, Bruzzone M, Dettoni F, Rossi R (2016) High tibial osteotomy in varus knees: indications and limits. *Joints* 4(2):98–110
14. Micicoi G, Grasso F, Kley K, Favreau H, Khakha R, Elhinger M, Jacquet C, Ollivier M (2021) Osteotomy around the knee is planned toward an anatomical bone correction in less than half of patients. *Orthop Traumatol Surg Res* 107(4):102897
15. Micicoi G, Jacquet C, Sharma A, LiArno S, Faizan A, Kley K, Parratte S, Ollivier M (2020) Neutral alignment resulting from tibial vara and opposite femoral valgus is the main morphologic pattern in healthy middle-aged patients: an exploration of a 3D-CT database. *Knee Surg Sports Traumatol Arthrosc* 29(3):849–858
16. Micicoi G, Khakha R, Kley K, Wilson A, Cerciello S, Ollivier M (2020) Managing intra-articular deformity in high Tibial osteotomy: a narrative review. *J Exp Orthop* 7(1):65
17. Micicoi G, Martz P, Jacquet C, Fernandes LR, Khakha R, Ollivier M (2021) High Tibial Osteotomy With Miniaci Planning Using Manual and Semiautomated Digital Measures. *Video Journal of Sports Medicine* 1(6):263502542110329
18. Nakayama H, Schröter S, Yamamoto C, Iseki T, Kanto R, Kurosaka K, Kambara S, Yoshiya S, Higa M (2018) Large correction in opening wedge high tibial osteotomy with resultant joint-line obliquity induces excessive shear stress on the articular cartilage. *Knee Surg Sports Traumatol Arthrosc* 26(6):1873–1878
19. Paley D (2002) Principles of Deformity Correction. Springer, Berlin Heidelberg, Berlin, Heidelberg
20. Park J-Y, Chang CB, Kang D-W, Oh S, Kang S-B, Lee MC (2019) Development and validation of a prediction model for knee joint line orientation after high tibial osteotomy. *BMC Musculoskelet Disord* 20(1):434
21. Razak HRBA, Micicoi G, Khakha RS, Ehlinger M, Faizan A, LiArno S, Ollivier M (2021) Patients with varus knee osteoarthritis undergoing high tibial osteotomy exhibit more femoral varus but similar tibial morphology compared to non-arthritic varus knees. *Knee Surg Sports Traumatol Arthrosc* 30(2):680–687

22. Saragaglia D, Blaysat M, Mercier N, Grimaldi M (2012) Results of forty two computer-assisted double level osteotomies for severe genu varum deformity. *International Orthopaedics (SICOT)* 36(5):999–1003
23. Saragaglia D, Chedal-Bornu B (2014) Computer-assisted osteotomy for valgus knees: Medium-term results of 29 cases. *Orthop Traumatol Surg Res* 100(5):527–530
24. Saragaglia D, Mercier N, Colle P-E (2010) Computer-assisted osteotomies for genu varum deformity: which osteotomy for which varus? *Int Orthop* 34(2):185–190
25. Saragaglia D, Rubens-Duval B, Chaussard C (2007) Doubles ostéotomies assistées par ordinateur dans les grands genu varum. *Rev Chir Orthopéd Rép l'Appareil Moteur* 93(4):351–356
26. Schuster P, Geßlein M, Schlumberger M, Mayer P, Mayr R, Oremek D, Frank S, Schulz-Jahrsdörfer M, Richter J (2018) Ten-Year Results of Medial Open-Wedge High Tibial Osteotomy and Chondral Resurfacing in Severe Medial Osteoarthritis and Varus Malalignment. *Am J Sports Med* 46(6):1362–1370
27. Song J-H, Bin S-I, Kim J-M, Lee B-S (2020) What Is An Acceptable Limit of Joint-Line Obliquity After Medial Open Wedge High Tibial Osteotomy? Analysis Based on Midterm Results. *Am J Sports Med* 48(12):3028–3035

Authors and Affiliations

Matthieu Ollivier¹  · Jae-Sung An¹ · Kristian Kley² · Raghbir Khakha³ · Levi Reina Fernandes⁴ · Grégoire Micicoi⁵

✉ Matthieu Ollivier
ollivier.matthieu@yahoo.fr

¹ APHM, CNRS, ISM, Institute of Movement and Locomotion, Department of Orthopedics and Traumatology, Aix Marseille University, Sainte-Marguerite Hospital, 270 Boulevard Sainte Marguerite, BP 29, 13274 Marseille, France

² Orthoprofis Hannover Luisenstraße, 10/11, 30539 Hannover, Germany

³ Guys and St. Thomas' Hospitals, Great Maze Pond, London SE1 9RT, England

⁴ Department of Orthopedics and Traumatology, Hospital Pedro Hispano, Matosinhos, Portugal

⁵ Institute for Locomotion and Sports, iULS-University, Pasteur 2 Hospital, University Côte d'Azur, UR2CA Nice, France