



HAL
open science

Characterization of two familial cases presenting with a syndromic specific learning disorder and carrying (17q;21q) unbalanced translocations

Julie Coton, Audrey Labalme, Marianne Till, Gerald Bussy, Sonia Krifi Papoz, Gaetan Lesca, Delphine Heron, Damien Sanlaville, Patrick Edery, Vincent Des Portes, et al.

► To cite this version:

Julie Coton, Audrey Labalme, Marianne Till, Gerald Bussy, Sonia Krifi Papoz, et al.. Characterization of two familial cases presenting with a syndromic specific learning disorder and carrying (17q;21q) unbalanced translocations. *Clinical Case Reports*, 2018, 6 (5), pp.827-834. 10.1002/ccr3.1450 . hal-04480033

HAL Id: hal-04480033

<https://hal.science/hal-04480033>

Submitted on 27 Feb 2024

HAL is a multi-disciplinary open access archive for the deposit and dissemination of scientific research documents, whether they are published or not. The documents may come from teaching and research institutions in France or abroad, or from public or private research centers.


L'archive ouverte pluridisciplinaire **HAL**, est destinée au dépôt et à la diffusion de documents scientifiques de niveau recherche, publiés ou non, émanant des établissements d'enseignement et de recherche français ou étrangers, des laboratoires publics ou privés.



Distributed under a Creative Commons Attribution - NonCommercial - NoDerivatives 4.0 International License

CASE REPORT

Characterization of two familial cases presenting with a syndromic specific learning disorder and carrying (17q;21q) unbalanced translocations

Julie Coton¹, Audrey Labalme¹, Marianne Till¹, Gerald Bussy^{2,3}, Sonia Krifi Papoz², Gaetan Lesca^{1,4}, Delphine Heron⁵, Damien Sanlaville^{1,4}, Patrick Edery^{1,4}, Vincent des Portes² & Massimiliano Rossi^{1,4} 

¹Centre de référence des anomalies du développement, Service de Génétique, Hospices Civils de Lyon, Bron, France

²Service de Neuropédiatrie, Hospices Civils de Lyon, Bron, France

³Service de Génétique, CHU de Saint Etienne, Saint Etienne, France

⁴Centre de Recherche en Neurosciences de Lyon, INSERM U1028 CNRS UMR5292, GENDEV Team, Bron, France

⁵Département de Génétique et Centre de Référence « Déficiences intellectuelles de causes rares », AP-HP, Groupe Hospitalier Pitié-Salpêtrière et GRC-Génétique des Déficiences Intellectuelles de Causes rares, Université Pierre et Marie Curie, F-75013 Paris, France

Correspondence

Massimiliano Rossi, Centre de référence des anomalies du développement, Service de Génétique, Hospices Civils de Lyon, 59 boulevard Pinel, 69677 Bron Cedex, France.
Tel: +33 4 27 85 55 73;
Fax: +33 4 27 85 52 45;
E-mail: massimiliano.rossi01@chu-lyon.fr

Key Clinical Message

Chromosomal microarray (CMA) can detect pathogenic copy number variations in 15–20% of individuals with intellectual disability and in 10% of patients with autism spectrum disorders. The diagnostic rate in specific learning disorders (SLD) is unknown. Our study emphasizes the usefulness of CMA in the diagnostic workout assessment of familial SLD.

Keywords

17q duplication, 21q deletion, chromosomal microarray, developmental coordination disorder, dyspraxia, specific language impairment, specific learning disorder.

Funding Information

No sources of funding were declared for this study.

Received: 1 September 2017; Revised: 19 January 2018; Accepted: 5 February 2018

Clinical Case Reports 2018; 6(5): 827–834

doi: 10.1002/ccr3.1450

Introduction

Specific learning disorders are defined as a failure to learn or use specific academic skills despite age-appropriate learning opportunities and instruction, in the absence of intellectual disability or autism spectrum disorder [1, 2]. SLD include a wide range of neurodevelopmental disorders, such as specific language impairment (SLI), including phonological and speech disorders; dyslexia, encompassing difficulties related to decoding and spelling words; developmental coordination disorder (DCD), affecting specifically fine motor performance; and dyscalculia, characterized by difficulties to acquire basic arithmetic skills [2]. The prevalence of SLD differs significantly in the studies reported in the literature (1,2–20%), due to the heterogeneity of the definition criteria and diagnostic assessments [1, 2].

Genetic factors play a role in the etiology of a subset of SLD. Here, we report the clinical and molecular cytogenetic characterization of four children from two unrelated families presenting with a syndromic SLD, and we review the previously reported genetic causes of these specific neurodevelopmental disorders.

Clinical Report

Family 1

Patient 1

This patient was the first child of healthy unrelated parents. Family history was unremarkable. He was born at term, after an uneventful pregnancy. At birth, his occipital-frontal circumference (OFC) was 35 cm (0 SD); his length was

48 cm (-2 SD); and his weight was 3140 g (10–25th centile). Apgar was 10/10 at 1 and 5 min, respectively.

The child had gastroesophageal reflux during infancy, treated until 2 years of age. Gross motor milestones were normally achieved: The boy started sitting at 8 months and walking unsupported at 13 months of age. He pronounced his first words at the age of 16 months but, subsequently, a severe speech delay was noticed: He was able to associate only two words at the age of 3 years and started making sentences at the age of 7 years. He had speech therapy and attended a mainstream school with specific educational support. Behavior disorders were noted including a significant anxiety, impulsivity, and emotional lability. He also had sleep disturbance with frequent awakening. Hearing test was normal, and ophthalmological examination revealed astigmatism and mild myopia.

He was referred for a genetic assessment at 10 years of age. His OFC was 55 cm ($+0.5$ SD); his stature was 142.7 cm ($+0.5$ SD); his weight was 38.4 kg (between 75th and 90th centile); and his body mass index (BMI) was 18.8 ($+1.5$ SD). Dysmorphic features were noted (Fig. 1), including frontal upsweep, widely spaced and sparse eyebrows, edematous eyelids, narrow palpebral fissures, bilateral epicanthus, anteverted nares, and mild micrognathia. Spatulate fingertips, camptodactyly of the 5th left finger and clinodactyly of the 3rd right toe were also noted (Table 1). Neurological examination was normal. A neuropsychological assessment was performed (Table 2). Raven's Progressive Matrices and Peabody Pictures Vocabulary Test ruled out ID, whereas a SLD was diagnosed, characterized by severe SLI and DCD.

Brain magnetic resonance imaging (MRI) was normal. A large genetic and metabolic assessment was normal, including thyroid and liver function tests, CK level, full blood count, blood ammonia, plasma amino acids, screening for CDG syndromes, blood acylcarnitines, screening for creatine deficiencies, standard karyotype, molecular analysis of *FMR1*, *MECP2*, and *ARX*.

Patient 2

Patient 2 was the younger brother of patient 1. He was born at term after an uneventful pregnancy. At birth, his OFC was 34.5 cm (-1 SD); his length was 49.5 cm (-1 SD); and his weight was 3150 g (10–25th centile). Apgar score was 9 and 10 at 1 min at 5 min, respectively. The child had gastroesophageal reflux during infancy. During the first year of life, he had laryngeal stridor which, subsequently, progressively disappeared. He started walking independently at 18 months of age and showed speech delay, learning difficulties, and hyperactivity requiring speech and occupational therapy. He attended a mainstream school with specific educational support. Hearing

test was normal, and ophthalmological examination showed hyperopia.

At the age of 9 years, his OFC was 55 cm ($+1.5$ SD); his stature was 139.3 cm ($+1.5$ SD); his weight was 37 kg (between 90th and 97th centile); and BMI was 19.1 ($+2$ SD). Clinical examination showed a long face, frontal upsweep, wide-spaced and sparse eyebrows, narrow and down-slanting palpebral fissures, edematous eyelids, left epicanthus, micrognathia, and a long philtrum (Fig. 1). He also had spatulate fingertips, bilateral clinodactyly of the 3rd toes, and overriding 4th toes (Table 1). Neurological examination was normal. Neuropsychological assessment was consistent with a SLD, including SLI and DCD, associated with attention deficit/hyperactivity disorder (ADHD; Table 2).

Patient 3

The youngest sibling of the family was born at term after an uneventful pregnancy. At birth, his OFC was measured at 34 cm (-1 SD); his length was 52 cm (-0.5 SD); and his weight was 3210 g (50th centile). Apgar score was 10/10 at 1 and 5 min, respectively. As his two brothers, he had gastroesophageal reflux requiring treatment until the age of 2 years. He started walking independently at the age of 18 months. He was not able to pronounce any word at the age of 2 years; he had speech and occupational therapy with progressive speech improvement and he started attending a mainstream school.

He was referred to the genetic department at the age of 5 years. His OFC was 51 cm (-0.5 SD); his stature was 112.9 cm ($+0.5$ SD); his weight was 22 kg (90th percentile); and his BMI was 17.2 ($+1.5$ SD). Clinical examination revealed dysmorphic features similar to his brothers (Fig. 1), including frontal upsweep, wide-spaced eyebrows, edematous eyelids, narrow palpebral fissures, bilateral epicanthus, right convergent strabismus, a long philtrum, low posterior hairline, and micrognathia. Clubbing of fingers was noted and there was a deep web space between the 2nd and the 3rd fingers, bilaterally (Table 1). Neurological examination was normal. Neuropsychological assessment revealed, as his brothers, a SLD including SLI and DCD (Table 2). Ophthalmological examination showed hyperopia. On the basis of the pedigree, an X-linked disorder was initially suspected.

Family 2

Patient 4

This girl was born at term after an uneventful pregnancy. Parents were in good health; there was no consanguinity. A maternal uncle had learning difficulties, epilepsy, and overweight but it was not possible to have more detailed information about his clinical picture.

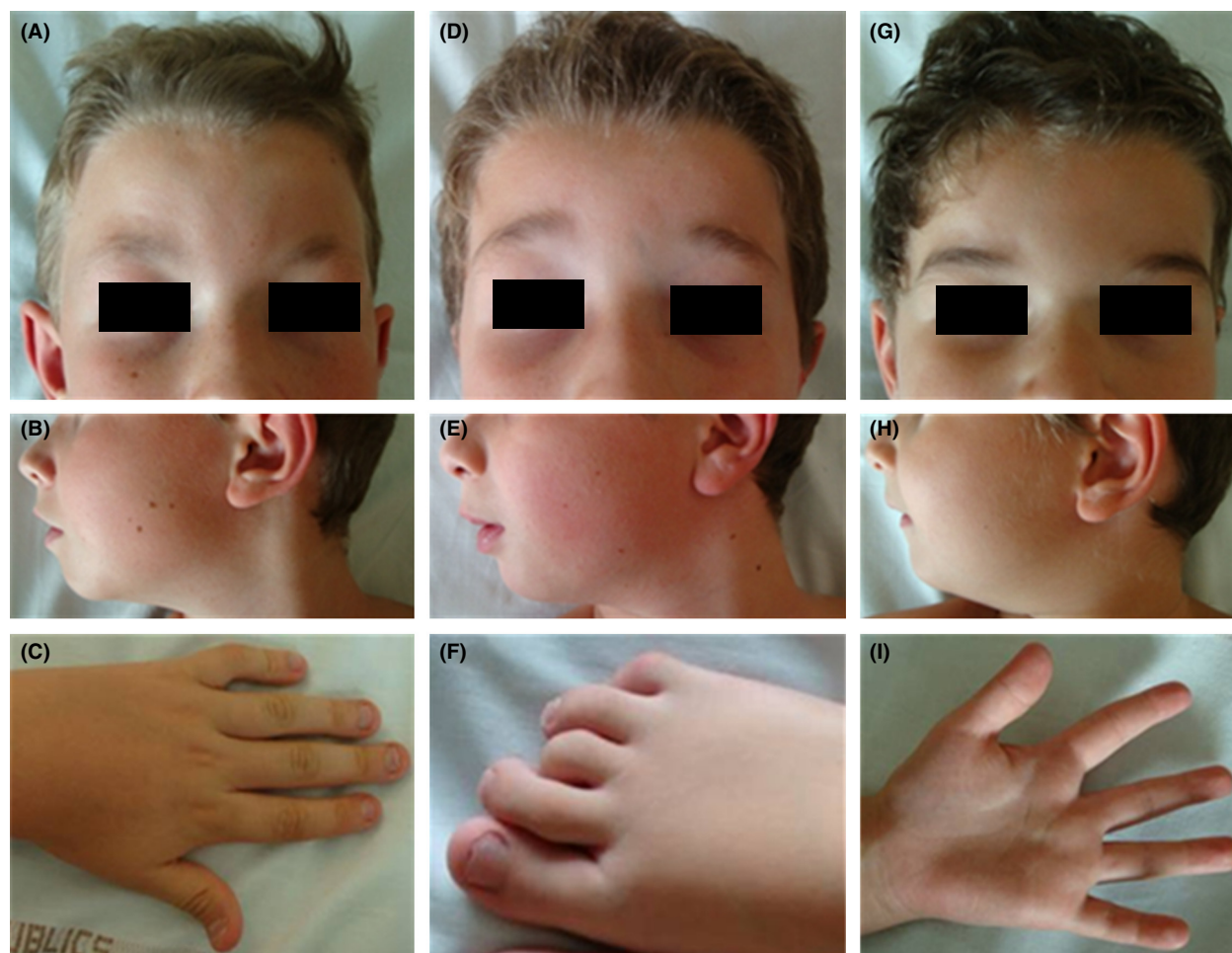


Figure 1. Clinical features of patients 1 (A–C), 2 (D–F), and 3 (G–I). Note frontal upsweep, widely spaced and sparse eyebrows, edematous eyelids, narrow palpebral fissures, epicanthus, mild micrognathia, and limb abnormalities including spatulate fingertips, camptodactyly of the 5th left finger in patient 1 (C), clinodactyly of the 3rd and 4th toes in patient 2 (F), and a deep web space between the 2nd and 3rd fingers in patient 3 (I).

At birth, patient 4's OFC was 33 cm (−1 SD); her length was 48 cm (−0.5 SD); and her weight was 2890 g (25–50th centile). She had recurrent otitis in the first year of life. She started walking independently at 16 months of age and she developed behavioral problems including stereotypic movements, echolalia, and an oppositional attitude, as well as learning difficulties. Overweight was also noted. She had speech and occupational therapy, and she attended a mainstream school with educational support.

She was examined at the age 3 years and 9 months. Her OFC was 48.4 cm (−1 SD); her stature was 98 cm (0 SD); her weight was 17 kg (90th percentile); and her BMI was 17.7 (+2 SD). Clinical examination showed dysmorphic features (Fig. 2) including edematous eyelids, bilateral epicanthus, apparent hypertelorism, a bulbous nasal tip, and thick lips (Table 1). Hands and feet were normal

as was neurological examination. Neuropsychological assessment was consistent with a SLD including SLI, DCD, and ADHD (Table 2).

Brain MRI was normal as was hearing test. Echocardiography, performed at birth because of a heart murmur, showed patent ductus arteriosus (PDA) and atrial septum defect. Repeated echocardiography at 6 years of age showed a persistent PDA with spontaneous resolution of the atrial septum defect.

Material and Methods

Chromosomal microarray was performed on a custom 244,000 (244k) or a 180,000 (180k) Agilent catalogue-oligonucleotide microarray (Human Genome CGH Microarray Kit 244A or SurePrint G3 Human CGH Microarray Kit, 4 × 180k; Agilent Technologies, Santa Clara, CA,

Table 1. Main clinical features of patients 1–4.

Patients	Family 1			Family 2
	1	2	3	4
Dysmorphic facial features	+	+	+	+
Frontal upsweep	+	+	+	–
Edematous eyelids	+	+	+	+
Wide-spaced eyebrows	+	+	+	+
Narrow palpebral fissures	+	+	+	–
Epicanthus	+	+	+	+
Anteverted nares	+	–	–	–
Bulbous nasal tip	–	–	–	+
Micrognathia	+	+	+	–
Limb abnormalities	+	+	+	–
Spatulate fingertips	+	+	+	–
Camptodactyly of fingers	+	–	–	–
Clinodactyly of toes	+	+	–	–
Gastroesophageal reflux	+	+	+	–
BMI (SD)	+1.5	+2	+1.5	+2
Congenital heart disease	–	–	–	+

SD, standard deviations.

USA) according to the manufacturer protocol in patients 1 and 4, respectively. Patients' DNA was compared with a control DNA on the custom 244k microarray or against DNA from two other patients with different diseases, according to the loop model for the catalogue 180k microarray. Concerning patient 1, given the first hypothesis of an X-linked disorder, the custom array was enriched in oligonucleotides on the X chromosome: The overall mean probe spacing was about 1530 bp and spacing between two probes on an X-linked ID gene was approximately 100 bp. The overall mean probe spacing on autosomes was around 28.5 kb.

Concerning patient 4, the catalogue 180K microarray had about 13 kb of mean probe spacing (www.genomics.agilent.com). Arrays were analyzed with Feature Extraction

9.5.3.1. Results were interpreted with DNA Analytics 4.0.85. The following parameters were used for interpretation: ADM-2, threshold: 5.0, window: 0.2 Mb, and cutoff: 0.25. A CNV was considered to have occurred if at least five contiguous oligonucleotides had an abnormal log₂ ratio for the 244k custom array or three contiguous oligonucleotides for the 180k catalogue array.

Results

Family 1

Chromosomal microarray, performed in patient 1, did not show pathogenic CNV on the X chromosome but revealed an unbalanced translocation between the long arms of chromosomes 17 and 21, leading to a 2.54 Mb 17q25.3qter duplication (78,502,910–81,060,000 bp) and a 3.65 Mb 21q22.3qter deletion (44,376,016–48,080,911 bp) (hg 19) (Fig. 3). Fluorescence in situ hybridization (FISH) analysis confirmed this result in patient 1 and showed the same unbalanced translocation in patients 2 and 3. FISH analysis revealed that the mother, the maternal grandfather, and a maternal aunt carried a balanced translocation (17q;21q); the father had normal chromosomes.

Family 2

Chromosomal microarray performed in patient 4 showed an unbalanced translocation between the long arms of chromosomes 17 and 21, leading to a 5.15 Mb 17q25.3qter duplication (7,611,654–81,060,000 bp) and a 1.66 Mb 21q22.3qter deletion (46,460,868–48,090,458 bp) (hg 19) (Fig. 4). FISH analysis confirmed the unbalanced translocation in the child and revealed that the mother and the maternal grandmother carried a balanced translocation (17q;21q); the father had normal chromosomes.

Table 2. Neuropsychological features of patients 1–4.

Patients	Family 1			Family 2	
	1	2	3	4	
Raven's progressive matrices	31 (25–50th percentile)	26 (10–25th percentile)	17 (50th percentile)	NE	Pathological threshold < 10th percentile
Peabody pictures vocabulary test	91	83	104	NE	Pathological threshold < 70
WISC IV/WPPSI III	NE	NE			Pathological threshold < 70
Verbal comprehension index			71	81	
Perceptual reasoning index			56	65	
Specific language impairment	+	+	+	+	
Developmental coordination disorder	+	+	+	+	
Attention deficit hyperactivity disorder	– (impulsivity)	+	– (impulsivity)	+	

NE, not evaluated.

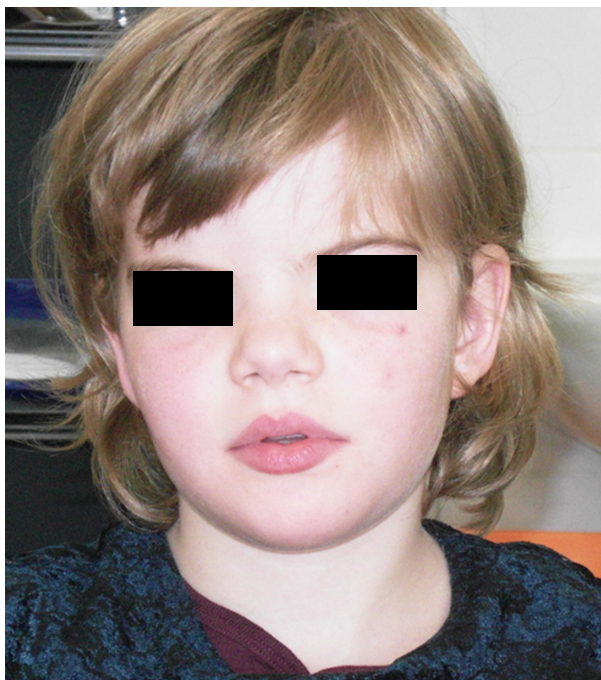

Figure 2. Clinical features of patients 4. Note edematous eyelids, bilateral epicanthus, apparent hypertelorism, a bulbous nasal tip, thick alae nasi, and thick lips.

The maternal uncle carried the same unbalanced translocation found in the child.

Discussion

We report the clinical and cytogenetic characterization of four children from two unrelated families with syndromic SLD, due to (17q;21q) unbalanced translocations resulting in partial 21q monosomy and partial 17q trisomy.

There is poor information available in the literature about this chromosomal abnormality. While several individuals have been reported carrying terminal 17q duplications associated with concomitant monosomy or trisomy of other chromosomes [3–9], the phenotype of pure 17q25.3 duplications has been reviewed only recently [10]. Deletions and duplications involving this chromosomal region appeared to be frequently associated with congenital heart diseases and neurological involvement [10]. It is interesting to notice that, among three patients carrying 17q25.3 duplications previously reported, one showed PDA as patient 4, and one had ADHD as patients 2 and 4 [10].

21q22 deletions have been reported in patients showing a wide phenotypic spectrum, including midline defects (frontonasal dysplasia, encephalocele, and corpus callosum agenesis) and learning disability [11]; syndromic

hypoplastic left heart [12]; and MCA/ID including microcephaly and ocular coloboma [13]. Thus, it is difficult to evaluate the effect of the 21q partial monosomy on the clinical phenotype observed in the patients here reported.

We reviewed the literature concerning the previously reported cytogenetic causes of SLD. Sex chromosome aneuploidies can be associated with SLI and dyslexia [14, 15]. The 7q11.23 duplication syndrome is frequently associated with speech and language difficulties, including speech delay and childhood apraxia of speech; interestingly, median IQ is 85, about 20% of patients have borderline intellectual abilities and only a minority of patients show ID (18%) [14, 16]. Velocardiofacial syndrome (“classical” 22q11.2 microdeletion syndrome), distal 22q11.2, and 16p11.2 microdeletions have been reported in association with a wide range of speech and language impairment [14, 17]. Among rarer chromosomal abnormalities, Cri-du-Chat syndrome, due to deletions of the short arm of chromosome 5, and 12p13.33 deletions have been reported to cause childhood apraxia of speech [18, 19]; microdeletions of 1p21.3, 10q22q23, 12p12.1, 15q11.2 and microduplications of 15q11.2q13 and 17p11.2p11.2 have been reported in association with SLI [14]; 2q37.3 deletions have been reported in association with DCD [20]. Monogenic causes of SLD are rare. In particular, mutations in *FOXP2* (OMIM: 605317), *FOXP1* (OMIM: 605515), *GRIN2A* (OMIM: 138253), *NRXN1* (OMIM: 600565), and *SETBP1* (OMIM 611060) have been reported in patients presenting with speech disorders as well as other neurobehavioral abnormalities [14, 21–24]. A few other loci for SLI have been mapped, such as SLI1 (OMIM: 606711) on chromosome 16q [25–27]; SLI2 (OMIM: 606712) on chromosome 19q [25]; SLI3 (OMIM: 607134) on chromosome 13q21 [28]; SLI4 (612514) on chromosome 7q35–36, including *CNTNAP2* (OMIM: 604569) [29, 30]; and SLI5 (OMIM: 615432) on chromosome 2q36.3, including *TM4SF20* (OMIM: 615404) [29, 31]. To the best of our knowledge, this is the first report of SLI and DCD associated with a chromosomal abnormality involving 21q22.3 and 17q25.3.

It is interesting to notice that a very small 21q22.3 deletion, including only four genes (*PCNT*, OMIM: 605925; *DIP2A*, OMIM: 607711; *S100B*, OMIM: 176990; and *PRMT2*, OMIM: 601961), has been reported in association with dyslexia; in particular, molecular variants in *DIP2A* and *S100B* have been reported in association with an increased risk of developmental dyslexia [32–34]. It might be possible to speculate that these genes might play a role in the SLD observed in the reported patients.

In conclusion, we report the clinical and molecular cytogenetic characterization of four children from two unrelated families, presenting with a SLD caused by

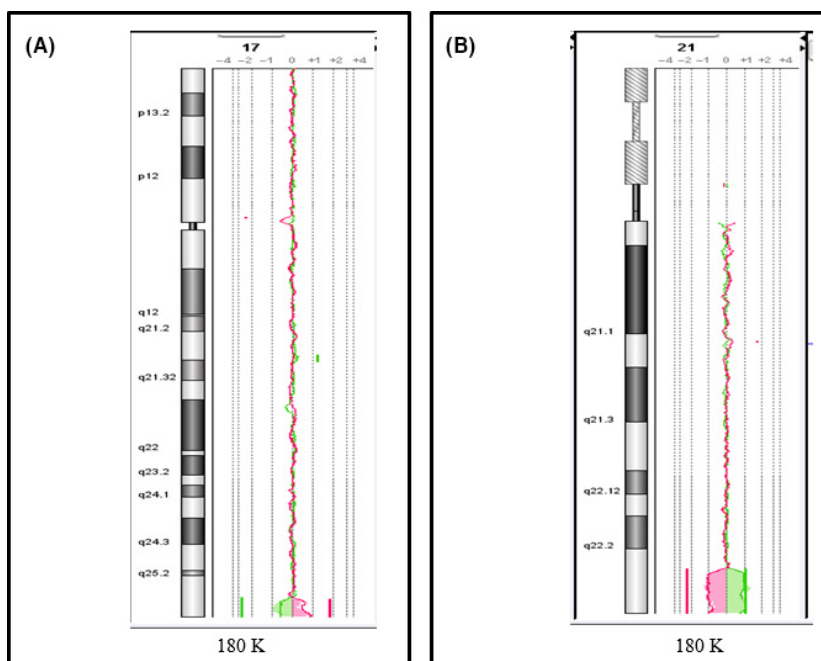


Figure 3. Cytogenetic features of patient 1, carrying an unbalanced translocation leading to 2.54 Mb 17q25.3 duplication spanning from 78,502,910 to 81,060,000 bp (hg19) (A), and a 3.65 Mb 21q22.3 deletion spanning from 44,376,016 to 48,080,911 bp (hg 19) (B).

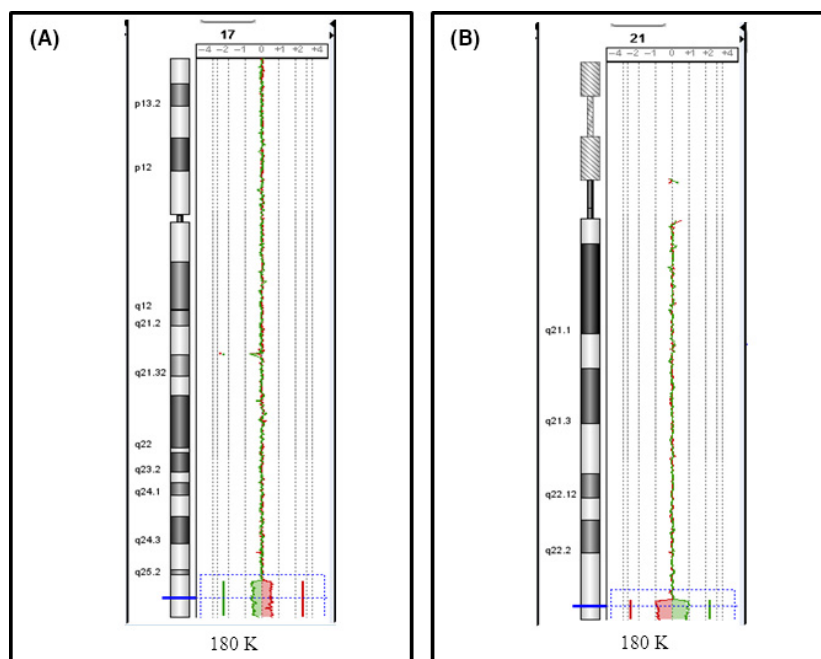


Figure 4. Cytogenetic features of patient 4, carrying an unbalanced translocation leading to a 5.15 Mb 17q25.3ter duplication, spanning from 7,611,654 to 81,060,000 bp (hg19) (A), and a 1.66 Mb 21q22.3ter deletion, spanning from 46,460,868 to 48,090,458 bp (hg 19) (B).

cryptic unbalanced translocations leading to 21q22.3 deletion and 17q25.3 duplication, thus expanding the spectrum of chromosomal abnormalities associated with these specific neurodevelopmental disorders.

From a practical point of view, CMA can detect pathogenic CNV in 15% to 20% of individuals with ID and/or multiple congenital abnormalities and in 10% of patients with autistic spectrum disorders (ASD) but the

diagnostic rate in SLD is currently unknown, given their heterogeneity. Our study emphasizes the usefulness of CMA in the diagnostic workout assessment of familial SLD.

Acknowledgment

We are very grateful to the patients and their family for their cooperation.

Authorship

JC and MR: collected the clinical and molecular cytogenetic information about the patients, reviewed the literature, and wrote the manuscript. DH and VdP: referred the patients and provided clinical data. GB and SKP: provided the neuropsychological data. AL, MT, and DS: provided the molecular cytogenetic data. VdP, GL, and PE: critically reviewed the manuscript.

Conflict of Interest

All the authors declare no conflict of interest.

References

- Fortes, I. S., C. S. Paula, M. C. Oliveira, I. A. Bordin, Mari. J. de Jesus, and L. A. Rohde. 2016. A cross-sectional study to assess the prevalence of DSM-5 specific learning disorders in representative school samples from the second to sixth grade in Brazil. *Eur. Child Adolesc. Psychiatry* 25:195–207.
- Tannock, R. 2013. Rethinking ADHD and LD in DSM-5: proposed changes in diagnostic criteria. *J. Learn. Disabil.* 46:5–25.
- Bacino, C. A., C. D. Kashork, N. A. Davino, and L. G. Shaffer. 2000. Detection of a cryptic translocation in a family with mental retardation using FISH and telomere region-specific probes. *Am. J. Med. Genet.* 92:250–255.
- Brisset, S., S. Kasakyan, A. C. L'Hermine, V. Mairovitz, E. Gautier, M. C. Aubry, et al. 2006. De novo monosomy 9p24.3-pter and trisomy 17q24.3-qter characterised by microarray comparative genomic hybridisation in a fetus with an increased nuchal translucency. *Prenat. Diagn.* 26:206–213.
- Fryns, J. P., C. Parloir, and H. Van den Berghe. 1979. Partial trisomy 17q. Karyotype: 46, XY, der(21), t(17;21)(q22;p13). *Hum. Genet.* 49:361–364.
- Marques, F., R. Heredia, C. de Oliveira, M. T. Cardoso, J. Mazzeu, and R. Pogue. 2015. Partial trisomy 17q and partial monosomy 20q in a boy with craniosynostosis. *Am. J. Med. Genet. Part A* 167A:412–416.
- McCann, E., E. Sweeney, J. Sills, P. May, and S. Smith. 2006. Pfeiffer-type cardiocranial syndrome: a patient with features of this condition and with an unbalanced subtelomeric rearrangement involving chromosomes 1p and 17q. *Clin. Dysmorphol.* 15:81–84.
- Sarri, C., J. Gyftodimou, D. Avramopoulos, M. Grigoriadou, W. Pedersen, E. Pandelia, et al. 1997. Partial trisomy 17q22-qter and partial monosomy Xq27-qter in a girl with a de novo unbalanced translocation due to a postzygotic error: case report and review of the literature on partial trisomy 17qter. *Am. J. Med. Genet.* 70:87–94.
- Velagaleti, G. V., S. M. Jalal, R. C. Michaelis, T. F. Rowe, J. R. Nichols, and L. H. Lockhart. 2003. Molecular cytogenetic characterization of a de novo unbalanced translocation leading to trisomy 17q25→qter and monosomy 18p11.3→pter in a girl with dysmorphic features. *Clin. Dysmorphol.* 12:29–33.
- Probst, F. J., R. A. James, L. C. Burrage, J. A. Rosenfeld, T. P. Bohan, C. H. Ward Melver, et al. 2015. De novo deletions and duplications of 17q25.3 cause susceptibility to cardiovascular malformations. *Orphanet J. Rare Dis.* 10:75.
- Guion-Almeida, M. L., A. Richieri-Costa, F. S. Jehee, M. R. Passos-Bueno, and R. M. Zechi-Ceide. 2012. Frontonasal dysplasia, callosal agenesis, basal encephalocele, and eye anomalies syndrome with a partial 21q22.3 deletion. *Am. J. Med. Genet. Part A* 158A:1676–1679.
- Ciocca, L., M. C. Digilio, A. Lombardo, G. D'Elia, A. Baban, R. Capolino, et al. 2015. Hypoplastic left heart syndrome and 21q22.3 deletion. *Am. J. Med. Genet. Part A* 167A:579–586.
- Fukai, R., Y. Hiraki, G. Nishimura, M. Nakashima, Y. Tsurusaki, H. Saitsu, et al. 2014. A de novo 1.4-Mb deletion at 21q22.11 in a boy with developmental delay. *Am. J. Med. Genet. Part A* 164A:1021–1028.
- Barnett, C. P., and B. W. van Bon. 2015. Monogenic and chromosomal causes of isolated speech and language impairment. *J. Med. Genet.* 52:719–729.
- Simpson, N. H., L. Addis, W. M. Brandler, V. Slonims, A. Clark, J. Watson, et al. 2014. Increased prevalence of sex chromosome aneuploidies in specific language impairment and dyslexia. *Dev. Med. Child Neurol.* 56:346–353.
- Mervis, C. B., C. A. Morris, B. P. Klein-Tasman, S. L. Velleman, and L. R. Osborne. 2015. 7q11.23 duplication syndrome. In: R. A. Pagon, M. P. Adam, H. H. Ardinger, S. E. Wallace, A. Amemiya, L. J. H. Bean, T. D. Bird, C. T. Fong, H. C. Mefford, R. J. H. Smith, K. Stephens, eds. *GeneReviews*® [Internet], Seattle, WA.
- Raca, G., B. S. Baas, S. Kirmani, J. J. Laffin, C. A. Jackson, E. A. Strand, et al. 2013. Childhood apraxia of speech (CAS) in two patients with 16p11.2 microdeletion syndrome. *Eur. J. Hum. Genet.* 21:455–459.
- Marignier, S., G. Lesca, J. Marguin, G. Bussy, D. Sanlaville, and V. des Portes. 2012. Childhood apraxia of speech

- without intellectual deficit in a patient with cri du chat syndrome. *Eur. J. Med. Genet.* 55:433–436.
19. Thevenon, J., P. Callier, J. Andrieux, B. Delobel, A. David, S. Sukno, et al. 2013. 12p13.33 microdeletion including ELKS/ERC1, a new locus associated with childhood apraxia of speech. *Eur. J. Hum. Genet.* 21:82–88.
 20. Ogura, K., K. Takeshita, C. Arakawa, K. Shimojima, and T. Yamamoto. 2014. Neuropsychological profiles of patients with 2q37.3 deletion associated with developmental dyspraxia. *Am. J. Med. Genet. Part B* 165B:684–690.
 21. Horn, D., J. Kapeller, N. Rivera-Brugues, U. Moog, B. Lorenz-Depiereux, S. Eck, et al. 2010. Identification of FOXP1 deletions in three unrelated patients with mental retardation and significant speech and language deficits. *Hum. Mutat.* 31:E1851–E1860.
 22. Lai, C. S., S. E. Fisher, J. A. Hurst, F. Vargha-Khadem, and A. P. Monaco. 2001. A forkhead-domain gene is mutated in a severe speech and language disorder. *Nature* 413:519–523.
 23. Lesca, G., G. Rudolf, N. Bruneau, N. Lozovaya, A. Labalme, N. Boutry-Kryza, et al. 2013. GRIN2A mutations in acquired epileptic aphasia and related childhood focal epilepsies and encephalopathies with speech and language dysfunction. *Nat. Genet.* 45:1061–1066.
 24. Turner, S. J., A. T. Morgan, E. R. Perez, and I. E. Scheffer. 2015. New genes for focal epilepsies with speech and language disorders. *Curr. Neurol. Neurosci. Rep.* 15:35.
 25. SLI Consortium (SLIC). 2004. Highly significant linkage to the SLI1 locus in an expanded sample of individuals affected by specific language impairment. *Am. J. Hum. Genet.* 74:1225–1238.
 26. Li, N., and C. W. Bartlett. 2012. Defining the genetic architecture of human developmental language impairment. *Life Sci.* 90:469–475.
 27. Newbury, D. F., L. Winchester, L. Addis, S. Paracchini, L. L. Buckingham, A. Clark, et al. 2009. CMIP and ATP2C2 modulate phonological short-term memory in language impairment. *Am. J. Hum. Genet.* 85:264–272.
 28. Bartlett, C. W., J. F. Flax, M. W. Logue, V. J. Vieland, A. S. Bassett, P. Tallal, et al. 2002. A major susceptibility locus for specific language impairment is located on 13q21. *Am. J. Hum. Genet.* 71:45–55.
 29. Bartlett, C. W., J. F. Flax, M. W. Logue, B. J. Smith, V. J. Vieland, P. Tallal, et al. 2004. Examination of potential overlap in autism and language loci on chromosomes 2, 7, and 13 in two independent samples ascertained for specific language impairment. *Hum. Hered.* 57:10–20.
 30. Centanni, T. M., J. N. Sanmann, J. R. Green, J. Iuzzini-Seigel, C. Bartlett, W. G. Sanger, et al. 2015. The role of candidate-gene CNTNAP2 in childhood apraxia of speech and specific language impairment. *Am. J. Med. Genet. Part B* 168:536–543.
 31. Wiszniewski, W., J. V. Hunter, N. A. Hanchard, J. R. Willer, C. Shaw, Q. Tian, et al. 2013. TM4SF20 ancestral deletion and susceptibility to a pediatric disorder of early language delay and cerebral white matter hyperintensities. *Am. J. Hum. Genet.* 93:197–210.
 32. Kong, R., S. Shao, J. Wang, X. Zhang, S. Guo, L. Zou, et al. 2015. Genetic variant in DIP2A gene is associated with developmental dyslexia in Chinese population. *Am. J. Med. Genet. Part B* 171:203–208. <https://doi.org/10.1002/ajmg.b.32392>.
 33. Matsson, H., M. Huss, H. Persson, E. Einarsdottir, E. Tiraboschi, J. Nopola-Hemmi, et al. 2015. Polymorphisms in DCDC2 and S100B associate with developmental dyslexia. *J. Hum. Genet.* 60:399–401.
 34. Poelmans, G., J. J. Engelen, J. Van Lent-Albrechts, H. J. Smeets, E. Schoenmakers, B. Franke, et al. 2009. Identification of novel dyslexia candidate genes through the analysis of a chromosomal deletion. *Am. J. Med. Genet. Part B* 150B:140–147.