



HAL
open science

Extracorporeal Photopheresis Reduces Fibrotic and Inflammatory Transcriptomic Biological Marker of Chronic Antibody-mediated Kidney Rejection

Arnaud Lionet, Marine van Triempon, Martin Figeac, Victor Fages, Jean-Baptiste Gibier, François Provot, Mehdi Maanaoui, Nicolas Pottier, Christelle Cauffiez, François Glowacki

► **To cite this version:**

Arnaud Lionet, Marine van Triempon, Martin Figeac, Victor Fages, Jean-Baptiste Gibier, et al.. Extracorporeal Photopheresis Reduces Fibrotic and Inflammatory Transcriptomic Biological Marker of Chronic Antibody-mediated Kidney Rejection. *Transplantation Direct*, 2024, 10 (3), pp.e1587. 10.1097/TXD.0000000000001587 . hal-04479830

HAL Id: hal-04479830

<https://hal.science/hal-04479830>

Submitted on 5 Apr 2024

HAL is a multi-disciplinary open access archive for the deposit and dissemination of scientific research documents, whether they are published or not. The documents may come from teaching and research institutions in France or abroad, or from public or private research centers.

L'archive ouverte pluridisciplinaire **HAL**, est destinée au dépôt et à la diffusion de documents scientifiques de niveau recherche, publiés ou non, émanant des établissements d'enseignement et de recherche français ou étrangers, des laboratoires publics ou privés.

OPEN

Extracorporeal Photopheresis Reduces Fibrotic and Inflammatory Transcriptomic Biological Marker of Chronic Antibody-mediated Kidney Rejection

Arnaud Lionet^{1,2}, Marine Van Triempon, MD,¹ Martin Figeac, MD, PhD,³ Victor Fages, MD,¹ Jean-Baptiste Gibier, MD, PhD,⁴ François Provot, MD,¹ Mehdi Maanaoui, MD,^{1,5} Nicolas Pottier, PharmD, PhD,² Christelle Cauffiez, PhD,² and François Glowacki, MD, PhD^{1,2}

Background. The benefit of extracorporeal photopheresis on the course of kidney transplant rejection is unknown. The aim of our study was to investigate the variations in transcriptomics on graft biopsies when extracorporeal photopheresis was used to treat chronic humoral rejection after kidney transplantation. **Methods.** We retrospectively analyzed the mRNA expression of 770 genes of interest in graft biopsies performed before and after treatment. Eight patients received an average of 23 extracorporeal photopheresis sessions over 4 mo between the 2 biopsies. **Results.** Transcriptomic analysis of the graft biopsies identified a significant (adjusted $P < 0.05$) increase in *CAV1* mRNA in all patients and a significant decrease in *CD19*, *IL21*, *PAX5*, and *SFTPA2* mRNAs in 7 of 8 patients. **Conclusions.** In patients treated with extracorporeal photopheresis for chronic humoral rejection after renal transplantation, omic analysis of repeated biopsies shows a reduction in fibrotic and inflammatory transcriptomic biologicals markers.

<http://links.lww.com/TXD/A615>

(*Transplantation Direct* 2024;10: e1587; doi: 10.1097/TXD.0000000000001587.)

Received 5 October 2023. Revision received 27 November 2023.

Accepted 6 December 2023.

¹ Department of Nephrology and Kidney Transplantation, University Hospital Huriez, CHU-Lille, Lille, France.

² CNRS, Inserm, CHU Lille, Institut Pasteur de Lille, UMR9020-U1277—CANTHER, University of Lille, Lille, France.

³ CNRS, Inserm, CHU Lille, Institut Pasteur de Lille, US 41—UAR 2014—PLBS, University of Lille, Lille, France.

⁴ Pathology Department, CHU-Lille, France.

⁵ CNRS, Inserm, CHU Lille, Institut Pasteur de Lille, UMRU1190 Translational Research for Diabetes, University of Lille, Lille, France.

Correspondence: Arnaud Lionet, MD, Department of Nephrology and Kidney transplantation, University Hospital Huriez, Polonovski street 1, 59037 Lille, France. (arnaud.lionet@chru-lille.fr).

A.L., M.V.T., V.F., M.M., F.P., and F.G. participated in patient care. A.L., V.F., M.M., J.B.G., N.P., and C.C. participated in the writing of the article. A.L., M.V.T., M.F., N.P., F.P., C.C., and F.G. participated in research design. A.L., M.V.T., M.F., and F.G. participated in data analysis. J.B.G. and M.F. participated in the performance of the research (histologic and transcriptomic analysis).

A.L. have received honorarium from Therakos to conduct a Workshop on photopheresis. Other authors of this manuscript have no conflicts of interest to disclose.

This research did not receive any specific grant from funding agencies in the public, commercial, or not-for-profit sectors.

Supplemental digital content (SDC) is available for this article. Direct URL citations appear in the printed text, and links to the digital files are provided in the HTML text of this article on the journal's Web site (www.transplantationdirect.com).

Copyright © 2024 The Author(s). *Transplantation Direct*. Published by Wolters Kluwer Health, Inc. This is an open-access article distributed under the terms of the Creative Commons Attribution-Non Commercial-No Derivatives License 4.0 (CCBY-NC-ND), where it is permissible to download and share the work provided it is properly cited. The work cannot be changed in any way or used commercially without permission from the journal.

ISSN: 2373-8731

DOI: 10.1097/TXD.0000000000001587

Despite progress over the past decade, long-term survival of kidney graft remains a challenging issue for nephrologists.¹ Chronic antibody-mediated rejection (cABMR) is one of the leading causes of kidney-allograft failure and is often the result of insufficient immunosuppression or poor adherence to immunosuppressive treatment.² cABMR is viewed as a continuous process that can begin any time after transplantation with great clinical heterogeneity, ranging from subclinical rejection to allograft loss.³ The diagnosis of cABMR is based on specific histological lesions as described in the Banff classification with or without detection of donor-specific antibodies (DSA).⁴ Histological criteria use semiquantitative score for microvascular inflammation, C4d staining, chronic glomerulopathy, peritubular capillary basement membrane multilayering, and transplant arteriopathy, that together define cABMR.⁵ cABMR can be dichotomized into active cABMR and chronic inactive cABMR based on the presence of a criterion of antibody interaction with the endothelium. If this criterion is present on the biopsy, the cABMR is defined as active. If this criterion is absent on the biopsy but have been previously documented, the cABMR is defined as inactive.⁴ Given the complexity and subjectivity associated with this classification, new transcriptomic tools have been developed to better define cABMR, with in particular, the inclusion of the “increased expression of gene transcripts in the biopsy tissue strongly associated with ABMR” in the Banff definition of cABMR since 2017.⁴ Nevertheless, a more precise understanding of allograft rejection physiopathology and phenotypes is still critical, especially to develop specific and effective

treatments for this condition. Indeed, current therapeutic strategies are mainly based on the results of retrospective data or pilot trials, such as intravenous immunoglobulins (IVIg) and Rituximab, complement blockade, Bortezomib, or interference with IL6 (Interleukin 6)/IL6 receptor signaling.⁶ The benefit of such therapies remains unproven and their cost and adverse effects have to be assessed in clinical practice.

Extracorporeal photopheresis (ECP) is an immunomodulating apheresis therapy, that has proven to be effective in graft versus host disease.⁷ The exact mechanism of action is not fully understood but ECP appears to exert an immunomodulatory effect with a decrease in proinflammatory cytokines and effector T cells and an increase in antiinflammatory cytokines and regulatory T cells, which contribute to allograft acceptance without infectious adverse events.⁸ In addition, a direct antifibrotic effect of ECP has recently been suggested in a mouse lung transplantation model.^{9,10} Thus, this technique could be interesting in the management of cABMR and its use in kidney transplantation is beginning to be evaluated.^{11,12}

In this study, we investigated the effects of ECP in cABMR using transcriptomic analysis. We report the results of 8 patients with biopsy-proven cABMR that were treated with ECP and in whom we performed kidney biopsies with histological and transcriptomic analyses before and after treatment.

MATERIALS AND METHODS

Data Source and Ethical Statement

This study was performed according to the Declaration of Helsinki and the Declaration of Istanbul. No organs were procured from prisoners. Ethical committee was not required, according to French laws and the local institutional review board (Centre Hospitalier Universitaire, Lille), as the study was monocentric and observational. Informed consent was obtained from all subjects. Once fully pseudonymized, the dataset was processed under French and EU data protection laws and regulations (Commission Nationale de l'Informatique et des Libertés, CNIL).

Patients and Design

We present the results of a retrospective single-center case series of 8 kidney transplant recipients with biopsy-proven cABMR according to Banff classification and treated by ECP therapy between 2016 and 2020 at Lille University Hospital, France.

Inclusion criteria were as follows:

- age >18 y old,
 - transplant kidney recipients,
 - with biopsy-proven cABMR according to Banff 2017 criteria,
 - who failed or were not eligible to standard treatment,
 - decision to treat with ECP according to the transplant team's habits,
 - patients who have been treated with ECP for at least 3 mo,
 - with a control biopsy performed after a minimum of 3 mo of treatment with ECP, and
 - patient consent to participate in this retrospective study.
- Exclusion criteria were as follows:
- absence of peripheral veins or AVF, which allow ECP to be performed, and
 - opposition of the patient or Patients unable to understand the clinical trial and/or to give consent.

Half of the patients met the criteria for active cABMR and the other half for inactive cABMR, but all them had a microvascular inflammation score (g+ptc) ≥ 2 . Decision to initiate ECP was taken in view of the existence of microvascular inflammation associated with cABMR, after consensus within the nephrology team and after information and agreement of the patients. The objective of this therapy was to provide a salvage therapy in patients with or without previous acute ABMR who failed or were not eligible to standard treatment (IVIg, steroids, and plasmapheresis). ECP was prescribed on top of previous treatment regimen without concomitant new immunosuppressive drugs. Patients were monitored for kidney function and adverse events and underwent systematic biopsies at the end of ECP treatment to assess histologically the impact of ECP on cABMR according to Banff classification. Transcriptomic analysis was carried out for each biopsy. All patients gave their consent to participate in this study.

ECP Procedure and Characteristics

During each ECP session, patient blood was collected from a peripheral venous catheter or from an arteriovenous fistula (AVF). The peripheral blood mononuclear cells were separated by cytopheresis, treated with methoxsalen (Uvadex, THERAKOS, Wokingham, United Kingdom), exposed to UV A light, and, finally, the irradiated cells were reinfused into the patient. All ECP sessions have been performed with the Cellex THERAKOS (Therakos Lotus Park, London, United Kingdom). ECP procedure was based on an induction phase with 2 ECP sessions per week during the first 6 wks, then 1 session weekly from week 6 to 12 and a maintenance phase with 2 ECP sessions monthly until repeated biopsy. ECP characteristics were recorded, such as duration of treatment, number of ECP sessions, ECP session duration, vascular access, blood volume processed, cellular collection volume, number of white blood cells, erythrocytes and platelets, and % of treated cells. All patients received photoprotection recommendations.

Kidney Biopsy and NanoString Gene-expression Profiling

Each patient had biopsy-proven cABMR and systematic biopsy after 3 mo of ECP treatment. The reasons for the biopsies that led to the initial diagnosis of cABMR were either for increased creatinine, increased proteinuria, or the emergence of DSA. Ten- μm -thick sections were obtained from frozen or alcohol-formalin-acetic acid (AFA) fixed-paraffin embedded tissue-block to collect the 300ng of RNA required for analyses. RNA was isolated and extracted using the tissue RNA Isolation Kit (Roche Diagnostics GmbH, Mannheim, Germany), and then concentration was assessed with the NanoDrop spectrophotometer (Thermo Fisher Scientific Inc., Waltham, MA, United States); 300 ng of total RNA from each sample was then hybridized to the nCounter Human Organ Transplant Panel (NanoString Technologies, Seattle, WA, United States). This panel evaluates the expression of 758 target genes and 12 internal reference genes for data normalization. Expression data were normalized and analyzed with the nSolver Analysis Software (version 4.0.70).

Statistical and Bioinformatic Analyses

Baseline characteristics of patients and ECP characteristics are described as means and standard deviations for continuous variables.

For transcriptomic analysis, normalization was done using the 12 housekeeping genes included in the panel. Differential expression was done comparing paired samples after and before treatment (DESeq2 bioconductor package). *P* values were adjusted for multiple testing using Benjamini Hochberg procedure. We used a volcano plot to show differential gene expression on kidney transplant biopsies and select differentially expressed gene based. The selection of genes showing a significant difference in expression before and after PCE was based on the adjusted $P < 0.05$ and a fold change > 1.25 . We used boxplots with medians and interquartile ranges (IQRs) to represent RNA counts (expressed in \log_2) per sample with a significant difference, on biopsies performed before and after ECP. Further analyses were carried out in the R language using the DeSeq2 package.

RESULTS

Baseline Characteristics of Kidney-allograft Recipients

Baseline clinical characteristics of the 8 included patients are described in Table 1. The mean age was 45 y. Fifty percent of patients were male; 50% of patients were undergoing second transplantation. All kidneys were from deceased donors, and 5 patients (62.5%) had previously experienced acute ABMR. All patients were classified as cABMR on kidney biopsy according to Banff classification at time of biopsy. The interval between transplantation and cABMR ranged from 2.9 to 166 mo. Mean plasmatic creatinine at time of cABMR was 1.8 mg/dL, and 3 patients had anti-HLA DSAs.

ECP Procedure and Characteristics

Description of ECP procedure and characteristics are detailed in Supplemental data (Table S1, SDC, <http://links.lww.com/TXD/A614>) for each patient. Mean duration of ECP treatment was 3.9 mo with a mean number of sessions of 23 and a mean duration of 109 min per session. Patient number 8 had a longer ECP treatment duration compared with others (8.3 mo), as she was under anticoagulant therapy for brachiocephalic trunk stenosis, which did not allow us to perform repeated biopsy after 3 mo as scheduled. Six patients (75%) had an arteriovenous fistula that was used for ECP, whereas peripheral venous catheter was used for 2 patients. Mean blood volume processed was 1523 mL. Numbers and percentages of treated cells were used as quality controls. We did not observe any adverse event associated with ECP treatment.

Biological and Graft Evaluation

Biological and histological graft characteristics are described in Supplemental data (Tables S2 and S3, SDC, <http://links.lww.com/TXD/A614>), for each patient, before and after ECP treatment. Renal function remained stable after ECP for 3 patients, decreased for 1 patient, and increased for 4 patients. Comparison of microvascular inflammation (g+ptc) scores on biopsies before and after treatment showed an improvement in 5, a stability in 1 patient and a worsening in 2 patients. DSAs data before and after ECP were available for 3 patients; we found no significant difference on DSA titers evolution after treatment.

Molecular Marker of cABMR Before and After ECP

Data from the nanostring analysis can be viewed on the Gene Expression Omnibus public repository (ID: GSE240778). To identify differential gene expression on kidney transplant biopsies and select genes of interest, we used a Volcano plot that is represented in Figure 1. We identified 8 genes that were significantly modulated after ECP treatment (adjusted $P < 0.05$) (Figure 2). In particular, transcriptomic analysis revealed that only expression of *CAV1* was increased in all patients, whereas *CD19*, *IL21*, *PAX5*, and *SFTPA2* expression was decreased for 7 out of 8 patients between the 2 biopsies. There was also a significant decrease in *POU2AF1*, *PF4*, and *SOST* mRNA expression but with greater interindividual variations.

DISCUSSION

In this study, we evaluated the potential benefits of ECP in the treatment of cABMR using transcriptomic analysis. The most striking result is a switch in transcripts toward an antifibrotic biologic marker with an increase in Caveolin-1 (*CAV1*) expression and a decrease in *SFTPA2* expression. Increased *CAV1* expression was observed in all our patients between the 2 biopsies. These results echo the work of Liu et al recently reported which suggests a direct antifibrotic action of ECP.^{9,10} In this study, the authors demonstrated that ECP decreases bionchiolar fibrosis in a murine lung allograft model by limiting TGF- β bioavailability through the production of decorin. *CAV1* also plays a crucial role in the regulation of TGF- β signaling through the internalization and degradation of TGF- β receptors.^{13–15} Its role in pathological tissue fibrosis has been demonstrated in *CAV1*-deficient (*CAV1*^{-/-}) mouse models that develop exacerbated fibrosis with abundant connective tissue deposition.^{14,16} Interestingly, *CAV1* gene transfer via adenovirus vectors in *CAV1*^{-/-} mice induces a reduction in collagen deposition in bleomycin-induced lung fibrosis models.¹⁷ Moreover, *CAV1*^{-/-} mice display exacerbated renal interstitial fibrosis after unilateral ureteral obstruction, a preclinical model of TGF- β -induced renal fibrogenesis.¹⁸ *CAV1* function is also of potential interest in the context of kidney transplantation.^{19–21} Indeed, 2 studies reported that donor *CAV1* single nucleotide variation could influence graft fibrosis and long-term outcome after kidney transplantation.^{20,21} In a recent study, Gambella et al²² reported that Caveolin-1 is overexpressed in cABMR and could be a key marker in patients with cABMR. Overexpression of *CAV1* could thus be a compensatory mechanism to the fibrotic lesions induced by cABMR but both its kinetics and prognostic significance remain to be determined. There are 2 arguments in favor of an elevation of *CAV1* under the action of ECP rather than by the spontaneous evolution of cABMR natural history. First, we observed in our patients concomitantly with the elevation of *CAV1*, a decrease in *SFTPA2* (surfactant protein A2), which has been described to exert a profibrotic effect in kidney.²³ Second, this antifibrotic effect of ECP occurs while we observe a decrease in the expression of mRNAs of proteins involved in inflammation (*IL-21*) and in the allogeneic response (*CD19* and *PAX5*). *IL-21* is a key inflammatory cytokine implicated in humoral immunity. Murine models have shown that *IL-21* is deleterious once rejection is triggered. Indeed, in a kidney transplant

Downloaded from http://journals.lww.com/transplantationdirect by BNDMfsePHKav1ZEoum1tIQINka+kLLhEZgbs Hhd4XMI0hCymWCX1AMN7Qp/IIQIH3D3DD006Ry7TVSF14Cf3V/C4/OAVpDDa8KKG/V0Vmy+78= on 04/08/2024

TABLE 1.
Patient baseline characteristics at ECP initiation

Patient number	1	2	3	4	5	6	7	8
Age (at time of cABMR)	46	38	51	51	38	52	53	33
Gender	F	M	F	F	M	M	F	M
Graft rank	2	1	2	1	2	2	1	1
cPRA	98%	0%	90%	0%	0%	99%	40%	0%
ESRD cause	Vesicoureteral reflux	Vesicoureteral reflux	Renal dysplasia	Vascular	Tubulointerstitial	Dense deposit disease	FSGS	Vascular
Deceased donor	Y	Y	Y	Y	Y	Y	Y	Y
Former acute ABMR	Y	Y	N	N	Y	Y	N	Y
Type of rejection	a-CABMR	a-CABMR	na-CABMR	na-CABMR	a-CABMR	na-CABMR	na-CABMR	a-CABMR
Interval between transplantation and cABMR (in mo)	2.9	81.7	22.4	15.6	138	52.4	166	39.5
Reasons for biopsy								
Increased creatinine	Y	Y	Y	N	Y	N	N	Y
Increased proteinuria	N	Y	N	Y	N	Y	Y	Y
DSA (Specificity)	Y (Cw5)	N	N	N	Y (A1)	Y	N	Y (A1)
Biology and immunology at time of cABMR								
Creatinine (mg/dL)	1.7	1.4	1.4	2.2	2.8	1.3	1.4	2.1
Albuminuria/creatinine ratio (mg/g)	47	865	43	2600	66	424	1700	851
Number of anti-HLA DSAs	1	NA	0	0	1	0	0	NA
Immunosuppression at time of cABMR								
Tacrolimus	Y	Y	Y	Y	Y	Y	Y	Y
Mycophenolate mofetil	Y	Y	N	Y	Y	Y	N	Y
Everolimus	N	N	Y	N	N	N	N	N
Steroids	Y	Y	Y	N	Y	Y	Y	Y

a-CABMR, active-chronic antibody-mediated rejection; cPRA, calculated panel reactive antibody; DSA, donor-specific antibody; ESRD, end-stage renal disease; F/M, female/male; FSGS, focal segmental glomerulosclerosis; HLA, human leukocyte antigen; NA, not available; na-CABMR, nonactive-chronic antibody-mediated rejection; Y/N, yes/no.

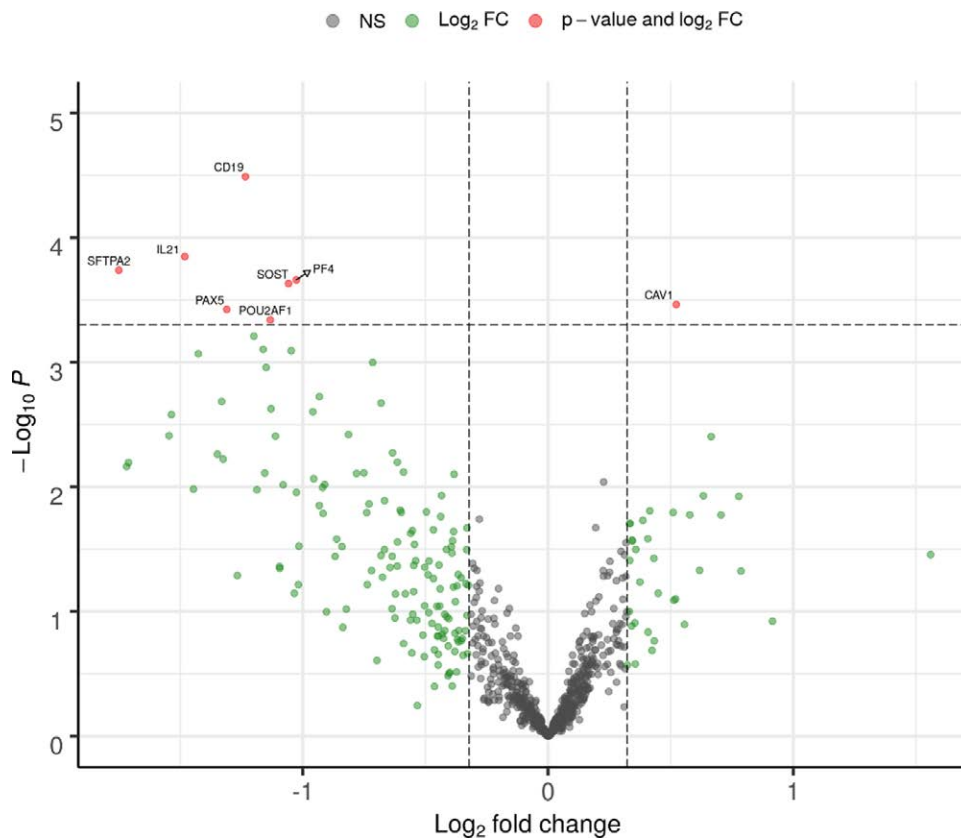


FIGURE 1. Volcano plot showing differential gene expression (P value/foldchange) on kidney transplant biopsies, before and after ECP using the BHOT assessed by the NanoString nCounter platform. The threshold of the y-axis (dotted line) correspond to adjusted $P < 0.05$. The threshold of the x-axis (dotted line) correspond to Fold Change < -1.25 or Fold Change > 1.25 . BHOT, Banff Human Organ Transplant Panel; ECP, extracorporeal photopheresis.

mouse model, injection of exogenous IL-21 increases C4d deposition, glomerulitis, tubulitis, and interstitial inflammation in the graft.²⁴ Lowering IL-21 could therefore be beneficial in cases of allograft rejection. Our results support this hypothesis as other B-cell markers, such as CD19 and PAX5 mRNA expressions were significantly decreased after ECP.

The anti-inflammatory effect of ECP was expected; after reinjection of apoptotic cells following their irradiation, ECP treatment is known to be associated with a switch from T helpers 1 (Th1) to Th2, an increase in Th1 cytokines and interleukin-12, a switch from dendritic cells 1 to 2, and it induces tolerance through induction of regulatory T cells.²⁴ This switch towards type 2 immune response could be a key to the regulation of tissue regeneration.²⁵ This anti-inflammatory effect could also have an impact on preventing the development of fibrotic lesions. Indeed, fibrosis is viewed as a consequence of dysregulated tissue repair response, especially during chronic inflammation disorders²⁶ and an antifibrotic effect of ECP has been reported in patients with chronic graft versus host disease or systemic sclerosis, as well as in a mouse lung transplantation model.^{7,27}

Our study has several limitations. This is a retrospective study with no control group, so it is not possible to attribute with certainty that the transcriptomic changes observed are only due to ECP. With a small number of patients, we may have selected patients with heterogeneous graft rejection

profiles. However, we used Banff classification at time of biopsy to define cABMR in those patients, which is currently the gold standard in graft tissue assessment. Noteworthy, although we only studied 8 potentially heterogeneous patients, all of them display a similar transcript profile. Our follow-up was rather short (mean duration 3.9 mo), which did not allow us to demonstrate a benefit on renal function and DSAs. On the other hand, this short-term follow-up limited the risk of confounding factors (infection, drug toxicity...), which could have influenced kidney biopsy analysis. To increase the sensitivity of the analysis, each patient was used as his own control and ECP was prescribed on top of previous treatment regimen without concomitant new immunosuppressive drugs. Furthermore, other pathways involved in fibrosis were not explored, such as the impact of decorin, which has been previously described in the lung. Of note, decorin is also expressed in the kidney²⁸ and it would be interesting to evaluate the impact of ECP on the expression of decorin in the kidney, in the setting of cABMR.

CONCLUSION

In patients treated with ECP for cABMR after renal transplantation, transcriptomic analysis of repeated biopsies shows a reduction in fibrotic and inflammatory molecular biologicals markers. This study provides further support for investigating the use of ECP as a therapy for cABMR in renal transplantation.

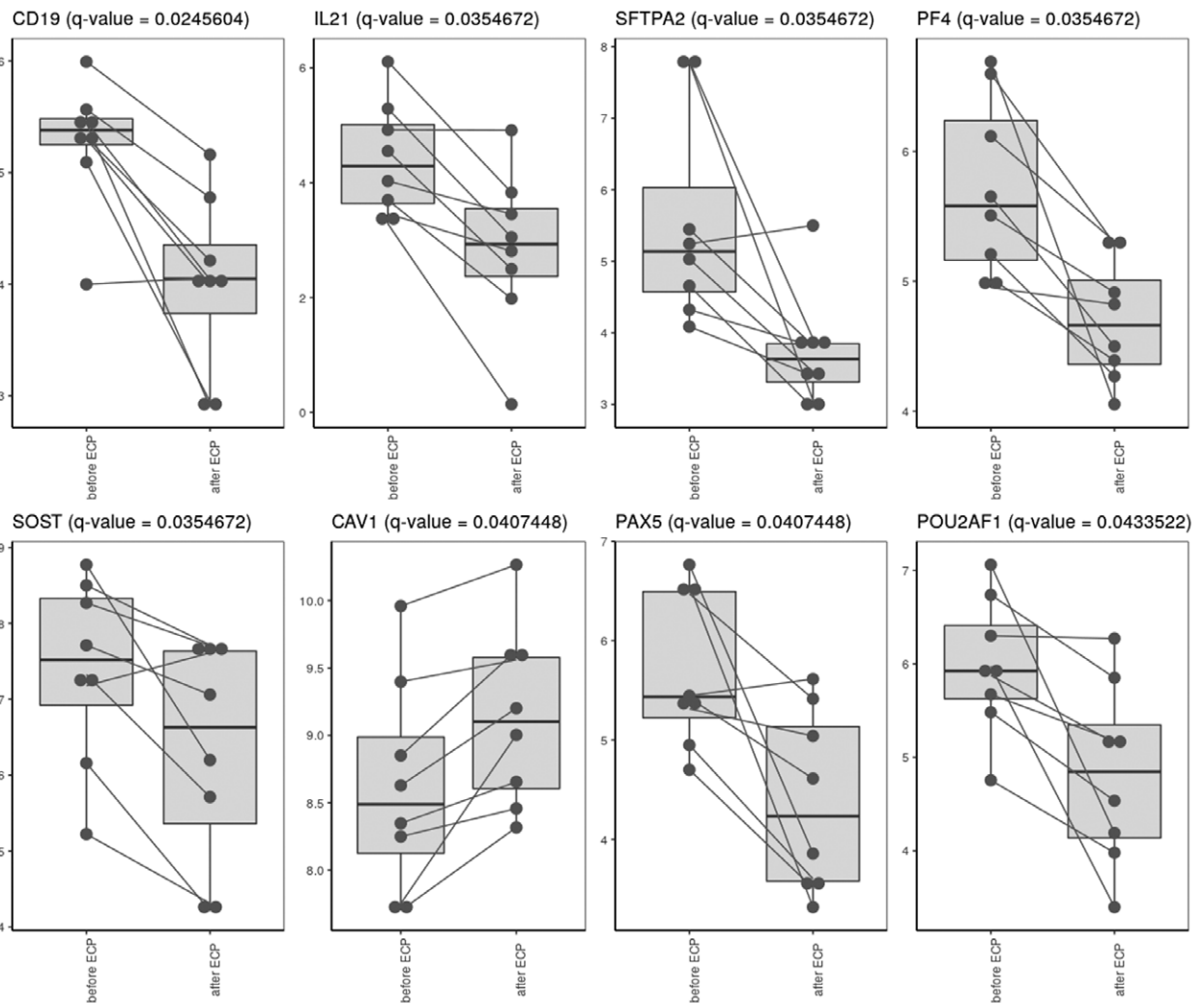


FIGURE 2. Boxplots showing RNA counts (expressed in log₂) per sample with a significant difference (set to adjusted $P < 0.05$), on biopsies performed before and after ECP. Cav1, Caveolin 1; CD19, CD19 molecule; ECP, extracorporeal photopheresis; IL21, interleukin 21; PAX5, Paired Box 5; PF4, platelet factor 4; POU2AF1, POU class 2 Homeobox associating factor 1; SFTPA2, surfactant protein A2; SOST, sclerostin.

REFERENCES

- Coemans M, Süsal C, Döhler B, et al. Analyses of the short- and long-term graft survival after kidney transplantation in Europe between 1986 and 2015. *Kidney Int.* 2018;94:964–973.
- Sellarés J, de Freitas DG, Mengel M, et al. Understanding the causes of kidney transplant failure: the dominant role of antibody-mediated rejection and nonadherence. *Am J Transplant.* 2012;12:388–399.
- Lefaucheur C, Loupy A. Antibody-mediated rejection of solid-organ allografts. *N Engl J Med.* 2018;379:2580–2582.
- Loupy A, Haas M, Roufousse C, et al. The banff 2019 kidney meeting report (I): updates on and clarification of criteria for T cell- and antibody-mediated rejection. *Am J Transplant.* 2020;20:2318–2331.
- Haas M, Sis B, Racusen LC, et al; Banff Meeting Report Writing Committee. Banff 2013 meeting report: inclusion of c4d-negative antibody-mediated rejection and antibody-associated arterial lesions. *Am J Transplant.* 2014;14:272–283.
- Lai X, Zheng X, Mathew JM, et al. Tackling chronic kidney transplant rejection: challenges and promises. *Front Immunol.* 2021;12:661643.
- Del Fante C, Scudeller L, Viarengo G, et al. Response and survival of patients with chronic graft-versus-host disease treated by extracorporeal photochemotherapy: a retrospective study according to classical and national institutes of health classifications: ECP IN cGVHD. *Transfusion.* 2012;52:2007–2015.
- Del Fante C, Seghatchian J, Perotti C. Reflections on the usefulness of extracorporeal photopheresis in renal transplant rejection: a concise review of the involved mechanisms and therapeutic perspectives. *Transfus Apher Sci.* 2018;57:115–117.
- Hutchinson JA, Benazzo A. Extracorporeal photopheresis suppresses transplant fibrosis by inducing decorin expression in alveolar macrophages. *Transplantation.* 2023;107:1010–1012.
- Liu Z, Liao F, Zhu J, et al. Reprogramming alveolar macrophage responses to TGF- β reveals CCR2+ monocyte activity that promotes bronchiolitis obliterans syndrome. *J Clin Invest.* 2022;132:e159229.
- Gregorini M, Del Fante C, Pattonieri EF, et al. Photopheresis abates the Anti-HLA antibody titer and renal failure progression in chronic antibody-mediated rejection. *Biology.* 2021;10:547.
- Tamain M, Sayegh J, Lionet A, et al. Extracorporeal photopheresis for the treatment of graft rejection in 33 adult kidney transplant recipients. *Transfus Apher Sci* 2019;58:515–524.
- Zhang XL, Topley N, Ito T, et al. Interleukin-6 regulation of transforming growth factor (TGF)-beta receptor compartmentalization and turnover enhances TGF-beta1 signaling. *J Biol Chem.* 2005;280:12239–12245.
- Drab M, Verkade P, Elger M, et al. Loss of caveolae, vascular dysfunction, and pulmonary defects in caveolin-1 gene-disrupted mice. *Science.* 2001;293:2449–2452.
- Luo S, Yang M, Zhao H, et al. Caveolin-1 regulates cellular metabolism: a potential therapeutic target in kidney disease. *Front Pharmacol.* 2021;12:768100.
- Razani B, Zhang XL, Bitzer M, et al. Caveolin-1 regulates transforming growth factor (TGF)-beta/SMAD signaling through an interaction with the TGF-beta type I receptor. *J Biol Chem.* 2001;276:6727–6738.

17. Wang XM, Zhang Y, Kim HP, et al. Caveolin-1: a critical regulator of lung fibrosis in idiopathic pulmonary fibrosis. *J Exp Med*. 2006;203:2895–2906.
18. Park HC, Yasuda K, Ratliff B, et al. Postobstructive regeneration of kidney is derailed when surge in renal stem cells during course of unilateral ureteral obstruction is halted. *Am J Physiol Renal Physiol*. 2010;298:F357–F364.
19. Maanaoui M, Lenain R, Hamroun A, et al. Caveolin-1 rs4730751 single-nucleotide polymorphism may not influence kidney transplant allograft survival. *Sci Rep*. 2019;9:15541.
20. Van der Hauwaert C, Savary G, Pinçon C, et al. Donor caveolin 1 (CAV1) genetic polymorphism influences graft function after renal transplantation. *Fibrogenesis Tissue Repair*. 2015;8:8.
21. Moore J, McKnight AJ, Simmonds MJ, et al. Association of caveolin-1 gene polymorphism with kidney transplant fibrosis and allograft failure. *JAMA*. 2010;303:1282–1287.
22. Gambella A, Barreca A, Osella-Abate S, et al. Caveolin-1 in kidney chronic antibody-mediated rejection: an integrated immunohistochemical and transcriptomic analysis based on the Banff Human Organ Transplant (B-HOT) Gene Panel. *Biomedicines*. 2021;9:1318.
23. Hao J, Zhao X, Yu W, et al. Surfactant protein a induces the pathogenesis of renal fibrosis through binding to calreticulin. *Exp Ther Med*. 2019;17:459–464.
24. Guo L, Lv J, Zhang J, et al. Elevated serum IL-21 levels are associated with stable immune status in kidney transplant recipients and a mouse model of kidney transplantation. *Aging (Albany NY)*. 2020;12:18396–18414.
25. Heshmati F. Updating ECP action mechanisms. *Transfus Apher Sci*. 2014;50:330–339.
26. Gieseck RL, Wilson MS, Wynn TA. Type 2 immunity in tissue repair and fibrosis. *Nat Rev Immunol*. 2018;18:62–76.
27. Henderson NC, Rieder F, Wynn TA. Fibrosis: from mechanisms to medicines. *Nature*. 2020;587:555–566.
28. Mogyorosi A, Ziyadeh FN. What is the role of decorin in diabetic kidney disease? *Nephrol Dial Transplant* 1999;14:1078–1081.