



**HAL**  
open science

## **Assessment of diaphragm motion using ultrasonography in a patient with facio-scapulo-humeral dystrophy: A case report**

Abdallah Fayssoil, Tanya Stojkovic, Adam Ognà, Pascal Laforet, Helene Prigent, Frederic Lofaso, David Orlikowski, Guillaume Bassez, Bruno Eymard, Anthony Behin

### **► To cite this version:**

Abdallah Fayssoil, Tanya Stojkovic, Adam Ognà, Pascal Laforet, Helene Prigent, et al.. Assessment of diaphragm motion using ultrasonography in a patient with facio-scapulo-humeral dystrophy: A case report. *Medicine*, 2019, 98 (4), pp.e13887. 10.1097/MD.0000000000013887 . hal-04459938

**HAL Id: hal-04459938**

**<https://hal.science/hal-04459938>**

Submitted on 15 Feb 2024

**HAL** is a multi-disciplinary open access archive for the deposit and dissemination of scientific research documents, whether they are published or not. The documents may come from teaching and research institutions in France or abroad, or from public or private research centers.

L'archive ouverte pluridisciplinaire **HAL**, est destinée au dépôt et à la diffusion de documents scientifiques de niveau recherche, publiés ou non, émanant des établissements d'enseignement et de recherche français ou étrangers, des laboratoires publics ou privés.



Distributed under a Creative Commons Attribution - NonCommercial 4.0 International License

# Assessment of diaphragm motion using ultrasonography in a patient with facio-scapulo-humeral dystrophy

## A case report

Abdallah Fayssol, MD, PhD<sup>a,b,\*</sup>, Tanya Stojkovic, MD<sup>a</sup>, Adam Ojna, MD<sup>c</sup>, Pascal Laforet, MD, PhD<sup>a,b</sup>, Helene Prigent, MD, PhD<sup>b</sup>, Frederic Lofaso, MD, PhD<sup>b</sup>, David Orlikowski, MD, PhD<sup>b</sup>, Guillaume Bassez, MD, PhD<sup>a</sup>, Bruno Eymard, MD, PhD<sup>a</sup>, Anthony Behin, MD<sup>a</sup>

### Abstract

**Rationale:** Diaphragm is the main inspiratory respiratory muscle and little is known about diaphragm ultrasound in facio-scapulo-humeral muscular dystrophy, a neuromuscular disease characterized by an asymmetric skeletal muscle involvement.

**Patient concerns:** Diaphragm function evaluation

**Diagnosis:** Diaphragm muscle weakness attested by the drop of vital capacity (VC) value from sitting position (74%) to supine position (46%).

**Interventions:** A diaphragm ultrasound was performed in supine position, from the anterior subcostal window

**Outcomes:** We found an opposite side to side hemi diaphragm displacement, either during sniff maneuver or during deep inspiration maneuver, showing a cranial abnormal reduced motion of the right hemi diaphragm whereas the left hemi diaphragm moved caudally.

**Lessons:** Diaphragm weakness may be present with an asymmetric pattern and an opposite motion during inspiration or sniff manoeuvre in facio-scapulo-humeral muscular dystrophy. A future study with a systematic evaluation of a greater number of FSHD1 patients will be necessary to characterize this population.

**Abbreviations:** FSHD = facioscapulo-humeral dystrophy; MIP = maximal inspiratory pressure; SNIP = sniff nasal inspiratory pressure; VC = vital capacity.

**Keywords:** diaphragm weakness, FSHD1, ultrasound

## 1. Introduction

Facioscapulo-humeral dystrophy (FSHD) is the third most common genetic muscular dystrophy, with an estimated prevalence of 1/8000.<sup>[1,2]</sup> This disease is characterized by an asymmetric muscular involvement, affecting initially the face and the shoulder girdle, followed by the truncal, humeral and lower extremity muscles. Among FSHD forms, the autosomal dominant FSHD1 is the most prevalent one (95%). This disease results from the loss of a subset of repeated units in the D4Z4

macrosatellite repeat array (chromosome 4q35)<sup>[3,4]</sup> that leads to an aberrant production of DUX4, a double homeobox transcription factor with toxic gain of function. Respiration function may be involved, providing a restrictive pattern<sup>[5-7]</sup> and a smaller D4Z4 size seems to be associated with a more severe form with an earlier onset of disease.<sup>[8]</sup> We report here a side-to-side opposite diaphragm motion using sonography in a patient with FSHD1. Informed consent was obtained from the patient for this case report.

## 2. Case report

A 61 year-old female with facio-scapulo-humeral dystrophy (FSHD1) was referred to our unit for evaluation. His past medical history was pertinent for diabetes mellitus and hypertension. Initial symptoms appeared at the age of 21 years with shoulder girdle weakness followed by difficulty walking. Clinical examination disclosed winged scapulae, weakness affecting the shoulder girdle, the facial, the trunk associated with a steppage gait. Cardiac function was normal with a left ventricular ejection fraction at 75%. Vital capacity (VC) value decreased from sitting position (74%) to supine position (46%), which attests diaphragm muscle impairment. In addition, sniff nasal inspiratory pressure (SNIP) was significantly decreased (17 cmH<sub>2</sub>O) as well as maximal inspiratory pressure (MIP at 12 cmH<sub>2</sub>O), related to a failure of strength's diaphragm muscle. Diaphragm ultrasound (Vivid E9, GE Medical Systems) was performed in

Editor: N/A.

The authors have no funding and no conflicts of interest to disclose.

<sup>a</sup> Myology Institute, Pitié Salpêtrière Hospital, APHP, Paris, <sup>b</sup> Raymond Poincaré Hospital, APHP, Garches, France, <sup>c</sup> Lausanne University Hospital, Lausanne, Switzerland.

\* Correspondence: Abdallah Fayssol, Myology Institute, Pitié Salpêtrière Hospital, Paris, France (e-mail: abdallah.fayssol@aphp.fr).

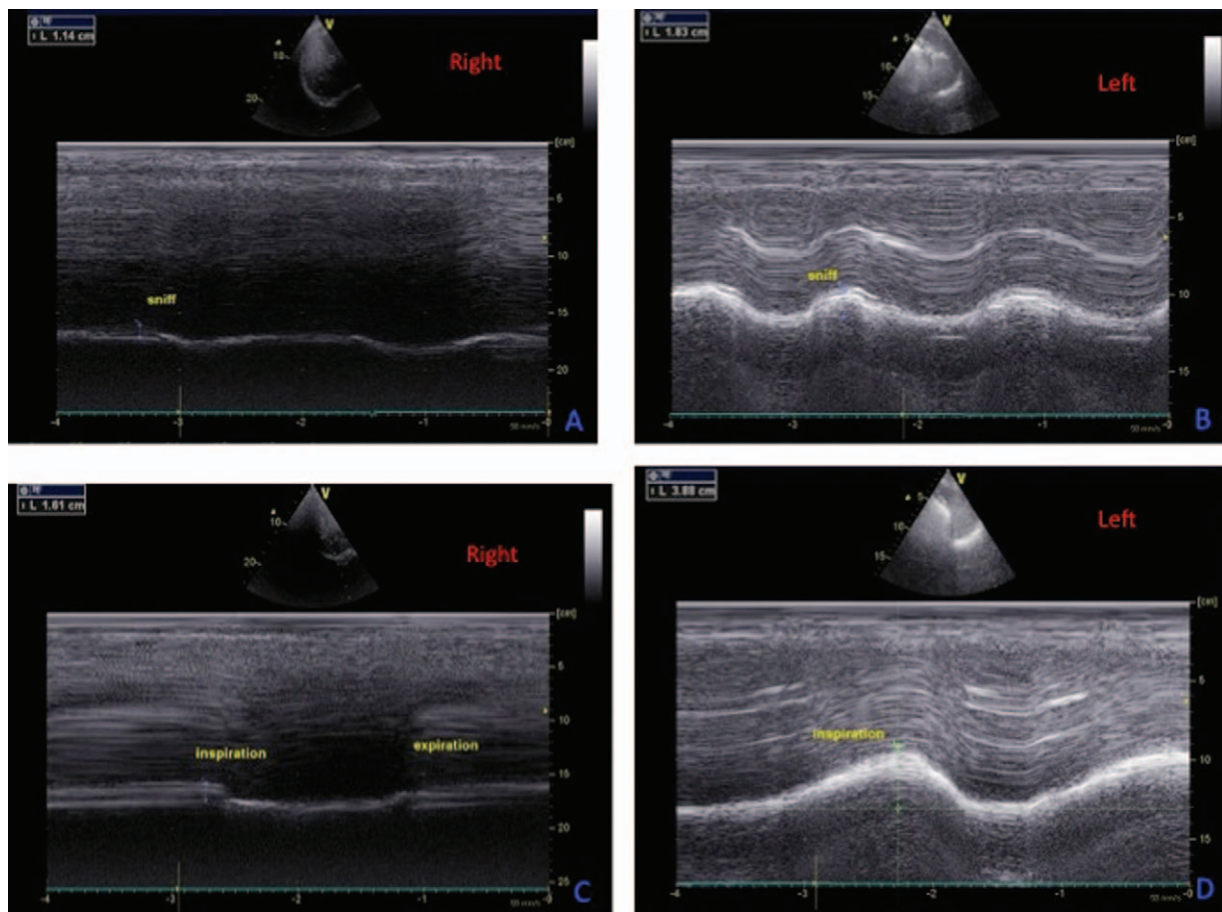
Copyright © 2019 the Author(s). Published by Wolters Kluwer Health, Inc. This is an open access article distributed under the terms of the Creative Commons Attribution-Non Commercial License 4.0 (CCBY-NC), where it is permissible to download, share, remix, transform, and buildup the work provided it is properly cited. The work cannot be used commercially without permission from the journal.

Medicine (2019) 98:4(e13887)

Received: 27 August 2018 / Received in final form: 30 November 2018 /

Accepted: 5 December 2018

<http://dx.doi.org/10.1097/MD.0000000000013887>



**Figure 1.** Diaphragm ultrasound imaging in FSHD1. The right hemi diaphragm moves cranially in an opposite direction during deep inspiration (C) or Sniff maneuver (A) in comparison with the normal caudal movement of the left hemi-diaphragm during deep inspiration (D) or Sniff maneuver (B). FSHD1 = facio-scapulo-humeral dystrophy.

supine position (45°), using a sector probe M5Sc-D (1.5–4.6 MHz), from the anterior subcostal window. The imaging exam disclosed an opposite side to side hemi diaphragm displacement, either during sniff maneuver or deep inspiration maneuver, with a cranial abnormal reduced motion of the right hemi diaphragm whereas the left hemi diaphragm moved caudally during inspiration or sniff maneuver (Fig. 1).

### 3. Discussion

Respiratory insufficiency is a frequent cause of morbidity and mortality in neuromuscular disorders. In FSHD1, the typical clinical pattern includes asymmetric skeletal muscle impairment, with atrophy and muscle fatty replacement of trapezius, teres major and serratus anterior.<sup>[9]</sup> Wheelchair is necessary in 20% of patients often after the 5th decade.<sup>[2]</sup> Respiratory function is not systematically involved, and a restrictive respiratory involvement was found in 9.8% of the largest published cohort with genetic confirmation of FSHD.<sup>[7]</sup> Only 1% of patients needed home mechanical ventilation in the Dutch FSHD population.<sup>[10]</sup> The respiratory insufficiency is particularly frequent in the infantile form and in patients with small D4Z4 repeats sizes.<sup>[11]</sup> Diaphragm is the main inspiratory respiratory muscle and little is known about diaphragm function in this disease. Classical pulmonary function tests assess global respiratory muscles function, and a decline in VC greater than 20% from the sitting to the supine position is

interpreted as an indirect sign of diaphragm weakness.<sup>[12]</sup> One study assessed global respiratory muscles and diaphragm using transdiaphragmatic pressures in FSHD patients<sup>[13]</sup> and reported a weakness affecting the expiratory muscles rather than the inspiratory muscles. Indeed, in FSHD, abdominal muscles—that are the main expiratory muscles—seem to be early affected, in association with protuberant abdomen and lumbar lordosis.<sup>[10,14]</sup> The *Beevor sign* may be present, due to selective weakness of the lower rectus abdominis. Contrarily to the study by Stübgen and Schultz,<sup>[13]</sup> that did not find any alteration of diaphragm function in FSHD using transdiaphragmatic pressures measurement, we found an asymmetric and opposite diaphragm motion in FSHD1 using sonography. This difference can be explained by the fact that transdiaphragmatic pressures may remain in normal range in patients with asymmetric diaphragm failure, since transdiaphragmatic pressures measure the global diaphragmatic function as the pressure difference between the pleural pressure (oesophageal) and the gastric pressure. On the contrary, the use of ultrasound allows detecting asymmetric diaphragm weakness.<sup>[15,16]</sup> For the diagnosis of diaphragm paralysis, chest X ray may have a significant sensibility but a lower specificity. Fluoroscopy was traditionally used for the diagnosis of diaphragm paralysis, showing a paradoxical motion during Sniff manoeuvre but this technique is currently outdated. Diaphragmatic muscle strength may be explored by the measurement of maximal static inspiratory pressure and sniff nasal inspiratory pressure.<sup>[17]</sup> These noninvasive

methods showed an excellent correlation ( $0.99 + -0.01, p < 0.001$ ) with sniff oesophageal pressure.<sup>[17]</sup> Ultrasound imaging is a noninvasive approach for diaphragm analysis and can be coupled with sniff manoeuvre. In our case, the weakness of diaphragm was confirmed by sniff, MIP, delta VC (decrease of VC from sitting to supine position) measurements and ultrasound imaging. Our results support the fact that diaphragm muscle may be impaired in FSHD1 with an asymmetrical distribution, and the disease seems thus to not affect only the expiratory respiratory muscles, as previously described. The diaphragm involvement was asymmetric in our case, likewise the asymmetric skeletal muscle involvement, a hallmark of FSHD1. This was not yet reported in the literature, except for one study that reported a bilateral diaphragm paralysis in a patient with FSHD.<sup>[18]</sup> Diaphragmatic ultrasound could be a sensitive monitoring tool in addition to functional respiratory tests. Our study should be considered as exploratory, since it disclosed some limitations that need to be addressed: we report the result of only one patient and we do not perform oesophageal pressure measurement.

### Author contributions

**Conceptualization:** Abdallah Fayssoil, Tanya Stojkovic, Adam Ogna.

**Formal analysis:** Pascal Laforet, Anthony Behin.

**Investigation:** Abdallah Fayssoil, Helene Prigent, Frederic Lofaso, David Orlikowski, Guillaume Bassez, Bruno Eymard, Anthony Behin.

**Methodology:** Abdallah Fayssoil.

**Validation:** Abdallah Fayssoil.

**Visualization:** Helene Prigent, Frederic Lofaso, David Orlikowski, Guillaume Bassez, Bruno Eymard.

**Writing – original draft:** Abdallah Fayssoil.

**Writing – review & editing:** Abdallah Fayssoil, Tanya Stojkovic, Adam Ogna, Pascal Laforet, Anthony Behin.

### References

- [1] Deenen JC, Arnts H, van der Maarel SM, et al. Population-based incidence and prevalence of facioscapulohumeral dystrophy. *Neurology* 2014;83:1056–9.

- [2] Tawil R, Van Der Maarel SM. Facioscapulohumeral muscular dystrophy. *Muscle Nerve* 2006;34:1–5.
- [3] Tawil R, van der Maarel SM, Tapscott SJ. Facioscapulohumeral dystrophy: the path to consensus on pathophysiology. *Skelet Muscle* 2014;4:12.
- [4] Upadhyaya M, Lunt PW, Sarfarazi M, et al. DNA marker applicable to presymptomatic and prenatal diagnosis of facioscapulohumeral disease. *Lancet* 1990;336:1320–1.
- [5] Santos DB, Boussaid G, Stojkovic T, et al. Respiratory muscle dysfunction in facioscapulohumeral muscular dystrophy. *Neuromuscul Dis* 2015;25:632–9.
- [6] Moreira S, Wood L, Smith D, et al. Respiratory involvement in ambulant and non-ambulant patients with facioscapulohumeral muscular dystrophy. *J Neurol* 2017;264:1271–80.
- [7] Scully MA, Eichinger KJ, Donlin-Smith CM, et al. Restrictive lung involvement in facioscapulohumeral muscular dystrophy. *Muscle Nerve* 2014;50:739–43.
- [8] Lemmers RJ, Goeman JJ, van der Vliet PJ, et al. Inter-individual differences in CpG methylation at D4Z4 correlate with clinical variability in FSHD1 and FSHD2. *Human Mol Genet* 2015;24:659–69.
- [9] Gerevini S, Scarlato M, Maggi L, et al. Muscle MRI findings in facioscapulohumeral muscular dystrophy. *Eur Radiol* 2016;26:693–705.
- [10] Wohlgemuth M, van der Kooi EL, van Kesteren RG, et al. Ventilatory support in facioscapulohumeral muscular dystrophy. *Neurology* 2004;63:176–8.
- [11] Nakagawa M, Matsuzaki T, Higuchi I, et al. Facioscapulohumeral muscular dystrophy: clinical diversity and genetic abnormalities in Japanese patients. *Intern Med* 1997;36:333–9.
- [12] Perrin C, Unterborn JN, Ambrosio CD, et al. Pulmonary complications of chronic neuromuscular diseases and their management. *Muscle Nerve* 2004;29:5–27.
- [13] Stübgen JP, Schultz C. Lung and respiratory muscle function in facioscapulohumeral muscular dystrophy. *Muscle Nerve* 2009;39:729–34.
- [14] Shahrazaila N, Wills AJ. Significance of Beevor's sign in facioscapulohumeral dystrophy and other neuromuscular diseases. *J Neurol Neurosurg Psychiatry* 2005;76:869–70.
- [15] Sarwal A, Walker FO, Cartwright MS. Neuromuscular ultrasound for evaluation of the diaphragm. *Muscle Nerve* 2013;47:319–29.
- [16] Lloyd T, Tang YM, Benson MD, et al. Diaphragmatic paralysis: the use of M mode ultrasound for diagnosis in adults. *Spinal Cord* 2006;44:505–8.
- [17] Héritier F, Rahm F, Pasche P, et al. Sniff nasal inspiratory pressure. A noninvasive assessment of inspiratory muscle strength. *Am J Respir Crit Care Med* 1994;150:1678–83.
- [18] Hazenberg A, van Alfen N, Voet NB, et al. Facioscapulohumeral muscular dystrophy and respiratory failure; what about the diaphragm? *Respir Med Case Rep* 2014;14:37–9.