



**HAL**  
open science

## Virtual preoperative planning of acetabular fractures using patient-specific biomechanical simulation: A case-control study

Mehdi Boudissa, Gaëtan Bahl, Hadrien Oliveri, Matthieu Chabanas, Jérôme Tonetti

### ► To cite this version:

Mehdi Boudissa, Gaëtan Bahl, Hadrien Oliveri, Matthieu Chabanas, Jérôme Tonetti. Virtual preoperative planning of acetabular fractures using patient-specific biomechanical simulation: A case-control study. *Orthopaedics & Traumatology: Surgery & Research*, 2021, 107 (6), pp.103004. 10.1016/j.otsr.2021.103004 . hal-04459884

**HAL Id: hal-04459884**

**<https://hal.science/hal-04459884>**

Submitted on 22 Jul 2024

**HAL** is a multi-disciplinary open access archive for the deposit and dissemination of scientific research documents, whether they are published or not. The documents may come from teaching and research institutions in France or abroad, or from public or private research centers.

L'archive ouverte pluridisciplinaire **HAL**, est destinée au dépôt et à la diffusion de documents scientifiques de niveau recherche, publiés ou non, émanant des établissements d'enseignement et de recherche français ou étrangers, des laboratoires publics ou privés.



Distributed under a Creative Commons Attribution - NonCommercial 4.0 International License

Original Article

## **Virtual preoperative planning of acetabular fractures using patient-specific biomechanical simulation: a case-control study.**

Mehdi **Boudissa**<sup>a,b,\*</sup>, Gaëtan **Bahl**<sup>b</sup>, Hadrien **Oliveri**<sup>b</sup>, Matthieu **Chabanas**<sup>b</sup>, Jérôme **Tonetti**<sup>a,b</sup>

a. Department of Orthopaedic and Trauma Surgery, Grenoble University Hospital, Univ. Grenoble Alpes, La Tronche, 38700, France

b. TIMC-IMAG lab, University Grenoble-Alpes, CNRS UMR 5525, La Tronche, 38700, France

\* **Corresponding author:** Mehdi Boudissa, Orthopaedic and Traumatological Surgery Service, University Hospital of Grenoble, North Hospital, Boulevard de la Chantourne, 38700 La Tronche, University Grenoble-Alpes, Grenoble, France.

Phone: +33601046824

E-mail: mboudissa@chu-grenoble.fr

### **Abstract**

#### *Introduction*

The first patient-specific biomechanical model for planning the surgical reduction of acetabular fractures was developed in our institution and validated retrospectively. There are no prior studies showing its effectiveness in terms of reduction quality, operative duration and intraoperative bleeding. Therefore, we performed a case control study aiming to: 1) evaluate the effect of preoperative simulation by patient-specific biomechanical simulator on the operating time and intraoperative bleeding, 2) evaluate the effect of preoperative simulation by patient-specific biomechanical simulator on the quality of reduction.

#### *Method*

All patients operated on between January 2019 and June 2019 after planning by biomechanical simulation were included in this case-control study. Each patient included was matched to 2 controls from our database (2015-2018) according to age and fracture-type. DICOM data were extracted from the preoperative high-resolution scanners to build a three-dimensional model of the fracture by semi-automatic segmentation. A biomechanical model was built to virtually simulate the different stages of surgical reduction. Surgery was then performed according to simulation data. Surgical duration, blood loss, radiological findings and intraoperative complications were recorded, analysed and compared.

### *Results*

Thirty patients were included, 10 in the simulation group and 20 in the control group. The two groups were comparable in terms of age, time from accident to surgery, fracture-type and surgical approach. The mean operative time was significantly reduced in the simulation group: 113 min  $\pm$  33 (60-180) versus 196 min  $\pm$  32 (60-260) ( $p=0.01$ ). Mean blood loss was significantly reduced in the simulation group: 505 mL  $\pm$  189 (100-750) versus 745 mL  $\pm$  130 (200-850) ( $p<0.01$ ). However, no significant difference was found in the radiological results according to Matta's criteria, although an anatomical reduction was obtained for 9 patients in the simulation group (90%) versus 12 patients in the control group (60%) ( $p=0.26$ ). A postoperative neurological complication was recorded in the control group (sensory deficit of the lateral cutaneous nerve of thigh).

### *Conclusion*

This study confirms the promising results of preoperative planning in acetabular trauma surgery based on patient-specific biomechanical simulation as well as its feasibility in routine clinical practice. By providing a better understanding of the fracture and its behavior, a reduction in intraoperative bleeding and in operative duration is achieved.

**Level of evidence:** III; Case-control study

**Key-words:** Acetabular fracture; Biomechanical model; Virtual planning; Computer-assisted surgery; Segmentation

## **1. Introduction**

Surgery of acetabular fractures represents a true challenge. From the understanding of the type of fracture using Letournel classification, through to the choice of approach (anterior and/or posterior) and finally, the surgical reduction which aims to achieve anatomical reduction for optimal clinical outcomes [1-5]. A lack of understanding of the fracture and a poor surgical strategy can lead to a poor reduction with sub-optimal clinical outcomes [1,5]. Several preoperative planning tools have been developed to facilitate the different steps in the management of these complex fractures [6-11]. Related studies appear to show an improvement in operative duration and a decrease in intraoperative bleeding as well as better surgical reductions, although a comparison with a control group is difficult given the rarity of these fractures, the variable experience of surgeons and the variety of techniques employed for the same fracture-type [6].

We developed a patient-specific biomechanical model for planning the surgical reduction of acetabular fractures, with promising results [12]. A retrospective validation of this simulator demonstrated its reliability in reproducing surgical reduction based on the different reduction manoeuvres applied [12]. There are no prior studies showing its effectiveness in terms of reduction quality, operative duration and intraoperative bleeding. To our knowledge, this is the first patient-specific biomechanical model that can be used in routine planning of surgery for acetabular fractures [6].

Therefore, we performed a case control study aiming to: 1) evaluate the effect of preoperative simulation by patient-specific biomechanical simulator on the operating time and intraoperative bleeding, 2) evaluate the effect of preoperative simulation by patient-specific biomechanical simulator on the quality of reduction.

## **2. Materials and Methods**

### **2.1 Patients**

The patients included in this study were all operated on by the first author after surgical planning by biomechanical simulation, between January 2019 and June 2019. Each patient included was matched to 2 control patients based on age (plus or minus 2 years) and fracture-type. Controls were taken from our database of more than 200 patients operated on between January 2015 and December 2018. Only patients operated on by a senior surgeon were retained in the control group. Despite the high number of patients in the database, no more than 2 controls per patient could be matched for age and for fracture-type. All patients gave their consent for the use of their data in biomedical research.

### **2.2 Description of the simulation**

A three-dimensional model of bone fragments was constructed by semi-automatic segmentation using the ITK-Snap software (ITK-Snap, Philadelphia, PA). After importing the DICOM data from the high-resolution preoperative scanner, the region to be segmented was selected by a grey-level thresholding method based on bone density in order to segment only bone structures. The software generated a semi-automatic segmentation based on a regional growth algorithm. A manual finish was required to separate the different fragments of the comminuted fractures [13]. Soft tissues were not included in the segmentation.

A patient-specific biomechanical model was constructed in the ArtiSynth simulation environment (ArtiSynth, Vancouver, Canada) [14]. Each bone fragment was considered as an

independent rigid body. The coxal bone attached to the sacroiliac joint is considered non-mobile (in the absence of sacroiliac disruption), while other bone fragments are mobile and moveable. The simulation takes into account collisions to avoid interpenetration phenomena between fragments that can distort the final reduction. The action of the various surgical instruments (clamps, Schanz screws, traction, etc.) is simulated by vectors and forces in translation and rotation. To make the simulation realistic, the curarized muscles and their effects on the bone fragments are simulated in correspondence with a global viscosity field. This simple but effective “trick” avoids non-anatomic displacements and digital instabilities related to the forces applied to the fragments. The soft tissues involved in the reduction and balance of the system (joint capsule, sacrospinous and sacrotuberous ligaments, inguinal ligament and pubic symphysis) were modelled and set in the model by the surgeon according to the types of fracture [12]. Thus, each patient-specific model is built by the surgeon and adapted to the fracture-type (Figure 1).

### **2.3 Description of the method**

The surgical strategy, including the approach and the implants used, was defined from discussions with trauma staff, in accordance with the recommendations of 3 surgeons specialized in acetabular traumatology. Anterior approaches (Stoppa-Cole, para-rectal or ilio-inguinal) and posterior (Kocher-Langenbeck) were used [3,4,15,16]. A biomechanical simulation was performed preoperatively according to the surgical strategy adopted for all patients included between January 2019 and June 2019. The ideal reduction sequence, that is to say, the reduction that uses the fewest manoeuvres necessary to achieve an optimal reduction had its sequence recorded and then reproduced during the surgical procedure. For all patients, the surgical duration, blood loss and intraoperative complications were evaluated. The quality of the reduction was analysed by an independent observer from the

postoperative scanners using Matta's criteria (anatomical reduction for 0-1 mm displacement, imperfect for 2-3 mm displacement and poor for more than 3 mm displacement) [3]. A residual inter-fragmentary gap or persistent step was sought and measured on the scanographic images in accordance with the method described by Borelli et al. [1,17]. The largest displacement was used to assess the quality of the final reduction. These data were compared with data collected retrospectively and recorded in our database between January 2015 and December 2018.

## **2.4 Statistics**

Statistical analyses were performed using StatView 5.5 software (SAS Institute, Cary, NC, USA). Qualitative variables were compared by a Chi-squared test and quantitative variables were compared by a Student's t-test. For non-parametric data (subgroup analysis) a Fisher's exact test for qualitative variables was used. A p-value less than 0.05 was considered statistically significant.

## **3. Results**

Ten simulations and 10 surgeries were performed in the simulation group versus 20 patients operated on without preoperative simulation in the control group. The demographic data and fracture-type of the cohort are summarized in Table 1. The two groups were comparable in terms of age, time from accident to surgery, fracture-type and surgical approach (Table 1). The simulated reduction sequences were replicated during the surgery and the resulting surgical reduction was compared to the simulated reduction. Biomechanical simulation accurately predicted the intraoperative behaviour of bone fragments and the final outcome in terms of the reduction (Table 2). The mean segmentation time was 82 min  $\pm$  18 (60-120). The mean simulation time was 22 min  $\pm$  4 (18-31). Figures 2 to 5 illustrate examples of

preoperative simulations and their final surgical outcome. Results of the comparison between the two groups are summarized in Table 3. The mean operating time was significantly reduced in the simulation group: 113 min  $\pm$  33 (60-180) versus 196 min  $\pm$  32 (60-260) ( $p=0.01$ ). Mean blood loss was significantly reduced in the simulation group: 505 mL  $\pm$  189 (100-750) versus 745 mL  $\pm$  130 (200-850) ( $p<0.01$ ). However, no significant differences were found in radiological results according to Matta's criteria, although anatomical reduction was achieved for 9 patients in the simulation group (90%) versus 12 patients in the standard group (60%) ( $p=0.26$ ). One postoperative neurological complication was recorded in the control group (sensory deficit of the lateral cutaneous nerve of thigh).

#### **4. Discussion**

The paradigm according to which the simulation was developed is based on the actual procedure rather than the desired result [12]. In the literature, all planning tools rely on geometric models to freely mobilize bone fragments in three dimensions and assemble them like a three-dimensional puzzle [6-10]. In a previous study, we reported the limitations of these planning methods that do not correspond to the surgical reality since bone fragments are linked to soft tissues such as the joint capsule or the sacrotuberous or sacrospinous ligaments [12]. Therefore, we developed this patient-specific biomechanical simulator. A previous retrospective study showed that this model faithfully reproduced the behaviour of bone fragments observed during surgery in accordance with the reduction manoeuvres performed. The present prospective clinical study confirms these results and the feasibility of this biomechanical simulation in regular clinical practice.

Regarding the quality of the final reduction, according to Matta's criteria, an anatomical reduction was achieved in 9 of the 10 patients in the simulation group (90%) versus 12



patients in the control group (60%) without the difference being statistically significant. This result is pertinent because the fractures were matched. The reproducibility of the simulation during the surgical procedure was 100% (Table 2) confirming the results of the previous simulator validation study [12]. In the simulation group the only imperfect reduction was achieved in 1 patient according to the results of the preoperative simulation (Figure 4). Indeed, the surgical strategy to treat this fracture of the anterior column associated with a posterior hemi-transverse one was to perform a modified Stoppa approach (anteromedial, intra-pelvic) to obtain the best reduction possible and later, a total hip replacement, given the age of the patient (55 years) and the presence of poor prognostic factors (cartilage roof impaction, femoral head protrusion and low scanographic “roof arc angle”) (Figures 4 and 5) [15]. The simulation showed that anatomical reduction could not be achieved by the modified Stoppa anterior approach alone as the posterior column would not be reduced regardless of anterior reduction manoeuvres employed. However, the interfragmentary gap was acceptable and at 1-year follow-up, the patient walked normally without pain and without technical aids.

One of the strengths of this study is the comparison of mean operating times and mean blood loss to a control group without simulation. This methodology, which is difficult given the many fracture-types and the scarcity of these lesions, has shown its efficacy in a recent study published by Sebaaly et al. [18]. This study has some limitations. The inter-observer reproducibility of the simulation could not be assessed because all simulations and surgeries in the simulation group were performed by the same operator. In contrast, patients in the control group were operated on by different senior surgeons (3 surgeons). This may represent a performance bias related to a difference in surgical experience. Indeed, the comparability of the results between the two groups assumes an identical distribution of

the surgeons' experience given the large learning curve of the surgical treatment of these fractures. The simulation could be improved by adding neurovascular structures, that represent intraoperative risks, such as blood vessels or sciatic, femoral and obturator nerves. However, the absence of intraoperative neurovascular complications in both groups demonstrates that, for a trained operator, the addition of neurovascular structures is not necessary.

Many other tools for planning and assisting acetabular fracture surgery have been developed and are complementary to our biomechanical simulation [6]. Some authors use custom-made plates produced from preoperative planning to guide reduction, others use 3D printing with promising results [19-22]. A combination of the different planning tools seems to be an interesting way to offer patients the best treatment available. Our planning tool can also be used as a surgical teaching and training tool. It would provide a better understanding of acetabular fractures and their treatment, which could be especially interesting for surgeons in training.

## **5. Conclusion**

This study confirms the promising results of preoperative planning in acetabular trauma surgery based on patient-specific biomechanical simulation, as well as its feasibility in routine clinical practice. By providing a better understanding of the fracture and its behaviour, a reduction in intraoperative bleeding and in operative duration is achieved. To our knowledge, this is the first patient-specific biomechanical simulator for reducing acetabular fractures.

**Conflict of Interest:** The authors declare that they have no conflict of interest in relation to this work. J. Tonetti is Associate Editor at Orthopaedics & Traumatology: Surgery & Research.

**Sources of funding:** This study received financial support from ANR France and the Foundation for l'Avenir (labex CAMI), reference ANR-11-LABX-0004.

**Contribution of the authors:** Mehdi Boudissa and Jérôme Tonetti: conception and writing; Gaetan Bahl and Hadrien Oliveri: conception and analysis; Matthieu Chabanas: writing.

## References:

- [1] Tonetti J, Jouffroy P, Dujardin F. Reconstruction of pelvic ring and acetabular fractures: What lies ahead? *Orthop Traumatol Surg Res* 2019;105:799-800.
- [2] Boudissa M, Orfeuvre B, Chabanas M, J Tonetti. Does semi-automatic bone-fragment segmentation improve the reproducibility of the Letournel acetabular fracture classification? *Orthop Traumatol Surg Res* 2017;103::633-638.
- [3] Matta JM, Merritt PO. Displaced acetabular fractures. *Clin Orthop Relat Res* 1988;230:83-97.
- [4] Letournel E. Acetabulum fractures: classification and management. *Clin Orthop Relat Res* 1980;151:81-106.
- [5] Merrill RK, Turvey BR, Landfair GL, Illical EM. Annual case volume is a risk factor for 30-day unplanned readmission after open reduction and internal fixation of acetabular fractures. *Orthop Traumatol Surg Res* 2020;106:103-108
- [6] Boudissa M, Courvoisier A, Chabanas M, Tonetti J. Computer assisted surgery in preoperative planning of acetabular fracture surgery: state of the art. *Expert Rev Med Devices* 2018;15:81-89.
- [7] Sebaaly A, Riouallon G, Zaraa M, Jouffroy P. The added value of intraoperative CT scanner and screw navigation in displaced posterior wall acetabular fracture with articular impaction. *Orthop Traumatol Surg Res* 2016;102:947-50.
- [8] Cimerman M, Kristan A. Preoperative planning in pelvic and acetabular surgery: The value of advanced computerised planning modules. *Injury* 2007;38:442-49.
- [9] Hu Y, Li H, Qiao G, Liu H, Ji A, Ye F. Computer-assisted virtual surgical procedure for acetabular fractures based on real CT data. *Injury* 2011;42:1121-24.

- [10] Fornaro J, Keel M, Harders M, Marincek B, Székely G, Frauenfelder T. An interactive surgical planning tool for acetabular fractures: initial results. *J Orthop Surg Res* 2010;4:5-50.
- [11] Upex P, Jouffroy P, Riouallon G. Application of 3D printing for treating fractures of both columns of the acetabulum: Benefit of precontouring plates on the mirrored healthy pelvis. *Orthop Traumatol Surg Res* 2017;103:331-34.
- [12] Boudissa M, Oliveri H, Chabanas M, Tonetti J. Computer-assisted surgery in acetabular fractures: Virtual reduction of acetabular fracture using the first patient-specific biomechanical model simulator. *Orthop Traumatol Surg Res* 2018;104:359-362.
- [13] Yushkevich PA, Piven J, Hazlett HC, Smith RG, Ho S, Gee JC et al. User-guided 3D active contour segmentation of anatomical structures: Significantly improved efficiency and reliability. *Neuroimage* 2006;31:1116-28.
- [14] Loyd J, Stavness I, Fels S. Springer, editor. *ArtiSynth: A fast interactive biomechanical modeling toolkit combining multibody and finite element simulation. Soft Tissue Biomechanical Modeling for Computer Assisted Surgery*; 2012, p. 355-394.
- [15] Sagi HC, Afsari A, Dziadosz D. The anterior intra-pelvic (modified rives-stoppa) approach for fixation of acetabular fractures. *J Orthop Trauma* 2010;24:263-70.
- [16] Elmadag M, Güzel Y, Acar MA, Uzer G, Arazi M. The Stoppa approach versus ilioinguinal approach for anterior acetabular fractures: a case control study assessing blood loss complications and function outcomes. *Orthop Traumatol Surg Res* 2014;100:675-80.
- [17] Borrelli J Jr, Ricci WM, Steger-May K, Totty WG, Goldfarb C. Postoperative radiographic assessment of acetabular fractures: a comparison of plain radiographs and CT scans. *J Orthop Trauma* 2005;19:299-304.

- [18] Sebaaly A, Jouffroy P, Emmanuel Moreau P, Rodaix C, Riouallon G. Intraoperative Cone Beam Tomography and Navigation for Displaced Acetabular Fractures: A Comparative Study. *J Orthop Trauma* 2018;32:612-616.
- [19] Wang H, Wang F, Newman S, Lin Y, Chen X, Xu L, Wang Q. Application of an innovative computerized virtual planning system in acetabular fracture surgery: A feasibility study, *Injury* 2016;47:1698-701.
- [20] Xu M, Zhang LH, Zhang YZ, Zhang LC, He CQ, Wang Y, Tang PF. Custom-made locked plating for acetabular fracture: a pilot study in 24 consecutive cases. *Orthopedics* 2014;7:660-67.
- [21] Chen K, Yang F, Yao S, Xiong Z, Sun T, Zhu F, Telemacque D, Drepaul D, Ren Z, Guo X. Application of computer-assisted virtual surgical procedures and three-dimensional printing of patient-specific pre-contoured plates in bicolumnar acetabular fracture fixation. *Orthop Traumatol Surg Res* 2019;105:877-884
- [22] Weidert S, Andress S, Suero E, Becker C, Hartel M, Behle M, Willy C. 3D printing in orthopedic and trauma surgery education and training : Possibilities and fields of application. *Unfallchirurg* 2019;122:444-451

**Legends:**

**Figure 1:** Biomechanical model of case n°6 with soft tissue modelling: joint capsule (pink), sacrospinous and sacrotuberous ligaments (pink), inguinal ligament (yellow), pubic symphysis (red) with anteroposterior (A), endopelvic (B) and exopelvic (C) views.

**Figure 2:** Endopelvic view (A), exopelvic view without extraction of the femoral head (B), exopelvic view with extraction of the femoral head (C) of the patient-specific biomechanical model of case n°6 after simulation of the reduction.

**Figure 3:** Case n°6: Preoperative axial CT scan view before (A) and after (B) the surgical reduction, showing the anatomical reduction. Postoperative radiograph of the pelvis in front of the last reduction (C).

**Figure 4:** Endopelvic (A) and exopelvic (B) views of the patient-specific biomechanical model of case n°2 before simulation of the reduction. Endopelvic (C) and exopelvic (D) views after simulation of the reduction, showing the imperfect reduction.

**Figure 5:** Case n°2: Preoperative axial CT scan view before (A) and after (B) the surgical reduction, showing the imperfect reduction. Postoperative radiograph of the pelvis in front of the last recoil (C).

**Table 1:** Characteristics of the series (click2 times: table excel)

Characteristics of the series	Simulation group (n = 10)	Control group (n = 20)	p value
Age (years)	55.3 ± 20.5	52.7 ± 15.9	0.8
<b>Sex</b>			
Male	10 (100%)	17 (85%)	0.53*
Female	0 (0%)	3 (15%)	0.53*
<b>Injury mechanism</b>			
Road traffic accident	3 (30%)	7 (35%)	0.87*
Sport-related accident	4 (40%)	9 (45%)	0.87*
Accident at work	1 (10%)	2 (10%)	0.87*
Low impact accident	2 (20%)	2 (10%)	0.87*
Time from accident to surgery (days)	5.9 ± 1.8	6.2 ± 2.3	0.33
<b>Fracture-type according to Letournel classification</b>			
<i>Simple fractures</i>			
Anterior column	2 (20%)	4 (20%)	1*
<i>Complex fractures</i>			
T	1 (10%)	2 (10%)	1*
Transverse + posterior wall	1 (10%)	2 (10%)	1*
Anterior column + posterior hemitransverse	4 (40%)	8 (40%)	1*
Double column	2 (20%)	4 (20%)	1*
<b>Approach</b>			
Anterior	9 (90%)	18 (90%)	1*
Posterior	1 (10%)	2 (10%)	1*
Double	0 (0%)	0 (0%)	1*
*Fisher's Exact Test			



**Table 2:** Case-by-case description of results in the simulation group (click 2 time: table excel)

Case	Age (years) / Gender	Fracture-type (Letournel classification[4])	Duration of simulation (without segmentation)(min)	Approach	Quality of the reduction (Matta's criteria[12])	Correlation between simulation and surgery
1	27 / Male	Transverse + posterior wall	20	Kocher-Langenbeck	Anatomical	Identical
2	55 / Male	Anterior column + posterior hemi-transverse	18	Stoppa	Imperfect	Identical
3	61 / Male	"T Shape"	25	Stoppa	Anatomical	Identical
4	29 / Male	Double column	18	Ilio-inguinal	Anatomical	Identical
5	86 / Male	Anterior column	19	Para-rectal	Anatomical	Identical
6	50 / Male	Anterior column + posterior hemi-transverse	25	Stoppa	Anatomical	Identical
7	51 / Male	Anterior column + posterior hemi-transverse	31	Stoppa	Anatomical	Identical
8	86 / Male	Anterior column + posterior hemi-transverse	19	Stoppa	Anatomical	Identical
9	67 / Male	Anterior column	20	Ilio-inguinal	Anatomical	Identical
10	41 / Male	Double column	24	Stoppa + external window of the ilio-inguinal approach	Anatomical	Identical

**Table 3:** Comparison of Series Results (click 2 times: table excel)

Characteristics of the series	Simulation group (n = 10) (%)	Control group (n = 20) (%)	p value
<b>Quality of the reduction (Matta's criteria[12])</b>			
Anatomical	9 (90%)	12 (60%)	0.26*
Imperfect	1 (10%)	5 (25%)	0.26*
Poor	0 (0%)	3 (15%)	0.26*
<b>Operative duration (min)</b>	113 ± 33	196 ± 32	<b>0.01</b>
<b>Blood loss (ml)</b>	505 ± 189	745 ± 130	<b>&lt; 0.01</b>
*Fisher's exact test			

Figure 1:

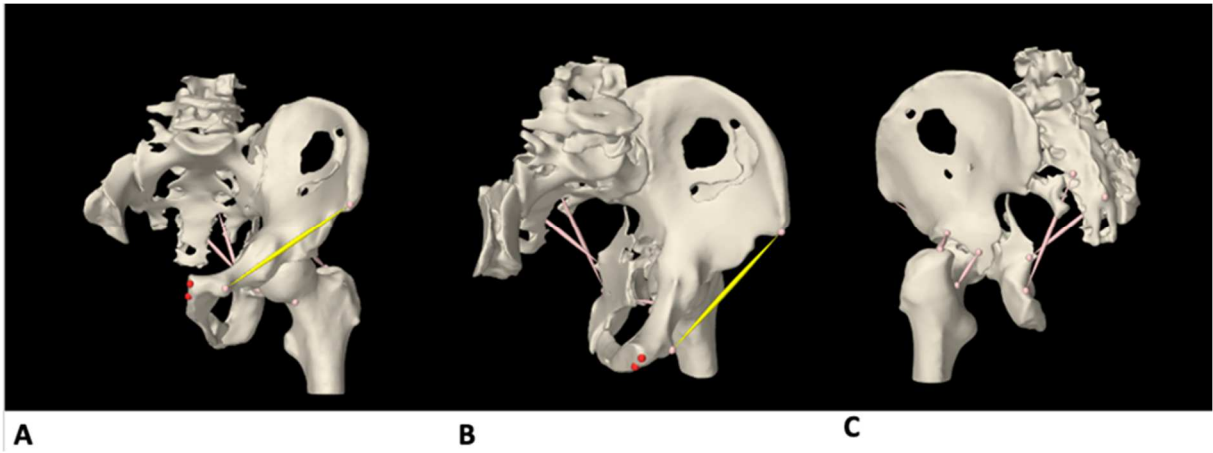


Figure 2:

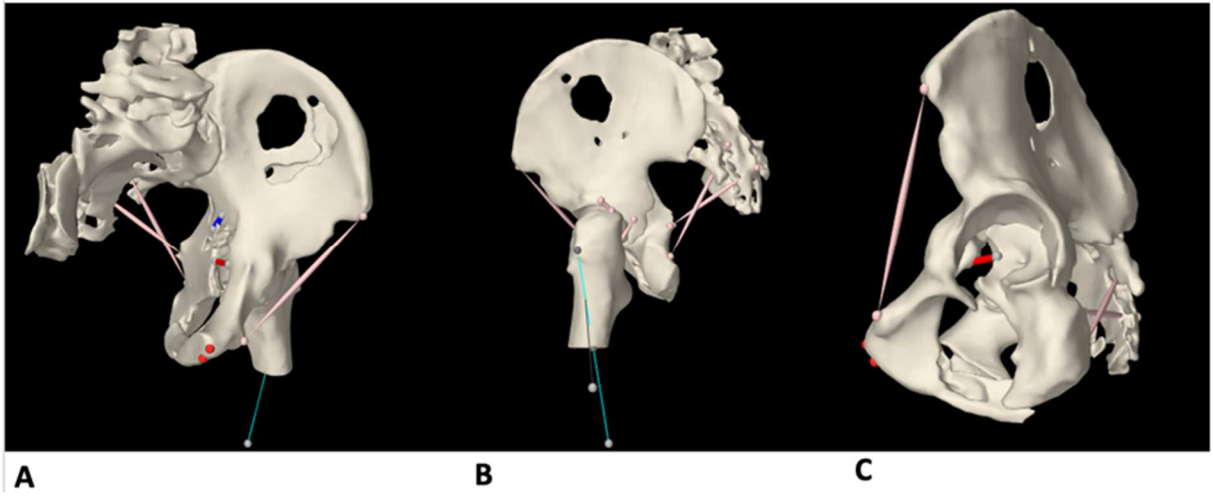
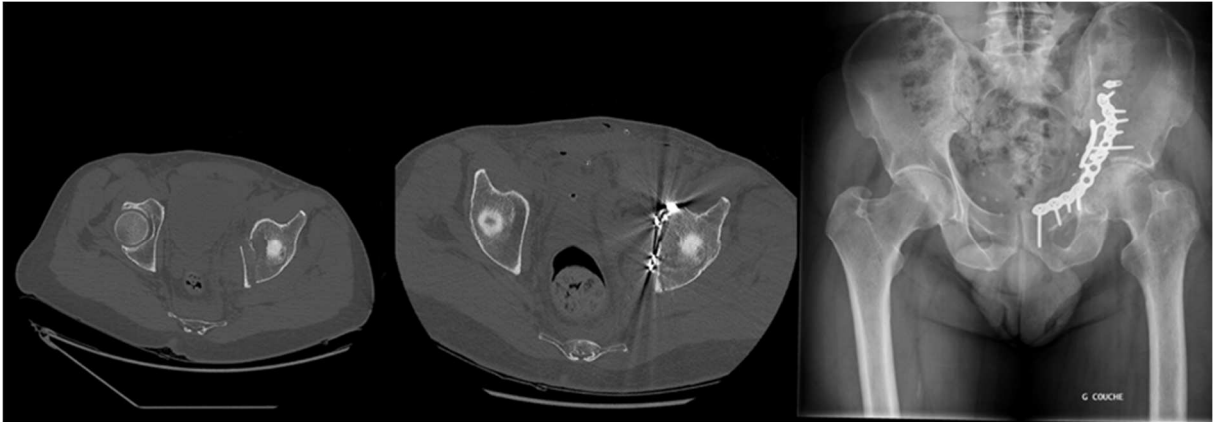


Figure 3:



A

B

C

Figure 4:

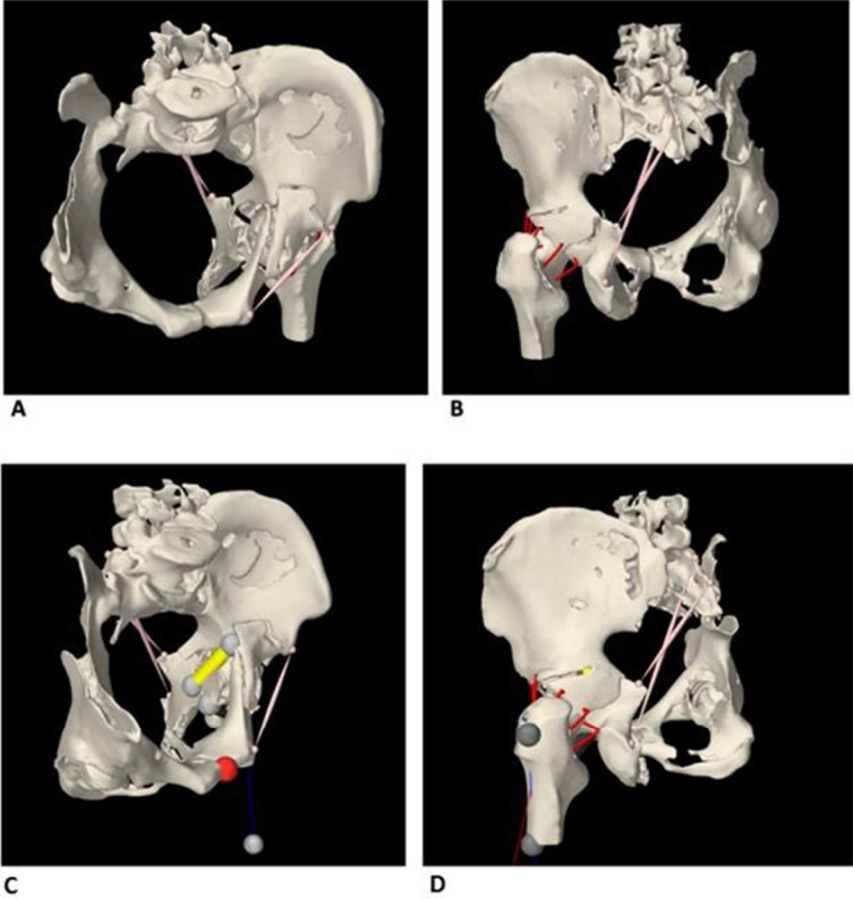
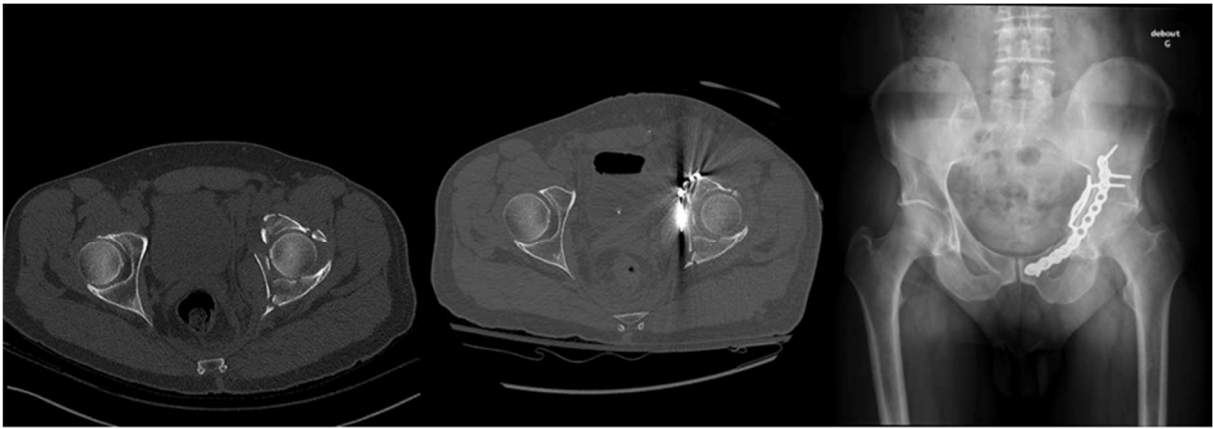


Figure 5:



A

B

C