



HAL
open science

A thrombopoietin receptor agonist to rescue an unusual platelet transfusion-induced reaction in a p.V1316M-associated von Willebrand disease type 2B patient

Caterina Casari, Remi Favier, Paulette Legendre, Alexandre Kauskot, Frederic Adam, Veronique Picard, Peter Lenting, Cecile Denis, Valerie Proulle

► To cite this version:

Caterina Casari, Remi Favier, Paulette Legendre, Alexandre Kauskot, Frederic Adam, et al.. A thrombopoietin receptor agonist to rescue an unusual platelet transfusion-induced reaction in a p.V1316M-associated von Willebrand disease type 2B patient. *Therapeutic Advances in Hematology*, 2022, 13, pp.204062072210768. 10.1177/20406207221076812 . hal-04455865

HAL Id: hal-04455865

<https://hal.science/hal-04455865v1>

Submitted on 5 Sep 2024

HAL is a multi-disciplinary open access archive for the deposit and dissemination of scientific research documents, whether they are published or not. The documents may come from teaching and research institutions in France or abroad, or from public or private research centers.

L'archive ouverte pluridisciplinaire **HAL**, est destinée au dépôt et à la diffusion de documents scientifiques de niveau recherche, publiés ou non, émanant des établissements d'enseignement et de recherche français ou étrangers, des laboratoires publics ou privés.

A thrombopoietin receptor agonist to rescue an unusual platelet transfusion-induced reaction in a p.V1316M-associated von Willebrand disease type 2B patient

Caterina Casari^{ID}, Remi Favier, Paulette Legendre, Alexandre Kauskot, Frederic Adam, Veronique Picard, Peter T. Lenting, Cecile V. Denis and Valerie Proulle^{ID}

Abstract: This report describes the first case of splenic injury in a patient with p.V1316M-associated von Willebrand disease type 2B (VWD2B) with chronic thrombocytopenia, successfully treated with nonoperative management including von Willebrand factor (VWF) replacement therapy, and platelet transfusions relayed by a thrombopoietin receptor agonist (TPO-RA, Eltrombopag). Eltrombopag was initially introduced to rescue an unusual post-platelet-transfusion reaction exacerbating the thrombocytopenia. In-depth analysis of the dramatic platelet count drop and VWF measurements timeline ruled out an allo-immune reaction and supported an alternative hypothesis of a sudden platelet clearance as a consequence of stress-induced release of abnormal VWF. One year later, a second life-threatening bleeding episode required urgent surgery successfully managed with VWF replacement therapy and platelet transfusions. Eltrombopag was further introduced in the post-surgery period to allow bleeding-free and platelet-transfusion-free successful recovery. Treatment decisions are particularly challenging in patients with VWD2B, and this case highlights how such decisions can benefit from understanding the molecular origin of platelet count fluctuations observed in these patients. Here, we successfully used a new therapeutic approach combining VWF-replacement therapy and initial platelet-transfusion relayed by TPO-RA to optimize patient management.

Plain language summary

A combination of von Willebrand factor replacement and thrombopoietin receptor agonist in thrombocytopenic patients with von Willebrand disease type 2B: a new therapy approach to optimize patient management?

- Therapeutic management of patients with von Willebrand disease type 2B are particularly challenging in case of severe thrombocytopenia.
- Treatment includes von Willebrand factor replacement therapy and iterative platelet transfusions.
- We describe the first case of splenic injury in a patient with p.V1316M-associated von Willebrand disease type 2B successfully treated with nonoperative management including von Willebrand factor replacement therapy and platelet transfusions relayed by a thrombopoietin receptor agonist.

Ther Adv Hematol

2022, Vol. 13: 1–10

DOI: 10.1177/
20406207221076812

© The Author(s), 2022.
Article reuse guidelines:
sagepub.com/journals-
permissions

Correspondence to:
Valerie Proulle
Service Hématologie
Biologique et Unité
Fonctionnelle
d'Hémostase Clinique,
Hôpital Cochin, APHP
Centre-Université de
Paris, 27 rue du Faubourg
Saint Jacques, 75014
Paris, France.
valerie.proulle@aphp.fr

Caterina Casari
Paulette Legendre
Alexandre Kauskot
Frederic Adam
Peter J. Lenting
Cecile V. Denis
INSERM UMR S 1176,
Université Paris-Saclay, Le
Kremlin-Bicêtre, France

Remi Favier
Service Hématologie
Biologique, Hôpital
Trousseau, APHP, CRPP,
Paris, France

Veronique Picard
Service Hématologie
Biologique, Hôpital
Bicêtre, APHP, Université
Paris-Saclay, Le Kremlin-
Bicêtre, France

- We showed that the unusual post-platelet-transfusion reaction associated with a dramatic platelet count drop was a consequence of stress-induced release of abnormal von Willebrand factor.
- The combination of von Willebrand factor replacement therapy and thrombopoietin receptor agonist may offer a new therapeutic approach to optimize patient management.

Keywords: eltrombopag, thrombocytopenia, thrombopoietin receptor agonist, von Willebrand disease type 2B, von Willebrand factor

Received: 19 August 2021; revised manuscript accepted: 9 January 2022.

Introduction

von Willebrand disease type 2B (VWD2B) is a rare inherited hemorrhagic disorder associating von Willebrand factor (VWF) and platelet abnormalities.¹ It is due to gain-of-function mutations clustered in exon 28 of *VWF* gene, increasing the affinity of the VWF-A1 domain for its platelet receptor glycoprotein Ib α . Platelet-bound VWF displays increased sensitivity to ADAMTS13-mediated proteolysis and induces platelet agglutination, leading to the loss of VWF high-molecular-weight multimers (HMWMs) and eventually thrombocytopenia. Platelet count (PC) is variable and can decrease concomitantly with increased VWF synthesis or release, such as, after desmopressin (DDAVP) administration or in stress situations, inflammation, or pregnancy. Although VWD2B is a heterogeneous disease, a genotype-phenotype correlation has been described.² Some mutations are associated with mild phenotypes, and others such as the p.V1316M substitution³ are responsible for severe manifestations due to the absence of VWF HMWMs and persistent platelet abnormalities. The latter include 1/a chronic macro-thrombocytopenia with giant platelets, due to megakaryocyte dysfunctions^{4,5} and increased platelet clearance⁶ and 2/a specific thrombopathy with defective integrin α IIb β 3 activation.^{7,8} Therapeutic management of patients carrying the p.V1316M variant can therefore be challenging, especially in case of life-threatening bleeding situations requiring exogenous VWF administration and iterative platelet transfusions.^{9,10}

Here, we report the exceptional case of a 13-year-old girl with p.V1316M-associated VWD2B who

developed an unusual post-platelet transfusion (PT) reaction and was successfully rescued with a thrombopoietin receptor agonist (TPO-RA) to overcome the thrombocytopenia during two serious bleeding episodes.

Case description

The patient was diagnosed at the age of 12, after a 10-year misdiagnosis of chronic refractory immune thrombocytopenia (ITP). She had persistent low PC ($30\text{--}50 \times 10^9/\text{L}$) with giant platelets, VWF:RCo of 0.15 IU/ml, VWF:Ag of 0.62 IU/ml, and FVIII:C >0.5 IU/ml (Table 1). She was first referred to our hospital for a splenic trauma and hemoperitoneum occurring after hula-hooping (Figure 1). Because of her hemodynamically stable condition, nonoperative management was proposed, based on international consensus¹¹ and literature experience in hemophiliac patients.¹² Strict immobilization was prescribed and both VWF replacement therapy ($30\text{--}60$ IU/kg/bid, Voncento®) and platelet transfusions (PT) were initiated at day 1 (D1) aiming to maintain VWF:Ag >1 IU/ml and PC $>50 \times 10^9/\text{L}$ for the following 6–8 weeks (Table 1). Unfortunately, at the end of the fourth PT at D10, the patient developed hypotension, cephalalgia, and hyperthermic shivering ($38\text{--}40^\circ\text{C}$). Paracetamol was administered and symptoms resolved 35 min later. Unexpectedly, PC dropped from 53 to 26 and $12 \times 10^9/\text{L}$ at 1 and 2 h post-PT, respectively, and spontaneously returned to $50\text{--}57 \times 10^9/\text{L}$, 15–24 h post-PT, with no hemorrhagic manifestation (Table 1, Figure 2(a)). Further investigations showed no signs of hemolysis, normal hemoglobin level (Hb), and negative

Table 1. Patient's laboratory evaluation and treatments.

Days/Weeks/Months	Laboratory evaluation					Treatments				
	Platelets ($\times 10^9/L$)	VWF:Ag (IU/ml)	VWF:RCo (IU/ml)	FVIII:C (IU/ml)	VWFpp (IU/ml)	Hemoglobin (g/dl)	Replacement therapy (VWF, IU)	Platelet transfusion (SPD)	TPO-RA (eltrombopag) (mg)	Tranexamic acid (g)
First episode (splenic trauma, hemoperitoneum)										
Day 1 (before treatment)	33	0.65	0.34	0.76	1.29	10.1	2000			
Day 1 (1 h after treatment)	60	1.24	0.70	1.08	1.15	8.9		6.2		3 (1 tid)
Day 1 (12 h after treatment)	48	1.06	0.59	1.1	1.04	9.8	2000 bid			
Day 2	44	1.81	1.01	1.46	0.95	9.7	2000 bid			3 (1 tid)
Day 3	42	1.43	0.59	1.02	0.86	9.8	2000 bid	6.8 + 4.2		3 (1 tid)
Day 5	155					11.1	2000 bid			
Day 5	105	1.52	0.75	1.27	0.82		2000 bid			
Day 7	67	1.60	0.81	1.13	0.92	12.4	2000 bid			3 (1 tid)
Day 9	56	1.54	0.53	1.12	0.87	11.4	2000 bid			3 (1 tid)
Day 10 (before PT)	53					11.5	2400 qd			3 (1 tid)
Day 10 (1 h after PT)	26	2.24	1.26	1.75	3.95	11.5		8.2		
Day 10 (2 h after PT)	12					11.1				
Day 11	50	2.53	1.33	1.52	1.07	11.6	2400 qd		25 qd	3 (1 tid)
Day 12	57					12.1	2400 qd		25 qd	3 (1 tid)
Week 3	148	0.88	0.17	0.84	0.97	11.7	2400 tiw		25 tiw	3 (1 tid)
Week 4	84	1.32	0.66	1.00	0.89	11.3	2400 tiw		25 tiw	3 (1 tid)
Week 6	42	0.58	0.27	0.59	0.53	10.6	2400 tiw		25 qd	3 (1 tid)
Week 24	45	0.52	0.16	0.67						
Week 35	21	0.60	0.24	0.64		13.4				
Second episode (ovarian cyst rupture, intraperitoneal hemorrhage)										
Day 1 (admission)	18	0.52	0.26			9.4				
Day 1 (before surgery)	80	1.06	0.62	1.33		7.7	3000 qd	4.5 (+ 3 RBCT+2 FFP)		
Day 2	56					8	3000 qd			3 (1 tid)

(Continued)

Table 1. (Continued)

Days/Weeks/Months	Laboratory evaluation				Treatments					
	Platelets ($\times 10^9/L$)	VWF:Ag (IU/ml)	VWF:RCo (IU/ml)	FVIII:C (IU/ml)	VWFpp (IU/ml)	Hemoglobin (g/dl)	Replacement therapy (VWF, IU)	Platelet transfusion (SPD)	TPO-RA (eltrombopag) (mg)	Tranexamic acid (g)
Day 2	84	2.46	1.74	1.3	10.7	3.5				
Day 2	58				9.4					3 (1 tid)
Day 3	54				8.6		3000 qd	(1 RBCT)		
Day 3	57	2.18	1.18	1.53	10.4					
Day 3	51				10.7					
Day 4	58	1.72	0.83	1.25	10.5		3000 qd		25 qd	3 (1 tid)
Day 4	40				11.5					
Day 5	46	0.62	0.15	1.41	11.2		3000 qd		25 qd	3 (1 tid)
Day 5	46				12.1					
Day 6	39	1.47	0.56	1.31	11.7		3000 qd		25 qd	3 (1 tid)
Day 7	45				12.7		3000 qd		25 qd	3 (1 tid)
Day 8	46				13		3000 qd		25 qd	3 (1 tid)
Day 9	42	1.26	0.45	1.05	13.1		3000 qd		25 qd	3 (1 tid)
Day 10	31				13.5		3000 qd		25 qd	3 (1 tid)
Day 11	38	1.06	0.42	0.99	12.8		3000 qd		25 qd	3 (1 tid)
Day 12	72	0.60	0.25	0.84	12.6				25 qd	3 (1 tid)
Month 3	26				13.8					
Month 5	26	0.52	0.19	0.58	12.7					

bid, twice a day; FFP, fresh frozen plasma, 1 unit; IU, International Unit; PT, platelet transfusions; qd, once a day; RBCT, red blood cells transfusion, 1 unit; tid, three times a day; tiw, three times a week; TPO-RA, thrombopoietin receptor agonist; VWF, von Willebrand factor; SPD, single platelet donor. Blood count was performed on blood anticoagulated with EDTA on a Sysmex XN[®]. Von Willebrand factor antigen [VWF: Ag] and factor VIII [FVIII:C] levels were measured on citrated platelet poor plasma (PPP) using STA[®]-Liatest-VWF-AG, STA[®]-ImmunoDefVIII and STA[®]-CKPrest on a STAR-Max[®], Stago according to manufacturer's instructions. VWF activity [VWF: RCo] was measured on PPP using BCvonWillebrand Reagent[®] on a CS-5100[®], Siemens according to manufacturer's instructions. VWF pro-peptide [VWFpp] was measured using an in-house ELISA as previously described.¹⁴

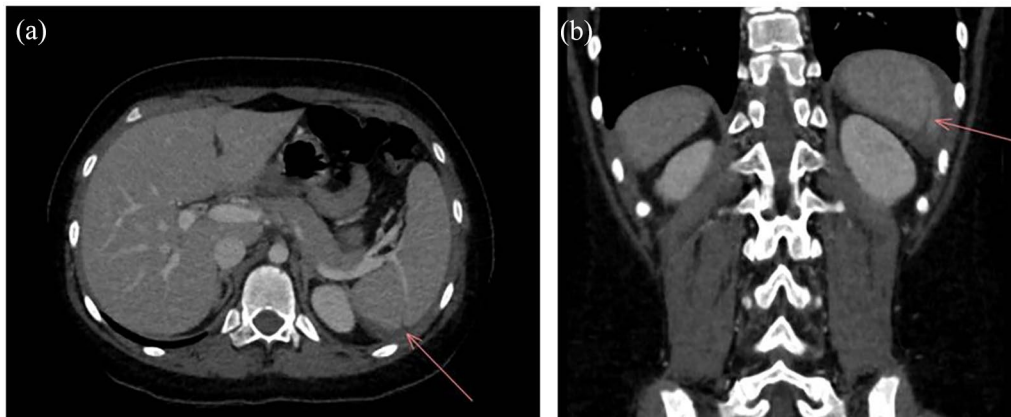


Figure 1. Computed tomography of the hemoperitoneum and splenic trauma: (a) hemoperitoneum seen as perisplenic blood collection (red arrow) and (b) splenic trauma seen as linear irregular hypodense area (red arrow).

blood cultures. Anti-HLA class I-II, anti-platelet-glycoprotein antibodies (anti-GPIaIIa, anti-GPIIbIIIa, anti-GPIb-IX) and ABO immune antibodies (IgG anti-A, anti-B) were measured after the PC drop to exclude an immune reaction. Neither anti-HLA class I-II nor specific anti-platelet-glycoprotein antibodies were evidenced. Instead, ABO immune antibodies were detected at high titers (IgG anti-A:1/512; anti-B:1/256), presumably consequent to the first ABO-incompatible PT (an A-pooled platelet unit was used while the patient is blood group O). PT was discontinued and oral TPO-RA (Eltrombopag, 25 mg/d) treatment was proposed and initiated at D11, after obtaining patient's parents informed consent. It resulted in an increase in PC, peaking at $148 \times 10^9/L$ the next following week, and plateauing $50\text{--}80 \times 10^9/L$ for the following 6 weeks during which the treatment was continued. One year later, the patient was again admitted for a voluminous intraperitoneal hemorrhage related to a left ovarian cyst rupture. PC ($18 \times 10^9/L$) and Hb (9.4 g/dl) were low and Hb further dropped (7.7 g/dl) despite immediate initiation of VWF replacement therapy (50 IU/kg/bid, Voncento®) and a first ABO-identical PT (Table 1, Figure 2(b)). An exploratory laparotomy was required and uneventful, surrounded by 1 per- and 1 immediate post-surgery PT. Eltrombopag was again prescribed (D4) to avoid any further PT-induced reaction. PC peaked as expected D12 ($72 \times 10^9/L$) and recovery was successful under the combination of Eltrombopag/VWF replacement up to D19 (Figure 2(b)). At 6-month follow-up, PC

was consistently below $30 \times 10^9/L$ and an estrogenic pill was introduced to manage menorrhagia while preventing the recurrence of the ovarian cyst (Table 1).

Discussion

In our patient, the first ABO-minor incompatible platelet transfusion might have been responsible for the appearance of the ABO immune antibodies, an occurrence previously associated with hemolysis with/without hyperthermia.¹⁵ However, in the absence of any subsequent signs of hemolysis or acute infection, and of any detectable alloimmunization, the dramatic drop in PC, which spontaneously resolved in 24 h, was unlikely attributable to a PT-related immune reaction. Conversely, post-transfusion PC kinetic was reminiscent of PC fluctuation post-DDAVP in patients with VWD2B,^{16,17} with a nadir at 30–60 min post-treatment and spontaneous return to baseline at 24 h. Similar to what happens during stressful situations, DDAVP induces massive release of endothelial, hyper-functional VWF, which exacerbates biological abnormalities including VWF proteolysis and thrombocytopenia.^{2,10,16,17} We hypothesized that the febrile post-transfusion reaction resulted in the stress situation provoking release of endogenous altered VWF and consequent sudden drop of the PC. Therefore, VWF propeptide (VWFpp) and VWF antigen (VWF:Ag) levels were measured to estimate endothelial VWF secretion and both endogenous/exogenous circulating VWF, respectively.

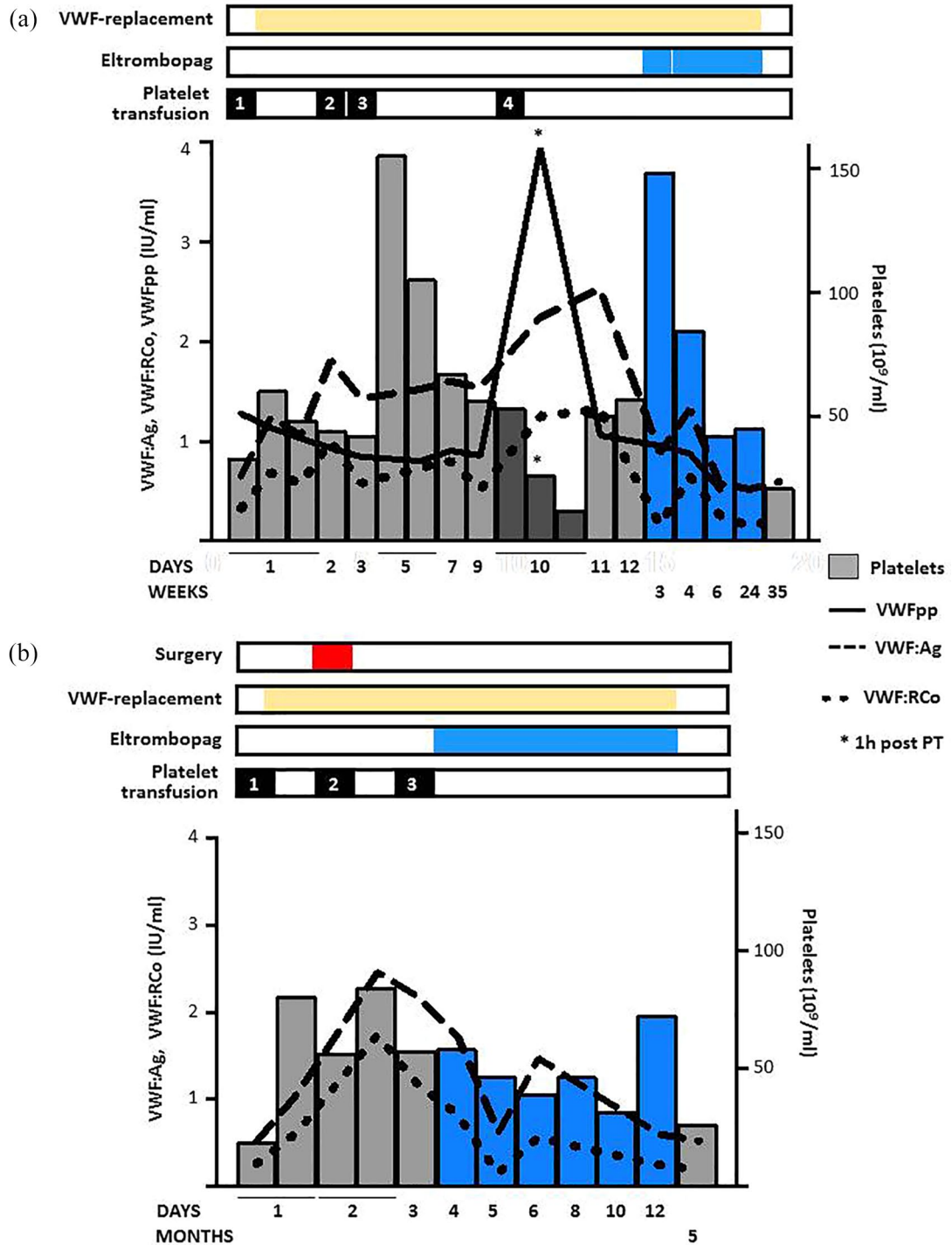


Figure 2. Timeline of patient's platelet count and von Willebrand factor antigen, activity and propeptide levels. Platelet count was measured in EDTA-anticoagulated blood on a Sysmex XN® (bars). VWF: Ag (dashed line) was measured in citrated-platelet poor plasma (PPP) using STA®-Liatest-VWF-AG® on a STAR-Max®, Stago, according to manufacturers' instructions. VWF: RCo (dotted line) was measured in PPP using BCvonWillebrand Reagent® on a CS-5100®, Siemens, according to manufacturers' instructions. VWFpp (solid line) was measured using an in-house ELISA as previously described.¹³ (a) Evolution of platelet count, VWF: Ag, VWF:RCo and VWFpp levels from Day 1 to Week 35 after the first bleeding episode. (b) Evolution of platelet count and VWF levels from Day 1 to Month 5 after the second bleeding episode.

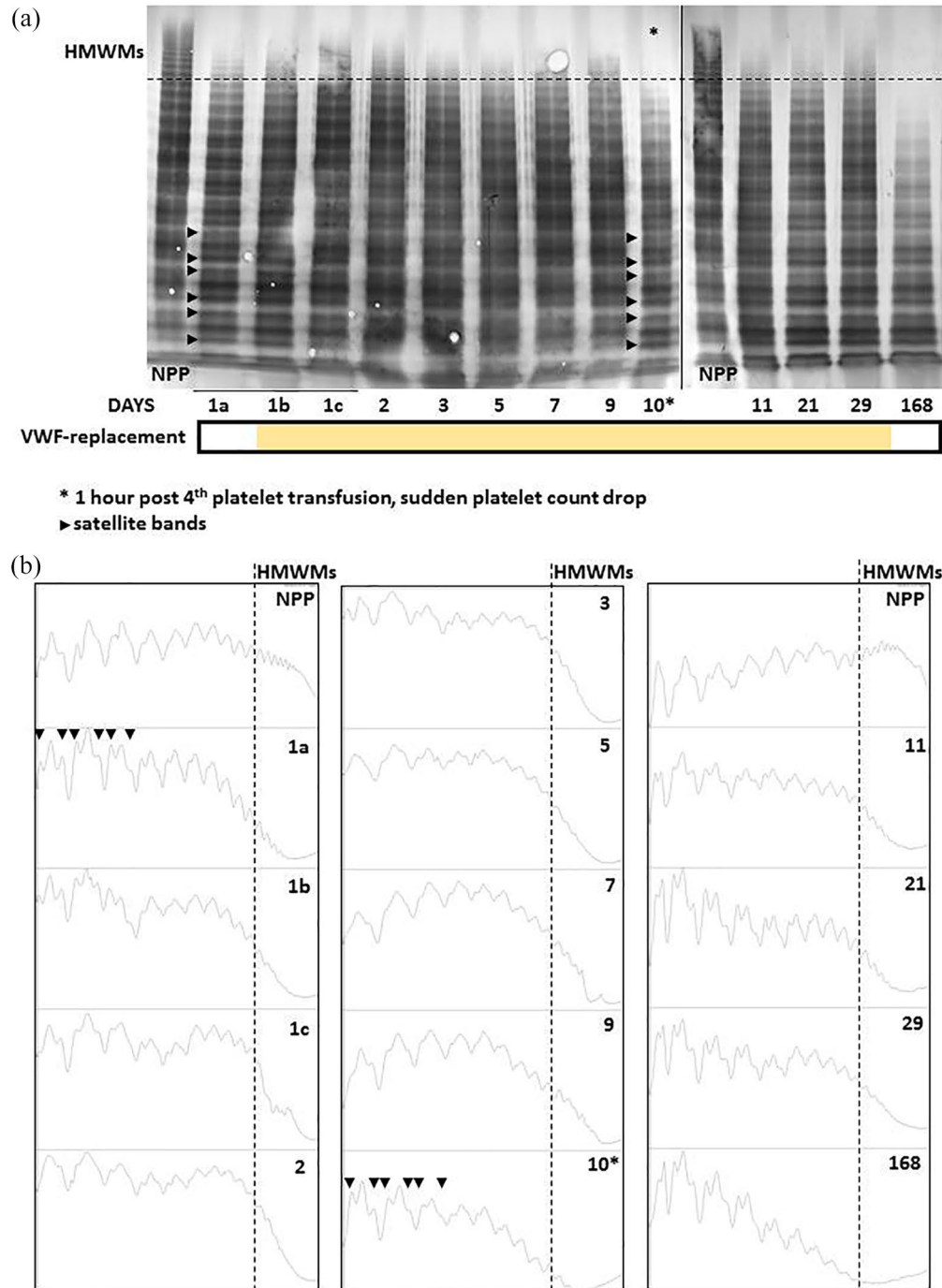


Figure 3. Multimer profile of patient's von Willebrand factor after the first bleeding episode. (a) The multimeric profile of VWF was analyzed in citrated-platelet poor plasma in 2% agarose gel essentially as previously described¹³ using an in-house alkaline phosphatase-conjugated anti-human VWF polyclonal antibody. Pictures were acquired using a G:BOX Chemi XT16 Image Systems and a Gene Tools version 4.0.0.0 (Syngene) software. The solid line separates two gels. The dashed line indicates VWF high molecular weight multimers (HMWMs). Arrowheads indicate satellite bands, such as VWF fragments derived from ADAMTS13-mediated proteolysis. (b) Profiles plots of multimers shown in (a). Multimer plots have been generated with ImageJ 2.1.0 software using the Gel Analyzer tool. NPP, normal pooled plasma.

VWF multimer profiles were measured to estimate secretion of endogenous altered VWF, administration of exogenous wild-type multimers, and their proteolytic state. While antigen levels were compatible with replacement regimen, VWFpp dramatically increased 1 h after the fourth PT (D10), concomitant with PC drop (Figure 2(a)). When analyzing multimer profiles (Figure 3), HMWMs were restored post-VWF replacement but punctually disappeared again at D10, 1 h post-PT. Satellite bands, the intensity of which reflects VWF proteolysis, appeared as smears in control plasma and as sharp, intense bands before treatment and again at D10, 1 h post-PT (Figure 3(a) and (b)), confirming enhanced proteolysis at these times. Together with the VWFpp peak and the brutal PC drop, these results support the hypothesis of a sudden release of altered VWF from the endothelial reservoirs triggered by the post-PT stress. The abnormal VWF is preferentially proteolyzed by ADAMTS13, consistent with sharp satellite bands, and punctually exacerbates thrombocytopenia. Conversely, while VWFpp returned to baseline at D11, HMWMs reappeared, and PC rose to the pre-PT level. This chronology further supports the deleterious role of the dramatic release of the abnormal p.V1316M-VWF in PC fluctuation in our case. Following initial PT required for the management of the first acute bleeding and the next vital surgery to maintain PC above $50\text{--}80 \times 10^9/\text{L}$, a TPO-RA was introduced to durably correct PC the next following weeks in this patient. Eltrombopag was initially introduced to prevent PT-induced stress reaction and avoid iterative PT required for the nonoperative management of the splenic injury. During the second life-threatening episode, Eltrombopag was started after surgery to successfully correct PC during the postoperative period without any further PT. To the best of our knowledge, this is the first case of splenic injury successfully treated with nonoperative management in a patient with p.V1316M-associated VWD2B and thrombocytopenia. Along with replacement therapy, initial PT were efficiently relayed by TPO-RA treatment to rise PC while avoiding iterative PT the next following weeks and allowed PT-free successful recovery.

TPO-RA, such as romiplostim and Eltrombopag, increase platelet production by activating JAK2/STAT5 pathway downstream of TPO-R, which results in megakaryocytes proliferation and

differentiation. Romiplostim competes directly with TPO for receptor-binding at its extra-cytoplasmic domain while eltrombopag binds at a distinct transmembrane site (residue H499).¹⁸ They have been first licensed for the treatment of chronic ITP and, the latter, for patients with severe aplastic anemia or interferon-ribavirin-treated hepatitis C. Clinical data suggest that TPO-RAs are comparably efficient in correcting PC in some hereditary thrombocytopenia such as myosin heavy chain 9-related disease (MYH9-RD) or Wiskott-Aldrich Syndrome (WAS).¹⁹ Eltrombopag has been efficiently used on a short-term basis to temporarily increase PC when needed prior surgery or invasive procedure in macrothrombocytopenia such as MYH9-RD, including in children.^{19–21} In a previous report, Eltrombopag was successfully used to correct a severe thrombocytopenia responsible for an intracranial hemorrhage in a p.V1316M-VWD2B patient.²² However, the question of whether the newly formed platelets remain dysfunctional is unanswered. In patients with WAS and ITP, eltrombopag treatment was not associated with platelet functional improvement.^{23,24} In VWD2B, platelet dysfunction derives from the interaction of hyper-active VWF with GPIIb α and abnormal activation of the PKC/P2Y12/Rap1 signaling pathway.⁸ The replacement therapy shifts the equilibrium toward high concentration of normal VWF, potentially protecting newly formed platelet from the PKC-dependent pre-activation. We therefore speculate that the combination of TPO-RA and VWF-replacement therapy over several weeks could favor the production of an increased number of normal platelets although future studies are required to prove this hypothesis.

Conclusion

In conclusion, we report the first case of VWD2B patient with splenic injury successfully treated with nonoperative management including VWF replacement therapy and TPO-RA. Eltrombopag was initially introduced to counteract the exacerbated thrombocytopenia post PT-stress reaction and successfully applied to prevent postoperative hemorrhage. The present case supports the safety and efficacy of eltrombopag administration in combination with VWF replacement therapy to improve the hemostatic management of nonurgent situations in thrombocytopenic VWD2B patients.

Author contributions

Caterina Casari: Conceptualization; Formal analysis; Methodology; Validation; Visualization; Writing – original draft; Writing – review & editing.

Remi Favier: Conceptualization; Formal analysis; Validation; Visualization; Writing – review & editing.

Paulette Legendre: Formal analysis; Methodology; Validation; Visualization; Writing – review & editing.

Alexandre Kauskot: Formal analysis; Methodology; Validation; Visualization; Writing – review & editing.

Frederic Adam: Formal analysis; Methodology; Validation; Visualization; Writing – review & editing.

Veronique Picard: Formal analysis; Methodology; Validation; Visualization; Writing – review & editing.

Peter J. Lenting: Formal analysis; Methodology; Validation; Visualization; Writing – review & editing.

Cecile V. Denis: Conceptualization; Formal analysis; Methodology; Supervision; Validation; Writing – review & editing.

Valerie Proulle: Conceptualization; Formal analysis; Funding acquisition; Investigation; Methodology; Supervision; Validation; Visualization; Writing – original draft; Writing – review & editing.

Conflict of interest statement

The authors declared the following potential conflicts of interest with respect to the research, authorship, and/or publication of this article: This research was supported by a research grant from CSL Behring to Valerie Proulle. The research grant from CSL Behring provided supports for VWF testing. The publication fees were paid by AEMSSI, Association pour l'Etude des Maladies du Sang et du Systeme Immunitaire, Le Kremlin-Bicetre, France. The other authors have no conflicts of interest to declare.

Funding

The authors received no financial support for the research, authorship, and/or publication of this article.

Statement of ethics

This case report complies with the guidelines for human studies and was conducted ethically in accordance with the World Medical Association Declaration of Helsinki. The case report is reported according to the CARE guidelines. The patient's parents gave their informed consent to publish the case.

ORCID iDs

Caterina Casari  <https://orcid.org/0000-0002-8271-6795>

Valerie Proulle  <https://orcid.org/0000-0003-3620-9570>

References

1. Leebeek FW and Eikenboom JC. Von Willebrand's disease. *N Engl J Med* 2016; 375: 2067–2080.
2. Federici AB, Mannucci PM, Castaman G, *et al.* Clinical and molecular predictors of thrombocytopenia and risk of bleeding in patients with von Willebrand disease type 2B: a cohort study of 67 patients. *Blood* 2009; 113: 526–534.
3. Rendal E, Penas N, Larrabeiti B, *et al.* Type 2B von Willebrand's disease due to Val1316Met mutation. Heterogeneity in the same sibship. *Ann Hematol* 2001; 80: 354–360.
4. Kauskot A, Poirault-Chassac S, Adam F, *et al.* LIM kinase/cofilin dysregulation promotes macrothrombocytopenia in severe von Willebrand disease-type 2B. *JCI Insight* 2016; 1: e88643.
5. Nurden P, Gobbi G, Nurden A, *et al.* Abnormal VWF modifies megakaryocytopoiesis: studies of platelets and megakaryocyte cultures from patients with von Willebrand disease type 2B. *Blood* 2010; 115: 2649–2656.
6. Casari C, Du V, Wu YP, *et al.* Accelerated uptake of VWF/platelet complexes in macrophages contributes to VWD type 2B-associated thrombocytopenia. *Blood* 2013; 122: 2893–2902.
7. Casari C, Berrou E, Lebret M, *et al.* von Willebrand factor mutation promotes thrombocytopenia by inhibiting integrin α IIb β 3. *J Clin Invest* 2013; 123: 5071–5081.
8. Casari C, Paul DS, Susen S, *et al.* Protein kinase C signaling dysfunction in von Willebrand disease (p.V1316M) type 2B platelets. *Blood Adv* 2018; 2: 1417–1428.

9. Connell NT, Flood V, Brignardello-Petersen R, *et al.* ASH ISTH NHF WFH 2021 guidelines on the management of von Willebrand disease. *Blood Adv* 2021; 5: 301–325.
10. Kruse-Jarres R and Johnsen JM. How I treat type 2B von Willebrand disease. *Blood* 2018; 131: 1292–1300.
11. Cocolini F, Montori G, Catena F, *et al.* Splenic trauma: WSES classification and guidelines for adult and pediatric patients. *World J Emerg Surg* 2017; 12: 40.
12. Sharma OP, Oswanski MF, Issa NM, *et al.* Role of non-operative management of spleen injury in patients with hemophilia: report of two patients with review of literature. *J Emerg Med* 2011; 41: e59–e64.
13. Obert B, Tout H, Veyradier A, *et al.* Estimation of the von Willebrand factor-cleaving protease in plasma using monoclonal antibodies to vWF. *Thromb Haemost* 1999; 82: 1382–1385.
14. van Schooten CJ, Denis CV, Lisman T, *et al.* Variations in glycosylation of von Willebrand factor with O-linked sialylated T antigen are associated with its plasma levels. *Blood* 2007; 109: 2430–2437.
15. Dunbar NM, Ornstein DL and Dumont LJ. ABO incompatible platelets: risks versus benefit. *Curr Opin Hematol* 2012; 19: 475–479.
16. Casonato A, Gallinaro L, Cattini MG, *et al.* Reduced survival of type 2B von Willebrand factor, irrespective of large multimer representation or thrombocytopenia. *Haematologica* 2010; 95: 1366–1372.
17. Casonato A, Daidone V, Galletta E, *et al.* Type 2B von Willebrand disease with or without large multimers: a distinction of the two sides of the disorder is long overdue. *PLoS ONE* 2017; 12: e0179566.
18. Ghanima W, Cooper N, Rodeghiero F, *et al.* Thrombopoietin receptor agonists: ten years later. *Haematologica* 2019; 104: 1112–1123.
19. Rodeghiero F, Pecci A and Balduini CL. Thrombopoietin receptor agonists in hereditary thrombocytopenias. *J Thromb Haemost* 2018; 16: 1700–1710.
20. Favier R, Ferial J, Favier M, *et al.* First successful use of eltrombopag before surgery in a child with MYH9-related thrombocytopenia. *Pediatrics* 2013; 132: e793–e795.
21. Pecci A, Barozzi S, d'Amico S, *et al.* Short-term eltrombopag for surgical preparation of a patient with inherited thrombocytopenia deriving from MYH9 mutation. *Thromb Haemost* 2012; 107: 1188–1189.
22. Espitia O, Ternisien C, Agard C, *et al.* Use of a thrombopoietin receptor agonist in von Willebrand disease type 2B (p.V1316M) with severe thrombocytopenia and intracranial hemorrhage. *Platelets* 2017; 28: 518–520.
23. Gerrits AJ, Leven EA, Frelinger AL, *et al.* Effects of eltrombopag on platelet count and platelet activation in Wiskott-Aldrich syndrome/X-linked thrombocytopenia. *Blood* 2015; 126: 1367–1378.
24. Haselboeck J, Kaider A, Pabinger I, *et al.* Function of eltrombopag-induced platelets compared to platelets from control patients with immune thrombocytopenia. *Thromb Haemost* 2013; 109: 676–683.