



HAL
open science

Stereotactic magnetic resonance imaging-guided radiotherapy for intracardiac metastases: A case report

M. Michalet, R. Tétreau, Jean Luc Pasquié, O. Chabre, D. Azria

► **To cite this version:**

M. Michalet, R. Tétreau, Jean Luc Pasquié, O. Chabre, D. Azria. Stereotactic magnetic resonance imaging-guided radiotherapy for intracardiac metastases: A case report. *Cancer/Radiothérapie*, 2024, 10.1016/j.canrad.2023.06.033 . hal-04452378

HAL Id: hal-04452378

<https://hal.science/hal-04452378v1>

Submitted on 12 Feb 2024

HAL is a multi-disciplinary open access archive for the deposit and dissemination of scientific research documents, whether they are published or not. The documents may come from teaching and research institutions in France or abroad, or from public or private research centers.

L'archive ouverte pluridisciplinaire **HAL**, est destinée au dépôt et à la diffusion de documents scientifiques de niveau recherche, publiés ou non, émanant des établissements d'enseignement et de recherche français ou étrangers, des laboratoires publics ou privés.

Stereotactic magnetic resonance imaging-guided radiotherapy for intracardiac metastases: A case report

M Michalet ¹, R Tétreau ², J-L Pasquié ³, O Chabre ⁴, D Azria ⁵

¹ Institut du cancer de Montpellier, 208, avenue des Apothicaires, 34298 Montpellier, France; Fédération universitaire d'oncologie radiothérapie d'Occitanie Méditerranée (FOROM), 208, avenue des Apothicaires, 34298 Montpellier, France; Inserm, U1194 IRCM, 208, avenue des Apothicaires, 34298 Montpellier, France. Electronic address: morgan.michalet@icm.unicancer.fr.

² Service d'imagerie médicale, institut du cancer de Montpellier, 208, avenue des Apothicaires, 34298 Montpellier, France.

³ Service de cardiologie, CHU de Montpellier, 371, avenue du Doyen-Gaston-Giraud, 34295 Montpellier cedex 5, France; CNRS, UMR9214, Montpellier, France; Inserm, U1046 Phymedexp, Montpellier, France; Université de Montpellier, Montpellier, France.

⁴ Service d'endocrinologie-diabétologie, CHU de Grenoble-Alpes, boulevard de la Chantourne, 38043 Grenoble cedex 9, France.

⁵ Institut du cancer de Montpellier, 208, avenue des Apothicaires, 34298 Montpellier, France; Fédération universitaire d'oncologie radiothérapie d'Occitanie Méditerranée (FOROM), 208, avenue des Apothicaires, 34298 Montpellier, France; Inserm, U1194 IRCM, 208, avenue des Apothicaires, 34298 Montpellier, France.

Keywords:

Adrenocortical carcinoma; Carcinome corticosurrénalien; Cardiac metastases; MR-guided radiotherapy; Métastases cardiaques; Radiothérapie guidée par IRM.

Mots clés :

Radiothérapie guidée par IRM Carcinome corticosurrénalien Métastases cardiaques

***Corresponding author.**

Institut du cancer de Montpellier, 208, avenue des Apothicaires, 34298 Montpellier, France.

E-mail address:

morgan.michalet@icm.unicancer.fr (M. Michalet).

Abstract

Adrenocortical carcinoma is a malignant tumor with a poor prognosis and a frequent metastatic extension. In very rare cases, a cardiac metastatic disease may occur, and surgical resection is essential for its management. MR-guided stereotactic radiotherapy is an attractive radiotherapy modality for the treatment of mobile thoracic tumors, enabling the target to be monitored continuously during irradiation, while the dosimetric plan can be adapted daily if necessary. We report here the case of a patient with intracardiac metastasis secondary to malignant adrenocortical carcinoma, treated with magnetic resonance imaging-guided stereotactic radiotherapy.

R é s u m é

Le corticosurrénalome est une tumeur maligne de pronostic défavorable avec une extension métastatique fréquente. Dans de très rares cas, il est possible d'observer une atteinte métastatique cardiaque, dont la prise en charge repose avant tout sur la résection chirurgicale. La radiothérapie les, permettant de suivre la cible de fac, on continue pendant l'irradiation, tout en adaptant quotidiennement le plan dosimétrique selon le besoin. Nous rapportons ici le cas d'une patiente atteinte d'une métastase intracardiaque secondaire à un corticosurrénalome malin, traitée par irradiation stéréotaxique guidée par IRM.

--

1. Introduction

Adrenocortical carcinoma is a rare endocrine malignancy arising from the adrenal gland. Adrenocortical carcinoma can secrete different cortical hormones (causing hypercorticism, hyperandrogenism, or primary aldosteronism), leading to different morbidity [1]. The prognosis is bad, with most of cases metastatic or locally advanced at time of diagnosis [2]. Surgery is the cornerstone of localized diseases treatment, whereas chemotherapy is used for metastatic diseases (mitotane for indolent diseases or more aggressive platinum-based regimens for others) [3].

Cardiac tumors are rare and most of them are benign [4]. Among malign tumors, metastatic tumors are 100 to 1000-fold more com-mon than primary cardiac tumors [5]. Treatment of cardiac tumors is classically based on surgical resection. Radiation therapy is a limited option due to limited heart constraint doses, even in old literature on this topic [6].

Magnetic resonance imaging (MRI)-guided radiotherapy is an interesting option for such treatment, thanks to three advantages in comparison to "standard" radiotherapy. It offers a good contrast for cardiac tumors using MR images contrast and the possibility to follow the

target during irradiation with continuous cine-MR images. Moreover, it is possible to daily adapt the plan to take into account the possible volume modifications [7,8]. We present in this article the case of a patient treated in our institution with MRI-guided radiation for an intracardiac metastasis from a primitive adrenocortical carcinoma.

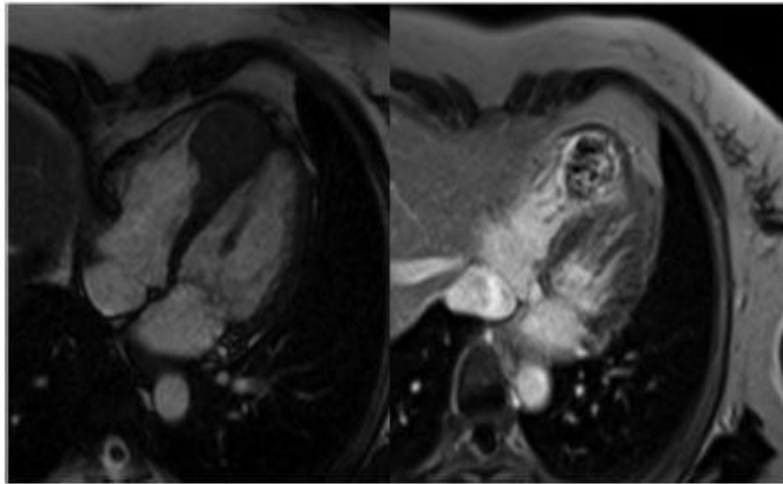


Fig. 1. Cardiac MRI performed before radiotherapy, showing a lesion of 41-mm developed from right ventricle with hyposignal on T2 sequence (left) and peripheral enhancement after gadolinium injection and necrotico-hemorrhagic changes on T1 sequence (right).

2. Case presentation

A 65-year-old female patient was addressed in our department; she had a history of adrenocortical carcinoma with a first treatment 10 years before, which consisted of a left adrenalectomy. She later developed local recurrence treated by partial diaphragmatic resection 7 years later and hepatic metastases treated with chemoembolization. Six years after this, she was diagnosed with an asymptomatic cardiac metastasis located in the right ventricle. A close follow-up was proposed, and the patient had been treated with radiofrequency for pulmonary metastases 5 years and 2 years before admission in our department. The cardiac mass did not progress since first radiofrequency treatment.

One month following the second radiofrequency treatment, the patient presented with electrocardiogram modifications, without clinical symptoms. A cardiac MRI was performed and found a 41-mm heterogeneous right ventricular mass, probably with septoapical myocardial origin, with intralesional necrotic-haemorrhagic changes, confirming the progression of this cardiac metastasis (Fig. 1). The CT-scan did not find any other progression except this cardiac lesion. The case was discussed in multidisciplinary staff meeting. The surgical resection was contra indicated due to technical impossibility. The patient was proposed for a radiotherapy.

Clinically, the patient was asymptomatic, with a performance status of 0. The cardiac report was good, with a left ventricular ejection fraction of 61% on echocardiography and no kinetic troubles.

We discussed this case in our department and proposed a stereotactic MR-guided radiotherapy. We chose to use the MRIdian (Viewray®), which is a MR-linear accelerator (6-MV linear accelerator combined with a 0.35-T MR-imaging device). We prescribed 30 Gy in five fractions every other day, over two weeks, with normalization on D50%, ensuring a target coverage (planning target volume [PTV]) of 95% within the 95% isodose. PTV was built with a 3-mm isotropic expansion from GTV, which was delineated using MRIdian simulation images, as well as a 1.5-T diagnostic MRI after registration.

Table 1
Stereotactic magnetic resonance imaging-guided radiotherapy for intracardiac metastases, report of a case: volumes and dose constraints.

Volumes	
Gross tumor volume (GTV)	44.21 cm ³
Planning target volume (PTV)	63.64 cm ³
Dose constraints	
Heart valves	< 0.5 cm ³ at 23 Gy, Dmax 38 Gy
Heart excluding PTV	< 15 cm ³ at 32 Gy, Dmax 38 Gy
Large bowel	Dmax < 32 Gy
Stomach	Dmax < 32 Gy

Dmax: maximum dose.

Volumes and dose constraints used are presented in Table 1. A 98.1% target coverage was obtained for the PTV V95%. The dose distribution is shown in Fig. 2.

A cardiological assessment with electrocardiogram and echocardiography was proposed before, during treatment (after the third fraction) and after the last fraction. A continuous electrocardiogram monitoring was performed during irradiation using an amagnetic scopus. The treatment was well tolerated with no evidence of cardiac dysfunction during and after treatment, and no other toxicity.

A close follow-up was performed with a clinical assessment at 1, 3 and 6 months and a CT-scan assessment at 3 and 6 months after treatment. We observed a progressive partial response as shown in Fig. 3. At 6 months post-treatment, the lesion measured 31 × 34 mm compared to 36 × 41 mm before treatment. The other already known secondary pulmonary lesions were stable. The patient was asymptomatic and the cardiological evaluation was perfectly stable.

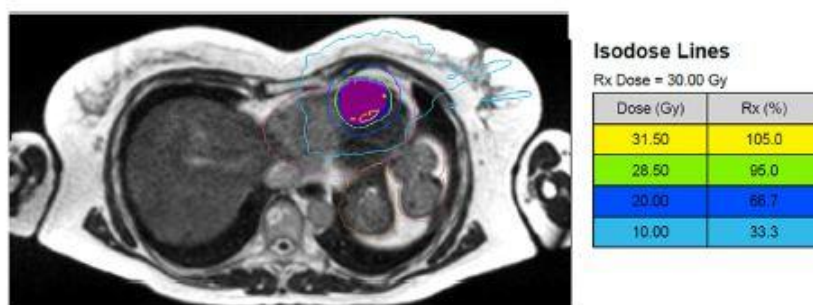


Fig. 2. Dose distribution of MRgRT with a prescription dose of 30 Gy in 5 fractions. GTV in purple colorwash, PTV in blue colorwash, 95% isodose in green.

Discussion

As cardiac metastases are rare situations, only few data are available concerning the use of radiotherapy in this situation. On the other hand, some data are emerging concerning the use of stereotactic radiotherapy for refractory ventricular tachycardia [9,10]. MR-guided radiotherapy is an interesting option for the treatment of cardiac masses. Corradini et al. described their experience of MRI-guided radiotherapy for primary cardiac sarcomas [11]. All patients were irradiated in a salvage situation after surgery with a prescription of 30 to 35 Gy in five fractions. All patients completed the treatment with a good tolerance.

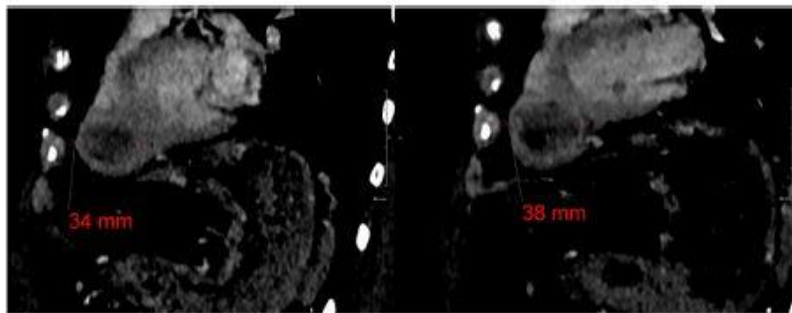


Fig. 3. CT-scan with iodine contrast product injection performed at 3 months (right) and 6 months (left) after treatment, showing a progressive partial response.

Other authors described their experience for the treatment of intracardiac and pericardial metastases using MRI-guided radiation [12]. They treated five patients with a median dose of 40 Gy in five fractions. After a median follow-up of 4.7 months, all patients presented a stable disease, partial or complete response. One patient presented with an atrial fibrillation 6 months after treatment.

Due to the larger lesion size than those described in the two previous articles, we chose to deliver a dose of 30 Gy in five fractions for this patient. We obtained a good partial response, with no other progressive lesion and no toxicity observed after a follow-up of 6 months. This result is encouraging, and we hope to obtain a better response in the following months along with a good quality of life.

Conclusion

MRI-guided radiotherapy appears to be a potential good option for inoperable cardiac tumors. A longer follow-up is required to assess late toxicity and survival outcomes.

Disclosure of interests

The authors have not declared their activities/relationships/interests.

References

- [1] Vaidya A, Nehs M, Kilbridge K. Treatment of adrenocortical carcinoma. *Surg Pathol Clin* 2019;12:997–1006.
- [2] Ahmed AA, Thomas AJ, Ganeshan DM, Blair KJ, Lall C, Lee JT, et al. Adrenal cortical carcinoma: pathology, genomics, prognosis, imaging features, and mimics with impact on management. *Abdom Radiol* 2020;45:945–63.
- [3] Jasim S, Habra MA. Management of adrenocortical carcinoma. *Curr Oncol Rep* 2019;21:20.
- [4] Taguchi S. Comprehensive review of the epidemiology and treatments for malignant adult cardiac tumors. *Gen Thorac Cardiovasc Surg* 2018;66:257–62.
- [5] Sarjeant JM, Butany J, Cusimano RJ. Cancer of the heart. *Am J Cardiovasc Drugs* 2003;3:407–21.
- [6] Cham WC, Freiman AH, Carstens PHB, Chu FCH. Radiation therapy of cardiac and pericardial metastases. *Radiology* 1975;114:701–4.
- [7] Mutic S, Dempsey JF. The ViewRay System: magnetic resonance-guided and controlled radiotherapy. *Semin Radiat Oncol* 2014;24:196–9.3
- [8] Michalet M, Bettaïeb O, Khalfi S, Ghorbel A, Valdenaire S, Debuire P, et al. Stereotactic MR-guided radiotherapy for adrenal gland metastases: first clinical results. *J Clin Med* 2022;12:291
- [9] Benali K, Bellec J, Jaksic N, Caille P, Rigal L, Simon A, et al. Cardiac stereotactic ablative radiotherapy for refractory ventricular arrhythmias: a radical alternative? A narrative review of rationale and cardiological aspects. *J Med Imaging Radiat Sci* 2021;52:626–35.
- [10] Cuculich PS, Schill MR, Kashani R, Mutic S, Lang A, Cooper D, et al. Non invasive cardiac radiation for ablation of ventricular tachycardia. *N Engl J Med* 2017;377:2325–36.
- [11] Corradini S, von Bestenbostel R, Romano A, Curta A, Di Gioia D, Placidi L, et al. MR-guided stereotactic body radiation therapy for primary cardiac sarcomas. *Radiat Oncol* 2021;16:60.
- [12] Sim AJ, Palm RF, De Lozier KB, Feygelman V, Latifi K, Redler G, et al. MR-guided stereotactic body radiation therapy for intracardiac and pericardial metastases. *Clin Transl Radiat Oncol* 2020;25:102–6.4