HAL
open science

Enhancing Myocardial Disease Prediction with DOC-NET+ Architecture: A Custom Data Analysis Approach for the EMIDEC Challenge

Mariem Dali, Rostom Kachouri, Narjes Benameur, Youness Laaroussi, Salam Laabidi

To cite this version:

Mariem Dali, Rostom Kachouri, Narjes Benameur, Youness Laaroussi, Salam Laabidi. Enhancing Myocardial Disease Prediction with DOC-NET+ Architecture: A Custom Data Analysis Approach for the EMIDEC Challenge. The 2nd International conference on Machine Learning and Data Engineering (ICMLDE 2023), Nov 2023, Dehradun, India. hal-04451330

HAL Id: hal-04451330

https://hal.science/hal-04451330v1

Submitted on 11 Feb 2024

HAL is a multi-disciplinary open access archive for the deposit and dissemination of scientific research documents, whether they are published or not. The documents may come from teaching and research institutions in France or abroad, or from public or private research centers.

L'archive ouverte pluridisciplinaire **HAL**, est destinée au dépôt et à la diffusion de documents scientifiques de niveau recherche, publiés ou non, émanant des établissements d'enseignement et de recherche français ou étrangers, des laboratoires publics ou privés.

International Conference on Machine Learning and Data Engineering (ICMLDE 2023)

Enhancing Myocardial Disease Prediction with DOC-NET+ Architecture: A Custom Data Analysis Approach for the EMIDEC Challenge.

Mariem Dali[a], Rostom Kachouri[b], Narjes Benameur[a], Younes Arous[c], Salam Laabidi[a,*]

[a] *University of Tunis El Manar, Higher Institute of Medical Technologies of Tunis, Research Laboratory of Biophysics and MedicalTechnologies, 1006 Tunis, Tunisia*
[b] *Gaspard Monge Computer Science Laboratory. ESIEE Paris, Gustave Eiffel university, France*
[c] *Departement of Radiology of the Military Hospital of Tunis, Bab alioua,1008 Montfleury, Tunis, Tunisia*

Abstract

Cardiovascular diseases, including myocarditis and myocardial infarction (MI), pose substantial health risks due to their life-threatening nature. This article delves into the complexities of distinguishing these conditions, as they share symptoms and diagnostic challenges. It underscores the vital role of advanced imaging techniques, such as cardiac magnetic resonance imaging (CMR), and emphasizes the emerging importance of artificial intelligence (AI), particularly the innovative DOC-Net+ architecture, in refining precision.

Through a comprehensive exploration of the EMIDEC challenge, which combines clinical data with MRI insights, this study highlights AI's potential to enhance diagnosis accuracy. Notably, our implementation of both the DOC-NET and DOC-NET+ architectures yielded promising classification results, achieving 97% and 98% accuracy, respectively, on our newly established dataset.

Keywords: Classification; EMIDEC Challenge; Custom Database; DOC-Net+

1. Introduction

Due to their potentially life-threatening nature, cardiovascular diseases pose a significant public health hazard. This category encompasses a wide range of illnesses that affect the anatomy, function, or electrical activity of the heart.

* Corresponding author. Tel.: +0-000-000-0000 ; fax: +0-000-000-0000 .
E-mail address: Mariem.dali@istmt.utm.tn

Click here to enter text.

From congenital defects to acquired disorders, cardiac illnesses have a profound impact on individuals of all ages, leading to severe health consequences and notably high mortality rates [1]. Among these conditions, Myocarditis and Myocardial Infarction (MI) stand out as two distinct cardiac diseases, often presenting with overlapping symptoms, similar test findings, diagnostic imaging limitations, and the need to consider timing and clinical context. These complexities further challenge their differentiation.

Myocarditis refers to the myocardium inflammation, often caused by viral infections or autoimmune processes [2]. In recent times, there have been concerns regarding myocarditis related to the coronavirus disease pandemic 2019 (COVID-19), caused by the severe acute respiratory syndrome coronavirus 2 (SARS-CoV-2). Its occurrence, either independently or in conjunction with COVID-19, has raised alarms within the medical community due to its potential impact on cardiac function and heightened risk of severe outcomes [3,4]. Conversely, MI, also recognized as a critical manifestation of coronary artery disease (CAD), occurs when the coronary arteries are obstructed, leading to insufficient blood supply. This condition is further categorized into two types: ST-elevation MI (STE-MI) and non-ST-elevation MI (NSTE-MI), both falling under the spectrum of acute coronary syndrome (ACS) [5].

Efficiently distinguishing between myocarditis and MI hinges on factors like patient history, risk elements, and symptom timing. Myocarditis is often linked to viral infections or autoimmunity, indicating inflammation, whereas MI is correlated with conditions like hypertension and smoking, associated with atherosclerosis. These distinctions become challenging in cases with incomplete patient histories, necessitating heightened investigative efforts. Given the common symptoms as chest pain, breathlessness, and fatigue, a refined exploratory approach is essential. The application of endomyocardial biopsy (EMB) proves valuable, directly assessing heart tissue. However, due to its invasiveness and potential for false negatives, EMB is selectively employed [6]. Although cardiac troponin, marker tests, ECG, and echocardiography provide initial insights, their limitations call for additional techniques [7-11]. This is where tools like cardiac magnetic resonance imaging (CMR) or coronary angiography significantly contribute to elevating diagnostic accuracy [12].

CMR plays a vital role in distinguishing between various disorders due to its unique sequencing methodologies. It can assess ventricular function, identify features associated with inflammation and oedema, and detect pathological anomalies, including scar tissue, by utilizing different sequences, particularly the Late Gadolinium Enhancement imaging (LGE) which utilizes a gadolinium-based contrast agent [13]. The utilization of CMR is significantly enhanced by the application of the Lake Louise Criteria (LLC), initially established in 2009 [14]. These criteria require the presence of at least two qualifications for a positive diagnosis, including oedema on T2-weighted imaging, hyperaemia on T1-weighted images, and fibrosis apparent through LGE, thereby improving clinical acuity.

However, successful interpretation of CMR images in complex scenarios requires an understanding of specific patterns and anomalies. In myocarditis, the delayed enhancement (DE) pattern often presents as a patchy or multifocal distribution throughout the myocardium, indicating localized inflammatory infiltrates and areas of myocyte damage. Conversely, MI exhibits a distinct pattern characterized by transmural enhancement extending from the endocardium to the epicardium. This transmural pattern encompasses the entire infarcted area, indicative of irreversible damage caused by coronary artery occlusion [15]. Distinguishing between myocarditis and MI based solely on small tissue feature changes can be challenging, as LGE patterns may be indeterminate or atypical. Additionally, image quality and artifacts, such as patient motion or metallic implants, can compromise clarity, making it difficult to visualize specific structures and measure tissue attributes. Furthermore, discrepancies in CMR procedures and approaches across different centres can further contribute to these challenges [16,17].

In recognition of the limitations discussed earlier, the EMIDEC challenge [18] emerged as a response to these quests. This challenge was conducted as part of the STACOM workshop, in conjunction with MICCAI 2020. The primary objective of the challenge was to leverage a combination of clinical physiological data and delayed enhancement magnetic resonance imaging (DE-MRI) to address the classification task. This initiative highlighted the increasing importance of artificial intelligence (AI) in cardiac imaging, aiming to enhance diagnostic accuracy and expedite the differentiation process [19].

The paper aims to present a state-of-the-art analysis of studies conducted within the context of the EMIDEC challenge. It will explore existing research and advancements in this field. Additionally, this work will introduce a novel database specifically created for this study, detailing the data collection procedure and the various imaging techniques employed. In addition, a thorough examination of the state-of-the-art will inform the selection of a specific technique for leveraging our new dataset.

The paper is structured as follows:

Section 2 provides an EMIDEC challenge overview and state-of-the-art studies in the domain.
Section 3 introduces the study's database, discussing its creation and protocol selection.
Section 4 presents experiment results and in-depth findings.
Finally, **Section 5** concludes by summarizing key insights and suggesting future research directions.

2. EMIDEC Background

2.1. EMIDEC Database

The EMIDEC challenge Dataset [18] comprises a comprehensive collection of delayed Enhancement (DE-MRI) scans and associated clinical information from 100 individuals. This dataset was created from real clinical exams acquired at the University Hospital of Dijon (France) and made available during the MICCAI 2020 conference. It includes DE-MRI images in the short-axis orientation, covering the left ventricle from the base to the apex, along with ground truth contours of the myocardium and diseased areas. Each DE-MRI examination typically consists of seven slices. The DE-MRI acquisitions were conducted using 1.5 T and 3 T magnets as part of a standard cardiovascular exam. In addition to the imaging, a text file containing 12 clinical details was provided, encompassing information such as sex, age, smoking habits, overweight status, hypertension, diabetes, family history of coronary artery disease, ECG, Killip max, troponin, ejection fraction, and NTproBNP. The dataset exhibits an asymmetric distribution, with approximately one-third of the cases classified as normal and the remaining two-thirds as pathological, representing real-world conditions observed in MRI departments.

However, it's imperative to recognize that the EMIDEC dataset is underpinned by a retrospective study design. Moreover, the acquisition of MR images adheres to a conventional cardiovascular examination protocol, potentially confining the applicability of the findings. Furthermore, it's noteworthy that the dataset exclusively encompasses DE-MRI scans in the short-axis orientation, a feature that might curtail a comprehensive evaluation of the myocardium's condition.

2.2. EMIDEC related Works

These studies can be broadly categorized into two primary domains: distinguishing between myocarditis and MI and differentiating normal cases from abnormal ones. In a notable study, Shi et al. employed a 3D Convolutional Neural Network (CNN) to predict the infarction area and calculate its volume. By integrating this information with other clinical parameters, they achieved promising results using a random forest model [20]. In another approach, Girum et al. proposed a two-stage framework employing separate neural networks to segment anatomical structures and pathological areas. Their method showed favourable accuracy by incorporating DE-MRI data and utilizing a cascaded support vector machine (SVM) [21]. Building upon these findings, Ivantsits et al. extended the research by combining deep learning (DL) and classical machine learning techniques (ML). Their approach yielded impressive accuracy in the classification task, showcasing the potential of these combined methodologies [22]. In 2023, Atallah et al. introduced AutoMyIn, an automated diagnostic tool for diagnosing MI. By training multiple lightweight CNNs using textural-based information from DE-MRI, they utilized the GLCM method with different grey levels [24]. Similarly, in the same year, Rahman et al. conducted a groundbreaking study focusing on classifying patients in the emergency department based solely on clinical information [25]. Their approach aimed to differentiate between myocarditis, MI, and other patient conditions using DE-MRI as the reference standard.

Lourenço et al.'s work was particularly attractive, achieving 100% accuracy. They employed Clinic-NET, a 4-layer fully connected neural network (FCNN), to achieve excellent classification performance using clinical parameters. By further enhancing their results through the incorporation of DE-MRI images processed with 3D convolutional layers, they demonstrated the effectiveness of their approach called DOC-NET [23].

Table 1 contains a summary of these results, including major findings, and limitations.

TABLE I. EMIDEC DATA IN RECENT STUDIES: FINDINGS AND LIMITATIONS

Authors, Reference	*Accuracy Results*	*Limitations*
Shi et al. [20]	95.3%	-very small Dataset -Extracted only spatial features. -Used only one type of feature extracted from one CNN.
Girum et al.[21]	80% (clinical parameters) 93.3% (DE-CMR)	- Limited generalizability to diverse datasets and real-world scenarios. - Dependency on clinical information availability and quality. - Potential interpretability and computational requirements challenges.
Ivantsits et al. [22]	96%	-very small Dataset -Extracted only spatial features. -Used only one type of feature extracted from the classical feature extraction method.
Lorenco et al. [23]	Clinic-NET : 85% DOC-NET : 95% DOC-NET+ :100% Clinic-NET+: 100%	-very small Dataset -Extracted only spatial features. -Used only one type of feature extracted from one CNN.
Rahman et al. [25]	Oversampling and Stacking: >97% Light Gradient and Boosting Machine: >96%.	- The results may not be applicable to other populations or diseases.
Attalah et al. [24]	Accuracy: 98% Sensitivity: 99% Specificity: 96% Precision: 96%	- Small training/validation samples that are not sufficient for deep learning of many hyperparameters.

All the studies faced challenges related to employing a relatively small dataset and the inability to cross-reference their methods with various datasets. These limitations underscored the necessity for additional validation. Encouraged by the remarkable performance exhibited by Lourenço et al.'s DOC-NET+ model, which achieved a flawless 100% accuracy in the EMIDEC challenge, we have opted to integrate this approach into our investigation. However, to ensure a precise alignment of the model with our research objectives, we have proactively taken steps to curate a tailored database. The following paragraph will provide in-depth insights into this database, explaining its construction process and relevance to our study pursuits.

3. Material and Methods

3.1. Database of interest

Through a fruitful collaboration with the Military Hospital of Tunis, we have successfully created a comprehensive and invaluable database of cardiac imaging. Our meticulous collection process utilized a 1.5T General Electric (GE) MRI Scanner, ensuring the acquisition of consistently high-quality images.

To capture a wide range of cardiac assessment aspects, we employed a variety of customized imaging techniques. Cine sequence images were collected across multiple planes, including long and short axis views, enabling a dynamic assessment of heart activity and accurate measurement of ventricular volumes. This approach allows for reliable monitoring of ventricular parameters and real-time observation of the heart's movement. Parameters were carefully considered to optimize both temporal and spatial resolution, as well as image contrast and clarity. The settings used were as follows: repetition time (TR) of 3.4 ms, echo time (TE) of 1.3 ms, flip angle (FA) of 50º, Field of View (FOV) ranging from 320-340 mm, matrix size of 256x144, and slice thickness of 8 mm.

Assessing the properties of the myocardium is of paramount importance in detecting, enhancing visibility, and understanding cardiac diseases. In our dataset, we employed two advanced techniques: phase-sensitive inversion recovery (PSIR) and late gadolinium enhancement (LGE). PSIR leverages the phase information of the acquired images to enhance visibility and improve scar tissue detection. LGE, on the other hand, requires the administration of a gadolinium-based contrast agent (Dotarem 0.2 mmol/kg body weight) and the acquisition of images using an inversion-recovery gradient-echo approach. This method reveals specific locations in the heart where the contrast agent accumulates selectively, offering crucial diagnostic insights into the number and distribution of tissue defects.

The inversion time (TI) was carefully and repeatedly adjusted to precisely nullify the myocardium, enabling optimal visualization of enhanced areas. This recurrent approach guarantees accurate capture of contrast uptake and dispersion, increasing the dataset's diagnostic value. The imaging parameters used for LGE imaging were as follows: TR = 10.5 ms, TE = 5.4 ms, FA of 30°, FOV of 350x262 mm², a matrix size of 256x162, a slice thickness of 6 mm, a receiver bandwidth (BW) of 140 Hz/px, and a GRAPPA acceleration factor of 2.

Our dataset is exceptionally rich, encompassing a diverse range of cases, including various forms and

manifestations of myocarditis and MI. These conditions present themselves in different stages and patterns, adding complexity and interest. Additionally, we have obtained longitudinal follow-up data for select patients, allowing for detailed observation and analysis of disease progression or stability over time. The diverse nature and complexity of the included cases make our dataset ideal for training and evaluating machine learning models. Exposure to a wide spectrum of scenarios enhances the model's ability to learn and generalize. Samples from our database are depicted in Figure 1, illustrating the contrast enhancement (blue arrow).

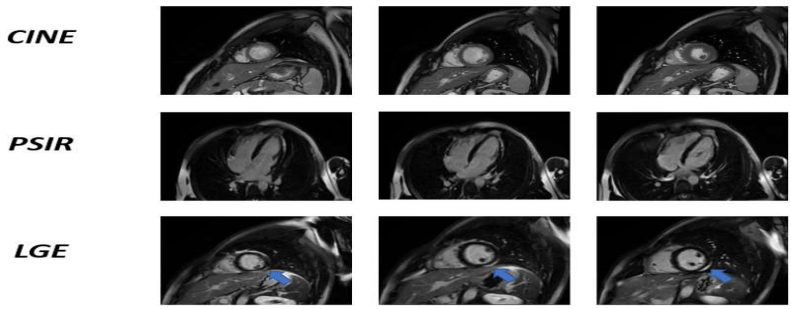

Fig. 1. Cine, PSIR and LGE samples for a 24 YO Pathological male subject.

3.2. DOC-NET and DOC-NET+

In our research, we were inspired by the architecture proposed by Lourenço et al. [23], which goes by the names DOC-NET and its enhanced successor DOC-NET+. These two DL neural networks were designed to capitalize on the potential of patient clinical data and DE-CMR images for the automated prediction of myocardial illnesses.

DOC-NET is an amalgamation of features extracted from DE-CMR images and metadata, resulting in a robust classification framework. Its image feature extraction design encompasses seven distinct layers: beginning with 3D convolutions employing 3x3x3 kernels and a stride of 2, spanning various channel counts (4, 8, 16, 32, 64, 16, 8). The subsequent layers incorporate instance layer-normalization, a 20% dropout probability, and the Parametric Rectified Linear Unit (PReLU) activation. The resultant image feature vector is flattened into an 8-element array and seamlessly combined with a 12-variable metadata set. This combined vector serves as the input to a fully connected neural network akin to Clinic-Net. The sizes of the three fully connected layers within DOC-NET are meticulously adjusted to match the updated input size: fc1 = 33, fc2 = 50, and fc3 = 16.
Evolved from its precursor, DOC-NET+, emerges as an upgraded version enriched with insights from DE-CMR. These insights are manifested as volumetric representations of segmentation labels, derived from meticulous manual segmentations or an innovative segmentation neural network.

4. Results and Discussion

In our classification task, we have chosen to adopt the DOC-NET+ architecture based on the exceptional performance reported by Lourenço et al. in the EMIDEC challenge [23]. To ensure a rigorous result, we have replicated the conditions of the challenge, using the same image numbers and patient distribution as the original dataset (normal patients is 33 and patients pathological is 67).

Table 2 contains the comprehensive findings of the accuracy rates achieved by both configurations. Furthermore, we will present a detailed comparison of our results with the EMIDEC database outcomes, providing for a better understanding of the effectiveness and generalizability of those protocols.

TABLE II. COMPARATIVE TABLE .

Protocol	**Accuracy (same image number and patient distribution)**	
	EMIDEC dataset	***Our new Dataset***
DOC-NET	95%	97%

Protocol	Accuracy (same image number and patient distribution)	
	EMIDEC dataset	***Our new Dataset***
DOC-NET+	100%	98%
Accuracy (Increasing patients' number and images)		
DOC-NET+	---	91%

The deployment of both the DOC-NET and DOC-NET+ layouts in our study initially produced outstanding results, highlighting their potential for precise classification. DOC-NET achieved a commendable 97% accuracy. This achievement was largely due to our initial focus on typical myocarditis and MI images, which the model found reasonably easy to learn and categorize consistently. However, as our dataset expanded to encompass a greater number of patients and a diverse array of diseases in various forms and stages, the model's accuracy encountered challenges. The accuracy diminished to 91% as the dataset complexity increased. This decline highlights the influence of dataset characteristics on the model's ability to generalize effectively. To delve further into the factors contributing to this decrease in performance, we identified specific instances where the model struggled to correctly identify pathology. By analyzing these cases, we aim to gain insights into limitations and potential weaknesses when dealing with challenging scenarios. In the upcoming **Figure 2**, we will provide a comprehensive overview of these complex cases, offering visual examples and discussing potential reasons for misclassification.

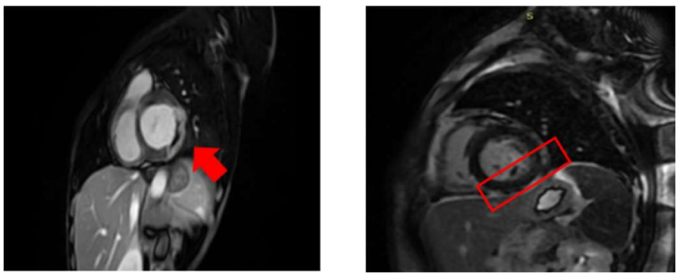

(a) (b)

Fig. 2. New Database examples of misclassified images.

When patients exhibit multiple disorders simultaneously, the model often faces difficulties and a potential reduction in accuracy. This may stem from the model's limitations in distinguishing and precisely identifying conditions that overlap or coexist.

For example, in the case of one patient (a), the LGE images displayed a contrast pattern suggestive of ischemic cardiomyopathy (IDM) (indicated by the red arrow). However, it remains uncertain why the model failed to accurately predict this condition in that specific instance. The presence of a confounding factor, such as no reflow, could conceivably influence the model's predictions, and contribute to the observed discrepancy.

Furthermore, the model's struggle to accurately predict the specific image could also be attributed to the intricate and variable nature of the myocarditis pattern. Myocarditis often presents a multifocal distribution, which poses a challenging task for the model's classification capabilities, as evidenced in case (b).

5. Conclusion

Finally, this study undertook a complete examination of the EMIDEC Challenge's state-of-the-art. We developed a large database of CMR images using a 1.5T GE MRI scanner, which allowed us to gain deep insights into heart tissue and irregularities. Implementing advanced DOC-NET and DOC-NET+ architectures, we achieved promising classification results. DOC-NET reached 97% accuracy on our new dataset, while DOC-NET+ achieved 98%.

However, with the inclusion of more complex cases, DOC-NET+'s accuracy decreased to 91%. Our analysis of misclassified images highlighted limitations, especially in complex cases.

Future work will focus on refining algorithms to handle diverse data sources and incorporating additional heart function parameters for improved predictions. We'll also explore more sensitive parametric approaches for enhanced cardiac issue forecasting.

References

[1] Tsao, Connie W., et al. "Heart disease and stroke statistics—2023 update: a report from the American Heart Association." *Circulation* 147.8 (2023): e93-e621.

[2] Aretz, H T et al. "Myocarditis. A histopathologic definition and classification." *The American journal of cardiovascular pathology* vol. 1,1 (1987): 3-14.

[3] Niazi, Sana, et al. "The Cardiac effects of COVID-19: review of articles." *Current Problems in Cardiology* 47.2 (2022): 100981.

[4] Sozzi, Fabiola B., et al. "Viral myocarditis: classification, diagnosis, and clinical implications." *Frontiers in Cardiovascular Medicine* 9 (2022): 908663.

[5] Sandoval, Yader, Kristian Thygesen, and Allan S. Jaffe. "The universal definition of myocardial infarction: present and future." *Circulation* 141.18 (2020): 1434-1436.

[6] Ahmed, Talha. and Amandeep Goyal. "Endomyocardial Biopsy." *StatPearls*, StatPearls Publishing, 8 May 2023.

[7] Caforio, Alida LP, et al. "Current state of knowledge on aetiology, diagnosis, management, and therapy of myocarditis: a position statement of the European Society of Cardiology Working Group on Myocardial and Pericardial Diseases." *European heart journal* 34.33 (2013): 2636-2648.

[8] Jeserich, Michael, et al. "Non-invasive imaging in the diagnosis of acute viral myocarditis." *Clinical research in cardiology* 98 (2009): 753-763.

[9] Morgera, Tullio, et al. "Electrocardiography of myocarditis revisited: clinical and prognostic significance of electrocardiographic changes." *American heart journal* 124.2 (1992): 455-467.

[10]

[11] Miklozek, Candace L., et al. "Myocarditis presenting as acute myocardial infarction." *American heart journal* 115.4 (1988): 768-776.

[12] Ferreira, Vanessa M., et al. "Cardiovascular magnetic resonance in nonischemic myocardial inflammation: expert recommendations." *Journal of the American College of Cardiology* 72.24 (2018): 3158-3176.

[13] Friedrich, Matthias G., et al. "Cardiovascular magnetic resonance in myocarditis: a JACC white paper." *Journal of the American College of Cardiology* 53.17 (2009): 1475-1487.

[14] Pan, Jonathan A., Yoo Jin Lee, and Michael Salerno. "Diagnostic performance of extracellular volume, native T1, and T2 mapping versus Lake Louise criteria by cardiac magnetic resonance for detection of acute myocarditis: a meta-analysis." *Circulation: Cardiovascular Imaging* 11.7 (2018): e007598.

[15] Aquaro, Giovanni Donato, et al. "Diagnostic and prognostic role of late gadolinium enhancement in cardiomyopathies." *European Heart Journal Supplements* 25.Supplement_C (2023): C130-C136.

[16] Camastra, Giovanni S., et al. "Late enhancement detected by cardiac magnetic resonance imaging in acute myocarditis mimicking acute myocardial infarction: location patterns and lack of correlation with systolic function." *Journal of Cardiovascular Medicine* 8.12 (2007): 1029-1033.

[17] Vermes, Emmanuelle, et al. "Patterns of myocardial late enhancement: typical and atypical features." *Archives of cardiovascular diseases* 105.5 (2012): 300-308.

[18] Lalande, Alain, et al. "Emidec: a database usable for the automatic evaluation of myocardial infarction from delayed-enhancement cardiac MRI." *Data* 5.4 (2020): 89.

[19] Nakamura, Tomofumi, and Tetsuo Sasano. "Artificial intelligence and cardiology: Current status and perspective." *Journal of Cardiology* 79.3 (2022): 326-333.

[20] Shi, Jixi, Zhihao Chen, and Raphaël Couturier. "Classification of pathological cases of myocardial infarction using convolutional neural network and random forest." *Statistical Atlases and Computational Models of the Heart. M&Ms and EMIDEC Challenges: 11th International Workshop, STACOM 2020, Held in Conjunction with MICCAI 2020, Lima, Peru, October 4, 2020, Revised Selected Papers 11*. Springer International Publishing, 2021.

[21] Girum, Kibrom Berihu, et al. "Automatic myocardial infarction evaluation from delayed-enhancement cardiac MRI using deep convolutional networks." *Statistical Atlases and Computational Models of the Heart. M&Ms and EMIDEC Challenges: 11th International Workshop, STACOM 2020, Held in Conjunction with MICCAI 2020, Lima, Peru, October 4, 2020, Revised Selected Papers 11*. Springer International Publishing, 2021.

[22] Ivantsits, Matthias, et al. "Deep-learning-based myocardial pathology detection." *Statistical Atlases and Computational Models of the Heart. M&Ms and EMIDEC Challenges: 11th International Workshop, STACOM 2020, Held in Conjunction with MICCAI 2020, Lima, Peru, October 4, 2020, Revised Selected Papers 11*. Springer International Publishing, 2021.

[23] Lourenço, Ana, et al. "Automatic myocardial disease prediction from delayed-enhancement cardiac MRI and clinical information." *Statistical Atlases and Computational Models of the Heart. M&Ms and EMIDEC Challenges: 11th International Workshop, STACOM 2020, Held in Conjunction with MICCAI 2020, Lima, Peru, October 4, 2020, Revised Selected Papers 11*. Springer International Publishing, 2021.

[24] Attallah, Omneya, and Dina A. Ragab. "Auto-MyIn: Automatic diagnosis of myocardial infarction via multiple GLCMs, CNNs, and SVMs." *Biomedical Signal Processing and Control* 80 (2023): 104273.

[25] Rahman, Sheikh Shah Mohammad Motiur, et al. "Automatic classification of patients with myocardial infarction or myocarditis based only on clinical data: A quick response." *Plos one* 18.5 (2023): e0285165.