



HAL
open science

A Robustness Study of Machine Learning Based Methods for Macula Detection in Pathological Fundus Images

Yaroub Elloumi, Rostom Kachouri

► **To cite this version:**

Yaroub Elloumi, Rostom Kachouri. A Robustness Study of Machine Learning Based Methods for Macula Detection in Pathological Fundus Images. 2023 Twelfth International Conference on Image Processing Theory, Tools and Applications (IPTA), Oct 2023, Paris, France. 10.1109/IPTA59101.2023.10320012 . hal-04451216

HAL Id: hal-04451216

<https://hal.science/hal-04451216>

Submitted on 11 Feb 2024

HAL is a multi-disciplinary open access archive for the deposit and dissemination of scientific research documents, whether they are published or not. The documents may come from teaching and research institutions in France or abroad, or from public or private research centers.

L'archive ouverte pluridisciplinaire **HAL**, est destinée au dépôt et à la diffusion de documents scientifiques de niveau recherche, publiés ou non, émanant des établissements d'enseignement et de recherche français ou étrangers, des laboratoires publics ou privés.

A Robustness Study of Machine Learning Based Methods for Macula Detection in Pathological Fundus Images

Yaroub Elloumi
Medical Technology and Image Processing
Laboratory
ISITCom Hammam-Sousse, University
of Sousse, Tunisia
yaroub.elloumi@esiee.fr

Rostom Kachouri
Gaspard Monge Computer Science
Laboratory, ESIEE-Paris, Gustave
Eiffel University, France
rostom.kachouri@esiee.fr

Abstract—: The macula detection is an important step for screening retinal diseases. Several methods have been proposed for detecting macula, with the aim of achieving a higher detection performance despite retinal pathologies. Their processing principles are based on well-known anatomical criteria of macula. However, these criteria are subject to significant changes caused by various eye pathologies. Therefore, it leads to a non-performing macula detection, and hence pathology screening. The objective of this work is to study the robustness of the macula detection methods in terms of retinal pathologies. For this purpose, the main macular criteria are extracted. Then, recent macula detection methods are detailed where the macula criteria taken into account are identified. Thereafter, the retinal pathologies that affect the macula are listed where caused macula changes are figured out. This study allows us to synthesise the robustness of each method in terms of pathologies.

Keywords— Macula, Fundus image, Macular pathologies, Machine Learning.

I. INTRODUCTION

Fundus examination is a valuable tool in screening several retinal diseases, such as hypertensive retinopathy and cardiovascular diseases [1]. The fundus image allows modelling the internal side of the retina which is composed by a macula, an Optic Disc (OD) and a vessel tree. The macula is responsible for clear, sharp and detailed vision [2], where its center is called the fovea. The macula is characterized by a circularity, darkness with respect to other retinal components, and a lack of vessels. Several methods of locating the macula have been proposed in the literature. The aim of these methods is the efficient detection of the macula from healthy and pathological images. They differ in terms of addressed macula characteristics. Several recent methods have succeeded to achieve high detection performances. Several studies have been proposed concerning the macula detection methods [3, 4], which are interested in classifying methods in terms of processing principles.

However, several pathologies may affect the macula and involves changing its characteristics such as increasing its intensity in the case of Macular Hole (MH) or Diabetic Macular Edema (DME), altering its circularity as in Age-related Macular Degeneration (AMD) or Retinal Venous Occlusion (RVO), or adding vessel as in Proliferative Diabetic Retinopathy (PDR) [5]. Knowing that they are based on macula characteristics their performances may degrade with respect to the affected pathologies. The objective of this work is to carry out a comparative study of macula detection methods and evaluate the robustness of macula

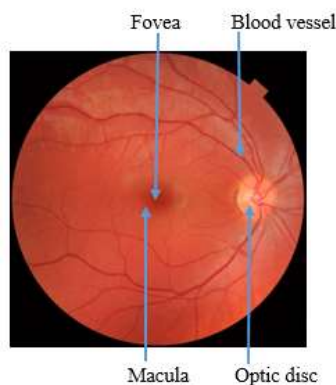


Fig. 1. The components of the eye fundus.

detection in terms of pathologies. The remaining sections of this paper are organized as follows. In section 2, we describe the characteristics of the macula. The section 3 is dedicated for detailing the main pathologies that affect the macula region. We describe recent macula detection methods in section 4. In section 5, we study the robustness of the macula detection in relation to pathologies. Finally, we conclude and suggest perspectives in section 6.

II. MORPHOLOGICAL CHARACTERISTICS OF THE MACULA

The macula is the central area of the retina. It is responsible for central vision [6] and it plays an essential role in the precision of gestures and activities. The macula has main characteristics which are:

- **Circularity:** the macula is the central circular area ([6]) of the retina. The macula center has a small depression called the fovea.
- **Intensity:** the ‘ganglion cell Layer’ becomes thinner until disappearing in the fovea. Therefore, the macula appears as the darkest region [6] compared to other components of the retina with degradation in intensity until reaching the fovea, as shown in the fundus image of Figure 2(A) and the OCT in Figure 3 [7].
- **Lack of vessels inside:** the macula is an area devoid of retinal vessels [8]. Figure 2(B) shows a segmentation of the retinal vessels which are lacking in the central macular zone, called central avascular zone.
- **Elliptic form of main vessels around:** the macula diameter is between 3 to 4 mm where the OD to fovea distance is equal to 2.5 times the OD diameter [6]. the macula is positioned in the center of the elliptic form of main vessels [9].

This work was supported by the PHC-Maghreb 48672RG Research program.

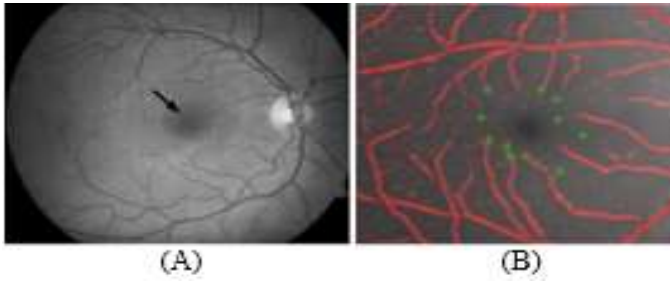


Fig. 2. the characteristics of the macula: (A) Circularity / intensity and Elliptic form of main vessels around, (B) lack of vessels inside.

III. MACULAR PATHOLOGIES

In this section, we detail the main ocular pathologies affecting the macula, where we focus on AMD, RVO, MH, DR and DME.

A. Age-related Macular Degeneration (AMD)

The AMD is a chronic, progressive and disabling degenerative retinal disease. It affects the macula causing degeneration of visual retinal cells (yellow spots on the retina). It affects elderly people after 50 where 30 million people worldwide have AMD. The dry AMD form implies adding high intensity lesions called drusens as illustrated in figure 3.(a), where wet AMD brings to adding new abnormal retinal vessels in the macular region, called choroidal neovessels as shown in the fundus image of figure 3.(b) [10].

B. Macular Hole (MH)

The MH causes a tear in macular tissue. It affects three in every thousand elderly people worldwide. This disease causes a distorted perception of central vision (scotoma) or an area of blurred vision in the center of the visual field. This pathology gives the possibility for the appearance of new dark areas. There are two main successive stages of MH: the lamellar MH affects only certain layers of the retina and are less dangerous for vision [11]; the full-thickness MH affects all retinal layers and causes significant loss of vision as shown in figure 3.(c) [12].

C. Diabetic Retinopathy (DR)

The DR reaches people who have diabetes for several years, where 93 million people worldwide are affected. The Non Proliferative DR stage causes lesions close to the main vessels as illustrated in figure 3.(d). The proliferative DR stage leads to adding new abnormal blood vessels in the whole retina, and particularly in the macula as shown in figure 3.(e).

D. Retinal Venous Occlusion (RVO)

The RVO is the second most common cause of retinal vascular disease, after the DR. It corresponds to a slowdown in the venous circulation of the retina, hence suffering the retinal cells from lack of oxygen. The RVO begins after the age of 60 and reaches 16.4 million worldwide. The first RVO stage affects the central vein of the retina. It is characterised by the presence of small hemorrhages next to the blood vessels as shown in figure 3.(f). The second stage leads to a circulatory disorder that affects all retinal venous drainage. It is characterized by severe tortuosity and dilatation of all branches of the central retinal vein as illustrated in figure 3.(g) [13].

E. Diabetic Macular Edema (DME)

The DME is caused by a thickening of the macular region due to the buildup of blood and fluid in the macula. The DME begins after age 50 and reaches 21 million worldwide. It is a common cause of progressive vision loss among diabetic patients which can lead to blindness. It causes bright lesions in the macular region. Between the two stages of DME, the difference relies on the distance between the fovea and the lesions [14], which is below two times the diameter of OD in the case of the severe stage, as illustrated in figure 3.(h).

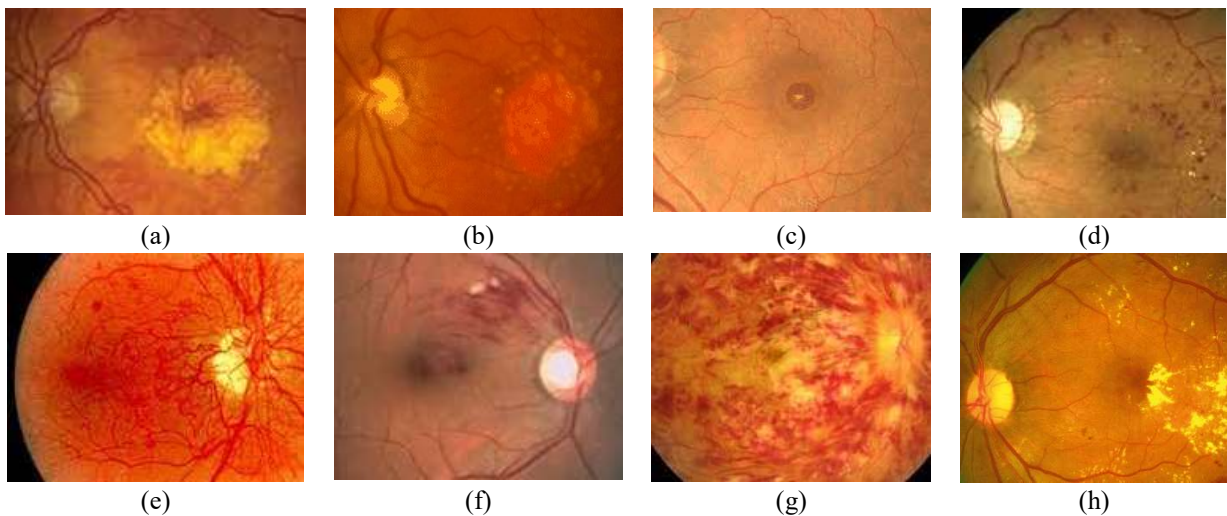


Fig. 3. The DME is caused by a thickening of the macular region due to the buildup of blood and fluid in the macula. The DME begins after age 50 and Pathological fundus images: (a) Dry AMD; (b) Wet AMD; (c) MH; (d) non-proliferative DR; (e) proliferative DR; (f) Branch RVO; (g) central RVO; (h) DMLA.

TABLE I. CHANGES EFFECTED BY PATHOLOGIES ON THE MACULA

Morphological characteristic	AMD	RVO	MH	DME	DR
Circularity	X		X	X	
Intensity	X	X	X	X	
Inside lack of vessels	X	X			X
Relative main vessels Position					

F. Impact of Macular Pathologies on the Morphological Characteristics of the Macula

The detection of the macular region plays an important role in the detection of pathologies. It is therefore very important to identify this region with great precision. The higher intensity of drusens and exudates caused by AMD and DME, respectively, and the dark texture of MH involves altering the intensity distribution of the macula. Furthermore, the drusens involved by AMD or the hard exudates of the DME or MH tear, involves modifying the circular border of the macula. In addition, the new abnormal retinal vessels in the macula involve changing the criteria of the lack of vessels in the macular region. However, based on the anatomy of the retina, there is no pathology that affects the size of the macula and repositions it in relation to other components. The changes in the characteristics affected by the pathologies are shown in Table 1.

IV. RELATED WORKS: SYNTHESIS OF MACULAR LOCATION METHODS

The public databases available online which are MESSIDOR, DRIVE, DIARETDB1 and HEIMED are the most used to evaluate macula detection methods. The majority of DBs contain DR affected images and Some of them contain AMD affected images. However, no one contains images including MH or RVO pathologies. Table 2 characterizes the pathologies contained in the DBs. We deduce that the works detailed in [6], [15] and [16] achieve better performance when using MESSIDOR rather than using DIARETDB1 which contains more pathological images. According to the detection metrics illustrated in table 1, the intensity based methods are always performed in reduced execution times compared to other ones.

The morphological characteristics of the macula (e.g. circularity, intensity, absence of vessels, position relative to the retina center, distance from the OD and relative position to vascular structure) have been explored by macula localization methods [17], [18]. In the work proposed by AKRAM et al. [19], intensity is used to identify dark regions from the retinal texture. Then, a classification based on the "Gaussian mixture model" (GMM) algorithm is applied to classify candidate regions as macular or non-macular. Similarly, intensity is used to segment the macula and identify the fovea in the method proposed by [19] et al [20] and Kumar et al [21]. The intensity feature is combined with the fovea - OD distance in the methods proposed by Kamble et al. [22], Singh et al. [23] and Rahim et al. [24]. In Aquino's work [6], circularity and the retinal axis are used to segment the fovea. Then, the robustness of the method is improved by using the avascular feature and the fovea-DO distance feature in the case of the presence of several lesions in the macular zone.

TABLE II. PATHOLOGIES CONTAINED IN DB

Pathology DB	AMD	RVO	Macular hole	DME	DR
E-OPHTHA	-	-	-	X	X
ARIA	X	-	-	-	-
MESSIDOR	-	-	-	X	X
HEIMED	-	-	-	X	-
DIARETDB0	-	-	-	X	X
DIARETDB1	-	-	-	-	X
DRIVE	-	-	-	-	X
STARE	X	-	-	-	X
HRF	-	-	-	-	X
KAGGLE	-	-	-	-	X

In the work developed by MEDHI and DANDAPAT [25], vessel intensity and absence characteristics are used, to detect and then to eliminate the OD, fundus lesions, and then to locate the macula center. The work of MUBBASHAR and AKRAM [26] explored the retinal axis, the vascular tree, the OD-fovea distance, and circularity for macula detection.

Alan D Fleming et al [27] detect the main vessels, then use the elliptical shape to locate the OD. Subsequently, the intensity and OD-fovea distance are explored to detect the macular zone. Li and Chutatape et al. [28] used the "modified active shape model" [29] for vessel segmentation. Subsequently, the position of the macula is obtained by fitting he parabolic model to the geometric distance.

Tobin et al [30] have proposed a method for localizing the fovea based on morphological features of the macula such as position relative to the vascular structure and distance from the OD. The method starts with the segmentation of the vascular structure using the method proposed in [31]. Subsequently, a parabolic model is used to extract the macula area encompassed by the main vessels. The location of the fovea is finally deduced as a function of distance from the OD. In work [32], the authors proposed a method consisting in segmenting the retinal blood vessel structure and fitting it with a parabolic model, with the aim of locating the fovea in the image as the vertex of this parabolic curve. Table 3 summarizes the characteristics and details of the above-mentioned works.

V. DISCUSSION

Accordingly, the validation of macula location method should be based on the three anatomical criteria at the same time, where it has been demonstrated that the use of one or two characteristics does not guarantee an efficient detection of the macula. Moreover, the method evaluation should be performed using a DB containing all macular pathologies to guarantee its performance in the clinical context.

The morphological characteristics used by each method for the macula detection are cited in this table 1. Automated macula detection can play a major role in early detection of the disease. The earlier the disease is detected, the better the chances of saving eyesight. In recent years, much research has been published in this regard. In the literature, most of the methods use the color characteristic. To achieve an efficient location of the macula despite the macular pathologies, the method should take into account the eventual changes caused by the pathologies to the features of the macula.

TABLE III. LITERATURE REVIEW ON MACULAR LOCATION METHODS

Work	Morphological characteristic of the macula					Databases (N° of images)	accuracy	Processing principles
	Circularity	Intensity	Lack of vessels inside	Position with respect to the	Main vessels Position			
Akram et al.[18]		X		X		MESSIDOR (1200) HEIMED (169)	98.4% 95.2%	Adaptative thresholding
et al. [19]		X				DIARETDB0 (130) DIARETDB1 (89) HEIMED (169)	96.92% 97.75% 98.81%	Clustering
Kumar et al. [21]		X				MESSIDOR (1200)	96%	Top hat filtering
Kamble et al. [22]		X		X		MESSIDOR (1200) HEIMED (169)	99.66% 99.4%	Digital wavelet transformation
Singh et al. [23]		X		X		NA	NA	Morphologic operators
Rahim et al., [24]		X		X		HRF (45) DIARETDB0(130) MESSIDOR(1200)	NA	Fuzzy Filtering Tophat filtering
Aquino et al. [6]	X		X	X		MESSIDOR (1136) DIARETDB1 (89)	98.24% 94.38%	Low pass filtering Invarying Moment charact.
Medhi et Dandapat [25]		X	X			DRIVE (37) DIARETDB1 (89)	100% 95.51	otsu thresholding Canny filtering Black top-Hat filtering
Medhi and Dandapat [33]		X	X			DIARETDB0(127) DIARETDB1(86) HRF (45) MESSIDOR (400)	96.85% 97.67% 100% 96.25%	Morphological operations Otsu's thresholding Black_tophat filtering
Deka et al.[34]					X	MESSIDOR (800) DIARETDB1 (89) STARE (50)	97.75% 95.5% 96%	Digital wavelet transformation Region-growing method
Alan D Fleming et al [27]		X		X		Local (1056) STARE (79)	96.5% 89.2%	Gradient filtering Hough Transformation Region growing method
Li et Chutatape et al. [28]				X	X	Local(35)	100%	Active form method linear least square
Kao et al.[32]		X	X			DIARETDB0 (130) DIARETDB1 (89) MESSIDOR (1200)	93.1% 92.1% 97.8%	Gaussian filtering
Tobin et al. [30]				X	X	Local (345)	92.5%	Convolution filtering Steerable filtering Hough Transformation
Chin et al [35]				X	X	MESSIDOR	80%	Wavelet transformation GMM classifier
Zheng et al. [36]		X	X			DRIVE HEI-MED DIARETDB1	100% 98.8% 93.3%	Morphological operators
J. H. Tan[37]		X				DRIVE (40)	92.68%	CNN with 7 layers
Y. Fu [38]				X	X	Kaggle (120) Messidor (100) IDRiD (516)	89.16% 97% 95.34%	Surface fitting Unet
L. Huang [39]		X				IDRiD (516) Messidor (1200)	97.8%	ResNet
Hasan et al [40]						IDRiD (516)	100%	DRNet

VI. CONCLUSION AND FUTURE WORK

Several works are proposed for the detection of the macula in fundus images. The challenge is to ensure a robust detection of the macula independently from ocular pathologies. The objective of this work is to study the robustness of the detection of the macula in relation to pathologies.

For this purpose, we identified the main macula characteristics. Then, we described the localization methods and the macular pathologies. Thereafter, the robustness method is discussed based on pathologies. This study allows to recommend future works to address all anatomical criteria of macula to achieve a higher location performance whatever the pathology is. Moreover, it is essential to propose Data Bases composed by images affected by all main macular pathologies to ensure a trustworthy evaluation.

REFERENCES

- [1] Digital ocular fundus imaging: a review. *Ophthalmologica*, 226(4), 161-181.
- [2] Akram, U., Jamal, I., & Tariq, A. (2012). Blood vessel enhancement and segmentation for screening of diabetic retinopathy. *TELKOMNIKA (Telecommunication Computing Electronics and Control)*, 10(2), 327-334.
- [3] Joshi, S., & Karule, P. T. (2017, June). Fundus image analysis for detection of fovea: A review. In 2017 International Conference on Intelligent Computing and Control (I2C2) (pp. 1-5). IEEE.
- [4] Veras, R., Medeiros, F., Silva, R., & Ushizima, D. (2013, July). Assessing the accuracy of macula detection methods in retinal images. In 2013 18th International Conference on Digital Signal Processing (DSP) (pp. 1-6). IEEE.
- [5] Wilkinson, C. P., Ferris III, F. L., Klein, R. E., ee, P. P., Agardh, C. D., Davis, M., ... & Group, G. D. R. P. (2003). Proposed international clinical diabetic retinopathy and diabetic macular edema disease severity scales. *Ophthalmology*, 110(9), 1677-1682.
- [6] Aquino, A. (2014). Establishing the macular grading grid by means of fovea centre detection using anatomical-based and visual-based features. *Computers in biology and medicine*, 55, 61-73.
- [7] Karadag, A. S., Kalenderoglu, A., & Orum, M. H. (2018). Optical coherence tomography findings in conversion disorder: are there any differences in the etiopathogenesis of subtypes?. *Archives of Clinical Psychiatry (São Paulo)*, 45(6), 154-160.
- [8] Fadzil, M. A., Izhar, L. I., & Nugroho, H. A. (2010). Determination of foveal avascular zone in diabetic retinopathy digital fundus images. *Computers in biology and medicine*, 40(7), 657-664.
- [9] Mubbashar, M., Usman, A., & Akram, M. U. (2011, July). Automated system for macula detection in digital retinal images. In 2011 International Conference on Information and Communication Technologies (pp. 1-5). IEEE.
- [10] Heesterbeek, T. J., Lechanteur, Y. T., Lorés-Motta, L., Schick, T., Daha, M. R., Altay, L., ... & de Jong, E. K. (2020). Complement Activation Levels Are Related to Disease Stage in AMD. *Investigative Ophthalmology & Visual Science*, 61(3), 18-18.
- [11] Hee, M. R., Puliafito, C. A., Wong, C., Duker, J. S., Reichel, E., Schuman, J. S., ... & Fujimoto, J. G. (1995). Optical coherence tomography of macular holes. *Ophthalmology*, 102(5), 748-756.
- [12] Gegundez-Arias, M. E., Marin, D., Bravo, J. M., & Suero, A. (2013). Locating the fovea center position in digital fundus images using thresholding and feature extraction techniques. *Computerized Medical Imaging and Graphics*, 37(5-6), 386-393.
- [13] Cugati, S., Wang, J. J., Knudtson, M. D., Rochtchina, E., Klein, R., Klein, B. E., ... & Mitchell, P. (2007). Retinal vein occlusion and vascular mortality: pooled data analysis of 2 population-based cohorts. *Ophthalmology*, 114(3), 520-524.
- [14] Mookiah, M. R. K., Acharya, U. R., Fujita, H., Tan, J. H., Chua, C. K., Bhandary, S. V., ... & Tong, L. (2015). Application of different imaging modalities for diagnosis of diabetic macular edema: a review. *Computers in biology and medicine*, 66, 295-315.
- [15] GeethaRamani, R., & Balasubramanian, L. (2018). Macula segmentation and fovea localization employing image processing and heuristic based clustering for automated retinal screening. *Computer methods and programs in biomedicine*, 160, 153-163.
- [16] Kao, E. F., Lin, P. C., Chou, M. C., Jaw, T. S., & Liu, G. C. (2014). Automated detection of fovea in fundus images based on vessel-free zone and adaptive Gaussian template. *Computer methods and programs in biomedicine*, 117(2), 92-103.
- [17] R. I.S., B. M. Arikerie, and B. M. Reshmi, "A review on automatic identification of fovea in retinal fundus images," *International Journal of Medical Engineering and Informatics*, vol. 12, no. 2, p. 169, 2020, doi: 10.1504/IJMEI.2020.106900.
- [18] S. Joshi and P. T. Karule, "Fundus image analysis for detection of fovea: A review," in 2017 International Conference on Intelligent Computing and Control (I2C2), Jun. 2017, pp. 1-5. doi: 10.1109/I2C2.2017.8321966.
- [19] M. U. Akram, A. Tariq, S. A. Khan, and M. Y. Javed, "Automated detection of exudates and macula for grading of diabetic macular edema," *Computer Methods and Programs in Biomedicine*, vol. 114, no. 2, pp. 141-152, Apr. 2014, doi: 10.1016/j.cmpb.2014.01.010.
- [20] G. R and L. Balasubramanian, "Macula segmentation and fovea localization employing image processing and heuristic based clustering for automated retinal screening," *Comput Methods Programs Biomed*, vol. 160, pp. 153-163, Jul. 2018, doi: 10.1016/j.cmpb.2018.03.020.
- [21] T. A. kumar, S. Priya, and V. Paul, "A Novel Approach to the Detection of Macula in Human Retinal Imagery," *IJSPS*, vol. 1, no. 1, pp. 23-28, 2013, doi: 10.12720/ijsp.1.1.23-28.
- [22] "Localization of optic disc and fovea in retinal images using intensity based line scanning analysis - ScienceDirect." <https://www.sciencedirect.com/science/article/abs/pii/S0010482517301130> (accessed May 31, 2022).
- [23] A. Singh, N. Sengar, A. Issac, and M. K. Dutta, "An automated imaging algorithm for macula detection in fundus images," in 2016 Ninth International Conference on Contemporary Computing (IC3), Aug. 2016, pp. 1-4. doi: 10.1109/IC3.2016.7880226.
- [24] S. S. Rahim, V. Palade, J. Shuttleworth, and C. Jayne, "Automatic screening and classification of diabetic retinopathy and maculopathy using fuzzy image processing," *Brain Inf.*, vol. 3, no. 4, pp. 249-267, Dec. 2016, doi: 10.1007/s40708-016-0045-3.
- [25] J. P. Medhi and S. Dandapat, "An effective fovea detection and automatic assessment of diabetic maculopathy in color fundus images," *Computers in Biology and Medicine*, vol. 74, pp. 30-44, Jul. 2016, doi: 10.1016/j.compbiomed.2016.04.007.
- [26] M. Mubbashar, A. Usman, and M. U. Akram, "Automated system for macula detection in digital retinal images," in 2011 International Conference on Information and Communication Technologies, Jul. 2011, pp. 1-5. doi: 10.1109/ICICT.2011.5983555.
- [27] A. D. Fleming, K. A. Goatman, S. Philip, J. A. Olson, and P. F. Sharp, "Automatic detection of retinal anatomy to assist diabetic retinopathy screening," *Phys. Med. Biol.*, vol. 52, no. 2, pp. 331-345, Dec. 2006, doi: 10.1088/0031-9155/52/2/002.
- [28] H. Li and O. Chutatape, "Automated feature extraction in color retinal images by a model based approach," *IEEE Transactions on Biomedical Engineering*, vol. 51, no. 2, pp. 246-254, Feb. 2004, doi: 10.1109/TBME.2003.820400.
- [29] T. F. Cootes, C. J. Taylor, D. H. Cooper, and J. Graham, "Active Shape Models-Their Training and Application," *Computer Vision and Image Understanding*, vol. 61, no. 1, pp. 38-59, Jan. 1995, doi: 10.1006/cviu.1995.1004.
- [30] K. W. Tobin, E. Chaum, V. P. Govindasamy, and T. P. Karnowski, "Detection of Anatomic Structures in Human Retinal Imagery," *IEEE Transactions on Medical Imaging*, vol. 26, no. 12, pp. 1729-1739, Dec. 2007, doi: 10.1109/TMI.2007.902801.
- [31] F. Zana and J.-C. Klein, "Segmentation of vessel-like patterns using mathematical morphology and curvature evaluation," *IEEE Transactions on Image Processing*, vol. 10, no. 7, pp. 1010-1019, Jul. 2001, doi: 10.1109/83.931095.
- [32] E.-F. Kao, P.-C. Lin, M.-C. Chou, T.-S. Jaw, and G.-C. Liu, "Automated detection of fovea in fundus images based on vessel-free zone and adaptive Gaussian template," *Computer Methods and Programs in Biomedicine*, vol. 117, no. 2, pp. 92-103, Nov. 2014, doi: 10.1016/j.cmpb.2014.08.003.

- [33] J. P. Medhi and S. Dandapat, "Automatic detection of fovea using property of vessel free region," in 2015 Twenty First National Conference on Communications (NCC), Feb. 2015, pp. 1–6. doi: 10.1109/NCC.2015.7084852.
- [34] D. Deka, J. P. Medhi, and S. R. Nirmala, "Detection of macula and fovea for disease analysis in color fundus images," in 2015 IEEE 2nd International Conference on Recent Trends in Information Systems (ReTIS), Jul. 2015, pp. 231–236. doi: 10.1109/ReTIS.2015.7232883.
- [35] K. S. Chin, E. Trucco, L. Tan, and P. J. Wilson, "Automatic fovea location in retinal images using anatomical priors and vessel density," *Pattern Recognition Letters*, vol. 34, no. 10, pp. 1152–1158, Jul. 2013, doi: 10.1016/j.patrec.2013.03.016.
- [36] S. Zheng, L. Pan, J. Chen, and L. Yu, "Automatic and efficient detection of the fovea center in retinal images," in 2014 7th International Conference on Biomedical Engineering and Informatics, Oct. 2014, pp. 145–150. doi: 10.1109/BMEI.2014.7002760.
- [37] J. H. Tan, U. R. Acharya, S. V. Bhandary, K. C. Chua, and S. Sivaprasad, "Segmentation of optic disc, fovea and retinal vasculature using a single convolutional neural network," *Journal of Computational Science*, vol. 20, pp. 70–79, May 2017, doi: 10.1016/j.jocs.2017.02.006.
- [38] Y. Fu, G. Zhang, J. Li, D. Pan, Y. Wang, and D. Zhang, "Fovea localization by blood vessel vector in abnormal fundus images," *Pattern Recognition*, vol. 129, p. 108711, Sep. 2022, doi: 10.1016/j.patcog.2022.108711.
- [39] L. Huang, H. Lei, W. Liu, Z. Li, H. Xie, and B. Lei, "End-to-End Multi-task Learning Regression Network for Fovea Localization in Fundus Images," in 2022 IEEE 35th International Symposium on Computer-Based Medical Systems (CBMS), Jul. 2022, pp. 389–393. doi: 10.1109/CBMS55023.2022.00076.
- [40] Md. K. Hasan, Md. A. Alam, Md. T. E. Elahi, S. Roy, and R. Marti, "DRNet: Segmentation and localization of optic disc and Fovea from diabetic retinopathy image," *Artificial Intelligence in Medicine*, vol. 111, p. 102001, Jan. 2021, doi: 10.1016/j.artmed.2020.102001.