



HAL
open science

Long-term follow-up of a LPC animal model using Optimal control MRI contrast targeting short T2 components

Claire Lemoine, Thomas Grenier, Eric van Reeth van Reeth, Hoai-Thu Nguyen, Benoît Vernier, Sophie Gaillard, Olivier Beuf, Durand Dubief, Fabien Chauveau, Helene Ratiney

► To cite this version:

Claire Lemoine, Thomas Grenier, Eric van Reeth van Reeth, Hoai-Thu Nguyen, Benoît Vernier, et al.. Long-term follow-up of a LPC animal model using Optimal control MRI contrast targeting short T2 components. ESMRMB 2023, Oct 2023, Basel, Switzerland. hal-04446089

HAL Id: hal-04446089

<https://hal.science/hal-04446089v1>

Submitted on 8 Feb 2024

HAL is a multi-disciplinary open access archive for the deposit and dissemination of scientific research documents, whether they are published or not. The documents may come from teaching and research institutions in France or abroad, or from public or private research centers.

L'archive ouverte pluridisciplinaire **HAL**, est destinée au dépôt et à la diffusion de documents scientifiques de niveau recherche, publiés ou non, émanant des établissements d'enseignement et de recherche français ou étrangers, des laboratoires publics ou privés.

Long-term follow-up of a LPC animal model using Optimal control MRI contrast targeting short T2 components

Claire Lemoine(1), Thomas Grenier (1), Eric Van-Reeth (1), Hoai-Thu Nguyen (1), Benoit Vernier (1), Sophie Gaillard(1), Olivier Beuf(1), Françoise Durand Dubief (1), Fabien Chauveau(2), H  l  ne Ratiney(1)

1. Univ Lyon, INSA-Lyon, Universit   Claude Bernard Lyon 1, UJM-Saint Etienne, CNRS, Inserm, CREATIS UMR 5220, U1294, F -69100, LYON, France
2. Centre de Recherche en Neurosciences de Lyon Inserm U1028, CNRS UMR5292, F-69677, LYON, France

Introduction

This work studies, in a Multiple Sclerosis animal model with focal lesion, the behavior over time of a MRI contrast obtained with an optimized magnetization preparation designed with optimal control to obtain a hyperintensity signal from short T2 components which are associated with myelin. An advanced image analysis pipeline was developed to analyze this MRI contrast data and to compare it with histological myelin assessment.

Methods

Animal Model

A total of 24 animals (adult female Sprague-Dawley rats) were used. Demyelination was induced in the right Corpus Callosum (CC) by stereotactically injecting 4 μ l of 1% lysophosphatidylcholine (LPC) dissolved in saline [6]. This model produces controlled, focal demyelinating lesions. The rats were then scanned four times over the course of six months.

MRI acquisition and histological analysis

MRI acquisitions were performed on an 11.7T horizontal MRI system (Bruker Biospin MRI GmbH). In this study, 2 MRI contrasts were obtained according to the following sequences: 1) a T2-weighted axial sequence (RARE: TR/TE=5500/64ms, RARE factor=8) noted T2w in the following. 2) a signal enhancement sequence of short T2 components obtained with optimized magnetization preparation pulses in front of a fast gradient echo sequence (MPRAGE)[5] (noted as OC). The magnetization preparation consisted in (90  ) - (8.5ms) - (180  ) - (8.5ms) - (-90  ) - (646ms) - - which resulted in an optimized T2Prep-inversion recovery. (fig. 1).

These 2 contrast images were acquired with the same field of view, slice thickness and resolution (8 slices of thickness 0.75 mm, resolution in the plane of 117 μ m x 117 μ m). 23 rats were sacrificed at various time points ranging from 50 days to 200 days after injection.

Subsequently, histological analysis was performed using Sudan Black B (SBB) staining to quantify myelin content.

Image Analysis (see fig. 2)

1. Preprocessing

Preprocessing steps applied prior to image analysis consisted of 1) brain mask extraction using a template rat image, [2]. 2) bias artefact suppression using the N4 algorithm [3]. 3) co-registration in a longitudinal way on the template rat.

2. CC Segmentation and tessellation: CC were segmented using a UNet model [4]. Data augmentation was used to improve the generalization robustness.

To precisely analyse intensities in the CC, UNet masks were tessellated into 12 regions (see fig. 2).

3. In order to conduct an analysis of intensities over time longitudinal normalization was performed using healthy contra-lateral regions of the CC as a reference for intensity values and applying an intensity harmonization process to both T2-weighted and optical coherence images.

4. Histology image processing we manually selected the 2 slices that best matched the region of interest identified, on T2w, using anterior commissure as landmarks. These 2 slices were then registered on MRI with a rigid registration followed with a deformable one. The CC tessellation of MRI T2w images were then used to obtain the CC tessellation on the histological slices.

Results

For the majority of the rats (13/24) the volume of the ipsilateral corpus callosum measured on OC images was decreasing over time (-1% to - 8%) whereas the volumes of the contralateral either remain within 2% of variation or slightly increasing (from up to 4%) over time.

When considering mean and standard deviation of the signal intensity of each parcel for every acquisition, OC contrast provides a more informative analysis compared to T2 where all acquisitions have same low values. The middle part of Figure 1 shows two of these representations. For the majority (19/24) the intensity was decreasing between first and last acquisition on the injured CC. The OC contrast appears to be responsive to changes in the myelin content of the corpus callosum over time.

Figure 3 shows profiles and CC thickness measurement on registered in vivo and ex vivo images. The observations indicate that, when it comes to the thickness of the corpus callosum (CC), there is a higher degree of similarity between histology and T2) imaging compared to OC imaging.

Conclusion

Optimal control MRI contrast dedicated to myelin enhancement appear to reveal interesting sensitivity to myelin evolution compared to T2w in a MS model. However, at first sight T2w offer more similarity with *ex vivo* reality than optimal control images. In this LPC rat model, if remyelination occurred, it happened in the first month, afterwards a slight deterioration of the myelin and loss of volume of the corpus callosum was observed (without the rats showing any disabling clinical signs). Histological images still reveal deteriorated CC on the injured side.

Reference:

- [1] Khodanovich et al. ,Scientific Report, 2017
- [2] Klein S.et al. ,IEEE TMI, 2010
- [3] Tustison N.J., et al. IEEE TMI, 2010
- [4] Ronneberger O. et al., MICCAI, 2015
- [5] Vernier B., et al. IEEE ISBI, 2021
- [6] Zhang M.,et al. Contrast Media Mol Imaging, 2019

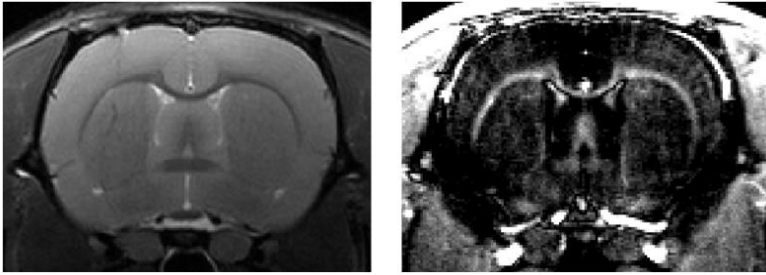


Figure 1: left T2w RARE image , right OC contrast image enhancing signal of short T2 components

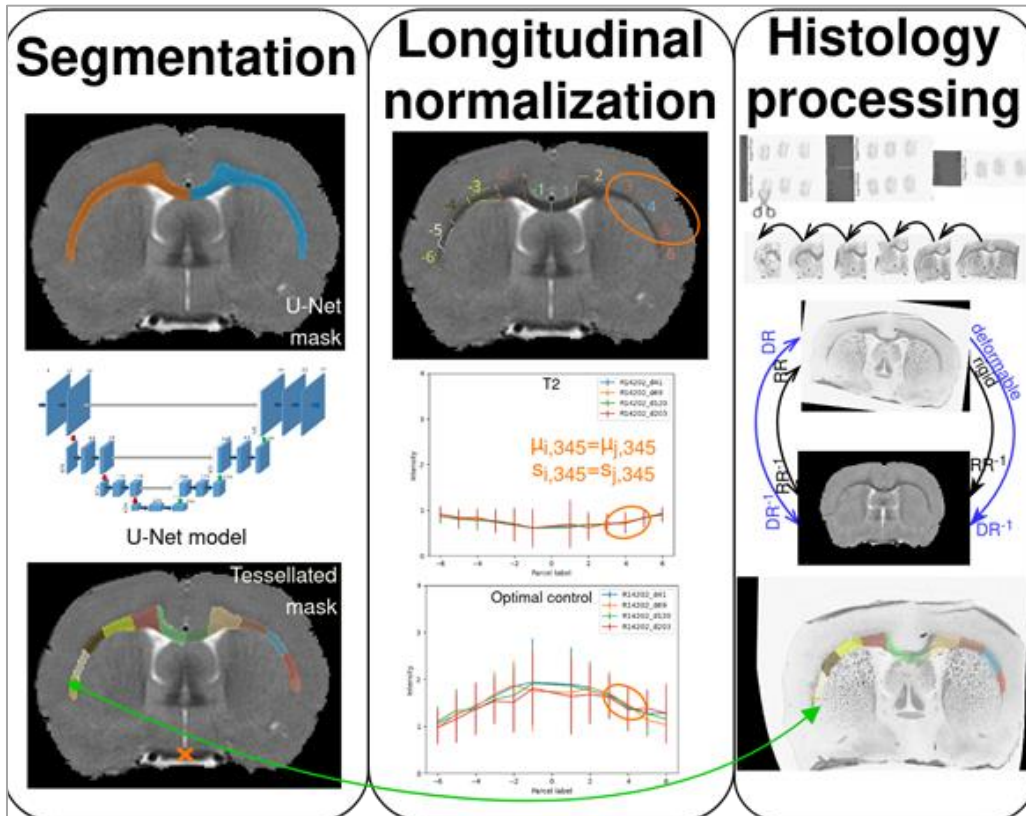


Figure 2- Illustration of the image analysis pipeline after images were preprocessed to be registered on the same rat template and normalized.

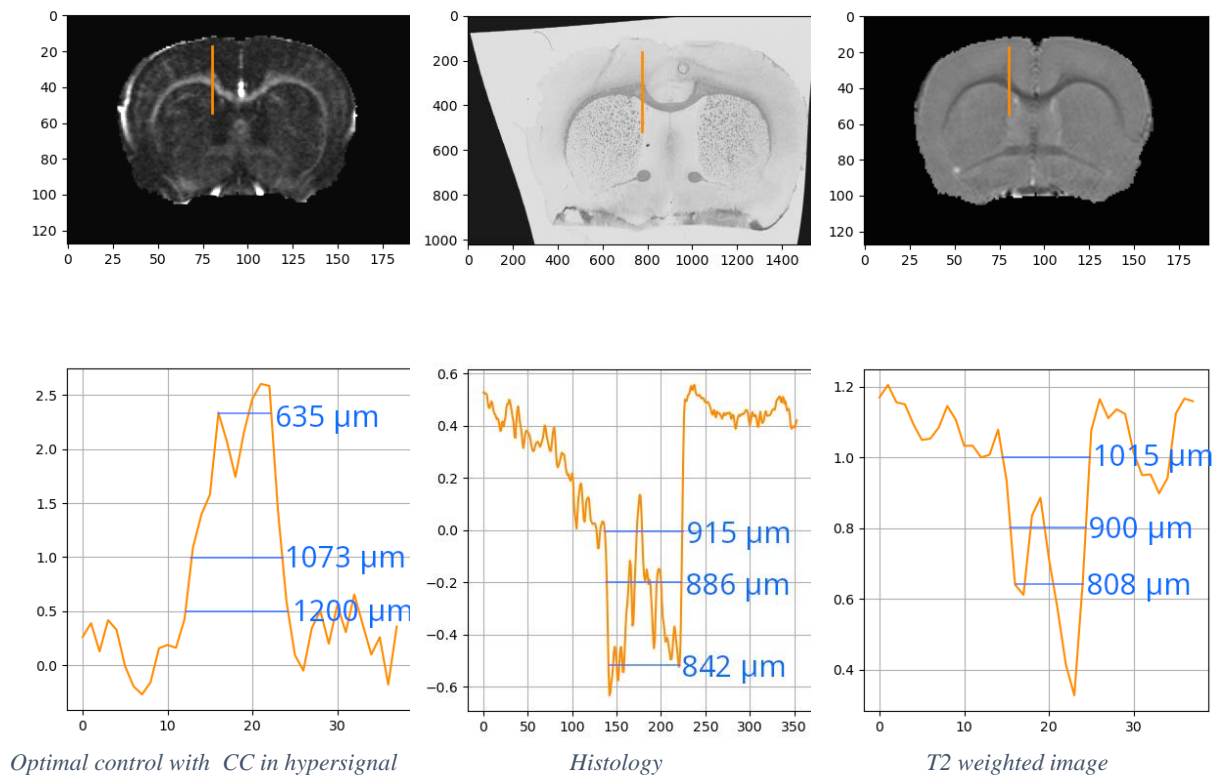


Figure 3: Comparison of profiles on injured CC for two sequences and histology on a rat LPC model

Acknowledgement:

This material is based upon work done on the ISO 9001:2015 PILoT facility. This work was carried out within the framework of a project financed by a ARSEP research grant and Neurodis fondation, and within the framework of the LABEX PRIMES (ANR-11-LABX-0063) as well as the program "Investissements d'Avenir" (ANR-11-IDEX-0007) of the French State, managed by the Agence Nationale de la Recherche (ANR)