



HAL
open science

Thoracoscopic Anterior Vertebral Body Tethering in Lenke Type-1 Right Adolescent Idiopathic Scoliosis

Clément Jeandel, Nicolas Bremond, Marie Christine de Maximin, Yan Lefèvre, Aurélien Courvoisier

► To cite this version:

Clément Jeandel, Nicolas Bremond, Marie Christine de Maximin, Yan Lefèvre, Aurélien Courvoisier. Thoracoscopic Anterior Vertebral Body Tethering in Lenke Type-1 Right Adolescent Idiopathic Scoliosis. *JBJS Essential Surgical Techniques*, 2023, 13 (3), pp.e22.00027. 10.2106/JBJS.ST.22.00027. hal-04443394

HAL Id: hal-04443394

<https://hal.science/hal-04443394v1>

Submitted on 10 Jan 2025

HAL is a multi-disciplinary open access archive for the deposit and dissemination of scientific research documents, whether they are published or not. The documents may come from teaching and research institutions in France or abroad, or from public or private research centers.

L'archive ouverte pluridisciplinaire **HAL**, est destinée au dépôt et à la diffusion de documents scientifiques de niveau recherche, publiés ou non, émanant des établissements d'enseignement et de recherche français ou étrangers, des laboratoires publics ou privés.



Distributed under a Creative Commons Attribution 4.0 International License

SUBSPECIALTY PROCEDURES

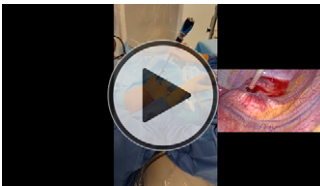
THORACOSCOPIC ANTERIOR VERTEBRAL BODY TETHERING IN LENKE TYPE-1 RIGHT ADOLESCENT IDIOPATHIC SCOLIOSIS

Clément Jeandel, MD, Nicolas Bremond, MD, Marie Christine de Maximin, MD, Yan Lefèvre, MD, PhD, Aurélien Courvoisier, MD, PhD

Published outcomes of this procedure can be found at: *J Bone Joint Surg Am.* 2020 May 6; 102(9):769-77, *Spine (Phila Pa 1976).* 2014 Sep 15;39(20):1688-93, and *J Bone Joint Surg Am.* 2021 Sep 1;103(17):1611-9.

Investigation performed at Centre alpin de la scoliose, Centre hospitalier Universitaire de Grenoble, Hôpital Couple Enfant, La Tronche, France

COPYRIGHT © 2023 BY THE JOURNAL OF BONE AND JOINT SURGERY, INCORPORATED



Click the arrow above or go to surgicaltechniques.jbjs.org to view the video article described in this summary.

Abstract

Background: Vertebral body tethering (VBT) is indicated for skeletally immature patients with progressive adolescent idiopathic scoliosis (AIS) who have failed or are intolerant of bracing and who have a major coronal curve of 40° to 65°. The vertebral body must be structurally and dimensionally adequate to accommodate screw fixation, as determined radiographically. The best indication for VBT is a flexible single major thoracic curve with nonstructural compensating lumbar and proximal thoracic curves (Lenke 1A or 1B). VBT allows for progressive correction of the deformity without spinal fusion by utilizing a minimally invasive fluoroscopic technique.

Description: The procedure for a right thoracic curve is performed with use of a right thoracoscopic approach with the patient in the left lateral decubitus position. The thoracoscope is introduced through a portal at the apex of the curvature in the posterior axillary line. Instrument portals are created lateral to each vertebral body in the mid-axillary line. Screws are inserted into each vertebral body under biplanar fluoroscopic control and with intraoperative neuromonitoring. An electroconductivity probing device, while not mandatory, is routinely utilized at our practice. The tether is attached to the most proximal screw of the construct, and then reduction is obtained sequentially by tensioning the tether from one vertebral screw to the next.

Alternatives: Bracing is the gold-standard treatment for progressive AIS involving the immature spine. The most commonly utilized surgical treatment is posterior spinal fusion (PSF), which should be considered when the major coronal curve exceeds 45°.

Rationale: PSF has proven to be a dependable technique to correct scoliotic deformities. It has a low complication rate and good long-term outcomes. However, concerns exist regarding the stiffness conferred by PSF and the long-term effects of adjacent segment disease. Thus, interest had developed in non-fusion solutions for AIS correction. VBT utilizes the Hueter-Volkman principle to guide growth and correct deformity. Compressive forces applied to the convexity of the deformity by a polyethylene tether allow the patient's growth to realign the spine. Intraoperative correction triggers growth modulation, and

Disclosure: The Disclosure of Potential Conflicts of Interest forms are provided with the online version of the article (<http://links.lww.com/JBJSST/A421>).

most of the modulation seems to occur during the first 12 months postoperatively. The best results have been seen with a short Lenke type-1A curve in a patient with closed triradiate cartilage, a Risser 3 or lower (ideally Risser 0) iliac apophysis, and a flexible curve characterized by a 50% reduction of the major coronal curve angle on side-bending radiographs.

Expected Outcomes: In 57 immature patients with a Lenke type-1A or 1B curve (i.e., a 30° to 65° preoperative Cobb angle), Samdani et al.³ found a main thoracic Cobb angle reduction from 40° ± 7° preoperatively to 19° ± 13° at 2 years after VBT. In the sagittal plane, the T5-T12 kyphosis measured 15° ± 10° preoperatively, 17° ± 10° postoperatively, and 20° ± 13° at 2 years. No major neurologic or pulmonary complications occurred. A total of 7 (12.3%) of the 57 patients underwent surgical revision, including 5 for overcorrection and 2 to span additional vertebrae. In a study of 21 skeletally mature patients, Pehlivanoglu et al.⁴ found that the Cobb angle was reduced from 48° preoperatively to 16° on the first-erect postoperative radiograph and finally to 10° at the latest follow-up (mean, 27.4 months). The 2 main complications of VBT reported in the literature are overcorrection and tether breakage. Both may require revision, which explains the higher rate of revision observed for VBT compared with PSF.

Important Tips:

- Good patient selection is important. VBT is most appropriate in cases of a flexible Lenke type-1A or 1B curve in an immature child before Risser stage 3 and after triradiate cartilage closure.
- Always monitor and control screw positioning in both anteroposterior and lateral planes fluoroscopically.
- The screws should be placed parallel to the vertebral end plates or, even better, be angled inferiorly for the upper vertebrae and angled superiorly for the lower vertebrae to decrease the risk of pull-out when tensioning the device and during growth modulation. Less tension on the uppermost and lowermost instrumented vertebrae than at the apex, as controlled by the tensioning device, can also help to limit pull-out.

Acronyms and Abbreviations:

- VBT = vertebral body tethering
- AIS = adolescent idiopathic scoliosis
- IONM = intraoperative neuromonitoring
- PSF = posterior spinal fusion
- UIV = upper instrumented vertebra
- LIV = lower instrumented vertebra
- AP = anteroposterior
- K-wire = Kirschner wire

Clément Jeandel, MD^{1,2}

Nicolas Bremond, MD³

Marie Christine de Maximin, MD³

Yan Lefevre, MD, PhD⁴

Aurélien Courvoisier, MD, PhD³

¹Centre hospitalier Universitaire de Montpellier, Hôpital Lapeyronie, Montpellier, France

²Polyclinique Saint Roch, Montpellier, France

³Centre alpin de la scoliose, Centre hospitalier Universitaire de Grenoble, Hôpital Couple Enfant, La Tronche, France

⁴Hôpital des Enfants-Groupe hospitalier Pellegrin, Centre hospitalier Universitaire de Bordeaux, Bordeaux, France

Email for corresponding author: docteurjeandel@orthopediepediatrie.fr

References

1. Newton PO, Bartley CE, Bastrom TP, Kluck DG, Saito W, Yaszay B. Anterior Spinal Growth Modulation in Skeletally Immature Patients with Idiopathic Scoliosis: A Comparison with Posterior Spinal Fusion at 2 to 5 Years Postoperatively. *J Bone Joint Surg Am.* 2020 May 6;102(9):769-77.
2. Samdani AF, Pahys JM, Ames RJ, Grewal H, Pelletier GJ, Hwang SW, Betz RR. Prospective Follow-up Report on Anterior Vertebral Body Tethering for Idiopathic Scoliosis: Interim Results from an FDA IDE Study. *J Bone Joint Surg Am.* 2021 Sep 1;103(17):1611-9.

3. Samdani AF, Ames RJ, Kimball JS, Pahys JM, Grewal H, Pelletier GJ, Betz RR. Anterior vertebral body tethering for idiopathic scoliosis: two-year results. *Spine (Phila Pa 1976)*. 2014 Sep 15;39(20):1688-93.
4. Pehlivanoglu T, Oltulu I, Oflluoglu E, Sarioglu E, Altun G, Korkmaz M, Yildirim K, Aydogan M. Thoracoscopic Vertebral Body Tethering for Adolescent Idiopathic Scoliosis: A Minimum of 2 Years' Results of 21 Patients. *J Pediatr Orthop*. 2020 Nov/Dec;40(10):575-80.
5. Danielsson AJ, Nachemson AL. Back pain and function 23 years after fusion for adolescent idiopathic scoliosis: a case-control study-part II. *Spine (Phila Pa 1976)*. 2003 Sep 15;28(18):E373-83.
6. Pesenti S, Jouve JL, Morin C, Wolff S, Sales de Gauzy J, Chalopin A, Ibnoukhatib A, Polirsztok E, Walter A, Schuller S, Abelin-Genevois K, Leroux J, Lechevallier J, Kabaj R, Mary P, Fuentes S, Parent H, Garin C, Bin K, Peltier E, Blondel B, Chopin D; SOFCOT. Evolution of adolescent idiopathic scoliosis: results of a multicenter study at 20 years' follow-up. *Orthop Traumatol Surg Res*. 2015 Sep;101(5):619-22.
7. Newton PO. Spinal growth tethering: indications and limits. *Ann Transl Med*. 2020 Jan;8(2):27.
8. Takahashi Y, Saito W, Yaszay B, Bartley CE, Bastrom TP, Newton PO. Rate of Scoliosis Correction After Anterior Spinal Growth Tethering for Idiopathic Scoliosis. *J Bone Joint Surg Am*. 2021 Sep 15;103(18):1718-23.
9. Ruzic JC, Moreno A, Morin C. Technique simplifiée de drainage thoracique dans la chirurgie antérieure de la scoliose chez l'enfant. *Rev Chir Orthop Repar Appar Mot*. 1998 Oct;84(6):550-3.
10. Trobisch PD, Baroncini A. Preliminary outcomes after vertebral body tethering (VBT) for lumbar curves and subanalysis of a 1- versus 2-tether construct. *Eur Spine J*. 2021 Dec;30(12):3570-6.