



HAL
open science

Femoral fracture during breech vaginal delivery: A case report

C. Curtelin, E. Delille, C. Bailly, V. Equy, P. Hoffmann, A. Courvoisier, D. Riethmuller

► To cite this version:

C. Curtelin, E. Delille, C. Bailly, V. Equy, P. Hoffmann, et al.. Femoral fracture during breech vaginal delivery: A case report. *Journal of Gynecology Obstetrics and Human Reproduction*, 2022, 51 (3), pp.102310. 10.1016/j.jogoh.2022.102310 . hal-04443350

HAL Id: hal-04443350

<https://hal.science/hal-04443350>

Submitted on 22 Jul 2024

HAL is a multi-disciplinary open access archive for the deposit and dissemination of scientific research documents, whether they are published or not. The documents may come from teaching and research institutions in France or abroad, or from public or private research centers.

L'archive ouverte pluridisciplinaire **HAL**, est destinée au dépôt et à la diffusion de documents scientifiques de niveau recherche, publiés ou non, émanant des établissements d'enseignement et de recherche français ou étrangers, des laboratoires publics ou privés.



Distributed under a Creative Commons Attribution - NonCommercial 4.0 International License

Femoral fracture during breech vaginal delivery: A case report.

Curtelin C, Delille E, Bailly C, Equy V, Hoffmann P, Courvoisier A[°], Riethmuller D*.

University Grenoble-Alpes

and

Department of Gynecology-Obstetrics and Reproductive Medicine

[°]Department of Paediatric Orthopaedic Surgery

Grenoble Alpes University Hospital, Grenoble, France

*Corresponding author

Key words: breech presentation – vaginal birth – femoral fracture

No conflict of interest for all the authors

Introduction

Femoral fracture is a rare but significant fetal injury, occurring in 1 to 2 out of 1000 live births, more frequent and likely to happen when the fetus is malpositioned or in a breech presentation [1]. For a long time, cesarean sections have been considered as a protective factor against neonatal long bone fractures among other risks [2].

However, in the PREMODA study [3], the total number of neonatal "injuries" (a composite criterion) was significantly higher in the vaginal arm compared to the cesarean section arm with an OR of 3.90 (95%CI: 2.40-6.34). However, if one examines the site of injury, this statistical result is explained by the much greater number of clavicle fractures in the vaginal arm (15 versus 5), whereas other more serious fractures (mainly femur) occurred only in the cesarean arm. In the Term Breech Trial [4] this distinction is not possible as clavicle and long bone fractures were pooled (1 case in the cesarean group and 6 cases in the vaginal group).

This has been confirmed by several more recent retrospective series and case reports that have shown that most neonatal femoral fractures occur during cesarean delivery for breech presentation [1, 5-12]. In contrast, we present here the case of a unilateral femoral fracture during vaginal delivery by a healthy primiparous woman.

Case report

We report the case of a 29 year-old woman without any medical issues who delivered vaginally at term in the maternity unit of Grenoble University Hospital France in April 2021.

The fetus was diagnosed with Fallot cardiopathy with, nevertheless, good caliber pulmonary vessels. The third trimester fetal biometry estimation was within the 10th percentile with an incomplete footling breech presentation. Radiologic pelvimetry showed a normal bonny pelvis (conjugate = 133 mm, transverse = 127 mm and interspinous = 106 mm) with a Magnin Index of 26. Vaginal delivery was encouraged for this woman.

The patient started rapid spontaneous labor at term (40 weeks) with the fetus still in an incomplete footling breech presentation (sacro-iliac-right-anterior position with the right leg extended). The duration of the 2nd stage of the labor was 1.5 hours. It was decided to encourage maternal expulsive efforts due to fetal heart rate abnormalities (atypical variable decelerations). The fetal sacrum was at station +2 and the right leg was totally externalized. However, due to a lack of progression the highly experienced obstetrician applied traction on the foot of the externalized right lower limb with the classical technique while the left leg was still bent in a transverse position within the pelvis. This was followed by Lovset's maneuver and the use of Tessier spatulas for entrapment of the after-coming head after a failed Mauriceau's maneuver (as described by Offringa et al. [13]), permitting the delivery of a 2570g girl. Her Apgar was 5 at one minute and 10 at five minutes. Arterial pH was 7.19 and venous pH 7.25. A 1st degree perineal injury was observed.

An abnormal angle of the left lower limb was quickly noted and a spiroïdal mid-femoral shaft fracture was diagnosed (figure 1). The newborn was quickly transferred to the pediatric ICU and the lower limb was immobilized. There were no signs of any other fractures, demineralization or osteo-articular abnormalities. The short-term progress was favorable with a skin traction of the injured limb during one month (figure 2, figure 3). However, this entailed the first cardiac surgery being delayed by two weeks.

At five months the infant was doing well with no complications related to her leg fracture and her cardiac management was successful.

Discussion

Nowadays, for breech presentation, femoral fracture is more likely to happen during a cesarean than during vaginal delivery. In the PREMODA study [3], femoral fractures only occurred in the cesarean group and in the Term Breech Trial [4] this information is not available. Several recent cases have been reported of fracture after cesarean for breech presentation whereas there are no recent published reports of this injury after vaginal delivery.

Risk factors for cesarean delivery of breech presentation have been highlighted in retrospective series particularly for preterm delivery, fetal macrosomia, multiple pregnancy, metabolic bone diseases, and emergency cesarean delivery [6, 14].

In the present case none of those risk factors were present. Despite the incomplete footling breech presentation the decision for vaginal delivery was made based on the fetal heart rate abnormalities presented by a fetus with a cardiac malformation. This required birth without any delay with possibly complex forceful maneuvers performed by a very experienced obstetrician. The incomplete breech presentation forced the obstetrician to apply traction on the only accessible lower limb (the right leg in this case). This traction to just one leg might have caused impaction of the left leg against the pelvis and caused the fracture.

The fracture was spiroïdal and located in the mid-femoral shaft, which is typical of obstetrical fractures occurring with breech presentations according to Morris and al. [14]. However, the fractured limb is more likely to be the extended one, while in the present case it was the bent limb.

Unfortunately, there is no retrospective series that details subtypes of breech presentation involved in this kind of complication.

Even if femoral fractures occur more often during cesarean deliveries (with an odds ratio of 11 [7]), this case reminds us to take extra care during vaginal deliveries, especially those with unusual presentation such as incomplete footling breech. Prevention of this exceptional situation appears to be difficult and to date no particular maneuver has been described for it.

Long bone neonatal fractures usually have a good prognosis when they are diagnosed early, as described by Kancherla et al. in a series of 10 newborns with no adverse consequence of the fracture at 5 years follow up [15]. The clinical features of the fracture are not often clear and the diagnosis is sometimes several days after birth [16]. This should encourage the neonatologist to request an early X-ray if forceful obstetrical maneuvers were needed, so as not to delay the diagnosis and its treatment.

The prevalence of such complications remains very low at around 0.027 fractures for 1000 vaginal births [7] and should not discourage obstetricians from performing natural birth techniques with any type of breech presentation.

Acknowledgement

We thank Alison Foote (Grenoble, France) for critical reading and substantial editing of the manuscript.

References:

1. Kanat Pektaş M, Koyuncu H, Kundak AA. Long bone fractures in neonatal intensive care units of Afyonkarahisar: Five-year's experience. *J Turk Soc Obstet Gynecol.* 2020;16(4):21923.
2. Gunay T, Turgut A, Demircivi Bor E, Hocaoglu M. Comparison of maternal and fetal complications in pregnant women with breech presentation undergoing spontaneous or induced vaginal delivery, or cesarean delivery. *Taiwan J Obstet Gynecol.* 2020;59(3):3927.
3. Goffinet F, Carayol M, Foidart JM, Alexander S, Uzan S, Subtil D et al. Is planned vaginal delivery for breech presentation at term still an option? Results of an observational prospective survey in France and Belgium. *Am J Obstet Gynecol.* 2006;194(4):1002-11.
4. Hannah ME, Hannah WJ, Hewson SA, Hodnett ED, Saigal S, Willan AR. Planned caesarean section versus planned vaginal birth for breech presentation at term: a randomised multicentre trial. Term Breech Trial Collaborative Group. *Lancet.* 2000;356(9239):1375-83.
5. Högberg U, Fellman V, Thiblin I, Karlsson R, Wester K. Difficult birth is the main contributor to birth-related fracture and accidents to other neonatal fractures. *Acta Paediatr.* 2020;109(10):20408.
6. Pavone V, Vescio A, Montemagno M, de Cristo C, Lucenti L, Pavone P, et al. Perinatal femoral fracture: A ten-year observational case series study. *Children.* 2020;7(10):156.
7. Toker A, Perry ZH, Cohen E, Krymko H. Cesarean section and the risk of fractured femur. *Isr Med Assoc J IMAJ.* 2009;11(7):4168.
8. Cebesoy FB, Cebesoy O, Incebiyik A. Bilateral femur fracture in a newborn: an extreme complication of cesarean delivery. *Arch Gynecol Obstet.* 2009;279(1):734.
9. Capobianco G, Viridis G, Lisai P, Cherchi C, Biasetti O, Dessole F, et al. Cesarean section and right femur fracture: A rare but possible complication for breech presentation. *Case Rep Obstet Gynecol.* 2013;2013:13.
10. Matsubara S, Izumi A, Nagai T, Kikkawa I, Suzuki M. Femur fracture during abdominal breech delivery. *Arch Gynecol Obstet.* 2008;278(2):1957.
11. Vellingiri K, Venkataraman S, Shanthappa AH, Seenappa H. Femur Shaft Fracture in Newborns: A Report of Two Cases. *Cureus.* 2021;13(1):e12504.
12. Farikou I, B, Ngo Nonga, Handy Eone D, Sosso Maurice A. Fracture of the Femur of a newborn after cesarean section for breech presentation and fibroid uterus : A case report and literature review. *J Orthop Case Rep.* 2014;4(1):1820.
13. Offringa Y, Mottet N, Parant O, Riethmuller D, Vidal F, Guerby P. Spatulas for entrapment of the after-coming head during vaginal breech delivery. *Arch Gynecol Obstet.* 2019;299(5):1283-8.
14. Morris S, Cassidy N, Stephens M, McCormack D, McManus F. Birth-associated femoral fractures: incidence and outcome. *J Pediatr Orthop.* 2002;22(1):2730.
15. Kancherla R, Sankineani SR, Naranje S, Rijal L, Kumar R, Ansari T, et al. Birth-related femoral fracture in newborns: risk factors and management. *J Child Orthop.* 2012;6(3):17780.
16. Kanai Y, Honda Y, Honda T, Sanpei M. Delayed birth-related femur fracture after cesarean section: A case report. *Am J Perinatol Rep.* 2018;08(03):e15860.

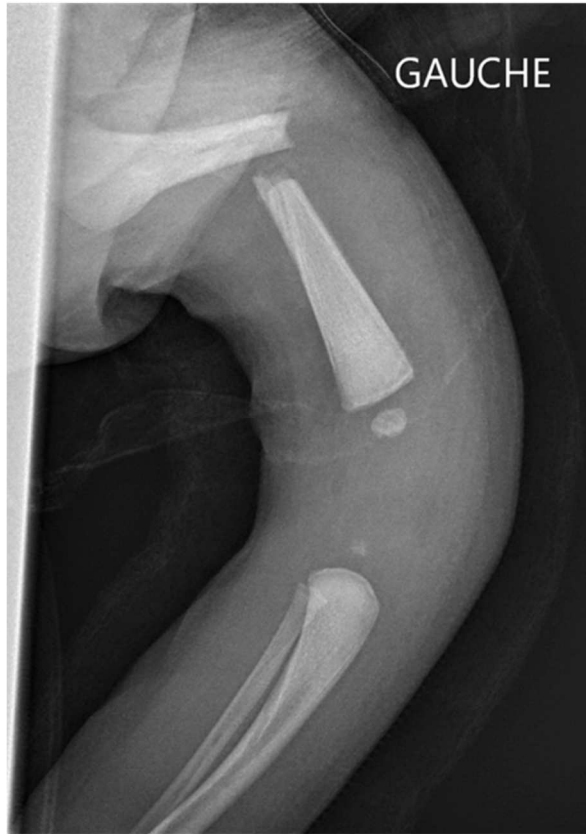

Figure 1: initial post-natal X Ray

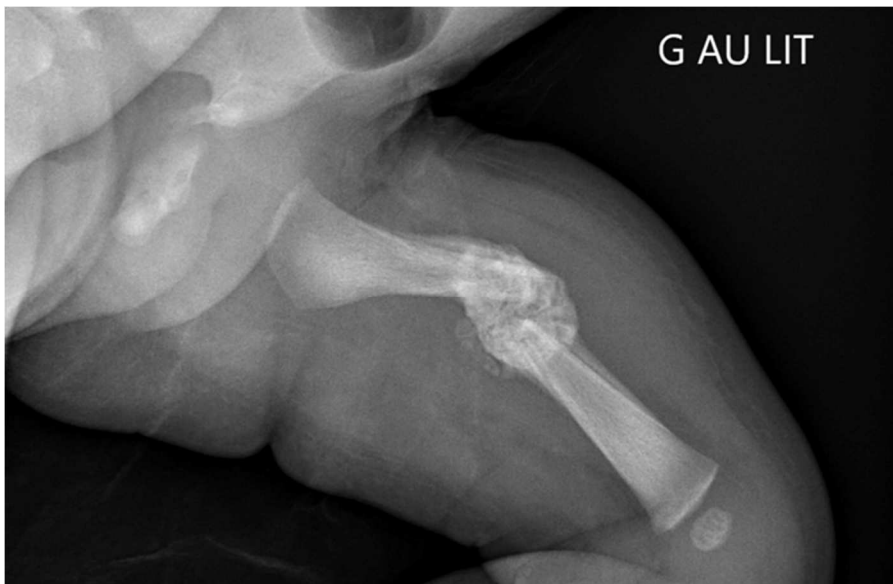


Figure 2: X ray at day 14 after skin traction

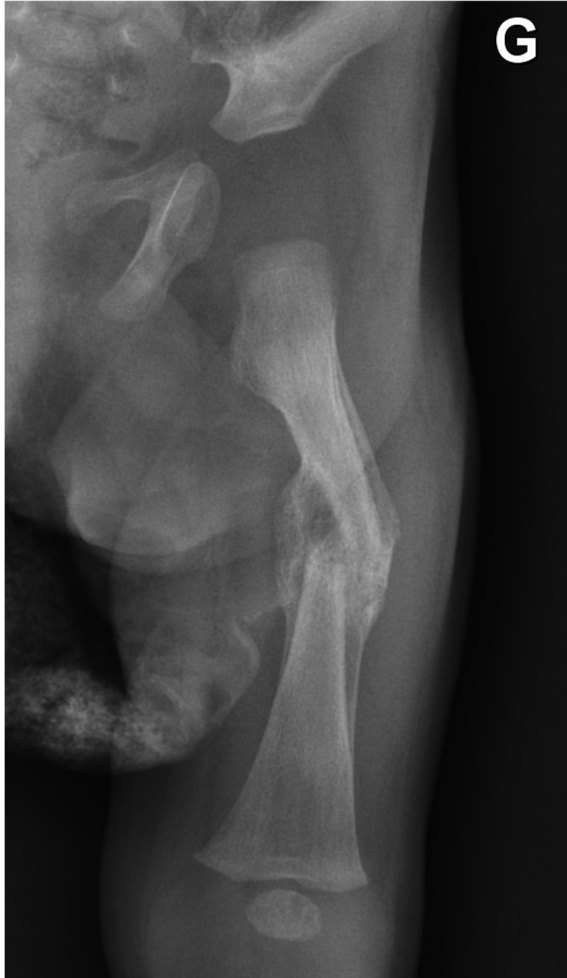

Figure 3: X ray after 2 months