



Section III: Disorders of Mitochondrial Energy Metabolism. Disorders of Pyruvate Metabolism and the Tricarboxylic Acid Cycle

Michèle Brivet, Pauline Gaignard, Manuel Schiff

► To cite this version:

Michèle Brivet, Pauline Gaignard, Manuel Schiff. Section III: Disorders of Mitochondrial Energy Metabolism. Disorders of Pyruvate Metabolism and the Tricarboxylic Acid Cycle. Georg F. Hoffmann, Johannes Zschocke, William L. Nyhan. Inherited Metabolic Diseases, A Clinical Approach., 2017, 978-3-662-49410-3. 10.1007/978-3-662-49410-3 . hal-04440886

HAL Id: hal-04440886

<https://hal.science/hal-04440886>

Submitted on 6 Feb 2024

HAL is a multi-disciplinary open access archive for the deposit and dissemination of scientific research documents, whether they are published or not. The documents may come from teaching and research institutions in France or abroad, or from public or private research centers.

L'archive ouverte pluridisciplinaire **HAL**, est destinée au dépôt et à la diffusion de documents scientifiques de niveau recherche, publiés ou non, émanant des établissements d'enseignement et de recherche français ou étrangers, des laboratoires publics ou privés.

Section III: Disorders of Mitochondrial Energy Metabolism

Disorders of Pyruvate Metabolism and the Tricarboxylic Acid Cycle

Michèle Brivet, 2 rue Anatole France, 94270 Le Kremlin Bicêtre, France. michele.brivet@gmail.com

Pauline Gagnard, Service de Biochimie, Hôpital Bicêtre, 78 Rue de General Leclerc, 94275, Le Kremlin Bicêtre Cedex, France. pauline.gagnard@aphp.fr

Manuel Schiff, Centre de Référence des Maladies Héréditaires du Métabolisme, Hôpital Necker-Enfants Malades, 149 rue de Sèvres 75015 Paris, France. manuel.schiff@aphp.fr

Résumé

Owing to the role of pyruvate and the tricarboxylic acid (TCA) cycle in energy metabolism, as well as in gluconeogenesis, lipogenesis and amino acid synthesis, defects in pyruvate metabolism and in the TCA cycle almost invariably affect the central nervous system. The severity and the different clinical phenotypes vary widely among patients and are not always specific, the range of manifestations extending from overwhelming neonatal lactic acidosis with early death to relatively normal adult life and variable effects on systemic functions. Similar clinical manifestations may be caused by other defects of energy metabolism, especially defects of the mitochondrial respiratory chain. Diagnosis relies primarily on biochemical analyses of accumulated metabolites in body fluids, DNA analysis and, in some instances, confirmation by definitive enzymatic assays in cells or tissues. Prenatal diagnosis is now achieved preferentially by DNA analysis. Pyruvate carboxylase (PC) deficiency constitutes a defect both in the TCA cycle and in gluconeogenesis, but generally presents with severe neurological dysfunction and lactic acidosis rather than with fasting hypoglycaemia. Deficiency of phosphoenolcarboxykinase (PEPCK) is limited to its cytosolic form and affects gluconeogenesis. Deficiency of pyruvate dehydrogenase complex (PDHC) impedes glucose oxidation and aerobic energy production, and ingestion of carbohydrate aggravates lactic acidosis. The defects of mitochondrial pyruvate carrier have the same presentation as PDHC deficiencies. Treatment of disorders of pyruvate metabolism comprises avoidance of fasting (PC deficiency) or minimising dietary carbohydrate intake (PDHC deficiency) and enhancing anaplerosis (restoration of pools of intermediate metabolites). Dihydrolipoamide dehydrogenase (E3) deficiency affects PDHC and also the 2-ketoglutarate dehydrogenase complex (KDHC) and the branched-chain 2-ketoacid dehydrogenase (BCKD) complex, with biochemical manifestations of all three disorders. The deficiencies of the TCA cycle enzymes interrupt the cycle but do not always result in accumulation of the corresponding substrates. Succinyl-CoA ligase deficiency causes a mild methylmalonic accumulation. Succinate dehydrogenase deficiency represents a unique disorder affecting both the TCA cycle and the respiratory chain. The defects of the malate-aspartate shuttle (MAS) impede the import of reduced nicotinamide adenine dinucleotide (NADH) from the cytosol to the mitochondrion and the subsequent pyruvate oxidation. NAXE and NAXD deficiencies disrupt the cellular NAD(P)HX repair system and cause lethal neurometabolic disorders of early childhood.

Keywords/ Lactic Acidosis, Pyruvate Dehydrogenase, Ketogenic Diet, Pyruvate Carboxylase, Pyruvate Dehydrogenase Complex.

Owing to the role of pyruvate and the tricarboxylic acid (TCA) cycle in energy metabolism, as well as in gluconeogenesis, lipogenesis and amino acid synthesis, defects in pyruvate metabolism and in the TCA cycle almost invariably affect the central nervous system. The severity and the different clinical phenotypes vary widely among patients and are not always specific, the range of manifestations extending from overwhelming neonatal lactic acidosis with early death to relatively normal adult life and variable effects on systemic functions. Similar clinical manifestations may be caused by other defects of energy metabolism, especially defects of the mitochondrial respiratory chain (Chapter 14). Diagnosis relies primarily on biochemical analyses of accumulated metabolites in body fluids, DNA analysis and, in some instances, confirmation by definitive enzymatic assays in cells or tissues. Prenatal diagnosis is now achieved preferentially by DNA analysis. Pyruvate carboxylase (PC) deficiency constitutes a defect both in the TCA cycle and in gluconeogenesis, but generally presents with severe neurological dysfunction and lactic acidosis rather than with fasting hypoglycaemia. Deficiency of phosphoenolcarboxykinase (PEPCK) is limited to its cytosolic form and affects gluconeogenesis. Deficiency of pyruvate dehydrogenase complex (PDHC) impedes glucose oxidation and aerobic energy production, and ingestion of carbohydrate aggravates lactic acidosis. The defects of mitochondrial pyruvate carrier have the same presentation as PDHC deficiencies. Treatment of disorders of pyruvate metabolism comprises avoidance of fasting (PC deficiency) or minimising dietary carbohydrate intake (PDHC deficiency) and enhancing anaplerosis (restoration of pools of intermediate metabolites). Dihydrolipoamide dehydrogenase (E3) deficiency affects PDHC and also the 2-ketoglutarate dehydrogenase complex (KDHC) and the branched-chain 2-ketoacid dehydrogenase (BCKD) complex (Chapter 18), with biochemical manifestations of all three disorders. The deficiencies of the TCA cycle enzymes interrupt the cycle but do not always result in accumulation of the corresponding substrates. Succinyl-CoA ligase deficiency causes a mild methylmalonic accumulation. Succinate dehydrogenase deficiency represents a unique disorder affecting both the TCA cycle and the respiratory chain. The defects of the malate-aspartate shuttle (MAS) impede the import of reduced nicotinamide adenine dinucleotide (NADH) from the cytosol to the mitochondrion and the subsequent pyruvate oxidation. NAXE and NAXD deficiencies disrupt the cellular NAD(P)HX repair system and cause lethal neurometabolic disorders of early childhood.

Pyruvate is formed by glycolysis from glucose and other monosaccharides, from lactate and from alanine, a neoglucogenic amino acid (● Fig. 11.1).

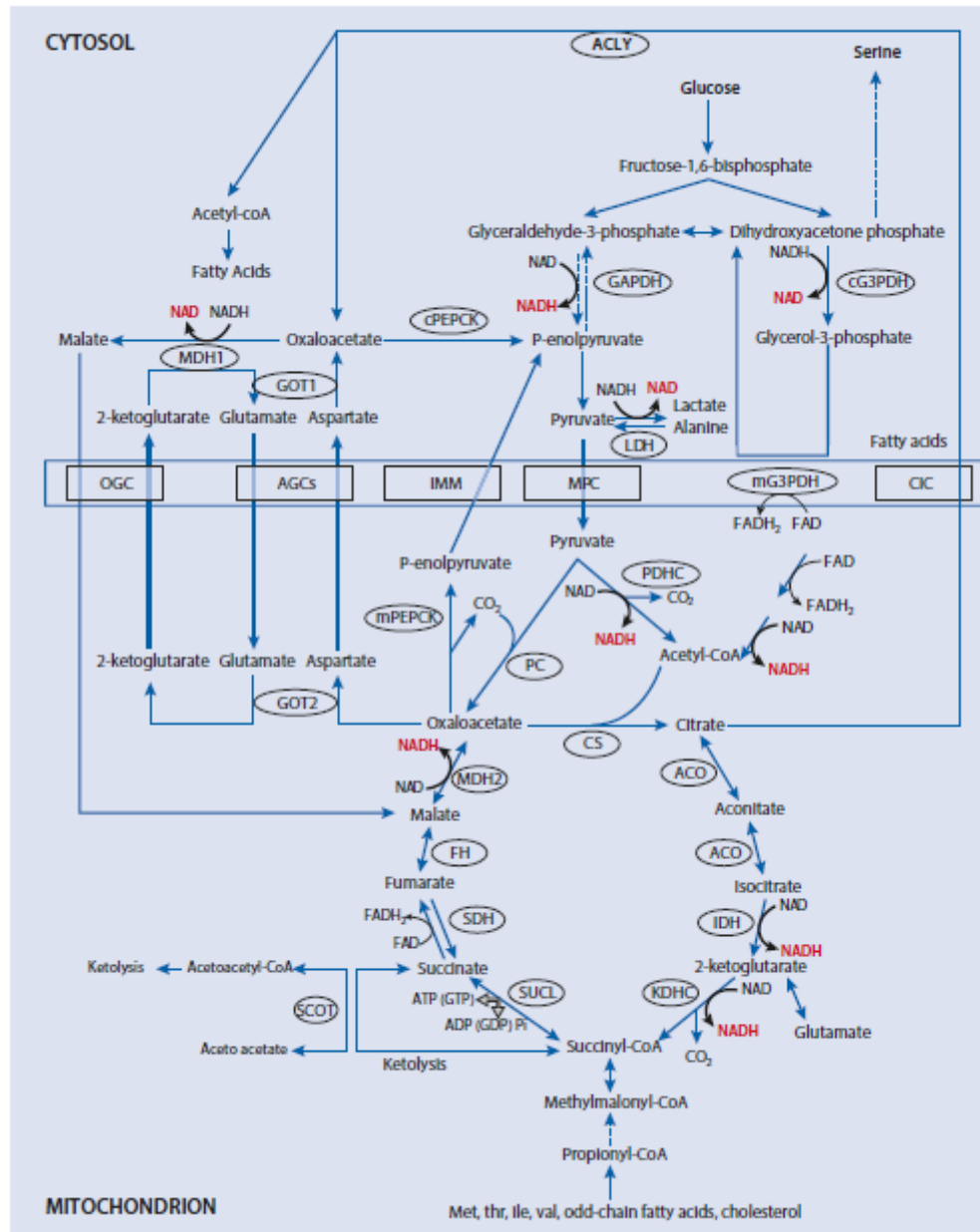


Fig. 11.1. Overview of glucose, Pyruvate/lactate, fatty acid and amino acid oxidation by the tricarboxylic acid cycle. Aco, aconitase ; AGCs, aspartate glutamate carriers 1 et 2; ATP, adenosine triphosphate ; CS, citrate synthase ; FH, fumarase ; GAPDH, glyceraldehyde-3-phosphate dehydrogenase ; GOT1, GOT2, glutamate oxaloacetate transaminases 1 and 2 ; cG3PDH, mG3PDH cytosolic and mitochondrial glycerol-3-phosphate dehydrogenases; GTP : guanosine triphosphate ; IDH, isocitrate dehydrogenase ; IMM, inner mitochondrial membrane ; KDHC, 2-ketoglutarate dehydrogenase complex ; LDH, lactate dehydrogenase; MDH1, MDH2 malate dehydrogenases 1 and 2 ; MPC mitochondrial pyruvate carrier ; OGC oxoglutarate carrier ; PDHC, pyruvate dehydrogenase complex ; PC, pyruvate carboxylase ; cPEPCK, mPEPCK cytosolic and mitochondrial

phosphoenolpyruvate carboxykinases ; SCOT, succinyl-CoA 3-oxoacid CoA transferase ; SDH, succinate dehydrogenase ; SUCL, succinyl-CoA ligase.

The final stage of glycolysis converts glyceraldehyde-3-phosphate (GAP) into pyruvate generating cytosolic reduced adenine nucleotide (NADH) via GAP dehydrogenase (GAPDH). NADH is shuttled into the mitochondrion for re-oxidation, via the malate-aspartate shuttle (MAS) or via the glycerol-3-phosphate (G3P) shuttle. Two enzymes and two carriers are required for the function of the MAS : the two enzymes, glutamate oxaloacetate transaminase (GOT) and malate dehydrogenase (MDH) are present both in the cytoplasm (GOT1 and MDH1) and in the mitochondrial matrix (GOT2 and MDH2). The two carriers are located in the inner mitochondrial membrane (AGCs and OGC). AGC1 (or Aralar) is highly expressed in central nervous system and in skeletal muscle whereas AGC2 (or citrin) is mainly present in intestine and liver. The calcium sensibility of AGC1 plays a major role in the calcic regulation of substrate supply for the oxidative phosphorylation (OXPHOS) to the mitochondria. In neurons AGC1 is also crucial to supply cytosolic aspartate for N-Acetyl-aspartate formation (chapter 22). In the presence of high levels of glycolytically produced NADH, the cytosolic MDH1 reduces oxaloacetate into malate. Malate is exported from the cytosol into the mitochondrial matrix by OGC in exchange for 2-ketoglutarate. In the mitochondria, the oxidation of malate into oxaloacetate regenerates NADH, which can be used to pass electrons to the respiratory chain for ATP synthesis. Oxaloacetate and glutamate are then transformed into aspartate and 2-ketoglutarate by GOT2. AGC1 exports aspartate from the matrix to the cytosol in exchange for glutamate plus a proton and aspartate is then converted into oxaloacetate by GOT1 achieving the cycle. The G3P shuttle acts in a way similar to the MAS to re-oxidize the cytosolic pool of NADH but it is mainly involved in lipid biosynthesis (Chapter 35). DHAP from glycolysis is reduced to G3P by the cytosolic NAD-dependent GPDH. The mitochondrial GPDH re-oxidizes G3P to DHAP and transfers two electrons from FAD to the electron transport chain. The mitochondrial pyruvate carrier allows the uptake of pyruvate into mitochondria. Pyruvate can be then converted into acetyl-coenzymeA (acetyl-coA) by the pyruvate dehydrogenase complex (PDHC) for further oxidation in the TCA cycle. Pyruvate can also enter the gluconeogenic pathway by sequential conversion into oxaloacetate by pyruvate carboxylase (PC), followed by conversion to phosphoenolpyruvate by phosphoenolpyruvate carboxykinase (PEPCK). Acetyl-coA is also formed by fatty acid oxidation. One of the primary functions of the TCA cycle is to generate reducing equivalents in the form of NADH and reduced flavin adenine dinucleotide (FADH₂), which are utilized to produce energy under the form of ATP in the electron transport chain by the OXPHOS. The MAS senses cytosolic calcium (Ca²⁺) with respect to its Ca²⁺ sensitive component AGC1 and plays an essential role in the control of substrate supply for OXPHOS. Another important role of the TCA cycle comes from the fact that Succinyl-CoA is at the crossroad of several pathways (ketolysis, catabolism of isoleucine, valine, threonine, methionine, odd chain fatty acids and cholesterol) and that succinyl-CoA ligase (SUCL) can yield directly GTP and ATP in the absence of oxygen (a mechanism known as substrate level phosphorylation) and participates to mtDNA maintenance.

11.1 Pyruvate Carboxylase Deficiency (PC)

11.1.1 Clinical Presentation

PC deficiency is an autosomal recessive disorder with an incidence of around 1 in 250,000. Several dozen patients have been described in detail, allowing the definition of three overlapping phenotypes that probably constitute a continuum from the most severe (type B) to the less severe form (type C). For a review see [1].

1. Patients with the French phenotype (type B) become acutely ill 3–48 h after birth with hypothermia, hypotonia, lethargy and vomiting [1; 2; 3]. These children exhibit a severe neurological

neonatal deterioration with initially a preserved level of consciousness but then rapid deterioration with rigidity, hypokinesia and tremor (resembling infantile parkinsonism) and abnormal ocular movements [2]. Hepatomegaly, seizures and failure to thrive may occur. Most die in the neonatal period in the setting of severe lactic acidosis with intractable tubulopathy and multiorgan (liver) failure. Some survive, but they remain unresponsive and severely hypotonic and finally succumb from respiratory infection before the age of 5 months.

2. Patients with the North American phenotype (type A) become severely ill between 2 and 5 months of age. They develop progressive hypotonia and are unable to smile. Frequent episodes of acute vomiting, dehydration, tachypnoea, facial pallor, cold cyanotic extremities and lactic acidosis, characteristically precipitated by metabolic or infectious stress, occur. Clinical examination reveals pyramidal tract signs, ataxia and nystagmus. All patients are severely mentally retarded and most of them have seizures. Hepatomegaly and renal dysfunction (tubular acidosis) may also be present. Neuroradiological findings (also found in type B) include subdural effusions, severe antenatal ischaemia-like brain lesions and periventricular haemorrhagic cysts, followed by progressive cerebral atrophy and delayed myelination. Leigh syndrome has also been reported but its frequency remains uncertain. The course of the disease is generally progressive, with death in infancy.

3. The Type C phenotype is more benign and has only been reported in a few patients without clear ethnic predilection [1]. The clinical course is dominated by the occurrence of acute episodes of lactic acidosis and ketoacidosis, usually responding rapidly to hydration and bicarbonate therapy. Despite the important enzyme deficiency, the patients have a near-normal cognitive and neuromotor development. However, dystonia, episodic ataxia, dysarthria, transitory hemiparesis, seizures and subcortical leukodystrophy have been described in some cases.

Prenatal features have been reported on a limited number of cases. Ultrasound examination and MRI had revealed frontal horn impairment associated with subependymal and paraventricular cysts in few cases which could be suggestive of a PC deficiency in unknown families [4].

11.1.2 Metabolic Derangement

PC is a biotinylated mitochondrial matrix enzyme that converts pyruvate and CO₂ to oxaloacetate. It plays an important role in gluconeogenesis, anaplerosis and lipogenesis. For gluconeogenesis, pyruvate must first be carboxylated into oxaloacetate, because the last step of glycolysis, conversion of phosphoenolpyruvate to pyruvate is irreversible. Oxaloacetate, which cannot diffuse freely out of the mitochondrion, is translocated into the cytoplasm via the MAS. Once in the cytoplasm, oxaloacetate is converted into phosphoenolpyruvate by PEPCK, which catalyses the first committed step of gluconeogenesis.

The anaplerotic role of PC, i.e. the generation of TCA cycle intermediates from oxaloacetate, is even more important. In severe PC deficiency, the lack of TCA cycle intermediates lowers reducing equivalents in the mitochondrial matrix. This drives the redox equilibrium between 3-OH-butyrate and acetoacetate in the direction of acetoacetate thereby lowering the 3-OH-butyrate/acetoacetate ratio. Aspartate, formed in the mitochondrial matrix from oxaloacetate by transamination, also decreases. As a consequence, the translocation of reducing equivalents between cytoplasm and mitochondrial matrix by the MAS is impaired. This drives the cytoplasmic redox equilibrium between lactate and pyruvate in the direction of lactate, and the lactate/pyruvate (L/P) ratio increases. Reduced TCA cycle activity also plays a role in the increase of lactate and pyruvate. Since aspartate is required for the urea cycle, plasma ammonia and citrulline can increase. The low 2-ketoglutarate production explains the low plasma level of glutamate. The energy deprivation induced by PC deficiency has been postulated

to impair astrocytic buffering capacity against excitotoxic insults and to compromise microvascular morphogenesis and autoregulation, leading to white matter degeneration [1].

The key-role of PC in lipogenesis derives from the condensation of oxaloacetate with intramitochondrially produced acetyl-CoA into citrate. Deficient lipogenesis explains the widespread demyelination of the cerebral and cerebellar white matter and symmetrical periventricular cavities around the frontal and temporal horns of the lateral ventricles, reported in the few detailed neuropathological descriptions of PC deficiency. PC is present in oligodendrocytes, where it plays an anaplerotic role [5]. PC deficiency in the oligodendrocytes should result in insufficient fatty acid synthesis and myelin malformation, whereas the impairment of oxidative metabolism in microglial cells is associated with an inflammatory response possibly contributing to neurodegeneration [6].

In a patient with the type B phenotype, muscle biopsy disclosed nemaline rods that probably occurred due to defective energy metabolism. Mitochondrial accumulation in type 1 fibers raises the possibility that the thin filaments may become the target structures of mitochondrial dysfunction [7].

PC requires biotin as a cofactor. Secondary PC deficiency is thus also observed in biotin-responsive multiple carboxylase (Chapter 27) and in carbonic anhydrase VA deficiency (Chapter 19).

11.1.3 Genetics

PC deficiency is an autosomal recessive disorder. PC is a tetramer formed by 4 identical subunits organized in two conformational states over the course of its two steps enzymatic reaction.

In the fatal form, the presence of at least one truncating mutation in the PC gene tends to lead to type B presentation while biallelic missense mutations tend to lead to type A, with some exceptions. Structure-function studies showed that missense mutations disturbing the ligands fixation or the balance between the two conformational states seem to be associated to type A presentation. Missense mutations associated to type C presentation destabilize the monomers but do not lead to a misbalance between the conformers [8]. The p.Ala610Thr mutation, frequent in Indo-American patients, is associated with type A.

Mosaicism was reported in a few cases and found to be correlated with prolonged patient survival [9].

11.1.4 Diagnostic Tests

The most severely affected patients typically exhibit an elevated L/P ratio, low hydroxybutyrate/acetoacetate (H/A) ratio with paradoxical postprandial ketosis, hypercitrullinemia and hyperammonemia, with low glutamine, parameters that often remain unaltered in types A and C.

Hence, the possibility of PC deficiency should be considered in any child presenting with lactic acidosis and neurological abnormalities, especially if associated with hypoglycaemia, hyperammonaemia or ketosis. In neonates, a high L/P ratio associated with a low H/A ratio is nearly pathognomonic [2]. Discovery of cystic periventricular leukomalacia at birth associated with lactic acidosis is also highly suggestive. Typically, blood lactate increases in the fasting state and decreases after ingestion of carbohydrate.

In patients with type B, blood lactate concentrations reach 10–20 mM (normal <2.2 mM) with L/P ratios between 50 and 100 (normal lower <15). In patients with type A, blood lactate is 2–10 mM with normal or only moderately increased L/P ratio (less than 50). In patients with type C, lactate can be normal and only increase (usually above 10 mM) during acute episodes. Overnight blood glucose concentrations are usually normal. Hypoglycaemia can occur during acute episodes of metabolic acidosis. The blood H/A ratio is decreased (less than 2, normal 2.5–3).

Hyperammonaemia (100–600 $\mu\text{mol/L}$, normal <50), and an increase of blood citrulline (100–400 $\mu\text{mol/L}$, normal <40), lysine and proline, contrasting with low glutamine, are constant findings in patients with type B [2]. Plasma alanine is usually normal in type B, but increased (500–1400 $\mu\text{mol/L}$, normal <450) in all reported patients with type A. During acute episodes, aspartate can be very low [10]. An elevation of total cholesterol or its precursors (mevalonic acid) may occur in type A and B forms [1].

In cerebrospinal fluid (CSF), lactate, the L/P ratio and alanine are increased and glutamine is decreased. High levels of homovanillic acid (a metabolite of dopamine) in the CSF and low staining of GABAergic markers in the substantia nigra have been found in a type B patient [11].

Mutation analysis is now usually used for confirmation of the diagnosis and prenatal diagnosis.

Measurement of PC activity may be performed on cultured skin fibroblasts using $^{14}\text{CO}_3\text{HNa}$. Residual PC enzymatic activity is of limited value for the distinction among the 3 phenotypes because enzymatic analysis often yields activities below 5% of normal regardless of PC deficiency type [1]. But measurement of PC activity can prove if an unknown variant impairs PC activity.

11.1.5 Treatment and Prognosis

Outcomes of treated patients exhibiting the severe A and B forms are very poor. Patients should be promptly treated with intravenous 10% glucose with appropriate electrolytes and may require bicarbonate in the setting of severe metabolic acidosis ($\text{pH}<7.0$). In one patient with the French phenotype who was treated with high doses of citrate and aspartate [10], lactate and ketones diminished and plasma amino acids normalized, except for arginine. However, in the CSF, glutamine remained low and lysine elevated. An orthotopic hepatic transplantation completely reversed ketoacidosis and the renal tubular abnormalities and decreased lactic acidemia in a patient with a severe phenotype, although concentrations of glutamine in CSF remained low [12]. A patient with type B was started on early treatment with triheptanoin, a triglyceride containing three 7-carbon fatty acids (4 g of triheptanoin/kg body weight, providing 35% of total caloric intake) in order to restore anaplerosis by providing the intramitochondrial source of both oxaloacetate and acetyl-CoA [13]. Lactate, the L/P ratio, ammonia, and citrulline decreased rapidly with a progressive increase in glutamine. Although there was a clinical improvement without evidence of neurodegeneration, the patient died during an episode of acute decompensation at 8 months of age. Two further patients with type B have been reported to be unsuccessfully treated with triheptanoin, continuously from 11 and 21 days of age. They also received citrate, aspartate and dichloroacetate. No clinical or biochemical improvement was observed and the patients died at 7 and 8 months of age respectively with a severe neurological impairment [14].

Neither biotin, thiamine, dichloroacetate, high-fat diet nor high-carbohydrate diet has been shown to provide clinical benefit. PC deficiency is a contraindication for a ketogenic diet, since this would increase paradoxical ketosis due to decreased oxaloacetate availability.

Symptomatic treatment of seizures must be undertaken with caution since valproic acid and barbiturates have adverse effects in patients with energy defects. Exacerbation of lactic acidosis and increase of alanine, lysine and leucine have been reported with the use of ACTH in a type B patient with infantile spasms [1].

11.2 Phosphoenolpyruvate Carboxykinase Deficiency (PEPCK)

Six patients with this gluconeogenesis disorder have been described: they all have a deficiency of cytosolic phosphoenolcarboxykinase (PEPCK) confirmed at molecular level. Biallelic mutations in PCK1 induce recurrent illness or fasting-related hypoglycaemia with ketonuria and inconstant lactic acidemia. In one patient, an inaugural episode of liver failure with hyperammonaemia and encephalopathy has been resolved by dextrose administration. The neurological development was not altered [15;16;17].

Reduced activity of the mitochondrial PEPCK is now considered as a secondary phenomenon.

Structure and Activation/Deactivation System of the Pyruvate Dehydrogenase Complex

PDHC, and the two other mitochondrial 2-ketoacid dehydrogenases, KDHC and the BCKD complex, are similar in structure and analogous or identical in their specific mechanisms. They are composed of three components: E1, 2-ketoacid dehydrogenase; E2, dihydrolipoamide acyltransferase; and E3, dihydrolipoamide dehydrogenase. E1 is specific for each complex, utilizes thiamine pyrophosphate, and is composed of two different subunits, E1 α and E1 β . The E1 reaction results in decarboxylation of the specific 2-ketoacid. For the PDHC, the E1 component is the rate-limiting step and is regulated by phosphorylation/dephosphorylation catalysed by two enzymes, E1 kinase (inactivation) and E1 phosphatase (activation). E2 is a transacetylase that utilises covalently bound lipoic acid. E3 is a flavoprotein common to all three 2-ketoacid dehydrogenases. Another important structural component of the PDHC is E3-binding protein (E3BP), formerly protein X. This component has its role in attaching E3 subunits to the core of E2 (● Fig. 11.2, ● Fig. 11.3).

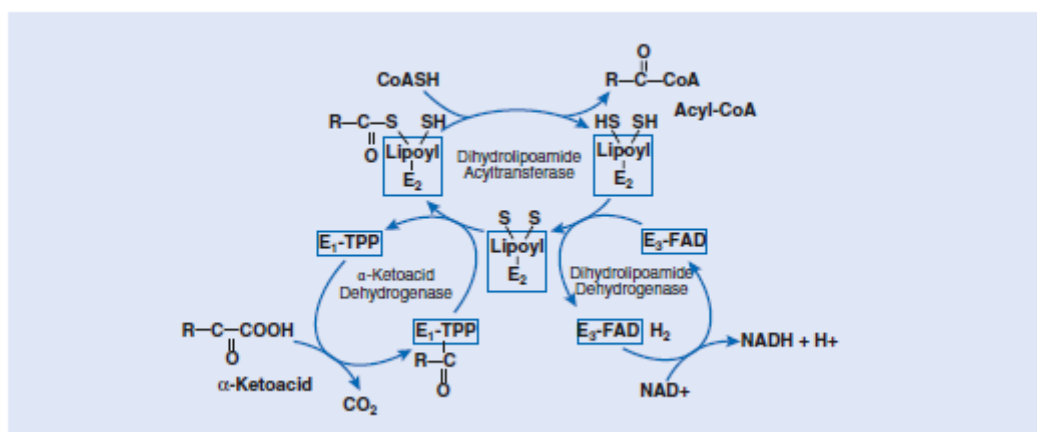


Fig. 11.2 Structure of the 2-ketoacid dehydrogenase complexes, pyruvate dehydrogenase complex (PDHC), 2-ketoglutarate dehydrogenase complex (KDHC) and the branched-chain α -ketoacid dehydrogenase complex (BCKD). CoA, coenzyme A; FAD, flavin adenine dinucleotide; NAD, nicotinamide adenine dinucleotide; R, methyl group (for pyruvate, PDHC) and the corresponding moiety for KDHC and BCKD; TPP, thiamine pyrophosphate

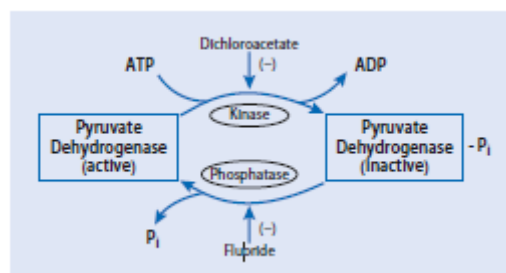


Fig. 11.3 Activation/deactivation of PDHE1 by dephosphorylation/phosphorylation. Dichloroacetate is an inhibitor of E1 kinase, and fluoride inhibits E1 phosphatase. ADP, adenosine diphosphate; P, phosphate

11.3 Pyruvate Dehydrogenase Complex Deficiency (PDHC)

11.3.1 Clinical Presentation

In a recent review, about 466 cases of PDHC deficiency have been reported [18] representing 74.2% of patients with a pyruvate oxidation disorder. Among them, 77% have a defect of the E1 α subunit (● Fig. 11.2). The most common symptoms of PDHE1 α deficiency are delayed development, hypotonia, seizures and ataxia.

In hemizygous males, three presentations are encountered: neonatal lactic acidosis, Leigh's encephalopathy and intermittent ataxia. These correlate with the severity of the biochemical deficiency and the location of the gene mutation. In the first presentation, neonatal lactic acidosis is often associated with brain dysgenesis, such as agenesis of the corpus callosum. In Leigh's encephalopathy, quantitatively the most important group, the initial presentation is usually within the first 5 years of life and includes respiratory disturbances or episodic weakness and ataxia with absence of tendon reflexes. Respiratory disturbances may lead to apnoea, dependence on assisted ventilation or sudden unexpected death. Intermittent dystonic posturing of the lower limbs occurs frequently. A moderate to severe developmental delay may manifest within the next few years. A very small subset of male patients is initially much less severely affected, with intermittent episodic ataxia after carbohydrate-rich meals, progressing slowly over years into mild Leigh's encephalopathy.

A number of patients have developed an acute flaccid neuropathy mimicking Guillain syndrome during infancy or an acute episodic ataxia [19][20], without mental retardation. Isolated optic atrophy with acute peripheral neuropathy can also be a late presenting finding [21].

Females with PDHE1 α deficiency tend to have a more uniform clinical presentation, although with variable severity, depending on variable X chromosome lyonization [22]. This includes dysmorphic features, microcephaly, moderate to severe mental retardation and spastic di- or quadriplegia, resembling non progressive encephalopathy. Dysmorphism comprises a narrow head with frontal bossing, wide nasal bridge, upturned nose, long philtrum and flared nostrils resembling fetal alcohol syndrome. Other features are low-set ears, short fingers and short proximal limbs, simian creases, hypospadias and an anteriorly placed anus. Seizures are encountered in almost all female patients. These appear within the first 6 months of life and are diagnosed as infantile spasms (flexor and extensor) or severe myoclonic seizures. Brain MRI frequently reveals severe cortical/subcortical atrophy, dilated ventricles, partial to complete corpus callosum agenesis [23]. Severe neonatal lactic acidosis can be present. An isolated paroxysmal exercise dystonia responding to thiamine was also seen in a female [24].

Males and females who are mosaic for PDHE1 α deficiency have been reported with an attenuated phenotype [25].

Neuropathology can reveal various degrees of dysgenesis of the corpus callosum usually associated with migration defects, such as the absence of the medullary pyramids, ectopic olivary nuclei, abnormal Purkinje cells in the cerebellum, dysplasia of the dentate nuclei, subcortical heterotopias and pachygyria [26].

In the rare reports of antenatal forms related to PDHE1 deficiency, fetal sonography and MRI displayed brain dysgenesis with enlargement of the lateral ventricles [27]. Postmortem examination showed clastic and neurodevelopmental lesions with a cranial dysmorphism [28].

The phenotype of the PDHE1 β deficiency is quite similar to that of the PDHE1 α deficiency [18]. About 20 patients were reported either with early-onset lactic acidosis and severe developmental delay or

with a moderate clinical course with slowly progressive neurological features reflecting basal ganglia and brain stem involvement associated with typical findings of Leigh syndrome [29].

Seven cases of PDHE2 (dihydrolipoamide transacetylase) deficiency have been described [30; 31; 32]. The phenotypic spectrum encompasses severe developmental delay with lactic acidosis to mild motor disability and moderate intellectual disability. Episodic dystonia is frequently observed whereas other neurological features like hypotonia are often less prominent. Bilateral lesions in the globus pallidus have been found in neuroradiological imaging. Lactate in blood is normal or slightly elevated.

The main clinical manifestations of E3BP (formerly protein X) deficiency are hypotonia, delayed psychomotor development and prolonged survival [18]. Often more slowly progressive, it also comprises early-onset neonatal lactic acidosis associated with subependymal cysts and thin corpus callosum and/or Leigh disease [33].

E1-phosphatase deficiency is very rare (● Fig. 11.3). Four cases with molecular identification of variants have been described with hypotonia, feeding difficulties and delayed psychomotor development [34].

11.3.2 Metabolic Derangement

Defects of PDHC provoke conversion of pyruvate into lactate and alanine rather than to acetyl-CoA, the gateway for complete oxidation of carbohydrate via the TCA cycle (● Fig. 11.1). The conversion of glucose to lactate yields less than one tenth of the ATP that would be derived from complete oxidation of glucose via the TCA cycle and the respiratory chain. Deficiency of PDHC thus specifically interferes with production of energy from carbohydrate oxidation, and hyperpyruvicaemia, lactic acidemia and hyperalaninaemia are aggravated by consumption of carbohydrate.

PDHC deficiency impairs production of NADH but, unlike respiratory chain or MAS defects, does not hamper oxidation of NADH. PDHC deficiency thus does not modify the NADH/NAD⁺ ratio in the cell cytosol, which is reflected in a normal L/P ratio both in blood and CSF. In contrast, deficiencies of respiratory chain complexes are generally characterised by a high L/P ratio (Chapter 1 and Chapter 14).

11.3.3 Genetics

All components of PDHC are encoded by nuclear genes, and synthesized in the cytoplasm as precursor proteins that are imported into the mitochondria, where the mature proteins are assembled into the enzyme complex. PDHA1 coding for E1 α -subunit is located on the X chromosome; therefore, most cases of PDHC deficiency are X-linked. To date, over 166 different mutations of PDHA1 have been characterized [35; 36; 37; 38]. About half of these are small deletions, insertions or frame-shift mutations, and the other half are missense mutations. Premature termination codons, mostly resulting from frame-shift insertions or deletions in exons 10 and 11, are frequently noted in females, while missense mutations predominate in males [36]. No null E1 α mutations have been identified in males, except in a mosaic state [25], suggesting that such mutations are likely to be lethal. Rare splicing mutations involve exonic [39] or intronic [40] regulatory sequences. A few large rearrangements have been identified, such as a large intragenic 5 kb deletion [41]. In only about 25% of cases was the mother of a child with PDHE1 α deficiency a carrier of the mutation. Therefore, since most cases of PDHC deficiency appear to be the consequence of new E1 α mutations, the overall rate of recurrence within any one same family is low.

Mutations in PDHB are a very rare cause of PDHC deficiency [18][42]. A deficiency in a patient was due to an increased proteasome-mediated degradation of the ubiquitinated E1 β subunit [43].

Mutations in the PDHX gene encoding the E3BP subunit are the second most frequent molecular cause of PDHC deficiency. All pathogenic mutations are truncating mutations. A founder mutation was found in a group of Roma children with cerebral palsy as clinical picture [44]. Other patients carry private mutations [45; 46]. Two large rearrangements have been identified, one of them due to retrotranspositional insertion of a full-length LINE-1 element [47].

Mutations in DLAT encoding E2 subunit [30; 31] and in the pyruvate dehydrogenase phosphatase gene (PDP1) [48; 49] have also been identified.

Activating mutations in the pyruvate dehydrogenase kinase isoenzyme 3 (PDK3) gene have been found to cause X-linked dominant Charcot-Marie-Tooth disease type 6. Findings suggest a reduced pyruvate flux due to Arg158His mutant PDK3-mediated hyper-phosphorylation of the PDHC as the underlying pathogenic cause of peripheral neuropathy [50; 51].

11.3.4 Diagnostic Tests

The most important laboratory test for initial recognition of PDHC deficiency is the measurement of lactate and pyruvate in blood and CSF. In PDHC deficiency, CSF lactate concentrations are generally raised and in excess of blood lactate [52]. Quantitative analysis of plasma amino acids and urinary organic acids may also be useful. Blood lactate, pyruvate and alanine can be intermittently normal when measured after an overnight fast, but characteristically an increase is observed after an oral carbohydrate load. While the L/P ratio is almost always normal, a high ratio can be found if the patient is acutely ill, if blood is very difficult to obtain, or if the measurement of pyruvate (which is unstable) is not done reliably. The practical solution allowing avoidance of these artefacts is to obtain several samples of blood, including samples collected under different dietary conditions (during an acute illness, after overnight fasting, and postprandially after a high-carbohydrate meal) (Chapter 1 and Chapter 3). Glucose tolerance or carbohydrate loading tests are not necessary for a definite diagnosis. In contrast to PC deficiency, fasting hypoglycaemia is not an expected feature of PDHC deficiency, and blood lactate and pyruvate usually decrease after fasting.

Molecular analysis of PDHC genes is often more efficient than measuring the enzyme activity. The most commonly used material for assay of PDHC activity is cultured skin fibroblasts. PDHC can also be assayed in lymphocytes, separated from EDTA-blood, after less than 2 days. PDHC is commonly assayed by measuring the release of $^{14}\text{CO}_2$ from $[1-^{14}\text{C}]$ pyruvate in cell homogenates and tissues. PDHC activity should be measured at low and high TPP concentrations to detect thiamine-responsive PDHC deficiency [53]. PDHC must also be activated (dephosphorylated; ● Fig. 11.3), which can be done by preincubation of whole cells or mitochondria with dichloroacetate (DCA, an inhibitor of the kinase; ● Fig. 11.3). In E1-phosphatase deficiency there is a deficiency in native PDH activity, but on activation of the PDH complex with DCA, activity becomes normal. The three catalytic components of PDHC can be assayed separately. Immunoblotting of the components of PDHC can help distinguish whether a particular protein is missing. In females with PDHE1 α deficiency, X inactivation can interfere with the biochemical analysis. E3BP, which anchors E3 to the E2 core of the complex, can only be evaluated using immunoblotting, since it has no catalytic activity [45].

11.3.5 Treatment and Prognosis

The prognosis for individuals with PDHC deficiency is generally poor, and treatment is not very effective. Experience with early prospective treatment to prevent irreversible brain injury is lacking. Perhaps the most rational strategy for treating PDHC deficiency is the use of a ketogenic diet [54] (Chapter 13). Oxidation of fatty acids, 3-hydroxybutyrate and acetoacetate are providers of alternative sources of acetyl-CoA. In a series of males with PDHC deficiency caused by identical PDHA1 mutations

it was found that the earlier the ketogenic diet was started and the more severe the restriction of carbohydrates, the better was the outcome for mental development and survival [55]. Thiamine has been given in variable doses (500–2,000 mg/day), with lowering of blood lactate and apparent clinical improvement in some patients [21; 56] (Chapter 29).

DCA offers another potential treatment for PDHC deficiency. DCA, a structural analogue of pyruvate, inhibits E1 kinase, thereby keeping any residual E1 activity in its active (dephosphorylated) form (● Fig. 11.3). DCA can be administered orally or parenterally usually at doses of 10-50 mg/kg/day. Of note, reversible sensory-motor peripheral neuropathy is a clinically limiting adverse effect of chronic DCA treatment [57]. Chronic DCA treatment was shown to be beneficial in some patients, improving the function of PDHC, and this has been related to specific DCA-sensitive mutations [58]. Sporadic reports have also shown a beneficial effect of concomitant DCA and high-dose thiamine (500 mg). A ketogenic diet and thiamine should thus be tried in each patient. DCA can be added in the setting of severe lactic acidosis, in acute situations. Phenylbutyrate in combination with DCA has shown to increase PDH activity in mice [59]. Fibroblasts of patients with PDHC deficiency and missense mutations responded with increase of activity when incubated with phenylbutyrate [60].

11.4 Dihydrolipoamide Dehydrogenase Deficiency (DLD)

11.4.1 Clinical Presentation

Approximately 30 cases of DLD (E3) deficiency have been reported. Since this enzyme is common to all the 2-ketoacid dehydrogenases (● Fig. 11.2), E3 deficiency results in multiple 2-ketoacid-dehydrogenase deficiency and should be thought of as a combined PDHC and TCA cycle defect. E3 deficiency phenotype is a continuum that ranges from early-onset neurological impairment to late-onset isolated liver disease. The most frequent presentation is severe and progressive hypotonia and failure to thrive, starting in the first months of life. Metabolic decompensations are triggered by infections. Progressively, hypotonia, psychomotor retardation, microcephaly and spasticity occur. Some patients develop a typical picture of Leigh's encephalopathy. In a few cases, the main clinical picture is a Reye-like syndrome characterized by recurrent bouts of liver failure frequently associated with encephalopathy. In two patients, the clinical presentation was primarily myopathic [61; 62].

11.4.2 Metabolic Derangement

DLD (E3) is a flavoprotein shared by all three mitochondrial 2-ketoacid dehydrogenase complexes (PDHC, KDHC and BCKD; ● Fig. 11.3). It is also the L component of the Glycine cleavage system (chapter 23).

The predicted metabolic manifestations for E3 deficiency are the result of the deficiency state for each enzyme: increased blood lactate and pyruvate, elevated plasma alanine, glutamate, glutamine and branched-chain amino acids (leucine, isoleucine, valine and often alloisoleucine), and increased urinary lactic, pyruvic, 2-ketoglutaric acids, branched-chain 2-hydroxy- and 2-ketoacids.

11.4.3 Genetics

DLD mutations are inherited as an autosomal recessive trait. The disease-causing mutations occur at different locations in the enzyme and affect preferentially either the reactive oxygen species generation or the affinity for the multienzyme complex that may explain variable phenotypic expression [63].

The p.Gly229Cys mutation is the major cause of E3 deficiency in Ashkenazi Jewish patients and in patients from the Middle East and the Maghreb and is often associated with the liver phenotype [64].

11.4.4 Diagnostic Tests

The initial diagnostic screening should include analyses of blood lactate and pyruvate, plasma amino acids, and urinary organic acids. However, the pattern of metabolic abnormalities is not seen in all patients or at all times in the same patient, making the diagnosis more difficult [65]. This is especially true for elevation of blood branched-chain amino acids concentrations which are rarely and moderately elevated.

In cultured skin fibroblasts, blood lymphocytes, or other tissues, the E3 component can be assayed using a spectrophotometric method. Clinical severity does not parallel the loss in E3 activity.

11.4.5 Treatment and Prognosis

There is no dietary treatment for E3 deficiency although restriction of dietary branched-chain amino acids was reportedly helpful in one case. dl-Lipoic acid has been tried, but its efficacy remains controversial [66]. Riboflavin was successful in correcting the myopathic phenotype in a patient with DLD deficiency and a chaperone effect was discussed [62].

11.5 2-Ketoglutarate Dehydrogenase Complex Deficiency (KDHC)

11.5.1 Clinical Presentation

Isolated deficiency of KDHC has been reported in several unrelated families. As in PDHC deficiency, the primary clinical manifestations included developmental delay, hypotonia, ataxia, opisthotonos and, less commonly, seizures and extrapyramidal dysfunction. On MRI, bilateral striatal necrosis can be found compatible with Leigh syndrome. In one patient the clinical picture was mild: during the first months of life, he developed opisthotonos and axial hypertonia, which improved with age. All patients presented in the neonatal period and early childhood [67].

11.5.2 Metabolic Derangement

KDHC is a 2-ketoacid dehydrogenase that is analogous to PDHC and BCKD (● Fig. 11.2). It catalyzes the oxidation of 2-ketoglutaric acid (2-KGA) to yield CoA and NADH. The E1 component, 2-ketoglutarate dehydrogenase, is a substrate-specific dehydrogenase that utilises thiamine and is composed of two different subunits. In contrast to PDHC, the E1 component is not regulated by phosphorylation/dephosphorylation. The E2 component, dihydrolipoyl succinyl-transferase, is also specific to KDHC and includes covalently bound lipoic acid. The E3 component is the same as for PDHC. An E3-binding protein has not been identified for KDHC. Since KDHC is integral to the TCA cycle, its deficiency has consequences similar to those of other TCA enzyme deficiencies.

11.5.3 Genetics

KDHC deficiency is inherited as an autosomal recessive trait. OGDH encodes the E1 component and DLST the E2 component. Before the identification of the molecular defects in OGDH in 2020, the diagnosis was solely confirmed by an enzymatic spectrophotometric assay in cultured skin fibroblasts.

11.5.4 Diagnostic Tests

Urinary organic acid analysis can show increased excretion of 2-KGA with or without concomitantly increased excretion of other TCA cycle intermediates. However, mildly to moderately increase of urinary 2-KGA is a common finding and not a specific marker of KDHC deficiency. Some patients with KDHC deficiency also have increased blood lactate with normal or increased L/P ratio. Plasma glutamate and glutamine may be increased.

11.5.5 Treatment and Prognosis

There is no known effective treatment.

11.6 Succinyl-CoA Ligase Deficiency (SUCL) Succinyl-CoA ligase deficiency

Succinyl-CoA ligase (SUCL) converts succinyl-CoA and GDP or ADP to succinate and GTP or ATP in the TCA cycle. This process, known as substrate-level phosphorylation, allows the formation of high energy-phosphates (GTP or ATP) in the absence of oxygen. A complex of SUCL with a nucleotide diphosphate kinase (NDPK) is also involved in mtDNA maintenance. Succinyl-CoA ligase is composed of an α -subunit (encoded by SUCLG1) and two β -subunits (encoded by SUCLA2 and SUCLG2). The substrate specificity for ADP or GDP is determined by the β -subunit, whereas the α -subunit is shared. SUCL deficiency causes mild methylmalonic aciduria, variable lactic acidosis, accumulation of succinylcarnitine and mitochondrial DNA depletion (Chapter 14). Patients with different genetic backgrounds have been found to have mutations in SUCLA2, and in SUCLG1 [68]. The clinical picture in patients with SUCLA2 mutations is highly homogeneous and comprises early-onset encephalomyopathy, dystonia, deafness and Leigh-like MRI abnormalities. Patients with SUCLG1 mutations are clinically heterogeneous, showing either a severe form with neonatal multiorgan failure and early death or a phenotype similar to those with SUCLA2 mutations. Hypertrophic cardiomyopathy and liver involvement are exclusively found in patients with SUCLG1 mutations [68].

11.7 Succinate Dehydrogenase Deficiency (SDH)

Succinate dehydrogenase (SDH) is part of both the TCA cycle and the respiratory chain, which explains why SDH deficiency resembles more the phenotypes associated with defects of the respiratory chain (Chapter 14).

The clinical picture of this very rare disorder is highly variable. Some patients have multisystem involvement, whereas others have only isolated cardiac or muscle injury with onset in adulthood and normal development. Neurological findings are the most frequent and include developmental regression following acute illness, initial hypotonia and spasticity. Severe cardiomyopathy (dilated or hypertrophic) is frequently reported. Ophthalmologic features include ophthalmoplegia, retinopathy, nystagmus, optic atrophy, and blindness [69]. Early-onset leukoencephalopathy with spasticity and motor regression involvement were reported in SDHA, SDHB [70; 71] and in deficiency of the assembly factor SDHAF1 [72].

Specific thalamus and brainstem MRI patterns observed in a cohort of 19 patients seem to be unique for the SDH-related leukoencephalopathy and to allow differentiation from other mitochondrial leukoencephalopathies [73]. Another specific but inconstant finding is accumulation of succinate in affected white matter seen at MRS [73].

SDH is part of a larger enzyme unit, complex II (succinate-ubiquinone oxidoreductase) of the respiratory chain. Complex II is composed of four subunits: the flavoprotein SDHA catalyzes the

oxidation of succinate to fumarate (formally, the 'succinate dehydrogenase' activity) (● Fig. 11.1); the iron-sulfur protein SDHB transfers electrons to the ubiquinone pool of the respiratory chain (the 'succinate-coenzyme Q reductase' activity); SDHC and SDHD subunits are anchoring proteins. In addition, SDHAF1 and SDHAF2 factors are required for correct assembly. Complex II is unique among the respiratory chain complexes in that all four of its subunits are nuclearly encoded.

SDHA mutations are the most common causes of isolated complex II deficiency, followed by SDHAF1 mutations. SDHB and SDHD mutations have been reported in only ten and two patients respectively [69 ; 74 ; 75]. Metabolic presentations have yet to be reported in associations with SDHC or SDHAF2. A myopathic phenotype observed first in Swedish patients with combined defects of SDH and aconitase is due to defects in separate iron-sulfur cluster encoding genes (chapter 14). As SDH plays a role as a tumor suppressor, a germline heterozygous mutation associated with a loss of heterozygosity of the wild type allele in the tumoral tissue induces pheochromocytoma or paraganglioma [76] (see fumarase deficiency, next section).

Lactic acidosis and elevated CSF lactate are inconstant findings and, in contrast to the other TCA cycle disorders, SDH deficiency does not always lead to a characteristic organic aciduria [69]. Diagnostic confirmation of a suspected SDH deficiency requires mitochondrial respiratory chain Complex II activity assay, by spectrophotometric procedures.

As SDHA is a flavoprotein, administration of riboflavin, a precursor of FAD, has been tested in some patients but a few of them have exhibited an improvement of their neurological conditions [69].

11.8 Fumarase Deficiency (FH)

Fewer than 100 patients with fumarase deficiency have been reported [77]. Most of the patients present in infancy with a severe encephalopathy, hypotonia, failure to thrive and seizures, poor neurological outcome and profound mental retardation. Dysmorphic features such as frontal bossing, hypertelorism and depressed nasal bridge were noted. Milder cases with developmental delay and epilepsy resembling non progressive cerebral palsy have also been reported.

Neuropathological changes include mainly ventriculomegaly with hydrocephaly and cerebral atrophy, Cortical malformations, polymicrogyria, have also been reported.

Antenatal manifestations include polyhydramnios, congenital hydrocephalus and premature birth [78].

Fumarase catalyzes the reversible interconversion of fumarate and malate (● Fig. 11.1). Its deficiency, like other TCA cycle defects, causes: (1) impaired energy production due to interruption in the flow of the TCA cycle and (2) potential secondary enzyme inhibition associated with accumulation in various amounts of metabolites proximal to the enzyme deficiency, such as fumarate, succinate, 2-KGA and citrate (● Fig. 11.1).

FH (the gene encoding for fumarase) mutations are inherited as an autosomal recessive trait. A single gene, encodes alternately translated transcripts to generate a mitochondrial and a cytosolic isoform. Heterozygous germline mutations in the fumarase gene are associated with a predisposition to cutaneous and uterine leiomyomas and to kidney [76]. As for succinate dehydrogenase (SDH) deficiency (see section above), fumarase and SDH loss of enzyme activity are solely observed in the tumoral tissues. This is due to the combination of a germline mutation (heterozygosity) with a somatic

loss of heterozygosity in the other allele (in the tumour). A similar mechanism is observed in focal forms of hyperinsulinism (Chapter 9).

The biological key finding is increased urinary fumaric acid, sometimes associated with increased excretion of succinic acid and 2-KGA. Fumarase enzyme activity can be assayed in mononuclear blood leukocytes or cultured skin fibroblasts, using a spectrophotometric method.

There is no specific treatment. A ketogenic diet is usually considered to be contraindicated for treating epilepsy associated with FH deficiency or other enzymatic defects within the TCA cycle, since the reduced TCA activity could impair the condensation of acetyl-CoA produced from fatty acids beta-oxidation with oxaloacetate. However, a milder course has been reported in one patient with early introduction of a high fat/low carbohydrates diet [79].

11.9 Mitochondrial Aconitase deficiency (ACO)

About thirty cases of mitochondrial aconitase deficiency due to biallelic ACO2 mutations have been reported with a large clinical spectrum ranging from infantile cerebellar and retinal degeneration (ICRD) with progressive microcephaly to isolated late onset optic atrophy. The correlation between the residual activity and the phenotypic severity is not fully consistent [80; 81]. Plasma metabolomics in eight patients identified a metabolic fingerprint of aconitase deficiency (decrease of cis-aconitate, isocitrate, 2-ketoglutarate, phosphoenol pyruvate and hydroxybutyrate) [82].

11.10 Mitochondrial Isocitrate Dehydrogenase deficiency (IDH)

Biallelic mutations in IDH3A and IDH3B encoding the A and B subunits of mitochondrial NAD⁺-specific isocitrate dehydrogenase (IDH3) have been found to be associated with nonsyndromic retinitis pigmentosa in 3 families [83]. One case of IDH3 deficiency was also described associated with severe encephalopathy, hypotonia and autonomic dysregulation [84]. Patients with somatic mutations in the gene encoding for the cytosolic NADP⁺-specific IDH1 or in the gene encoding for the mitochondrial NADP⁺-specific IDH2 have presented with malignant gliomas, acute myeloid leukaemia, or cholangiosarcoma [85]. These somatic point mutations in IDH1/2 alter the enzymes normal ability to convert isocitrate to 2-KGA and confer to the enzymes a new function: the ability to convert 2-KGA to d-2-hydroxyglutarate (D-2HG) an oncometabolite. Conversely, heterozygous germline mutations in IDH2 were identified in patients with d-2-hydroxyglutaric aciduria (D-2-HGA), a rare neurometabolic disorder characterized by supraphysiological levels of D-2HG [86]. Cancer has not been reported in these patients (Chapter 22).

11.11 Malate-aspartate shuttle defects (MAS)

Defects in some components of the malate-aspartate shuttle were described, with highly similar neurological phenotypes. Patients all exhibited early infantile progressive epileptic encephalopathies with microcephaly.

A defect of the mitochondrial aspartate glutamate carrier AGC1 encoded by SLC25A12 was first described [87] and has now been reported in four additional children [88; 89]. Brain MRI revealed hypomyelination, probably due to the lack of N-acetylaspartate. A ketogenic diet was initiated in one patient with a clear beneficial effect, probably by reducing the glycolytically generated NADH that

shifts the equilibrium of the MAS [90]. Defects in AGC2 (SLC25A13) are involved in type II citrullinemia (Chapter 19).

A homozygous mutation of MDH1 encoding the cytosolic MDH was recently described in two related children [91]. The absence of hyperlactataemia and increased blood glycerol-3-phosphate levels in both patients suggested a compensatory effect of the G3P shuttle.

Biallelic mutations in MDH2 encoding the mitochondrial MDH were described in three unrelated patients with increased lactate in blood and CSF [92]. Despite disruption of the TCA cycle, nearly normal concentrations of urinary organic acids were observed in these patients. A ketogenic diet has appeared to decrease the frequency of epileptic seizures for the two children. MDH2 was also identified as a pheochromocytoma and paraganglioma susceptibility gene [93]. Loss of heterozygosity of the wild type allele and significant reduction of MDH activity were observed in the tumours.

GOT2 deficiency has been identified in four children with variants of GOT2. Hyperlactataemia, mild hyperammonemia and citrullinemia were observed in these patients. The intramitochondrial synthesis of aspartate from oxaloacetate is decreased in GOT2 deficiency leading to lower concentrations of aspartate in the cytosol and reduced arginosuccinate synthesis with citrulline accumulation and hyperammonemia. Serine biosynthesis is also hampered by the impaired cytosolic redox imbalance. Treatment with pyridoxine (to activate residual GOT2 activity) and serine fully controlled seizures in two of these patients [94].

11.12 Mitochondrial citrate carrier deficiency

This disorder is responsible for D-2- and L-2-Hydroxyglutaric Aciduria (Chapter 22)

11.13 Mitochondrial pyruvate carrier deficiency (MPC)

MPC1 mutations have been described in 5 cases [95; 96]. Neonatal lactic acidosis in a female baby born to consanguineous parents was associated with generalized hypotonia and facial dysmorphism. Brain MRI revealed cortical atrophy, periventricular leukomalacia and calcifications. Progressive microcephaly, failure to thrive and neurological deterioration led to death at age 19 months. An affected fetus was found in a subsequent pregnancy. Three other patients with a mild progressive encephalopathy have been identified in consanguineous families of North African descent.

The mitochondrial pyruvate carrier (MPC) is a hetero-oligomer consisting in two obligate subunits encoded by the MPC1 and MPC2 genes. MPC mediates the proton symport of pyruvate across the inner mitochondrial membrane. Consequently, the metabolic derangement should be the same as in pyruvate dehydrogenase deficiency.

High lactate and pyruvate are found with normal L/P ratio. To evidence the transport defect, [2-14C] pyruvate oxidation is measured in digitonin-permeabilised versus disrupted fibroblasts. Digitonin induces outer cell membrane permeabilisation, leaving intracellular mitochondrial membranes intact. Oxidation of 2-14C-pyruvate is severely impaired in digitonin-permeabilised fibroblasts but not in disrupted cells. No treatment is known to date.

11.14 NAD(P)HX system repair defects

Deficiencies in the enzymes that repair the damages induced by water addition on reduced forms of pyridine dinucleotides have been recently discovered [97]. Hydration of NAD(P)H occurs spontaneously at high temperature or as a side effect of GAPDH, giving rise to hydrates NAD(P)HX which have lost their ability to exchange electrons and may inhibit several dehydrogenases. NAD(P)HX are prone to an irreversible cyclisation but the NAD(P)HX repair system allows the reconversion of both epimers S and R of NAD(P)HX to normal cofactors : a NAD(P)HX epimerase encoded by NAXE converts the S-form of NAD(P)HX in the R-form and a NAD(P)HX dehydratase encoded by NAXD dehydrates the R-form. Inactivating mutations have been discovered in both NAXE and NAXD [97, 98]. Most patients with a NAD(P)H system repair defect present with infantile progressive lethal encephalopathy, with skin lesions, elevated lactate in cerebrospinal fluid and episodes of deterioration triggered by fever episodes. Patients with onset in adulthood and a milder course have also been reported. Administration of high doses of vitamin D3 (nicotinamide) has been suggested as a treatment strategy [97] and has been shown to stabilize milder forms [99]

11.15 Protein-bound lipoic acid defect and defects in cofactors

See Chapter 23 and Chapter 29.

References

- [1] Marin-Valencia I, Roe CR, Pascual JM (2010) Pyruvate carboxylase deficiency: mechanisms, mimics and anaplerosis. *Mol Genet Metab* 101:9–17
- [2] Garcia-Cazorla A, Rabier D, Touati G et al. (2006) Pyruvate carboxylase deficiency: metabolic characteristics and new neurological aspects. *Ann Neurol* 59:121–127
- [3] Ostergaard E, Duno M, Møller LB et al. (2013) Novel Mutations in the PC Gene in Patients with Type B Pyruvate Carboxylase Deficiency. *JIMD Rep* 9:1–5
- [4] Egloff C, Eldin de Pecoulas A, Mechler C et al. (2018) Prenatal sonographic description of fetuses affected by pyruvate dehydrogenase or pyruvate carboxylase deficiency. *Prenat Diagn* 8: 607-616
- [5] Murin R, Cesar M, Kowtharapu BS et al. (2009) Expression of pyruvate carboxylase in cultured oligodendroglial, microglial and ependymal cells. *Neurochem Res* 34:480–489
- [6] Park LC, Zhang H, Sheu KF et al. (1999) Metabolic impairment induces oxidative stress, compromises inflammatory responses, and inactivates a key mitochondrial enzyme in microglia. *J Neurochem* 72:1948–1958
- [7] Unal O, Orhan D, Ostergaard E et al. (2013) A patient with pyruvate carboxylase deficiency and nemaline rods on muscle biopsy. *J Child Neurol* 28:1505–1508
- [8] Coci EG, Gapsys V, Shur N et al. (2019) Pyruvate carboxylase deficiency type A and type C: Characterization of five novel pathogenic variants in PC and analysis of the genotype–phenotype correlation. *Hum Mutat* 6: 816-827
- [9] Wang D, Yang H, De Braganca KC et al. (2008) The molecular basis of pyruvate carboxylase deficiency: Mosaicism correlates with prolonged survival. *Mol Genet Metab* 1-2: 31-38

- [10] Ahmad A, Kahler SG, Kishani PS et al. (1999) Treatment with pyruvate carboxylase deficiency with high doses of citrate and aspartate. *Am J Med Genet* 87:331–338
- [11] Ortez C, Jou C, Cortès-Saladelafont E (2013) Infantile parkinsonism and GABAergic hypotransmission in a patient with pyruvate carboxylase deficiency. *Gene* 532:302–306
- [12] Nyhan WL, Khanna A, Barshop BA et al. (2002) Pyruvate carboxylase deficiency – insights from liver transplantation. *Mol Genet Metab* 77:143–149
- [13] Mochel F, DeLonlay P, Touati G, et al. (2005) Pyruvate carboxylase deficiency: clinical and biochemical response to anaplerotic diet therapy. *Mol Genet Metab* 84:305–312
- [14] Breen C, White FJ, Scott CA et al. (2014) Unsuccessful treatment of severe pyruvate carboxylase deficiency with triheptanoin. *Eur J Pediatr* 173:361–366
- [15] Adams DR, Yuan H, Holyoak T et al. (2014) Three rare diseases in one Sib pair: RAI1, PCK1, GRIN2B mutations associated with Smith–Magenis Syndrome, cytosolic PECK deficiency and NMDA receptor glutamate insensitivity. *Mol Genet Metab* 3: 161-170
- [16] Santra S, Cameron JM, Shyr C et al. (2016) Cytosolic phosphoenolpyruvate carboxykinase deficiency presenting with acute liver failure following gastroenteritis. *Mol Genet Metab* 1: 21-27
- [17] Vieira P, Cameron J, Rahikkala E et al. (2017) Novel homozygous PCK1 mutation causing cytosolic phosphoenolpyruvate carboxykinase deficiency presenting as childhood hypoglycemia, an abnormal pattern of urine metabolites and liver dysfunction. *Mol Genet Metab* 4: 337-341
- [18] Sperl W, Fleuren L, Freisinger P et al. (2015) The spectrum of pyruvate oxidation defects in the diagnosis of mitochondrial disorders. *J Inherit Metab Dis* 38:391–403
- [19] Strassburg HM, Koch J, Mayr J et al. (2006) Acute flaccid paralysis as initial symptom in 4 patients with novel E1-alpha mutations of the pyruvate dehydrogenase complex. *Neuropediatrics* 37:137–141
- [20] Debray FG, Lambert M, Gagne R et al. (2008) Pyruvate dehydrogenase deficiency presenting as intermittent isolated acute ataxia. *Neuropediatrics* 39:20–23
- [21] Sedel F, Challe G, Laver JM et al. (2008) Thiamine responsive pyruvate dehydrogenase deficiency in an adult with peripheral neuropathy and optic neuropathy. *J Neurol Neurosurg Psychiatry* 79:846–847
- [22] De Meirleir L, Specola N, Seneca S, Lissens W (1998) Pyruvate dehydrogenase E1-alpha deficiency in a family: different clinical presentation in two siblings. *J Inherit Metab Dis* 21:224–226
- [23] De Meirleir L (2002) Defects of pyruvate metabolism and the Krebs cycle. *J Child Neurol* 17:S26–33
- [24] Castiglioni C, Verrigni D, Okuma C, Diaz A, et al. (2015) Pyruvate dehydrogenase deficiency presenting as isolated exercise induced dystonia successfully reversed with thiamine supplementation. *Eur J Ped Neurol* 19:497–503
- [25] Deeb KK, Bedoyan JK, Wang R et al. (2014) Somatic mosaicism for a novel PDHA1 mutation in a male with severe pyruvate dehydrogenase complex deficiency. *Mol Genet Metab Reports* 1: 362-367.

- [26] Michotte A, De Meirleir L, Lissens W et al. (1993) Neuropathological findings of a patient with pyruvate dehydrogenase E1 alpha deficiency presenting as a cerebral lactic acidosis. *Acta Neuropathol (Berl)* 85:674–678
- [27] Tamaru S, Kikuchi A, Takagi K et al. (2012) A case of pyruvate dehydrogenase E1 α subunit deficiency with antenatal brain dysgenesis demonstrated by prenatal sonography and magnetic resonance imaging. *J Clin Ultrasound* 4: 234-238
- [28] Pirot N, Crahes M, Adle-Biasette H et al. (2016) Phenotypic and neuropathological characterization of fetal pyruvate dehydrogenase deficiency. *J Neuropathol Exp Neurol* 3: 227-238
- [29] Quintana E, Mayr J, Garcia Silva M et al. (2009) PDHE(1) beta deficiency with novel mutations in two patients with Leigh syndrome. *J Inherit Metab Dis* 32 (Suppl 1):S330–S343
- [30] Head R, Brown R, Zolkipli Z et al. (2005) Clinical and genetic spectrum of pyruvate dehydrogenase deficiency: dihydrolipoamide acetyltransferase (E2) deficiency. *Ann Neurol* 58:234–241
- [31] McWilliam C, Ridout C, Brown R et al. (2010) Pyruvate dehydrogenase E2 deficiency: a potentially treatable cause of episodic dystonia. *Eur J Paediatr Neurol* 14:349–353
- [32] Friedman J, Feigenbaum A, Chuang N et al. (2017) Pyruvate dehydrogenase complex-E2 deficiency causes paroxysmal exercise-induced dyskinesia. *Neurology* 22: 2297-2298
- [33] Schiff M, Miné M, Brivet M et al. (2006) Leigh's disease due to a new mutation in the PDHX gene. *Ann Neurol* 59:709-714.
- [34] BedoyanJK, Hecht L, Zhang S et al (2019). A novel mutation in the pyruvate dehydrogenase phosphatase catalytic subunit gene (PDP1) causing pyruvate dehydrogenase complex deficiency. *JIMD reports* 48:26-35
- [35] Imbard A, Boutron A, Vequaud C et al. (2011) Molecular characterization of 82 patients with pyruvate dehydrogenase complex deficiency Structural implications of novel amino acid substitutions in E1 protein. *Mol Genet Metabol* 104:507–516
- [36] Lissens W, De Meirleir L, Seneca S et al. (2000) Mutations in the X-linked pyruvate dehydrogenase (E1) α subunit gene (PDHA1) in patients with a pyruvate dehydrogenase complex deficiency. *Hum Mutat* 15:209–219
- [37] Quintana E, Gort L, Busquets C et al. (2009) Mutational study in the PDHA1 gene of 40 patients suspected of pyruvate dehydrogenase complex deficiency. *Clin Gen* 77:274–282
- [38] Ridout CK, Keighley P, Krywawych S et al. (2008) A putative exonic splicing enhancer in exon 7 of the PDHA1 gene affects splicing of adjacent exons. *Hum Mutat* 29:451
- [39] Boichard A, Venet L, Naas T et al. (2008) Two silent substitutions in the PDHA1 gene cause exon 5 skipping by disruption of a putative exonic splicing enhancer. *Mol Genet Metab* 93:323–330
- [40] Miné M, Brivet M, Touati G et al. (2003) Splicing error in E1 alpha pyruvate dehydrogenase mRNA caused by novel intronic mutation responsible for lactic acidosis and mental retardation. *J Biol Chem* 278:11768–11772
- [41] Brivet M, Moutard ML, Zater M et al. (2005) First characterization of a large deletion of the PDHA1 gene. *Mol Genet Metab* 86:456–461

- [42] Okajima K, Korotchkina L, Rupar T et al. (2008) Mutations of the E1 beta subunit gene (PDHB) in four families with pyruvate dehydrogenase deficiency. *Mol Genet Metab* 93:371–380
- [43] Han Z, Srivastava A, Stacpoole P (2008) Pyruvate dehydrogenase complex deficiency caused by ubiquitination and proteasome-mediated degradation of the E1 subunit. *J Biol Chem* 283:237–243
- [44] Ivanov IS, Azmanov DN, Ivanova MB et al. (2014) Founder p.Arg446* mutation in PDHX gene explains over half of cases with congenital lactic acidosis in Roma children. *Mol Genet Metabol* 113:76–83
- [45] Brown RM, Head RA, Morris AM et al. (2006) Pyruvate dehydrogenase E3 binding protein (protein X) deficiency. *Dev Med Child Neurol* 9:756–60
- [46] Miné M, Brivet M, Schiff et al. (2006) A novel gross deletion caused by non-homologous recombination of the PDHX gene in a patient with pyruvate dehydrogenase deficiency. *Mol Genet Metab* 89:106–110
- [47] Miné M, Chen JM, Brivet M et al. (2007) A large genomic deletion in the PDHX gene caused by the retrotranspositional insertion of a full length LINE-1 element. *Hum Mutat* 28:137–142
- [48] Maj M, Mackay N, Levandovskyi V et al. (2005) Pyruvate dehydrogenase phosphatase deficiency: identification of the first mutation in two brothers and restoration of activity by protein complementation. *J Clin Endocrinol Metab* 90:4101–4107
- [49] Cameron J, Maj M, Levandovskyi V et al. (2009) Pyruvate dehydrogenase phosphatase (PDP1) null mutation produces a lethal infantile phenotype. *Hum Genet* 125:319–326
- [50] Kennerson ML, Yiu EM, Chuang DT et al. (2013) A new locus for X-linked dominant Charcot–Marie–Tooth disease (CMTX6) is caused by mutations in the pyruvate dehydrogenase kinase isoenzyme3 (PDK3) gene. *Hum Mol Gen* 22:1404–1416
- [51] Perez-Siles G, Ly C, Grant A et al. (2016) Pathogenic mechanisms underlying X-linked Charcot–Marie–Tooth neuropathy (CMTX6) in patients with a pyruvate dehydrogenase kinase 3 mutation. *Neurobiol Dis*: 237–244
- [52] De Meirleir L, Lissens W, Denis R et al. (1993) Pyruvate dehydrogenase deficiency: clinical and biochemical diagnosis. *Pediatr Neurol* 9:216–220
- [53] Naito E, Ito M, Yokota I et al. (2002) Diagnosis and molecular analysis of three male patients with thiamine-responsive pyruvate dehydrogenase complex deficiency. *J Neurol Sci* 201:33–37
- [54] Falk RE, Cederbaum SD, Blass JP et al. (1976) Ketogenic diet in the management of pyruvate dehydrogenase deficiency. *Pediatrics* 58:713–721
- [55] Wexler ID, Hemalatha SG, McConnell J et al. (1997) Outcome of pyruvate dehydrogenase deficiency treated with ketogenic diets. Studies in patients with identical mutations. *Neurology* 49:1655–1661
- [56] Naito E, Ito M, Yokota I et al. (2002) Thiamine-responsive pyruvate dehydrogenase deficiency in two patients caused by a point mutation (F2005L and L216F) within the thiamine pyrophosphate binding site. *Biochim Biophys Acta* 1588:79–84
- [57] Stacpoole PW, Martyniuk CJ, Margaret OJ et al. (2019) Dichloroacetate-induced peripheral neuropathy. *Int Rev Neurobiol* 145 :211–238

- [58] Fouque F, Brivet M, Boutron A et al. (2003) Differential effect of DCA treatment on the pyruvate dehydrogenase complex in patients with severe PDHC deficiency. *Pediatr Res* 53:793–799
- [59] Ferriero R, Iannuzzi C, Manco G et al. (2015) Differential inhibition of PDKs by phenylbutyrate and enhancement of pyruvate dehydrogenase complex activity by combination with dichloroacetate. *J Inher Metab Dis* 38:895–904
- [60] Ferriero R, Boutron A, Brivet M et al. (2014) Phenylbutyrate increases pyruvate dehydrogenase complex activity in cells harboring a variety of defects. *Ann Clin Translational Neurology* 1:462–470
- [61] Quintana E, Pineda M, Font A et al. (2010) Dihydrolipoamide dehydrogenase (DLD) deficiency in a Spanish patient with myopathic presentation due to a new mutation in the interface domain. *J Inher Metab Dis* 33:15–9
- [62] Carozzo R, Torraco A, Fiermonte G et al. (2014) Riboflavin responsive mitochondrial myopathy is a new phenotype of dihydrolipoamide dehydrogenase deficiency. The chaperone-like effect of vitamin B2. *Mitochondrion* 14:49–57
- [63] Ambrus A (2019) An Updated View on the Molecular Pathomechanisms of Human Dihydrolipoamide Dehydrogenase Deficiency in Light of Novel Crystallographic Evidence. *Neurochem Res* 10: 2307-2313
- [64] Brassier A, Ottolenghi C, Boutron A et al. (2013) Dihydrolipoamide dehydrogenase deficiency: A still overlooked cause of recurrent acute liver failure and Reye-like syndrome. *Mol Genet Metab* 1: 28-32
- [65] Odièvre M, Chrétien D, Munnich A et al. (2005) A novel mutation in the dihydrolipoamide dehydrogenase E3 subunit gene (DLD) resulting in an atypical form of α -ketoglutarate dehydrogenase deficiency *Hum Mutat* 25:323–324
- [66] Hong YS, Korman SH, Lee J et al. (2003) Identification of a common mutation (Gly194Cys) in both Arab Moslem and Ashkenazi Jewish patients with dihydrolipoamide dehydrogenase (E3) deficiency: possible beneficial effect of vitamin therapy. *J Inher Metab Dis* 26:816–818
- [67] Yap ZY, Strucinska K, Matsuzaki S et al. (2020) A biallelic pathogenic variant in the OGDH gene results in a neurological disorder with features of a mitochondrial disease. *J Inher Metab Dis*. jimd.12248.
- [68] Carozzo R, Verrigni D, Rasmussen M et al. (2016) Succinate-CoA ligase deficiency due to mutations in SUCLA2 and SUCLG1: phenotype and genotype correlations in 71 patients. *J Inher Metab Dis* 39:243–252
- [69] Jain-Ghai S, Cameron JM, Al Maawali A et al. (2013) Complex II deficiency-A case report and review of the literature. *Am J Med Genet Part A* 2: 285-294
- [70] Alston CL, Davison JE, Meloni F et al. (2012) Recessive germline SDHA and SDHB mutations causing leukodystrophy and isolated mitochondrial complex II deficiency. *J Med Genet* 49:569-577
- [71] Ardisson A, Invernizzi F, Nasca A et al. (2015) Mitochondrial leukoencephalopathy and complex II deficiency associated with a recessive SDHB mutation with reduced penetrance. *Mol Genet Metab Rep* 5:51-54
- [72] Ohlenbusch A, Edvardson S, Skorpen J et al. (2012) Leukoencephalopathy with accumulated succinate is indicative of SDHAF1 related complex II deficiency. *Orphanet J Rare Dis* 7:69

- [73] Helman G, Caldovic L, Whitehead MT et al. (2016) Magnetic resonance imaging spectrum of succinate dehydrogenase-related infantile leukoencephalopathy. *Ann Neurol* 3: 379-386
- [74] Kaur P, Sharma S, Kadavigere R et al. (2020) Novel variant p.(Ala102Thr) in SDHB causes mitochondrial complex II deficiency: Case report and review of the literature. *Ann Hum Genet* 4: 345-351
- [75] Alston CL, Ceccatelli Berti C, Blakely EL et al. (2015) A recessive homozygous p.Asp92Gly SDHD mutation causes prenatal cardiomyopathy and a severe mitochondrial complex II deficiency. *Hum Genet* 8: 869-879
- [76] Brière JJ, Favier J, Gimenez-Roqueplo AP et al. (2006) Tricarboxylic acid cycle dysfunction as a cause of human diseases and tumor formation. *Am J Physiol - Cell Physiol* 6: 1114-1120
- [77] Coman D, Kranc KR, Christodoulou (2020) Fumarate Hydratase Deficiency. In Adam MP, Ardinger HH, Pagon RA, et al., editors *GeneReviews*® p1993-2020.
- [78] Allegri G, Fernandes MJ, Scalco FB et al. (2010) Fumaric aciduria: An overview and the first Brazilian case report. *J Inher Metab Dis* 4: 411-419
- [79] Ryder B, Moore F, Mitchell A et al. (2018) Fumarase Deficiency: A Safe and Potentially Disease Modifying Effect of High Fat/Low Carbohydrate Diet. *JIMD Reports* 40:77-83
- [80] Sharkia R, Wierenga KJ, Kessel A et al. (2019) Clinical, radiological, and genetic characteristics of 16 patients with ACO2 gene defects: Delineation of an emerging neurometabolic syndrome. *J Inher Metab Dis* 2: 264-275
- [81] Blackburn PR, Schultz MJ, Lahner CA et al. (2020) Expanding the clinical and phenotypic heterogeneity associated with biallelic variants in ACO2. *Ann Clin Transl Neurol* 6: 1013-1028
- [82] Abela L, Spiegel R, Crowther LM et al. (2017) Plasma metabolomics reveals a diagnostic metabolic fingerprint mitochondrial aconitase (ACO2) deficiency. *PLoS One* 5: 1-15 e0176363.
- [83] Hartong DT, Dange M, McGee EL et al. (2008) Novel insights into the contributions of isocitrate dehydrogenases to the Krebs cycle from patients with retinitis pigmentosa. *Nat Genet* 40:1230–1234
- [84] Fattal-Valevski A, Eliyahu H, Fraenkel ND et al. (2017) Homozygous mutation, p.Pro304His, in IDH3A, encoding isocitrate dehydrogenase subunit is associated with severe encephalopathy in infancy. *Neurogenetics* 1: 57-61
- [85] Mondesir J, Willekens C, Touat M, de Botton S (2016) IDH1 and IDH2 mutations as novel therapeutic targets: current perspectives. *J Blood Med* 7:171-180
- [86] Kranendijk M, Struys EA, van Schaftingen E et al. (2010) IDH2 mutations in patients with D-2-hydroxyglutaric aciduria. *Science* 330:336
- [87] Wibom R, Lasorsa FM, Tökönen V et al. (2009) AGC1 Deficiency Associated with Global Cerebral Hypomyelination. *N Engl J Med* 5: 489-495
- [88] Falk MJ, Li D, Gai X et al. (2014) AGC1 Deficiency Causes Infantile Epilepsy, Abnormal Myelination, and Reduced N- Acetylaspartate. *JIMD Reports* 14:77-85.
- [89] Kavanaugh BC, Warren EB, Baytas O et al. (2019) Longitudinal MRI findings in patient with SLC25A12 pathogenic variants inform disease progression and classification. *Am J Med Genet Part A* 11: 2284-2291.

- [90] Dahlin M, Martin DA, Hedlund Z et al. (2015) The ketogenic diet compensates for AGC1 deficiency and improves myelination. *Epilepsia* 11: e176-e181
- [91] Broeks MH, Shamseldin HE, Alhashem A et al. (2019) MDH1 deficiency is a metabolic disorder of the malate–aspartate shuttle associated with early onset severe encephalopathy. *Hum Genet* 11-12: 1247-1257
- [92] Ait-El-Mkadem S, Dayem-Quere M, Gusic M et al. (2017) Mutations in MDH2, Encoding a Krebs Cycle Enzyme cause Early-Onset Severe Encephalopathy. *Am J Hum Genet* 1: 151-159
- [93] Cascón A, Comino-Méndez I, Currás-Freixes M et al. (2015) Whole-Exome Sequencing Identifies MDH2 as a New Familial Paraganglioma Gene. *J Natl Cancer Inst* 107(5) djv053
- [94] Van Karnebeek CDM, Ramos RJ, Wen XY et al. (2019) Bi-allelic GOT2 Mutations Cause a Treatable Malate- Aspartate Shuttle-Related Encephalopathy. *Am J Hum Genet* 3: 534-548
- [95] Brivet M, Garcia-Cazorla A, Lyonnet S et al. (2003) Impaired mitochondrial pyruvate importation in a patient and a fetus at risk. *Mol Gen Metab* 78:186–192
- [96] Bricker DK, Taylor EB, Schell JC et al. (2012) A mitochondrial pyruvate carrier required for pyruvate uptake in yeast, *Drosophila* and humans. *Science* 337:96–100
- [97] Kremer LS, Danhauser K, Herebian D et al. (2016) NAXE mutations disrupt the cellular NAD(P)HX repair system and cause a lethal neurometabolic disorder of early childhood. *American Journal of Human Genetics* 99, 894–902
- [98] van Bergen NJ, Guo Y, Rankin N et al. (2019) NAD(P)HX dehydratase (NAXD) deficiency :a novel neurodegenerative disorder exacerbated by febrile illnesses. *Brain* 142 : 50-58
- [99] Van Bergn NJ, Linster CL and Christodoulou J. (2020) Reply : NAD(P)HX dehydratase protein-truncating mutations are associated with neurodevelopmental disorder exacerbated by acute illness *Brain* 143 :1-3