



**HAL**  
open science

## Etiologic and prognostic value of external carotid artery thrombus detection during endovascular therapy for anterior circulation proximal occlusions

Thomas Courret, Thomas Tourdias, Jean Papaxanthos, Julien Labreuche, Florent Gariel, Jean-Sébastien Liegey, Stéphane Olindo, Pauline Renou, Jerome Berge, Xavier Barreau, et al.

### ► To cite this version:

Thomas Courret, Thomas Tourdias, Jean Papaxanthos, Julien Labreuche, Florent Gariel, et al.. Etiologic and prognostic value of external carotid artery thrombus detection during endovascular therapy for anterior circulation proximal occlusions. *European Journal of Neurology*, 2023, 30 (2), pp.380-388. 10.1111/ene.15623 . hal-04434828

**HAL Id: hal-04434828**

**<https://hal.science/hal-04434828v1>**

Submitted on 2 Feb 2024

**HAL** is a multi-disciplinary open access archive for the deposit and dissemination of scientific research documents, whether they are published or not. The documents may come from teaching and research institutions in France or abroad, or from public or private research centers.





L'archive ouverte pluridisciplinaire **HAL**, est destinée au dépôt et à la diffusion de documents scientifiques de niveau recherche, publiés ou non, émanant des établissements d'enseignement et de recherche français ou étrangers, des laboratoires publics ou privés.



Distributed under a Creative Commons Attribution - NonCommercial - NoDerivatives 4.0 International License

## ORIGINAL ARTICLE

# Etiologic and prognostic value of external carotid artery thrombus detection during endovascular therapy for anterior circulation proximal occlusions

Thomas Courret<sup>1</sup>  | Thomas Tourdias<sup>1,2</sup> | Jean Papaxanthos<sup>1</sup> | Julien Labreuche<sup>3</sup> | Florent Gariel<sup>1</sup> | Jean-Sebastien Liegey<sup>4</sup> | Stephane Olindo<sup>4</sup> | Pauline Renou<sup>4</sup> | Jerome Berge<sup>1</sup> | Xavier Barreau<sup>1</sup> | Sharmila Sagnier<sup>4,5</sup> | Patrice Menegon<sup>1,†</sup> | Ludovic Lucas<sup>4</sup>  | Pierre Briau<sup>4</sup> | Mathilde Poli<sup>4</sup> | Sabrina Debruxelles<sup>4</sup> | François Rouanet<sup>4</sup> | Vincent Dousset<sup>1,2</sup> | Igor Sibon<sup>4,5</sup>  | Gaultier Marnat<sup>1</sup> 

<sup>1</sup>Neuroradiology Department, CHU Bordeaux, Bordeaux, France

<sup>2</sup>INSERM-U862, Neurocentre Magendie, Bordeaux, France

<sup>3</sup>Department of Biostatistics, Université de Lille, CHU de Lille, Lille, France

<sup>4</sup>Neurology Department, CHU Bordeaux, Bordeaux, France

<sup>5</sup>UMR-5287-CNRS, Université de Bordeaux, EPHE PSL Research University, Bordeaux, France

## Correspondence

Thomas Courret, Neuroradiology Department, CHU Bordeaux, Place Amélie Raba Léon, 33000 Bordeaux, France.  
Email: [thomas.courret@gmail.com](mailto:thomas.courret@gmail.com)

## Abstract

**Background and purpose:** An early understanding of stroke mechanism may improve treatment and outcome in patients presenting with large vessel occlusion stroke (LVOS) treated with mechanical thrombectomy (MT). We aimed to investigate whether spontaneous external carotid artery (ECA) embolism detection during MT is associated with stroke etiology and clinical outcome.

**Methods:** We retrospectively reviewed our prospectively maintained institutional database including consecutive patients with anterior circulation LVOS treated with MT between January 2015 and August 2020.

**Results:** An ECA embolus was detected in 68 of 1298 patients (5.2%). The kappa coefficient for interobserver agreement was 0.89 (95% confidence interval [CI] 0.82–0.95). ECA embolism was significantly associated with intracranial internal carotid artery (ICA) occlusion ( $p < 0.001$ ), cardioembolic etiology ( $p < 0.001$ ) and a lower clot burden score ( $p < 0.001$ ). Day-1 variation of National Institutes of Health Stroke Scale score (adjusted odds ratio [OR] -2.7, 95% CI -4.9 to 0.3;  $p = 0.021$ ) and delta Alberta Stroke Program Early Computed Tomography Score (adjusted OR 0.9, 95% CI 0.2 to 1.5;  $p = 0.004$ ) were worse among patients with ECA emboli. There was no significant difference in 90-day functional outcome between groups (adjusted OR 0.8, 95% CI 0.42 to 1.52;  $p = 0.50$ ).

**Conclusion:** In patients with anterior circulation LVOS treated with MT, ECA embolism was significantly associated with cardioembolic etiology, high thrombus burden and proximal intracranial ICA occlusions. This underexplored angiographic pattern might provide a valuable etiologic clue to the underlying cause of anterior circulation LVOS and may also help determine the appropriate revascularization strategy.

†Deceased

This is an open access article under the terms of the [Creative Commons Attribution-NonCommercial-NoDerivs](https://creativecommons.org/licenses/by-nc-nd/4.0/) License, which permits use and distribution in any medium, provided the original work is properly cited, the use is non-commercial and no modifications or adaptations are made.

© 2022 The Authors. *European Journal of Neurology* published by John Wiley & Sons Ltd on behalf of European Academy of Neurology.

## KEYWORDS

etiology, external carotid artery, ischemic stroke, mechanical thrombectomy, outcome

## INTRODUCTION

Since the publication of major randomized controlled trials, mechanical thrombectomy (MT) has been a first-line treatment for anterior circulation large vessel occlusion stroke (LVOS) [1]. Major prognostic factors of early clinical improvement and good functional outcome at 3 months include successful and rapid recanalization [2].

Early identification of the occlusion mechanism is critical in decision making during endovascular treatment [3, 4]. In particular, the ability to distinguish embolic stroke from underlying arterial wall disease, such as large artery atherosclerosis or dissection, could be important in determining the best endovascular strategy since these stroke causes should be managed using the appropriate adjuvant mechanical and/or pharmacological approach [5–7]. Digitally subtracted angiography (DSA) performed during MT might identify stroke etiology by assessing occlusion topography and cervical artery patency. Early stroke etiology identification also improves decision making in secondary antithrombotic prevention strategies [8]. During MT, an embolus in the external carotid artery (ECA) may be identified. As previously described in two case reports, this finding may be associated with high clot burden and suggests the LVOS has a cardioembolic origin [9, 10]. However, the literature on ECA embolus frequency, underlying causes and consequences remains very limited to date.

While ECA embolus is asymptomatic and not considered a therapeutic target thanks to the bilateral ECA's, rich anastomotic network detection of an ECA embolus might be a helpful clue in determining stroke etiology. The aim of this study was to investigate whether the presence of ECA embolus, detected during endovascular therapy (EVT), is associated with stroke etiology and clinical outcomes.

## METHODS

### Study population

We retrospectively analyzed data from our prospectively collected database of consecutive patients presenting with LVOS treated with MT in our center between January 2015 and August 2020. Exclusion criteria were posterior circulation LVOS and unavailable or non-analyzable DSA images of the ECA (cervical DSA run not performed, motion artefacts, insufficient ECA opacification; see study flowchart, eFigure 1). Each DSA scan of the endovascular procedure was centrally and independently reviewed by two interventional neuroradiologists: one senior (more than 10 years' experience) and one junior (1 year's experience). Readers were blinded to all other imaging and clinical information. ECA embolus was defined as any formally identified flow arrest within the ECA artery and/or its branches (main ECA trunk, lingual artery, facial artery, maxillary-temporal trunk, middle meningeal artery, internal maxillary artery,

occipital artery and superficial temporal artery). Stenosis or vasospasm of the ECA were not recorded as ECA emboli. The DSA exploration protocol during EVT for anterior LVOS consisted of two first DSA runs: one focused on the cervical carotid bifurcation region and the second on the intracranial area. Only the initial DSA run was analyzed to minimize the risk of iatrogenic ECA thrombus after repeated endovascular maneuvers. Patients were classified into two groups according to the detection or not of an embolus within the ECA region. Disagreements between the two readers were resolved through consensus after a third DSA analysis by a senior reader (7 years' experience in neuroradiology). Among patients with angiographically confirmed ECA emboli, initial non-invasive imaging was also retrospectively reviewed to explore their detectability prior to MT.

### Collected data

Clinical, therapeutic and imaging data were prospectively collected at baseline and during follow-up. Stroke cause was determined according to the TOAST (Trial of ORG 10172 in Acute Stroke Treatment) classification system. The final etiology was based on follow-up and a panel of assessments including baseline imaging, computed tomography (CT) and magnetic resonance (MR) angiography or Doppler ultrasonography of the cervical arteries, biological samples, 48-h electrocardiogram recording in the stroke unit, transthoracic or transesophageal echocardiography and any additional explorations if needed.

Outcomes were assessed using modified Rankin Scale (mRS) score at 3 months by vascular neurologists or trained research nurses during face-to-face interview or telephone interviews with the patient, their relatives or their general practitioner. Favorable and excellent outcomes were defined as 90-day mRS scores 0–2 and 0–1, respectively (or return to pre-stroke mRS score). Successful, near-to-complete and complete reperfusion were defined as modified Thrombolysis In Cerebral Infarction (mTICI) scores 2b–2c–3, 2c–3 and 3, respectively. Clot burden score (CBS) was assessed on initial imaging [11]. First pass effect was defined as achieving a successful recanalization (mTICI score 2b–2c–3) with a single MT device pass. Early neurological (24-h variation of National Institutes of Health Stroke Scale [NIHSS] score) and imaging (24-h delta Alberta Stroke Program Early Computed Tomography Score [ASPECTS]) changes were recorded. Intracerebral hemorrhage (ICH) was evaluated using the European Cooperative Acute Stroke Study (ECASS)-II classification. Symptomatic ICH was defined as a neurological deterioration (NIHSS score worsening of  $\geq 4$  points) along with ICH. Initial, procedural and Day-1 imaging data were assessed and recorded in the prospectively maintained database by trained senior neuroradiologists. The data that support the findings of this study are available from the corresponding author upon reasonable request.

**TABLE 1** Main patient and treatment characteristics, overall and according to presence or absence of external carotid artery embolism

Characteristic	Overall (n = 1298)	External carotid artery embolism		SD
		No (n = 1230)	Yes (n = 68)	
Age, years, mean $\pm$ SD	71.5 $\pm$ 13.9	71.3 $\pm$ 14.0	74.8 $\pm$ 13.5	25.0
Men	645/1298 (49.7)	624/1230 (50.7)	21/68 (30.9)	-41.1
Medical history				
Hypertension	790/1273 (62.1)	743/1205 (61.7)	47/68 (69.1)	15.7
Diabetes mellitus	217/1266 (17.1)	210/1199 (17.5)	7/67 (10.4)	-20.5
Hypercholesterolemia	423/1268 (33.4)	397/1201 (33.1)	26/67 (38.8)	12.0
Current smoking	304/1266 (24.0)	295/1199 (24.6)	9/67 (13.4)	-28.8
Previous stroke or TIA	209/1230 (17.0)	194/1163 (16.7)	15/67 (22.4)	14.4
Previous antithrombotic medications				
None	695/1256 (55.3)	663/1189 (55.8)	32/67 (47.8)	23.2
Antiplatelets alone	289/1256 (23.0)	275/1189 (23.1)	14/67 (20.9)	
Anticoagulants alone	231/1256 (18.4)	213/1189 (17.9)	18/67 (26.9)	
Antiplatelets and anticoagulants	41/1256 (3.3)	38/1189 (3.2)	3/67 (4.5)	
Current stroke event				
Pre-stroke mRS score				
0	897/1238 (72.5)	854/1173 (72.8)	43/65 (66.2)	29.0
1	175/1238 (14.1)	167/1173 (14.2)	8/65 (12.3)	
2	83/1238 (6.7)	77/1173 (6.6)	6/65 (9.2)	
3	65/1238 (5.3)	60/1173 (5.1)	5/65 (7.7)	
>3	18//1238 (1.5)	15/1173 (1.3)	3/65 (4.6)	
Admission NIHSS score, median (IQR) <sup>a</sup>	16 (11-20)	16 (11-20)	19 (16-23)	58.8
Admission ASPECTS, median (IQR) <sup>b</sup>	8 (7-9)	8 (7-9)	8 (6-9)	-9.5
Directly admission in a comprehensive stroke center	672/1281 (52.5)	638/1213 (52.6)	34/68 (50.0)	-5.2
Initial cerebral imaging				
MRI	795/1296 (61.3)	753/1128 (61.3)	42/68 (61.8)	-0.9
CT scan	501/1296 (38.7)	475/1128 (38.7)	26/68 (38.2)	
Occlusion site				
M1-MCA	663/1298 (51.1)	642/1230 (52.2)	21/68 (30.9)	121.3
M2-MCA	224/1298 (17.3)	222/1230 (18.0)	2/68 (2.9)	
Intracranial ICA	218/1298 (16.8)	183/1230 (14.9)	35/68 (51.5)	
Tandem	168/1298 (12.9)	158/1230 (12.8)	10/68 (14.7)	
Extracranial ICA	24/1298 (1.8)	24/1230 (2.0)	0/68 (0.0)	
Others	1/1298 (0.1)	1/1230 (0.1)	0/68 (0.0)	
Clot burden score	8 (6-8)	8 (6-8)	6 (4-7)	84.2
Onset to imaging				
Unknown time of onset	410/1234 (33.2)	378/1168 (32.4)	32/66 (48.5)	33.6
$\leq$ 6 h	783/1234 (63.5)	751/1168 (64.3)	32/66 (48.5)	
>6 h	41/1234 (3.3)	39/1168 (3.3)	2/66 (3.0)	
LVOS etiology				
Large artery atherosclerosis	213/1298 (16.4)	212/1230 (17.2)	1/68 (1.5)	90.6
Cardioembolic	698/1298 (53.8)	639/1230 (52.0)	59/68 (86.8)	
Dissection	69/1298 (5.3)	69/1230 (5.6)	0/68 (0.0)	
Others/Undetermined	318/1298 (24.5)	310/1230 (25.2)	8/68 (11.8)	

TABLE 1 (Continued)

Characteristic	Overall (n = 1298)	External carotid artery embolism		
		No (n = 1230)	Yes (n = 68)	SD
Treatment				
Intravenous thrombolysis	738/1298 (56.9)	710/1230 (57.7)	28/68 (41.2)	-33.6
General anesthesia	122/1282 (9.5)	105/1125 (8.6)	17/67 (25.4)	45.7
Early recanalization on initial DSA run	82/1298 (6.3)	80/1230 (6.5)	2/68 (2.9)	-15.4
At least one MT device pass	1181/1298 (91.0)	1115/1230 (90.7)	66/68 (97.1)	26.1
First-line thrombectomy				
Contact aspiration	758/1127 (67.3)	709/1062 (66.8)	49/65 (75.4)	36.7
Stent-retriever	63/1127 (5.6)	63/1062 (5.9)	0/65 (0.0)	
Stent-retriever + contact aspiration	302/1127 (26.8)	286/1062 (26.9)	16/65 (24.6)	
Others	4/1127 (0.3)	4/1062 (0.4)	0/65 (0.0)	
Second-line thrombectomy				
Contact aspiration	56/232 (24.1)	53/213 (24.9)	3/19 (15.8)	66.5
Stent-retriever	30/232 (12.9)	28/213 (13.1)	2/19 (10.5)	
Stent-retriever + contact aspiration	144/232 (62.1)	130/213 (61.0)	14/19 (73.7)	
Others	2/232 (0.9)	2/213 (0.9)	0/19 (0.0)	
Adjuvant therapy				
None	1144/1296 (88.3)	1078/1128 (87.8)	66/68 (97.1)	37.4
Pharmacological	41/1296 (3.2)	41/1128 (3.3)	0/68 (0.0)	
Mechanical	66/1296 (5.1)	65/1128 (5.3)	1/68 (1.5)	
Both	45/1296 (3.5)	44/1128 (3.6)	1/68 (1.5)	

Note: Values are n/N (%), unless otherwise indicated.

Abbreviations: ASPECTS, Alberta Stroke Program Early Computed Tomography Score; CT, computed tomography; DSA, digitally subtracted angiography; IQR, interquartile range; MRI, magnetic resonance imaging; mRS, modified Rankin scale; NIHSS, National Institutes of Health Stroke Scale; MT, mechanical thrombectomy; SD, standard deviation; TIA, transient ischemic attack.

<sup>a</sup>57 missing values (embolus group, n = 2).

<sup>b</sup>91 missing values (embolus group, n = 2).

## Endovascular treatment

The indications for MT were based on standard guidelines, imaging data and patient comorbidities after multidisciplinary team discussion. MT was performed by trained neuroradiologists under local anesthesia and conscious sedation or general anesthesia depending on patient status, comorbidities and stroke severity. The MT strategy (stent-retriever, contact aspiration or combined) and choice of adjuvant therapy, including pharmacological (antiplatelet therapy, anticoagulant, thrombolytic, vasodilator) and/or mechanical treatment (intracranial or cervical angioplasty and/or stenting), were left to the discretion of the operator depending on suspected stroke etiology. Three angiography suites were used during the study period: biplane Innova 3131 (GE Healthcare), biplane Artis Q (Siemens) or monoplane Allura Xper FD20 (Philips Healthcare).

## Statistical Analysis

See Supplemental Material.

## RESULTS

During the study period, a total of 1611 patients with acute ischemic stroke attributable to LVOS were consecutively admitted to our center for EVT. Among these, 313 patients were excluded from analysis for the following reasons: posterior circulation LVOS (n = 166) and unavailable or not analyzable initial DSA run (n = 147; eFigure 1). The final analysis included 1298 patients: 5.2% (n = 68, 95% confidence interval [CI] 4.0%–6.5%) presented with at least one embolus in the ECA (eFigure 1). As shown in eTable 2, agreement between the two independent readers for the retrospective diagnosis of ECA embolism was excellent, with a kappa coefficient of 0.89 (95% CI, 0.82–0.95).

The main patient and treatment characteristics for the overall study cohort and for the cohort stratified according to diagnosis or not of ECA embolus are reported in Table 1. As shown in Table 2, the three predefined occlusion characteristics differed significantly between patients with and without ECA thrombi. Compared to patients without ECA embolus, unadjusted analysis in patients with ECA embolus showed a higher proportion of intracranial internal carotid artery (ICA) artery occlusion (51.5% vs. 14.9%;  $p < 0.001$  [see

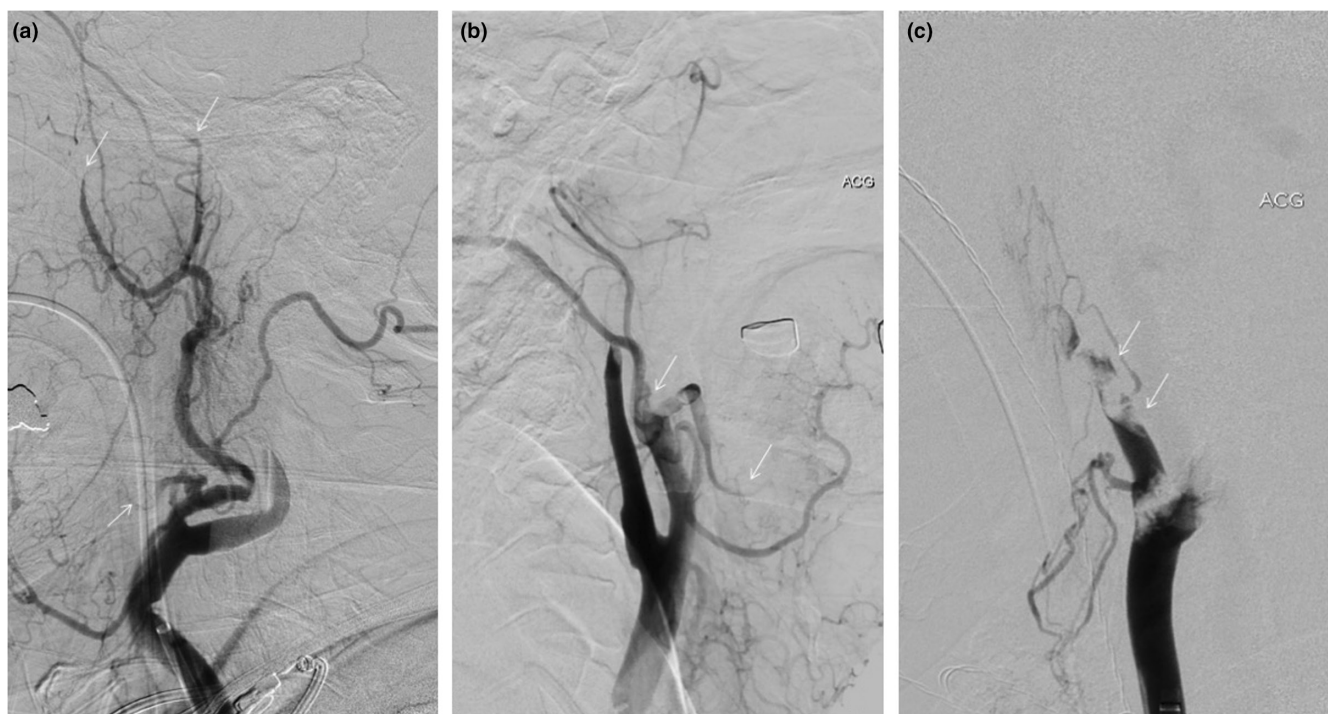**TABLE 2** Comparison of main thrombus characteristics according to presence or absence of external carotid artery embolism

LVOS characteristics	External carotid artery embolism		p value	Effect size (95% CI)
	No (n = 1230)	Yes (n = 68)		
Intracranial ICA occlusion	183/1230 (14.9)	35/68 (51.5)	<0.001	0.84 (0.59–1.10)
Cardioembolic etiology	639/1230 (52.0)	59/68 (86.8)	<0.001	0.82 (0.56–1.07)
Clot burden score <sup>a</sup> , median (IQR)	8 (6–8)	6 (4–7)	<0.001	–0.84 (–1.10 to –0.58)

Note: Values are n/N (%), unless otherwise indicated.

Abbreviations: CI, confidence interval; ICA, internal carotid artery; IQR, interquartile range; LVOS, large vessel occlusion stroke.

<sup>a</sup>123 missing values (embolus group, n = 7). Effect size is reported as standardized difference, calculated on rank-transformed value for clot burden score. A value of 0.8 (or –0.8 regarding the direction of difference) is interpreted in the literature as a large difference.



**FIGURE 1** Initial digitally subtracted angiography lateral views of three patients presenting with internal carotid artery occlusions associated with various locations of external carotid artery emboli (white arrows): (a) internal maxillary artery, middle meningeal artery and facial artery; (b) maxillary-temporal trunk and facial artery; and (c) main external carotid artery trunk

illustrative cases, [Figure 1](#)), a lower CBS (median [interquartile range] 6 [4–6] vs. 8 [6–8];  $p < 0.001$ ) and a higher proportion of final diagnosis of cardioembolic stroke etiology (86.8% vs. 52.0%;  $p < 0.001$ ). All differences were interpreted as large based on standard differences greater than 0.8 (absolute value). Regarding cardioembolic stroke etiology, detection of an ECA embolus was associated with a sensitivity of 8.5% (59/698, 95% CI 6.5%–10.8%), a specificity of 98.5% (591/600, 95% CI 97.1%–99.4%), a positive predictive value of 86.8% (59/68; 95% CI 76.3%–93.8%) and a negative predictive value of 52.0% (639/1230; 95% CI 45.2%–50.9%).

In the ECA embolism group, the causal embolic heart disease was already known at the time of stroke onset in 40 patients (58.8%). ECA thrombus was finally also detectable on initial non-invasive

imaging in 36 patients (52.9%). Details regarding cardioembolic etiology in the ECA embolism group are provided in [eTable 3](#); atrial fibrillation was the most represented etiology (42 patients, 71.2%).

As shown in [Table 3](#), patients with ECA embolism less often had a favorable outcome (unadjusted odds ratio [OR] 0.56, 95% CI 0.32–0.99), had a lower decrease in NIHSS score (baseline-adjusted mean difference in NIHSS score change –2.6, 95% CI –5.0 to –0.2) and a higher decrease in ASPECTS at 24 h (baseline-adjusted mean difference in ASPECTS change 0.9, 95% CI 0.3–1.6). After prespecified adjustment for age, admission NIHSS score and ASPECTS and onset to imaging time, only the difference in favorable outcome disappeared (adjusted OR 0.80, 95% CI 0.42–1.52). Similar results were found when 90-day mRS score was analysed as the ordinal variable (shift



**TABLE 3** Clinical outcomes according to presence or absence of external carotid artery embolism

Outcomes	External carotid artery embolism		Unadjusted		Adjusted <sup>d</sup>	
	No (n = 1230)	Yes (n = 68)	Effect size (95% CI)	p value	Effect size (95% CI)	p value
Clinical outcomes						
90-day favorable outcome	460/1051 (43.8)	18/59 (30.5)	0.56 (0.32–0.99) <sup>a</sup>	0.048	0.80 (0.42–1.52)	0.50
90-day excellent outcome	298/1051 (28.4)	11/59 (18.6)	0.58 (0.29–1.13) <sup>a</sup>	0.11	0.81 (0.39–1.64)	0.55
90-day mortality	218/1051 (20.7)	17/59 (28.8)	1.55 (0.86–2.78) <sup>a</sup>	0.14	1.09 (0.59–2.00)	0.77
24-h change in NIHSS score <sup>e</sup>	3.5 (2.9 to 4.0) <sup>b</sup>	0.8 (–1.5 to 3.2) <sup>b</sup>	–2.6 (–5.0 to –0.2) <sup>c</sup>	0.031	–2.7 (–4.9 to –0.3) <sup>c</sup>	0.021
24-h change in ASPECTS <sup>f</sup>	1.0 (0.9 to 1.2) <sup>b</sup>	2.0 (1.4–2.6) <sup>b</sup>	0.9 (0.3–1.6) <sup>c</sup>	0.001	0.9 (0.2–1.5) <sup>c</sup>	0.004
Any ICH	664/1121 (59.2)	43/63 (68.3)	1.48 (0.85–2.55) <sup>a</sup>	0.16	1.31 (0.73–2.36)	0.36
Parenchymal hematoma	153/1116 (13.7)	15/63 (23.8)	1.97 (1.07–3.60) <sup>a</sup>	0.028	1.73 (0.90–3.30)	0.097
Symptomatic ICH	94/1121 (8.4)	8/63 (12.7)	1.59 (0.73–3.44) <sup>a</sup>	0.24	1.39 (0.60–3.22)	0.44

Note: Values are n/N (%), unless otherwise indicated. Favorable outcome defined as 90-day mRS 0–2 or equal to pre-stroke mRS; excellent outcome defined as 90-day mRS 0–1 or equal to pre-stroke mRS.

Abbreviations: ASPECTS, Alberta Stroke Program Early Computed Tomography Score, CI, confidence interval; ICH, intracerebral hemorrhage; NIHSS, National Institutes of Health Stroke Scale; ICH, intracerebral hemorrhage.

<sup>a</sup>Odds ratio.

<sup>b</sup>Mean (95% CI) of change from baseline adjusted for baseline values.

<sup>c</sup>Mean between-group difference in change from baseline (95% CI) adjusted for baseline values.

<sup>d</sup>Calculated after handling missing values by multiple imputation and after adjustment for age, admission NIHSS score and ASPECTS, and onset to imaging time (treated as three-level categorical variable: unknown time of onset, ≤6 h, >6 h).

<sup>e</sup>131 missing values (embolus group, n = 9).

<sup>f</sup>197 missing values (embolus group, n = 8). Missing data were not excluded but they were replaced using a multiple imputation method (see Statistical Analysis).

analysis), with unadjusted and adjusted common ORs (indicating the odds of improvement of 1 point on the mRS score) of 0.50 (95% CI 0.31–0.80) and 0.70 (95% CI 0.43–1.15), respectively. Regarding haemorrhagic complications, only higher odds of parenchymal hematoma was observed in patients with ECA thrombi, with a non-significant difference in multivariate analysis (adjusted OR 1.73, 95% CI 0.90–3.30).

After excluding patients with early recanalization before any MT pass, among the patients with persisting proximal occlusion at the time of MT (1115 patients without and 66 with ECA emboli), several angiographic outcomes differed significantly according to presence or not of ECA thrombi (eTable 1). Patients with ECA thrombus less often had successful reperfusion (adjusted OR 0.45, 95% CI 0.24–0.84) and first pass effect (adjusted OR 0.46; 95% CI 0.25–0.85) and required a higher number of MT device passes (adjusted OR 1.37, 95% CI 1.15–1.62).

## DISCUSSION

Our study demonstrated that, in anterior LVOS, ECA embolism was strongly associated with cardioembolic etiology, high clot burden and proximal intracranial ICA occlusions. Among patients with persisting intracranial occlusion at the time of EVT, the initial detection of an embolus within the ECA was significantly associated with lower rates of successful reperfusion and first pass effect and with a higher number of MT passes. Poorer early clinical (Day-1 NIHSS

score) and imaging (Day-1 ASPECTS) outcomes were observed in patients with ECA thrombi. However, no difference was detected regarding clinical outcomes (90-day mRS score and mortality rate) between the two groups.

To the best of our knowledge, this is the first study investigating the prevalence of emboli within the ECA and their association with LVOS etiology and outcomes in a large cohort of consecutive patients with anterior LVOS treated with MT. Previous publications suggested a link between ECA embolism and cardioembolic etiology but these studies consisted of case reports involving only a very limited number of patients (two patients and one patient, respectively) [9, 10].

Early recognition of stroke mechanism may allow management to be adapted accordingly, avoiding unnecessary time-consuming or harmful endovascular maneuvers and potentially improving patient outcome. In many cases, LVOS etiology can be suspected at the very acute phase of the stroke (for example, in cases of known history of atrial fibrillation, identified large artery atherosclerosis or presence of other infarcts in distinct arterial territories). Nevertheless, in emergency circumstances, LVOS cause remains frequently unidentified at the time of MT, and final etiological diagnosis may not be made until a few days or months after the cerebrovascular event [12].

In the acute phase, awareness of stroke mechanism should favor appropriate choice of EVT strategy. In particular, a major issue in MT practice is the detection of underlying arterial wall disease, either cervical or intracranial (large artery atherosclerosis, dissection, or

in exceptional cases, vasculitis of toxic, radiation-induced or autoimmune causes). Underlying atherosclerosis or dissection requires specific endovascular and pharmacological adjuvant therapies, such as stenting or acute antiplatelet therapy. An appropriate EVT approach results in improved rates of intracranial recanalization and hastens cerebral reperfusion [13–17]. Ruling out these etiologies is of great benefit as cardioembolic LVOS is usually efficiently treated with standard MT approaches (stent-retriever, contact aspiration or combined approaches). Consequently, identifying an ECA embolus on the initial DSA runs should help to exclude a cervical ICA underlying the disease and encourage use of a standard MT technique. This angiographic finding can be especially useful in the setting of terminal intracranial ICA occlusions, which are frequently difficult to distinguish from true tandem occlusions (Figure 1). In addition, accurate identification of stroke etiology is important for the selection and initiation of the most appropriate therapy for secondary stroke prevention [18].

External carotid artery embolism was markedly associated with direct and indirect markers of high clot burden. The significant association with intracranial ICA occlusion topography and low CBS are obviously linked to larger thrombus burden [19]. After restricting the analysis to patients without recanalization at the time of MT, we observed that lower successful reperfusion and first pass effect rates and higher number of MT passes were also significantly associated with ECA embolism. These last points should be a prompt to choose an EVT strategy appropriate for high clot burden. Indeed, previous studies identified that a combined approach (contact aspiration combined with stent-retriever) may improve recanalization rate in cases of ICA terminus occlusions and/or lower CBS [20, 21]. With this in mind, detecting ECA emboli might encourage selection of an MT approach particularly adapted to larger clot burden. Moreover, first pass effect, an identified predictive factor of better functional outcome, is less likely to be achieved in ICA terminus occlusions [22].

In our study, a cardioembolic stroke origin was finally assumed in most of our patients with ECA embolus. Cardioembolic stroke etiologies encompass a wide range of heart diseases including atrial fibrillation, patent foramen ovale, aortic arch atheroma, prosthetic heart valve dysfunction, infective or aseptic endocarditis, cardiac tumors and other exceptional causes [23]. The detection of an occlusion within the ECA may be an important clue to help determine stroke etiology. The rate of cryptogenic stroke in our study, however, was similar to previously published data showing uncertain etiology in up to 30% of stroke cases [24]. Our results showed that, in a smaller fraction of patients in the ECA embolism group, there was no final identified stroke source. These findings suggest that embolic strokes of undetermined cause, classified as cryptogenic after complete diagnostic workup, may be of cardioembolic origin [25, 26]. ECA embolism may be a valuable clue in stroke etiology investigation and justify extensive etiologic explorations to detect paroxysmal atrial fibrillation or other hidden cardioembolic causes. Nevertheless, our study is not sufficient to clarify the complex issue of embolic stroke of unknown origin. In addition, it should be noted

that one patient in the ECA embolism group was classified as having stroke caused by large artery atherosclerosis. In this specific case, we identified a proximal ECA thrombus due to local extension from the ICA bulb atherosclerotic occlusion.

The implications of the close link between ECA embolism and cardioembolic stroke origin for secondary prevention and early initiation of anticoagulant treatment are also interesting. However, further prospective investigations may be required to confirm our findings and to further investigate the initiation of anticoagulant therapy for secondary prevention after ECA occlusion detection; until then, this should be a discussion point only.

In this study, we also found evidence of poorer clinical prognosis. We observed that Day-1 ASPECTS and NIHSS score were worse in the ECA embolism group. These factors are reported to be associated with poor long-term outcome [27]. However, no significant influence on 90-day outcome nor mortality was noted in our study, although the statistical analysis may lack power given the relative rarity of ECA embolism and the relatively low number of patients in this group ( $n = 68$ ). The main reason for the poorer early outcomes could be the higher clot burden in the ECA embolism group. To a lesser extent, despite presenting no direct ischemic risk owing to the ECA's rich anastomotic network, ECA emboli may limit collateral flow, preventing ophthalmic artery reversal. However, this phenomenon might be anecdotal and a less prevalent cause of poor outcome than the direct role of high thrombus burden.

Despite rare variations in ECA anatomy, identification of embolism in the ECA during endovascular treatment is fast and simple, providing that an initial DSA run exploring the carotid bifurcation region and the ECA territory is performed. In our study, inter-reader agreement was high, even with one reader having only short experience in interventional neuroradiology. Our data support the strong reliability of this angiographic marker and its simple detection.

These findings emphasize the diagnostic role of an endovascular procedure for LVOS. Indeed, we believe that, in addition to its obvious and important revascularization purpose, MT also has an important role to play in etiological diagnosis. Several specific angiographic patterns can be observed during the EVT which are sometimes only noticeable at this point. Cervical artery atherosclerosis or dissection, carotid web or intracranial underlying stenosis are important angiographic findings necessitating specific endovascular and long-term therapeutic strategies. Accordingly, ECA emboli should be included in the angiographic investigation and may constitute a new marker to be integrated into the etiological evidence.

Our study had some limitations. It was a single-center retrospective study and had limited statistical power because it included only a small number of patients with ECA embolism, a relatively rare condition. In some cases, ECA angiogram was missing or of poor quality, resulting in missing data; however, this applied to only a few cases in our cohort. Also, distal ECA thrombi may have been missed because it is difficult to investigate distal branches and occlusion beyond the field of view. The imaging



endpoints were not core laboratory-adjudicated. Nevertheless, imaging data were prospectively collected by a trained senior neuroradiologist. Furthermore, a systematic and appropriate methodology was used for the DSA analysis to identify ECA embolism (see Methods section). In addition, the possibility that a proportion of ECA emboli identified were iatrogenic cannot be excluded, due to catheterization of supra-aortic trunks; however, we believe that this possibility remains negligible. Iatrogenic embolism during cervical artery catheterization is rare thanks to device improvements over recent decades. Moreover, the study was performed in a high-volume comprehensive stroke center with experienced operators. Common carotid artery atherosclerosis or dissection are conceivable alternative causes of ECA embolism. Nonetheless, these arterial diseases are rare. We did not identify any isolated symptomatic common carotid atherosclerosis or dissection in our study population. Lastly, we only investigated this angiographic pattern on DSA. The extrapolation of this observation to non-invasive brain imaging (CT and MR angiograms) remains to be explored.

In conclusion, ECA embolism is a strong marker of high thrombus burden and cardioembolic etiology. This singular angiographic feature might be useful in making the decision to adapt MT strategy to high clot burden and in excluding underlying arterial wall disease such as atherosclerosis or dissection at the time of the endovascular procedure, especially in cases of intracranial ICA occlusion angiographic patterns. ECA embolism may also constitute emerging evidence to be included in etiological investigations for anterior circulation LVOS.

## CONFLICT OF INTEREST

The authors have no conflicts of interest to declare that are relevant to the content of this article.

## DATA AVAILABILITY STATEMENT

The data that support the findings of this study are available from the corresponding author upon reasonable request.

## ORCID

Thomas Courret  <https://orcid.org/0000-0002-7282-1153>

Ludovic Lucas  <https://orcid.org/0000-0003-2385-2604>

Igor Sibon  <https://orcid.org/0000-0002-1171-4215>

Gautier Marnat  <https://orcid.org/0000-0002-7611-7753>

## REFERENCES

- Goyal M, Menon BK, van Zwam WH, et al. Endovascular thrombectomy after large-vessel ischaemic stroke: a meta-analysis of individual patient data from five randomised trials. *The Lancet*. 2016;387(10029):1723-1731.
- Saver JL, Goyal M, van der Lugt A, et al. Time to treatment with endovascular thrombectomy and outcomes from ischemic stroke: a meta-analysis. *JAMA*. 2016;316(12):1279-1288.
- Matias-Guiu JA, Serna-Candel C, Matias-Guiu J. Stroke etiology determines effectiveness of retrievable stents: Table 1. *J NeuroInterventional Surg*. 2014;6(2):e11.
- Baek JH, Kim BM, Kim DJ, et al. Importance of truncal-type occlusion in stentriever-based thrombectomy for acute stroke. *Neurology*. 2016;87(15):1542-1550.
- Marnat G, Bühlmann M, Eker OF, et al. Multicentric experience in distal-to-proximal revascularization of tandem occlusion stroke related to internal carotid artery dissection. *Am J Neuroradiol*. 2018;39(6):1093-1099.
- Anadani M, Marnat G, Consoli A, et al. Endovascular therapy of anterior circulation tandem occlusions: pooled analysis from the TITAN and ETIS registries. *Stroke*. 2021;52(10):3097-3105.
- Tsang ACO, Orru E, Klostranec JM, et al. Thrombectomy outcomes of intracranial atherosclerosis-related occlusions: a systematic review and meta-analysis. *Stroke*. 2019;50(6):1460-1466.
- Hankey GJ. Secondary stroke prevention. *Lancet Neurol*. 2014;13(2):178-194.
- Tomsick T, Thangasamy S, Stamatis T, Khatri P, Broderick J. External carotid artery embolus with internal carotid artery occlusion with acute ischemic stroke: predictor of cardioembolic etiology. *J NeuroInterventional Surg*. 2012;4(2):101-104.
- Viaccoz A, Müller H, Perren F. Asymptomatic external carotid artery thrombosis in acute stroke. *Ultraschall Med - Eur J Ultrasound*. 2012;33(7):E357-E358.
- Puetz V, Dzialowski I, Hill MD, et al. Intracranial thrombus extent predicts clinical outcome, final infarct size and hemorrhagic transformation in ischemic stroke: the Clot Burden Score. *Int J Stroke*. 2008;3(4):230-236.
- Sposato LA, Cipriano LE, Saposnik G, Ruiz Vargas E, Riccio PM, Hachinski V. Diagnosis of atrial fibrillation after stroke and transient ischaemic attack: a systematic review and meta-analysis. *Lancet Neurol*. 2015;14(4):377-387.
- Papanagiotou P, Haussen DC, Turjman F, et al. Carotid stenting with antithrombotic agents and intracranial Thrombectomy leads to the highest recanalization rate in patients with acute stroke with tandem lesions. *JACC Cardiovasc Interv*. 2018;11(13):1290-1299.
- Marnat G, Lapergue B, Sibon I, et al. Safety and outcome of carotid dissection stenting during the treatment of tandem occlusions: a pooled analysis of TITAN and ETIS. *Stroke*. 2020;51(12):3713-3718.
- Chang Y, Kim BM, Bang OY, et al. Rescue stenting for failed mechanical thrombectomy in acute ischemic stroke: a multicenter experience. *Stroke*. 2018;49(4):958-964.
- Premat K, Dechartres A, Lenck S, et al. Rescue stenting versus medical care alone in refractory large vessel occlusions: a systematic review and meta-analysis. *Neuroradiology*. 2020;62(5):629-637.
- Marnat G, Delvoe F, Finitzis S, Lapergue B, Gariel F, Consoli A, et al. A multicenter preliminary study of Cangrelor following thrombectomy failure for refractory proximal intracranial occlusions. *Am J Neuroradiol* [Internet]. 2021;42(8):1452-1457. August 24, 2021. <http://www.ajnr.org/content/early/2021/06/11/ajnr.A7180>
- Kernan WN, Ovbiagele B, Black HR, et al. Guidelines for the prevention of stroke in patients with stroke and transient ischemic attack: a guideline for healthcare professionals from the American Heart Association/American Stroke Association. *Stroke*. 2014;45(7):2160-2236.
- Tan IYL, Demchuk AM, Hopyan J, et al. CT angiography clot burden score and collateral score: correlation with clinical and radiologic outcomes in acute middle cerebral artery infarct. *Am J Neuroradiol*. 2009;30(3):525-531.
- Humphries W, Hoit D, Doss VT, et al. Distal aspiration with retrievable stent assisted thrombectomy for the treatment of acute ischemic stroke. *J NeuroInterventional Surg*. 2015;7(2):90-94.
- Lee JS, Hong JM, Lee SJ, Joo IS, Lim YC, Kim SY. The combined use of mechanical thrombectomy devices is feasible for treating acute carotid terminus occlusion. *Acta Neurochir*. 2013;155(4):635-641.

22. Zaidat OO, Castonguay AC, Linfante I, et al. First pass effect. *Stroke*. 2018;49(3):660-666.
23. Kamel H, Healey JS. Cardioembolic stroke. *Circ Res*. 2017;120(3):514-526.
24. Yaghi S, Bernstein RA, Passman R, Okin PM, Furie KL. Cryptogenic stroke. *Circ Res*. 2017;120(3):527-540.
25. Hart RG, Diener HC, Coutts SB, et al. Embolic strokes of undetermined source: the case for a new clinical construct. *Lancet Neurol*. 2014;13(4):429-438.
26. Boeckh-Behrens T, Kleine JF, Zimmer C, et al. Thrombus histology suggests cardioembolic cause in cryptogenic stroke. *Stroke*. 2016;47(7):1864-1871.
27. Heit JJ, Mlynash M, Kemp SM, et al. Rapid neurologic improvement predicts favorable outcome 90 days after Thrombectomy in the DEFUSE 3 study. *Stroke*. 2019;50(5):1172-1177.

## SUPPORTING INFORMATION

Additional supporting information can be found online in the Supporting Information section at the end of this article.

**How to cite this article:** Courret T, Tourdias T, Papaxanthos J, et al. Etiologic and prognostic value of external carotid artery thrombus detection during endovascular therapy for anterior circulation proximal occlusions. *Eur J Neurol*. 2023;30:380-388. doi:[10.1111/ene.15623](https://doi.org/10.1111/ene.15623)