

Clinical and histological study of follicular helper T-cell lymphomas with indolent evolution

Ondine Messéant¹, Fanny Drieux^{2,3}, Nouhoum Sako^{4,5}, Virginie Fataccioli^{4,5}, Vincent Camus⁶, Cyrielle Robe^{4,5}, Roch Houot¹, Patrick Tas⁷, Francisco Llamas-Gutierrez⁷, Claire Lamaison⁷, Julie Abraham⁸, Manuela Delage-Corre⁹, Soraya Benguerfi¹⁰, Jean-Baptiste Bossard¹¹, Philippe Gaulard^{4,5,12#} and François Lemonnier^{5,12,13#}

1 Department of Hematology, University Hospital of Pontchaillou, Rennes, France; 2 INSERM U1245, University Hospital of Henri Becquerel, Rouen, France; 3 Department of Pathology, University Hospital of Henri Becquerel, Rouen, France; 4 Department of Pathology, University Hospital of Henri Mondor, AP-HP, Créteil, France; 5 INSERM U955, Mondor Biomedical Research Institute, Créteil, France; 6 Department of Hematology, University Hospital of Henri Becquerel, Rouen, France; 7 Department of Pathology, University Hospital of Pontchaillou, Rennes, France; 8 Department of Hematology, University Hospital of Dupuytren, Limoges, France; 9 Department of Pathology, University Hospital of Dupuytren, Limoges, France; 10 Department of Infectious Diseases and Medical Intensive Care, University Hospital of Pontchaillou, Rennes, France; 11 Department of Hematology, University Hospital of Lille, Lille, France; 12 Paris-East, Créteil University, Créteil, France; 13 Department of Lymphoid Malignancies, University Hospital of Henri Mondor, AP-HP, Créteil, France

PG and FL contributed equally as co-senior authors

Corresponding author:

Ondine Messéant
Hôpital Pontchaillou, Service Hématologie Clinique
2, rue Henri Le Guilloux - 35033 Rennes Cedex 09
Telephone number : +33299284291
Email : ondine.messeant@chu-rennes.fr

Abstract:

Introduction: Follicular helper T-cell lymphomas (TFHL) have an aggressive course with a poor outcome. European and US guidelines recommend anthracycline-based chemotherapy as a first-line treatment, but the 5-year overall survival rate is still approximately 30%. We describe here the features of a cohort of TFHL patients who experienced prolonged survival despite the absence of specific treatment or the initiation of steroid-based therapy.

Patients and methods: In our study, we describe 15 adult patients who suffered from TFHL and had not received intensive chemotherapy at diagnosis for any reason. Biopsies of these cases were centrally reviewed, and the mutational pattern was determined using next-generation sequencing.

Results: These 15 patients had the classic clinical, biological and pathological features of TFHL, angioimmunoblastic-type. *TET2* mutations were found in 83% of patients; *RHOA G17V*, *IDH2 R172* and *DNMT3A* mutations were found in 67%, 42% and 33% of the patients, respectively.

Among the 15 patients, 8 did not receive any treatment, and 7 received steroid-based treatment. Ten patients had progression (5 in each group). Four patients died (3 of them from the progression of their lymphoma). The median follow-up in our cohort was 53 months. The 5-year OS was 66%, 100% for untreated patients and 29% for the others. In those 2 groups, the median time to treatment initiation was 22 months from diagnosis.

Conclusion: We described a series of 15 well-characterized TFHL patients with an indolent outcome, suggesting that a watch-and-wait approach can be proposed in selected patients. Identifying factors predicting such evolution is warranted.

Keywords: Angioimmunoblastic T-cell lymphoma; indolent evolution; watch-and-wait, follicular helper T-cell lymphomas

Introduction

Follicular helper T-cell lymphomas (TFHLs) are one of the most frequently occurring subtypes of peripheral T-cell lymphoma (PTCL); they have distinct clinicopathologic features, an aggressive course and a poor outcome¹. European and US guidelines recommend anthracycline-based chemotherapy as a first-line treatment^{2,3}, but the 5-year overall survival (OS) rate is still less than 50%⁴. However, the first studies describing the disease included few patients who had prolonged survival despite the absence of chemotherapy, ranging from 24 to 45 months. These patients had spontaneous remissions or had been treated with steroids alone or immunosuppressive therapies^{5,6}. Nevertheless, these cases reported in the 1970s, prior to the recognition of the disease as a subtype of PTCL, were mainly diagnosed based on morphological assessments with limited immunohistochemistry and no genetic analysis. Because the angioimmunoblastic-type of TFHL (AITL) is a challenging diagnosis, the misclassification of some cases cannot be excluded⁷.

Furthermore, this "indolent" course of AITL has, to our knowledge, rarely been reported and studied since 1975. Here, we describe the clinical, pathological and molecular features of a series of AITL patients who experienced prolonged survival despite the absence of systemic chemotherapy.

Patients and methods

Data source and eligibility

Here, we present data obtained from a retrospective observational case series analysis from 16

institutions in France. Eligible patients had TFH lymphoma diagnosed on a lymph node biopsy with adequate material available for centralized review and, when necessary, additional immunohistochemical (IHC) or molecular analyses. Other inclusion criteria for this study were adult patients aged 18 years or older who had not received intensive chemotherapy at diagnosis for at least 2 years because of personal choice, physician's choice or advanced age. Patients who received a steroid-based treatment (alone or in combination with low-dose treatment) were analyzed in a dedicated cohort. Patients who had received intensive chemotherapy at diagnosis or within 6 months of diagnosis were excluded. Available clinical and biological characteristics of the patients, including data on their treatment and follow-up, were also required. Patients with too many missing data were excluded.

All patients signed a consent form to use their data for research purposes, either as part of a protocol study or according to local guidelines.

Definitions

We defined indolent evolution by the absence of progression requiring systemic treatment (except a low dose of steroids) for at least 6 months after the initial diagnosis.

We defined complete remission (CR) by the extinction of tumor masses on imaging (CT or PET CT) or by normalization of clinical and laboratory signs in the absence of imaging.

Histology, immunohistochemistry and molecular biology

Formalin-fixed paraffin-embedded (FFPE) lymph node (LN) biopsy samples at diagnosis were collected and reviewed centrally by at least 3 expert hematopathologists to establish a consensus diagnosis according to the criteria of the WHO classification updated in 2017⁸ and used for additional immunohistochemical and molecular analyses. Consensus was reached if all experts independently agreed on the diagnosis or after multihead or virtual discussion with knowledge of the molecular results.

Tumor DNA extracted from tumor biopsy was used for clonal analysis and next-generation sequencing using a panel relevant for TFH-PTCL, as previously described⁹.

Statistical analysis

We studied the clinical, biological, and histopathological features of this cohort of TFHL patients and examined possible predictors of indolent progression. Standard descriptive analyses were performed for clinical and biological parameters. Qualitative variables were presented as proportions (percentages), and quantitative variables were presented as medians with minimum and maximum values. Continuous variables were compared using the Mann–Whitney U test. Overall survival (OS) was

considered from the date of diagnosis to death, and progression-free survival (PFS) was considered from the date of diagnosis to disease progression, death, or last follow-up. Observation periods were censored at last follow-up if no events were observed. Survival estimates were calculated using the Kaplan–Meier method, and time-to-event distributions were compared using log-rank tests (univariate regression).

Statistical tests were performed using R 4.2.1 (R Foundation for Statistical Computing, Vienna, Austria); a p value ≤ 0.05 was considered statistically significant.

Results

Clinical and biological patient characteristics

Among the 28 patients identified in 8 centers, 13 were excluded, mainly for incomplete information (n=7), absence of an indolent course (n=4), or unconfirmed diagnosis of TFHL (n=1). Therefore, 15 patients with a confirmed diagnosis of TFHL of AITL-type (AITL) after central review were retained (Figure S1). Their clinical and laboratory findings are summarized in Table 1. Overall, the patients had classic AITL features. The median age at diagnosis was 78 years, and 13/15 (80%) patients had advanced-stage disease (III-IV). Polyadenopathies were present in 11/15 (73%) patients, B symptoms were present in 7/15 (47%), and skin rash occurred in 6 patients (40%). Six patients (40%) had an altered performance status ≥ 2 . The international prognostic index (IPI) was moderate risk (2-3), and the PIAI score revealed a low risk (0 or 1), both for 9/15 (60%) patients. Polyclonal hypergammaglobulinemia was present in 4 patients (36%). LDH levels were normal in the majority of cases (71%) or less than twice the normal level (21%). The EBV blood level (by PCR) was positive in 3/4 patients (range 3.5-4.7).

Table 1. Clinical and biological characteristics

Presentation	All patients (n=15)	No primary therapy (n=8)	Primary therapy (n=7)
Median age at diagnosis (IQR)	78 (64,5-80)	75,5 (64,5-84)	78 (65-79,5)
Sex			
Male	7 (47%)	3 (37,5%)	4 (57,1%)
Female	8 (53%)	5 (62,5%)	3 (42,9%)
Stage			
I	1 (7%)	1 (12,5%)	0
II	2 (13%)	1 (12,5%)	1 (14,3%)
III	9 (60%)	5 (62,5%)	4 (57,1%)
IV	3 (20%)	1 (12,5%)	2 (28,6%)
Extranodal involvement	4 (27%)	1 (12,5%)	3 (42,9%)
Description of extranodal sites			
Skin	1 (7%)	0	1 (14,3%)
Liver	1 (7%)	0	1 (14,3%)
Bone marrow	2 (14%)	1 (12,5%)	1 (14,3%)
B symptoms	7 (47%)	1 (12,5%)	6 (85,7%)
PS ≥ 2	6 (40%)	1 (12,5%)	5 (71,4%)

IPI			
0-1	3 (22%)	2 (28,6%)	1 (14,3%)
2-3	9 (60%)	5 (71,4%)	4 (57,1%)
4-5	2 (13%)	0	2 (28,6%)
MD	1	1	0
PIAI			
0-1	9 (60%)	7 (87,5%)	2 (28,6%)
2-5	6 (40%)	1 (12,5%)	5 (71,4%)
Median SUVmax (IQR)	6,7 (3,23-12,43)	3 (2-8,35)	9,5 (6,7-11,45)
Median follow-up (months) (IQR)	53 (24,5-77)	61 (37-74,5)	30 (23-79)
Primary therapy			
None	8 (53%)	8 (100%)	0
Steroids	5 (33%)		5 (71,4%)
Steroids and CT	1 (7%)		1 (14,3%)
Steroids and other	1 (7%)		1 (14,3%)
Response to steroid therapy		Not concerned	
CR	2 (13%)		2 (28,6%)
PR	4 (27%)		4 (57,1%)
SD	1 (7%)		1 (14,3%)
Progression during follow-up	10 (67%)	4 (50%)	6 (85,7%)
Other line therapy needed	5 (33%)	3	3
Median time from diagnosis to other therapy (months) (IQR)	22 (19,5-65)	52 (34-65)	21 (19,75-39,75)
Myeloid neoplasm	1 (7%)	0	1 (14,3%)
Secondary cancer	2 (13%)	1 (12,5%)	1 (14,3%)
Outcome			
Alive	11 (73%)	8 (100%)	3 (42,9%)
Dead	4 (27%)	0	4 (57,1%)
Blood count			
Median hemoglobin (g/dL) (IQR)	13,35 (11,15-14)	14 (13,6-14)	10,9 (9,35-12,7)
Median platelets (G/L) (IQR)	250 (212-277,5)	250 (228-251)	276 (201-330)
Presence of lymphopenia	8 (62%)	4	4
Median NPC/Ly ratio (IQR)	4,12 (2,82-5,25)	3,19 (1,80-4,83)	4,13 (4,11-10,8)
LDH level			
Normal	10 (71%)	6 (85,7%)	4 (57,1%)
Elevated but < 2N	3 (21%)	1 (14,3%)	2 (28,6%)
≥ 2N	1 (7%)	0	1 (14,3%)
MD	1	1	0
Serum protein electrophoresis			
Normal	6 (55%)	3 (60%)	3 (50%)
Polyclonal hypergammaglobulinemia	4 (36%)	2 (40%)	2 (33,3%)
Other**	1 (9%)	0	1 (16,7%)
MD	4	3	1
Median gammaglobulin level (IQR)	11,7 (9,5-16,95)	11,7 (10,7-16,9)	12,5 (8,13-29,7)
MD	3	2	2
Positive direct antiglobin test	3 (50%)	1	2
MD	9	6	4
Circulating neoplastic cells (FCM)	7 (70%)	4	3
MD	5	1	4

Table 1 shows the clinical and laboratory data of all patients and whether they were treated at diagnosis.

Abbreviations: CR: complete response, CT: chemotherapy; FCM: flow cytometry; IPI: International Prognostic Index, LDH: lactate dehydrogenase; Ly: lymphocytes; MD: missing data; NPC: neutrophilic polynuclear cells; PIAI: Prognostic Index for AITL; PR: partial regression of symptoms; PS: performance status; SD: stable disease; SUVmax: maximum standard uptake value in 18- fluorodeoxyglucose PET-CT. **: Hypogammaglobulinemia and monoclonal peak.

Histopathological and molecular characteristics

After review, the diagnosis of AITL was confirmed in 15 patients (one case was not confirmed and was

excluded) (Figure S1). All biopsies were lymph node samples; in some patients, a bone marrow biopsy (3) or a skin biopsy (2) was also reviewed. Histopathological and molecular data are summarized in Supplementary Table S1. A predominance of histological AITL pattern 3 according to Attygale was present (10 patients, 66%)¹⁰. Patterns 1 and 2 represented 1 (7%) patient each, one additional patient showed a mixed pattern and two patients demonstrated a distinctive perifollicular pattern with a preservation of mantle zones. Almost all tested cases showed atypical CD4+ cells (12/13, 92%), with a TFH phenotype (CD10+ in 11/15 cases, PD1+ in 13/13, ICOS+ in 13/13, CXCL13+ in 11/11 and BCL6+ in 12/13 cases) (Table S1). FDC expansion was observed in 11/14 cases, and EBV-positive B immunoblasts were observed in 6/13 (46%).

Regarding molecular biology data, a TCR clonal rearrangement was detected in 10/13 patients (77%) and a BCR clonal rearrangement in 1/8 (12.5%) patient. Among the 12 successfully sequenced patients. Sequencing failure was because of the absence of enough material for DNA extraction (2) or the presence of degraded DNA (1). *TET2* mutations were found in 10 patients (83%), including 6 with multiple mutations. Mutations in *RHOA G17V*, *IDH2 R172* and *DNMT3A* were found in 8 (67%), 5 (42%) and 4 (33%) patients, respectively. Figure 1 shows the different characteristics of patients according to their initial status (treated or not).

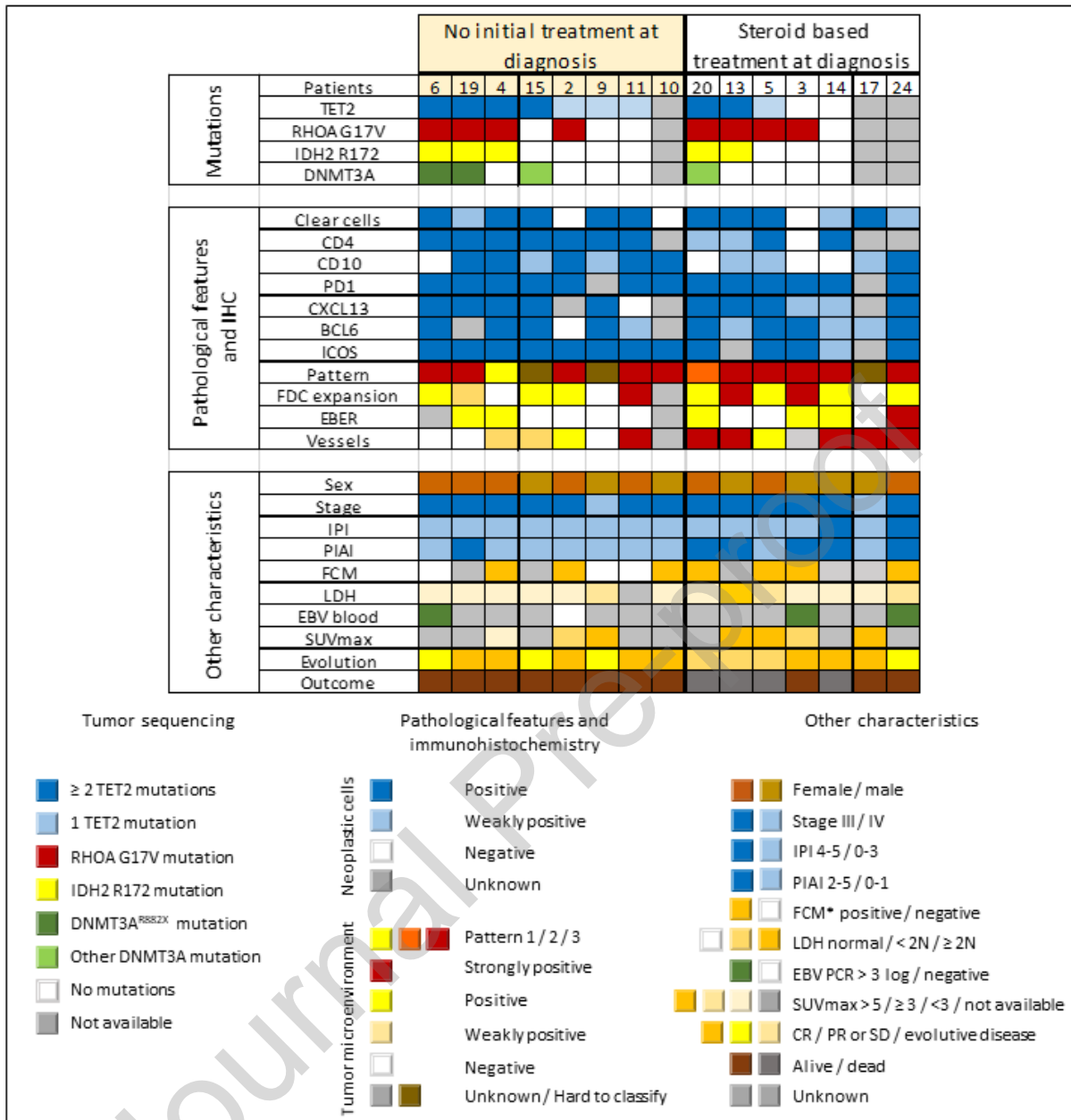


Figure 1. Description of the molecular, pathological, clinical and biological features of the 15 AITL patients.

The "mutations" section describes the distribution of *TET2*, *RHOA G17V*, *IDH2 R172* and *DNMT3A* mutations in each patient's tumors. The section "pathological features and immunohistochemistry" describes the pathological features of the AITL biopsy specimens. Blue is used to describe neoplastic cells, red the architecture (pattern) and vascular hyperplasia whereas the tumor microenvironment is scored in yellow. The pathologists assessed the different parameters in a semiquantitative way. Clear cells with large cytoplasm were described as frequent in dark blue cases and more scarce in light blue cases; they were absent in white cases, and this parameter was shaded when unknown. Immunohistochemical results for TFH markers (CD10, PD1, CXCL13, BCL6, ICOS) are scored as indicated in the legend. The presence of follicular dendritic cell (FDC) expansion was assessed by CD21 and/or CD23 immunostaining. It is noted in orange when this expansion was very important, with the presence of vessel corbelling, in yellow when the expansion was present but less marked and in white when there was no FDC expansion. The EBV status of B immunoblasts was established by EBV RNA (EBER) ISH. This status was concluded to be negative in the absence of large EBV-positive cells, positive between 1 and 5 large EBV-positive lymphoid cells (yellow) and strongly positive when more than 5 cells were positive per field (orange). The "other characteristics" section includes some clinical, biological and prognostic factors of the patients. "FCM" refers to the search for circulating neoplastic T cells by flow cytometry. It is marked positive in orange when an aberrant phenotype consistent with AITL was detected in peripheral blood by flow cytometry at the time of diagnosis. The

"LDH" line represents the LDH level at diagnosis before any treatment. EBV PCR in blood was available for 4 patients, and 3 of them were positive between 3 and 4 log.

* FCM: flow cytometry.

Disease progression, treatment regimens and survival

Among the 15 patients, 8 were not treated at diagnosis (mainly because of spontaneous lymphoma regression, n=5), and 7 patients received steroid-based treatment. Among these 7 patients, one (AITL14) also received anti-IL1 therapy for suspicion of giant cell arteritis. Another patient (AITL5) received methotrexate for 7 months without efficacy and was subsequently followed for 10 months without specific therapy. Ten patients (5 in the untreated group and 5 in the steroid-treated group) experienced disease progression during the follow-up, which was histologically confirmed for 6 of them (Figure 2). Among these 10 patients, 7 required treatment (4 from the steroid-based treated group and 3 from the untreated group), including 3 chemotherapy and 4 steroid-based treatments. The 4 patients from the steroid-based treated group died. Of these patients, 3 died from lymphoma progression, and one died from a lung infection. After treatment initiation in the 3 initially untreated patients, 2 had CR, and the remaining had a partial response (Figure S1). Eight patients did not require any treatment during the follow-up. The median follow-up in our cohort was 53 months (range: 18–126). The 5-year OS was 66% for all patients, 100% for untreated patients and 29% for the others. The median OS was not reached. In those 2 groups, the median time to treatment initiation was 22 months from diagnosis (range 16-93).

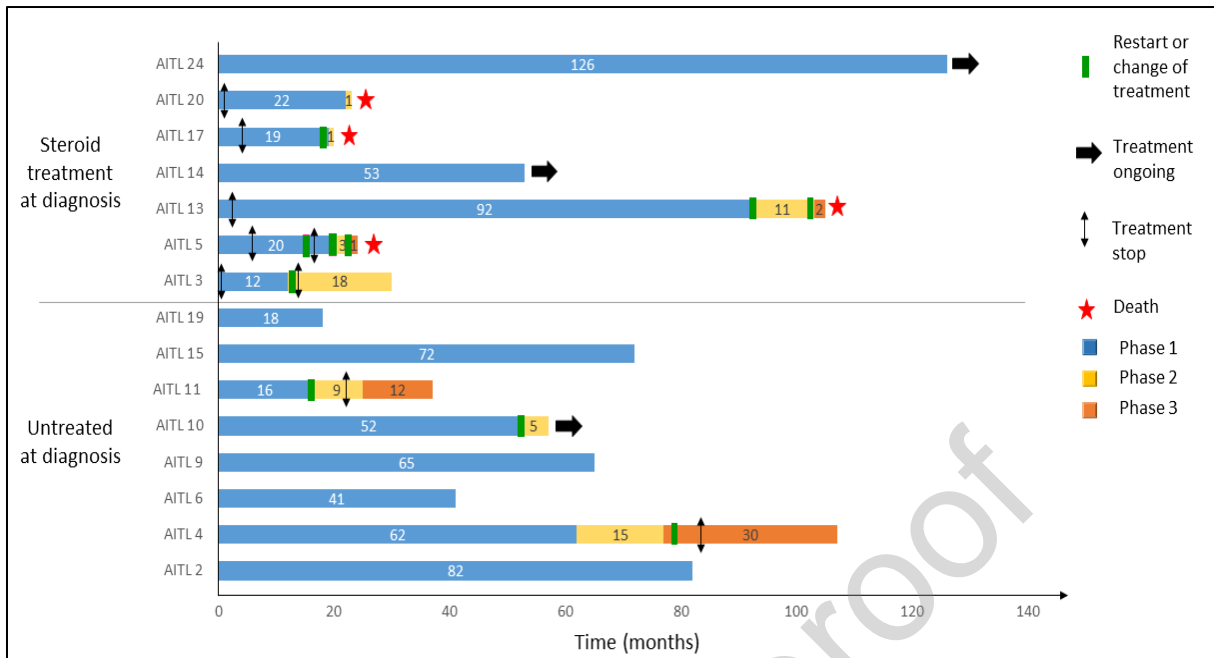


Figure 2. Patient outcomes.

The colored lines (phase 1, 2 or 3) represent the different time periods of the patients' disease history. Phase 1 (blue) is the time between the diagnosis and relapse or disease progression requiring treatment. Phases 2 and 3 also represent possible relapses of the disease. The green boxes represent times when a restart or a change in treatment was needed. The horizontal black arrows indicate patients for whom treatment was not stopped.

Two patients had a noteworthy evolution. An 80-year-old woman (AITL5) had stable disease for 10 months after steroids and oral methotrexate were stopped for inefficacy. She developed rapid progression after her third dose of COVID-19 BNT162b2 mRNA vaccine, as recently reported¹¹, with anasarca, disseminated lymph nodes and skin involvement. She received 2 cycles of systemic chemotherapy (CHOP), which was replaced with 5-azacitidine 3 months later. Unfortunately, she died from her AITL 5 months after the relapse. Of interest is another patient (AITL4), a 48-year-old woman who experienced 2 AITL relapses (both confirmed by biopsy) 5 and 6 years after the initial diagnosis, but no treatment was needed. Sixteen months after the first relapse, she developed a stage IV EBV+ nodal T/NK-cell lymphoma involving the LN, liver and lungs that was clonally unrelated to the initial AITL and did not harbor the previously described *TET2* and *RHOA* mutations. Following chemotherapy (L-asparaginase, gemcitabine, methotrexate, oxaliplatin and dexamethasone) and autologous hematopoietic stem cell transplantation, she remains in complete metabolic remission more than 3 years after the end of this treatment (Figures 2 and S1).

Discussion and perspectives

To our knowledge, our study is the first study to specifically focus on TFHL patients with an indolent course despite an absence of intensive chemotherapy at diagnosis. We listed and analyzed the clinical,

laboratory, pathological and molecular data of 15 patients. These patients had classic AITL features. More than a third of these patients suffered from a severe alteration of the general condition with a PS ≥ 2 , and 80% of the patients had an advanced stage (III or IV). Additionally, almost half of the patients had B-signs, and a skin rash occurred in 40% of patients. Although the limited number of patients in our series prevented a formal comparison between studies, the patients described in this study might be older but have less frequently elevated LDH levels or high IPI and PIAI scores than patients in other published AITL cohort series (Table S2) ^{4,12,13}. However, 3/15 patients had IPI 4-5, highlighting the fact that IPI imperfectly predicts outcome for a single patient.

The detection of recurrent AITL mutations, in addition to the histological features, supports a formal diagnosis of TFHL of AITL type (AITL) in our patients, even though we could not identify, within the limits of the NGS panel used, a mutational profile associated with this indolent evolution. Tumors also displayed the peculiar features of AITL. Pattern 1, which has been associated with a good outcome in a previous study ¹⁴, was not overrepresented in our series, although 2 patients disclosed a peculiar peri-follicular pattern. Notably, EBER ISH detected EBV-positive blasts in only 6/13 cases, which appeared less frequently than in previous series ^{12,13}. This finding could support the recent report that the presence of EBV could be a negative factor in AITL and PTCL NOS ¹⁵. However, the relationship between the presence of EBV-positive B cells and AITL remains poorly understood, and it is not known whether EBV plays an oncogenic role or EBV-positive cells are a consequence of the local immune deficiency induced by the tumor. The evolution of patient AITL4, who developed primary EBV+ nodal T/NK-cell lymphoma 88 months after the first diagnosis, is intriguing. This observation could support the hypothesis that AITL could induce immunodeficiency that could facilitate the emergence of EBV-positive lymphomas.

Iqbal et al. showed that patients with a high B-cell signature in the tumor had better outcomes than those with a high dendritic-cell or monocyte signature ¹⁶. Our immunohistochemical data do not indicate an obvious correlation with patient outcome. However, it would be interesting to analyze more precisely the tumor microenvironment in our series, especially with more discriminating technologies, such as spatial transcriptomic technologies.

We identified mutations in *TET2*, *RHOA G17V*, *IDH2* and *DNMT3A* in 83%, 67%, 42% and 33% of cases, respectively (Figure 1 and Table S1). Multiple *TET2* mutations were frequently found, which is also consistent with data reported in the literature ¹⁷⁻¹⁹. The detection of these recurrent mutations in AITL, in addition to the classic histological and phenotypic features, supports the diagnosis of AITL in these cases. Indeed, AITL is a difficult diagnosis and could be confounded with reactive conditions. Given the uncommon evolution of these patients, it is critical to corroborate the AITL diagnosis. In addition, in

our series, indolent evolution was not associated with the presence or absence of AITL-specific mutations.

Another intriguing observation was the occurrence of spontaneous complete responses in 5 patients. Whether disease control could be induced by immune control of the tumor or due to the loss of antigenic stimulation promoting tumor development is questionable. In this respect, the observation of rapid disease progression in a patient after COVID-19 vaccination may support the dependence of AITL TFH cells on antigenic stimulation ¹¹.

The patients described here had prolonged survival while receiving no treatment or steroid-based treatment, which is not in line with the NCCN and ESMO guidelines ^{2,3}. Of course, this prolonged survival needs to be carefully interpreted, as the patients were selected because of the indolent course of the disease. However, although our data are not sufficiently robust to support a watch-and-wait attitude in every paucisymptomatic patient, we believe that the description of sustained survival without chemotherapy in patients with confirmed AITL, especially those with spontaneous regression, could help physicians manage such patients. The small size of our cohort, the retrospective nature of our study, and the lack of comparison with patients with "classic" aggressive AITL are important limitations of our study, which probably prevented us from distinguishing clear predictive factors for this indolent course.

However, it would be important to identify such predictive factors. The mutational pattern is unlikely to bear such a prognosis, but analysis of specific clinical factors, neoplastic cells and microenvironment signatures could provide new insights to identify these patients.

Conclusion

We described here a series of 15 well-characterized patients who were remarkable because they had an indolent evolution of TFHL with prolonged survival without chemotherapy. This option suggests that a watch-and-wait strategy could be proposed to select patients with asymptomatic disease. Factors that predict this indolent evolution need to be identified.

Funding: This work was funded by FORCE Hémato.

References

1. Federico M, Rudiger T, Bellei M, et al. Clinicopathologic characteristics of angioimmunoblastic

- t-cell lymphoma: Analysis of the international peripheral t-cell lymphoma project. *J Clin Oncol.* 2013;31(2):240-246. doi:10.1200/JCO.2011.37.3647
2. d'Amore F, Gaulard P, Trümper L, et al. Peripheral T-cell lymphomas: ESMO Clinical Practice Guidelines for diagnosis, treatment and follow-up. *Ann Oncol.* 2015;26(June):v108-v115. doi:10.1093/annonc/mdv201
 3. Horwitz SM, Ansell S, Ai WZ, et al. T-Cell Lymphomas, Version 2.2022, NCCN Clinical Practice Guidelines in Oncology. *J Natl Compr Canc Netw.* 2022;20(3):285-308. doi:10.6004/jnccn.2022.0015
 4. Advani RH, Skrypets T, Civallero M, et al. Outcomes and prognostic factors in angioimmunoblastic T-cell lymphoma: final report from the international T-cell Project. *Blood.* 2021;138(3):213-220. doi:10.1182/blood.2020010387
 5. Frizzera G, Moran EM, Rappaport H. ANGIO-IMMUNOBLASTIC LYMPHADENOPATHY WITH DYSPROTEINÆMIA. *Lancet.* 1974;303(7866):1070-1073. doi:10.1016/S0140-6736(74)90553-4
 6. Frizzera G, Moran EM, Rappaport H. Angio-immunoblastic lymphadenopathy. Diagnosis and clinical course. *Am J Med.* 1975;59(6):803-818. doi:10.1016/0002-9343(75)90466-0
 7. Laurent C, Baron M, Amara N, et al. Impact of expert pathologic review of lymphoma diagnosis: Study of patients from the French Lymphopath network. *J Clin Oncol.* 2017;35(18):2008-2017. doi:10.1200/JCO.2016.71.2083
 8. Swerdlow SH, Campo E, Harris NL, Jaffe ES, Pileri SA, Stein H TJ. World Health Organization classification of Tumours of Haematopoietic and Lymphoid Tissues. *IARC.* 2017;Revised 4t.
 9. Lemonnier F, Safar V, Beldi-Ferchiou A, et al. Integrative analysis of a phase 2 trial combining lenalidomide with CHOP in angioimmunoblastic T-cell lymphoma. *Blood Adv.* 2021;5(2):539-548. doi:10.1182/bloodadvances.2020003081
 10. Attygalle AD, Kyriakou C, Dupuis J, et al. Histologic Evolution of Angioimmunoblastic T-cell Lymphoma in Consecutive Biopsies: Clinical Correlation and Insights Into Natural History and Disease Progression. *Am J Surg Pathol.* 2007;31(7):1077-1088. doi:10.1097/PAS.0b013e31802d68e9
 11. Goldman S, Bron D, Tousseyn T, et al. Rapid Progression of Angioimmunoblastic T Cell Lymphoma Following BNT162b2 mRNA Vaccine Booster Shot: A Case Report. *Front Med.* 2021;8(November):1-5. doi:10.3389/fmed.2021.798095

12. Mourad N, Mounier N, Brière J, et al. Clinical, biologic, and pathologic features in 157 patients with angioimmunoblastic T-cell lymphoma treated within the groupe d'étude des lymphomes de l'adulte (GELA) trials. *Blood*. 2008;111(9):4463-4470. doi:10.1182/blood-2007-08-105759
13. Tokunaga T, Shimada K, Yamamoto K, et al. Retrospective analysis of prognostic factors for angioimmunoblastic T-cell lymphoma: A multicenter cooperative study in Japan. *Blood*. 2012;119(12):2837-2843. doi:10.1182/blood-2011-08-374371
14. Tan LHC, Tan SY, Tang T, et al. Angioimmunoblastic T-cell lymphoma with hyperplastic germinal centres (pattern 1) shows superior survival to patterns 2 and 3: A meta-analysis of 56 cases. *Histopathology*. 2012;60(4):570-585. doi:10.1111/j.1365-2559.2011.04097.x
15. Kim TY, Min GJ, Jeon YW, et al. Impact of Epstein-Barr Virus on Peripheral T-Cell Lymphoma Not Otherwise Specified and Angioimmunoblastic T-Cell Lymphoma. *Front Oncol*. 2022;11(January):1-8. doi:10.3389/fonc.2021.797028
16. Iqbal J, Weisenburger DD, Greiner TC, et al. Molecular signatures to improve diagnosis in peripheral T-cell lymphoma and prognostication in angioimmunoblastic T-cell lymphoma. *Blood*. 2010;115(5):1026-1036. doi:10.1182/blood-2009-06-227579
17. Vallois D, Dobay MPD, Morin RD, et al. Activating mutations in genes related to TCR signaling in angioimmunoblastic and other follicular helper T-cell-derived lymphomas. *Blood*. 2016;128(11):1490-1502. doi:10.1182/blood-2016-02-698977
18. Dobay MP, Lemonnier F, Missiaglia E, et al. Integrative clinicopathological and molecular analyses of angioimmunoblastic T-cell lymphoma and other nodal lymphomas of follicular helper T-cell origin. *Haematologica*. 2017;102(4):e148-e151. doi:10.3324/haematol.2016.158428
19. Cortes JR, Ambesi-Impiombato A, Couronné L, et al. RHOA G17V Induces T Follicular Helper Cell Specification and Promotes Lymphomagenesis. *Cancer Cell*. 2018;33(2):259-273.e7. doi:10.1016/j.ccell.2018.01.001

Authors' Contributions

Julie Abraham: Resources. **Soraya Benguerfi:** Formal analysis. **Jean-Baptiste Bossard:** Resources. **Vincent Camus:** Resources. **Manuela Delage-Corre:** Resources. **Fanny Drieux:** Data Curation, Investigation. **Virginie Fataccioli:** Data Curation, Investigation. **Philippe Gaulard:** Investigation,

Supervision, Validation, Writing- Reviewing and Editing. **Roch Houot:** Resources, Writing - Review & Editing. **Claire Lamaison:** Investigation. **François Lemonnier:** Conceptualization, Methodology, Supervision, Validation, Visualization, Writing- Reviewing and Editing. **Francisco Llamas-Gutierrez:** Investigation. **Ondine Messéant:** Data Curation, Investigation, Methodology, Visualization, Writing - Original Draft. **Cyrielle Robe:** Investigation. **Nouhoum Sako:** Investigation. **Patrick Tas:** Resources.

Declaration of interests:

The authors declare that they have no known competing financial interests or personal relationships that could have appeared to influence the work reported in this paper.

Highlights

- Follicular helper T-cell lymphomas have an aggressive course with a poor outcome
- We describe 15 TFHL patients with an indolent outcome without specific treatment
- The 15 patients had the classic clinicobiological and pathological features of TFHL
- A watch-and-wait approach can be proposed in selected patients with TFHLs