



HAL
open science

Two novel tumours with NTRK2 fusion in the methylation class of extraventricular neurocytomas, including one intraventricular

Emmanuelle Uro-Coste, Arnault Tauziède-Espariat, Charlotte Dubucs, Dan Christian Chiforeanu, Aurore Siegfried, Yvan Nicaise, Luc Bauchet, Laurent Riffaud, Franck Bielle, Alexandre Vasiljevic, et al.

► To cite this version:

Emmanuelle Uro-Coste, Arnault Tauziède-Espariat, Charlotte Dubucs, Dan Christian Chiforeanu, Aurore Siegfried, et al. Two novel tumours with NTRK2 fusion in the methylation class of extraventricular neurocytomas, including one intraventricular. *Brain Pathology*, 2024, 34 (3), pp.e13223. 10.1111/bpa.13223 . hal-04416149

HAL Id: hal-04416149

<https://hal.science/hal-04416149v1>

Submitted on 20 Nov 2024

HAL is a multi-disciplinary open access archive for the deposit and dissemination of scientific research documents, whether they are published or not. The documents may come from teaching and research institutions in France or abroad, or from public or private research centers.

L'archive ouverte pluridisciplinaire **HAL**, est destinée au dépôt et à la diffusion de documents scientifiques de niveau recherche, publiés ou non, émanant des établissements d'enseignement et de recherche français ou étrangers, des laboratoires publics ou privés.



Distributed under a Creative Commons Attribution - NonCommercial - NoDerivatives 4.0 International License

LETTER TO THE EDITOR

Two novel tumours with *NTRK2* fusion in the methylation class of extraventricular neurocytomas, including one intraventricular

We report here about two novel tumours classified as extraventricular neurocytomas (EVN) using DNA-methylation profiling, associated with *NTRK2* fusions instead of the usual *FGFR1* alterations so far attributed to this tumoural entity [1, 2].

Case 1 concerned a 23-year-old woman who had a personal history of migraines, with revealing generalised epileptic seizures. MRI showed a centimetric lesion in T2 and FLAIR hypersignal in the posterior part of the left superior frontal gyrus, without spontaneous T1 hypersignal and a light contrast enhancement on injected T1 sequences. The imaging was stable for 4 years and the patient was asymptomatic under antiepileptic monotherapy. Over the next 3 years, a progressive worsening of the epilepsy was noted (under triple therapy) as well as increased contrast enhancement of the lesion (Figure 1A). A total removal of the lesion was then performed. At 14 months post-operatively, no neurological deficits or epileptic seizures were observed.

Histopathologically, the tumour had an oligo-like component lying in a neurofibrillary background with strong olig2 and synaptophysin positivities (Figure 1G,K,M). The neurofilament network was poor in the centre of the tumour and denser at the periphery in favour of an at less partially circumscribed glioma. ATRX expression was preserved and GFAP was expressed. Mib1 proliferative index was below 5%. Diagnoses of pilocytic astrocytoma, ganglioglioma, gangliocytoma, diffuse leptomeningeal glioneuronal tumour or glioneuronal tumour kinase-fused (GNT_KinF_A) could be discussed, highlighting the previously reported wide overlap of EVN with various glioneuronal entities [1–4].

In case 2, intracerebral calcifications were detected on profile skull x-rays during orthodontic treatment in an asymptomatic 15-year-old girl. MRI showed a pure intraventricular lesion in the frontal horn of the left lateral ventricle, extended to both lateral ventricles through an invasion of the septum pellucidum. This did not affect the corpus callosum. Contrast enhancement was seen in the septum pellucidum and along the outer wall of the frontal horn of the left lateral ventricle (Figure 1B). A total removal of the lesion was performed. Microscopically, the

tumour had two components: one was oligo-like, while the other corresponded to more differentiated cells with ganglionic appearance suggestive of ganglioglioma (Figure 1H). The neurofilament network showed a well circumscribed tumour (Figure 1J). Both components were strongly stained by synaptophysin and olig2 (Figure 1L,N). ATRX expression was preserved and GFAP was expressed. Mib1 proliferative index was below 5%. Both ganglionic cell differentiation and microcalcifications have been described in EVN [1, 2]. Five years after the initial surgery, there has been no recurrence and the patient is in good health.

For the two cases, the targeted NGS sequencing was negative, and RNA-sequencing retrieved a canonic *NTRK2* fusion with *SOX6* in case 1 and *PXDC1* in case 2 (Figure 1E). Genome-wide DNA methylation profiling indicated a diagnostic score of >0.9 for the extraventricular neurocytoma methylation class (MC) in v12.5 for both tumours (0.93119 and 0.93630 for case 1 and 2, respectively) [5]. We collected the IDAT files of 7 *FGFR1::TACC1* fusion EVN (4 from the RENOCLIP Network and 3 from the GEO Database) to enrich the DKFZ Database and perform a t-SNE [5]. Both cases were in the vicinity of other EVN (Figure 1F). A previous case of EVN with a *KIF5B::NTRK2* fusion was recently reported and u-MAP analysis also placed this case in the EVN methylation class [6].

Despite definition of the MC EVN from a series of initially histopathological diagnoses of EVN, this nosology seems to present key issues [2]. First, the study describing the MC EVN lacked a central neuroradiological review confirming the absence of ventricular contact of these tumours. Additionally, 7/26 (27%) DNA-methylation proven cases have no information concerning their precise location in the CNS [2]. Recently, Sato et al. reported a left intraventricular tumour in a 30-year-old woman with histology suggestive of central neurocytoma (but the authors did not perform olig2 immunohistochemistry), *FGFR1-TACC1* fusion and a methylation score of 0.99 for the MC class of EVN [7]. This case and the current case 2 seem to suggest that a subset of tumours classified as MC EVN are not extraventricular. The cellular origin of EVN is unknown, but the fact that they form a distinct molecular group suggests that these

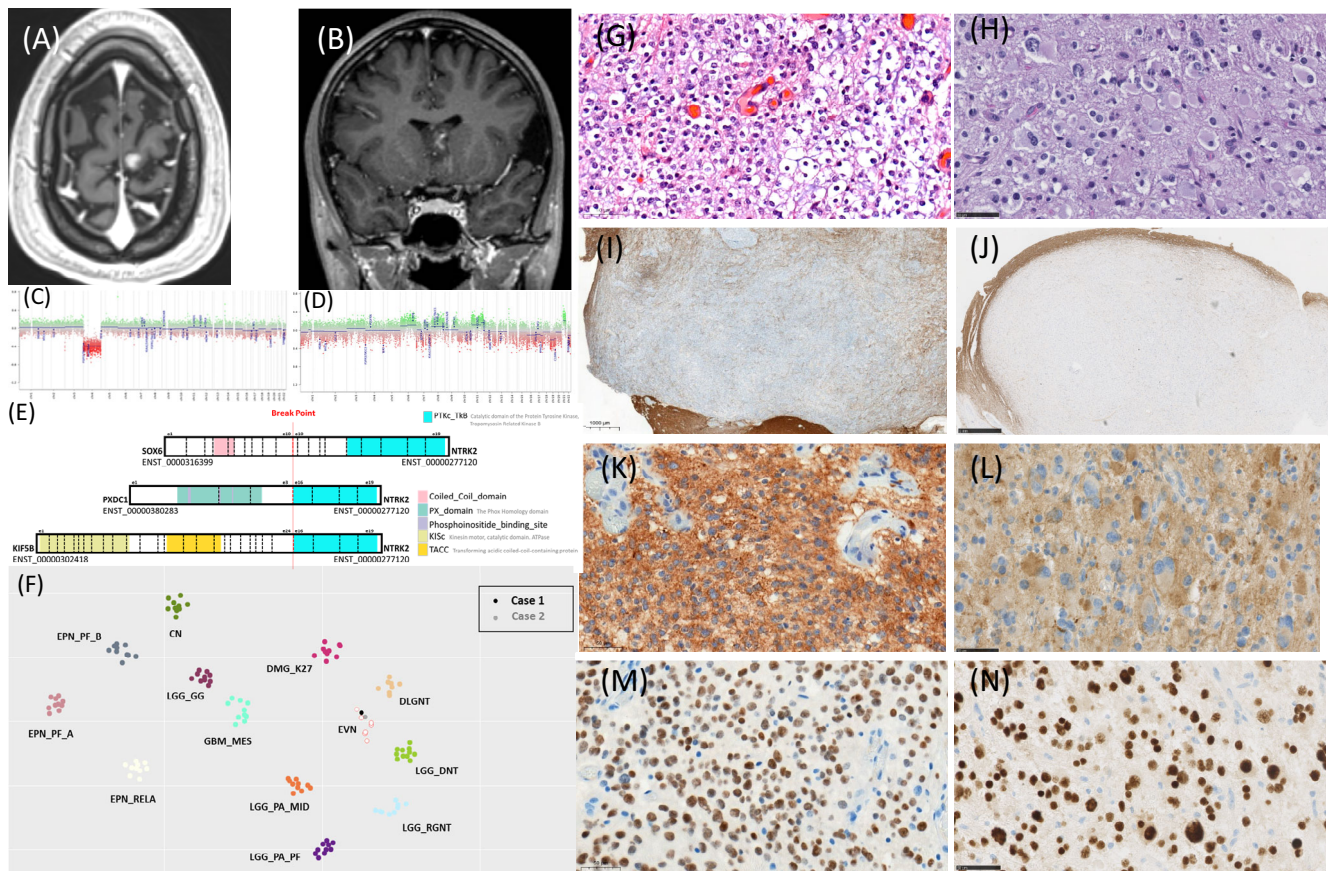


FIGURE 1 MRI on the T1 sequence shows discrete contrast enhancement of cortical (case 1) (A) or bilateral intraventricular (case 2) (B) lesions. CNV prediction from genome-wide methylation analysis with <http://www.bioconductor.org/packages/devel/bioc/html/conumee.html>, showing a flat profile except for chromosome 4 loss in case 1 (C) and a more complex profile in case 2 (D). Schematic representation of *NTRK2* fusions (E) in cases 1 and 2 alongside the case reported by Gubiotti et al. [6]. t-SNE analysis (F). H&E showed oligo-like component lying in a neurofibrillary background in case 1 (G) with ganglionic sometimes binucleated cells in case 2 (H). Neurofilaments showed a less circumscribed tumour in case 1 (I) than in case 2 (J). Synaptophysin positivity was observed in both cases: case 1 (K) and case 2 (L) as a strong nuclear staining with olig 2: case 1 (M) and case 2 (N).

tumours may arise from a specific precursor cell population, differing from the cells that give rise to central neurocytomas. Unlike the ventricular precursors of central neurocytomas, this specific cell population could possibly be extra or intraventricular.

Furthermore, the terminology ‘neurocytoma’ suggests that tumour cells express neuronal markers such as synaptophysin, but no glial markers such as Olig2. The current WHO classification states that olig2 expression has only been observed in a subset of extraventricular neurocytomas, but the cited publications report very few cases and date from a pre-methyloma era. Although the only article reporting a series of 26 MC EVN cases does not mention olig2 status, one published case of MC EVN and our two cases showed immunopositivity for this glial marker [2, 6].

The MC of EVN was reported as enriched in *FGFR1::TACC1* fusion [2]. Since they were first described, one case of MC EVN in the literature and the two current cases have been reported to harbour *NTRK2* fusions with three different genes: *KIFF5B*, *SOX6* in the current case 1 and *PXDC1* in the current case 2 (Figure 1E) [6]. The *KIFF5B::NTRK2*

fusion was also reported in a *GNT_KinF_A* [3]. The *SOX6::NTRK2* was previously reported in one glioneuronal tumour with *ATRX* alteration, kinase fusion and anaplastic features (GTAKA) whereas no *PXDC1::NTRK2* fusion has previously been described to our knowledge [8]. Several low-grade glioneuronal tumours share many overlapping histopathological (including neurocytic and oligodendroglioma-like morphology) and molecular features (including *FGFR1* and *NTRK2* fusions) [2, 3, 6, 8]. Further comprehensive studies including radiology, histopathology and genetics are needed to better characterize these tumours.

With these 2 novel cases, we have validated *NTRK2* fusions as alternative driver mutations for the MC EVN, which can be used as potential therapeutic targets. We present the second detailed case of an intraventricular presentation in the MC EVN. Our findings broaden the spectrum of MC EVN and have implications in terms of diagnosis, therapy and terminology. Further studies including radiology, histopathology, genetic and epigenetic analyses are necessary to suggest a consensual nosology proposition for these tumours.

ACKNOWLEDGEMENTS

We would like to thank the '111 des Arts' Association and 'Association pour la Recherche sur les Tumeurs Cérébrales' for their support. We are grateful to the Neuro-pathologists from the 'French Rare Tumour Network' (RENOCLIP-LOC) as well as Amélie Tartar and Karen Silva for their help. Thanks to Emmanuella Bassey for her proofreading. Samples were retrieved from Montpellier University Hospital Centre Tumour Bank BB-0033-00031 and Rennes University Hospital Centre Tumour Bank BB-0033-00056.

DATA AVAILABILITY STATEMENT

Data sharing is not applicable to this article as no new data were created or analyzed in this study.

Emmanuelle Uro-Coste^{1,2} 
 Arnault Tauziède-Espariat^{3,4} 
 Charlotte Dubucs¹
 Dan Christian Chiforeanu⁵
 Aurore Siegfried^{1,2}
 Yvan Nicaise²
 Luc Bauchet^{6,7}
 Laurent Riffaud⁸
 Franck Bielle^{9,10,11} 
 Alexandre Vasiljevic^{12,13}
 Romain Appay^{14,15}
 Solène Evrard^{1,2}
 Pascale Varlet^{3,4}
 Valérie Rigau^{7,16}

The Biopathology RENOCLIP-LOC network

¹*Department of Pathology, Toulouse University Hospital, Toulouse, France*

²*INSERM U1037, Cancer Research Center of Toulouse (CRCT), Toulouse, France*

³*GHU Psychiatrie et Neurosciences, Site Sainte-Anne, Service de Neuropathologie, Paris, France*

⁴*Institut de Psychiatrie et Neurosciences de Paris (IPNP), UMR_S1266, INSERM, Equipe IMA-BRAIN (Imaging Biomarkers for Brain Development and Disorders), University of Paris, Paris, France*

⁵*Department of Pathology, Rennes University Hospital, Rennes, France*

⁶*Department of Neurosurgery, Montpellier University Hospital, Montpellier, France*

⁷*Institute for Neuroscience of Montpellier (IGF), INSERM U1051, Montpellier University Hospital, Montpellier, France*

⁸*Department of Neurosurgery, University Hospital, Rennes, France*

⁹*Department of Neuropathology, AP-HP, Hôpitaux Universitaires Pitié-Salpêtrière Charles Foix, Paris, France*

¹⁰*Sorbonne University, UPMC, University of Paris, Paris, France*

¹¹*Brain and Spine Institute (ICM; INSERM, UMRS 1127; CNRS, UMR 7225), Paris, France*

¹²*Department of Neuropathology, Groupe Hospitalier Est, Hospices Civils de Lyon, Bron, France*

¹³*Claude Bernard University Lyon 1, Lyon, France*

¹⁴*APHM, CHU Timone, Service d'Anatomie Pathologique et de Neuropathologie, Marseille, France*

¹⁵*Aix-Marseille Univ, CNRS, INP, Inst Neurophysiopathol, Marseille, France*

¹⁶*Department of Pathology, Montpellier University Hospital, Montpellier, France*

Correspondence

Emmanuelle Uro-Coste, Service d'Anatomie et Cytologie Pathologiques, Institut Universitaire du Cancer-Oncopole, 1 avenue Irène Joliot-Curie, 31059 Toulouse cedex 9, France.

Email: uro-coste.e@chu-toulouse.fr

ORCID

Emmanuelle Uro-Coste  <https://orcid.org/0000-0001-7300-5724>

Arnault Tauziède-Espariat  <https://orcid.org/0000-0002-9979-0297>

Franck Bielle  <https://orcid.org/0000-0001-6564-6388>

REFERENCES

- Central Nervous System Tumours. WHO classification of tumours. 5th ed. Lyon, France: International Agency for Research on Cancer; 2021. p. 153–5.
- Sievers P, Stichel D, Schrimpf D, Sahm F, Koelsche C, Reuss DE, et al. FGFR1:TACC1 fusion is a frequent event in molecularly defined extraventricular neurocytoma. *Acta Neuropathol.* 2018; 136(2):293–302.
- Sievers P, Sill M, Schrimpf D, Friedel D, Sturm D, Gardberg M, et al. Epigenetic profiling reveals a subset of pediatric-type glioneuronal tumors characterized by oncogenic gene fusions involving several targetable kinases. *Acta Neuropathol.* 2022;144(5): 1049–52.
- Tauziède-Espariat A, Dangouloff-Ros V, Figarella-Branger D, Uro-Coste E, Nicaise Y, André N, et al. Clinicopathological and molecular characterization of three cases classified by DNA-methylation profiling as "glioneuronal tumors, NOS, subtype A". *Acta Neuropathol.* 2022;144(6):1179–83.
- Capper D, Hovestadt V, Schrimpf D, Sturm D, Koelsche C, Sahm F, et al. DNA methylation-based classification of central nervous system tumours. *Nature.* 2018;555(7697):469–74.
- Gubbiotti MA, Santi M, Storm PB, Li M, Xu F, Abdullaev Z, et al. First-time identification of a KIF5B-NTRK2 fusion in extraventricular neurocytoma. *J Neuropathol Exp Neurol.* 2023;82(3):272–5.
- Sato D, Takami H, Takayanagi S, Ikemura M, Matsuura R, Tanaka S, et al. Intraventricular central neurocytoma molecularly defined as extraventricular neurocytoma: a case representing the discrepancy between clinicopathological and molecular classifications. *Brain Tumor Pathol.* 2023;40(4): 230–4.
- Bogumil H, Sill M, Schrimpf D, Ismer B, Blume C, Rahmzade R, et al. Glioneuronal tumor with ATRX alteration, kinase fusion and anaplastic features (GTAKA): a molecularly distinct brain tumor type with recurrent NTRK gene fusions. *Acta Neuropathol.* 2023;145(5):667–80.