



HAL
open science

Étude comparative de classifieurs en apprentissage profond pour le diagnostic des lésions ductulaires intra-hépatiques

Nihad Bendada Soonekindt, Irene Mapped Fogaing, Vincent Vuiblet, Rudy Merieux, Julien Calderaro, Eric Desjardin, Nicolas Passat, Camille Boulagnon-Rombi

► To cite this version:

Nihad Bendada Soonekindt, Irene Mapped Fogaing, Vincent Vuiblet, Rudy Merieux, Julien Calderaro, et al.. Étude comparative de classifieurs en apprentissage profond pour le diagnostic des lésions ductulaires intra-hépatiques. Colloque Français d'Intelligence Artificielle en Imagerie Biomédicale (IABM), 2024, Grenoble, France. hal-04406673

HAL Id: hal-04406673

<https://hal.science/hal-04406673v1>

Submitted on 28 Mar 2024

HAL is a multi-disciplinary open access archive for the deposit and dissemination of scientific research documents, whether they are published or not. The documents may come from teaching and research institutions in France or abroad, or from public or private research centers.

L'archive ouverte pluridisciplinaire **HAL**, est destinée au dépôt et à la diffusion de documents scientifiques de niveau recherche, publiés ou non, émanant des établissements d'enseignement et de recherche français ou étrangers, des laboratoires publics ou privés.

COMPARATIVE STUDY OF DEEP LEARNING CLASSIFIERS FOR THE DIAGNOSIS OF INTRAHEPATIC DUCTULAR LESIONS

AUTHORS

Nihad. BENDADA SOONEKINDT 1,2, Irène. MAPPE FOGAING 1, Rudy. MERIEUX 1, Vincent. VUIBLET 1,2, Julien CALDERARO 3, Eric. DESJARDIN 4, Nicolas. PASSAT 4, Camille. BOULAGNON ROMBI 2,5.

AFFILIATIONS

1. Institut d'Intelligence Artificielle en Santé (IIAS), CHU de Reims, Université de Reims Champagne Ardenne, Reims, France
2. CHU de Reims, Service de Pathologie, Reims, France
3. Université Paris Est Créteil, INSERM, IMRB, CHU Henri Mondor, Service d'Anatomie et Cytologie Pathologiques, Créteil, France
4. Université de Reims Champagne Ardenne, CRESTIC, Reims, France
5. Université de Reims Champagne Ardenne, UMR CNRS 7369 MEDyC, Reims, France

INTRODUCTION

Intrahepatic cholangiocarcinoma (iCCA) is a primary hepatic malignancy that can be difficult to diagnose pathologically [1]. Its prevalence among primary liver cancers ranges from 10 to 15%. Its worldwide incidence rose 22% between 1987 and 2007 [2]. It presents numerous differential diagnoses, including benign ductular tumors such as biliary adenomas (BDA) and biliary hamartomas (BDH), with few discriminating histological criteria on biopsy specimens [3].

OBJECTIVE

This study aimed to explore deep learning performance using convolutional neural networks (CNN) to classify intrahepatic ductular lesions (iCCA and benign mimickers).

METHODOLOGY

We used a bi-centric cohort comprising 397 WSI that included annotated areas of "normal liver," "benign tumor" (biliary adenoma and hamartoma) and "malignant tumor" (intrahepatic cholangiocarcinoma).

We tested different classifiers (VGG16, VGG19, InceptionV3, DenseNet169, Xception, MobileNetV2, and ResNet50 models) with 3 different scenarios of binary and multi-class classification. The best model (VGG16) was used in a pipeline applied directly to whole slide images (WSI) as in routine medical practice.

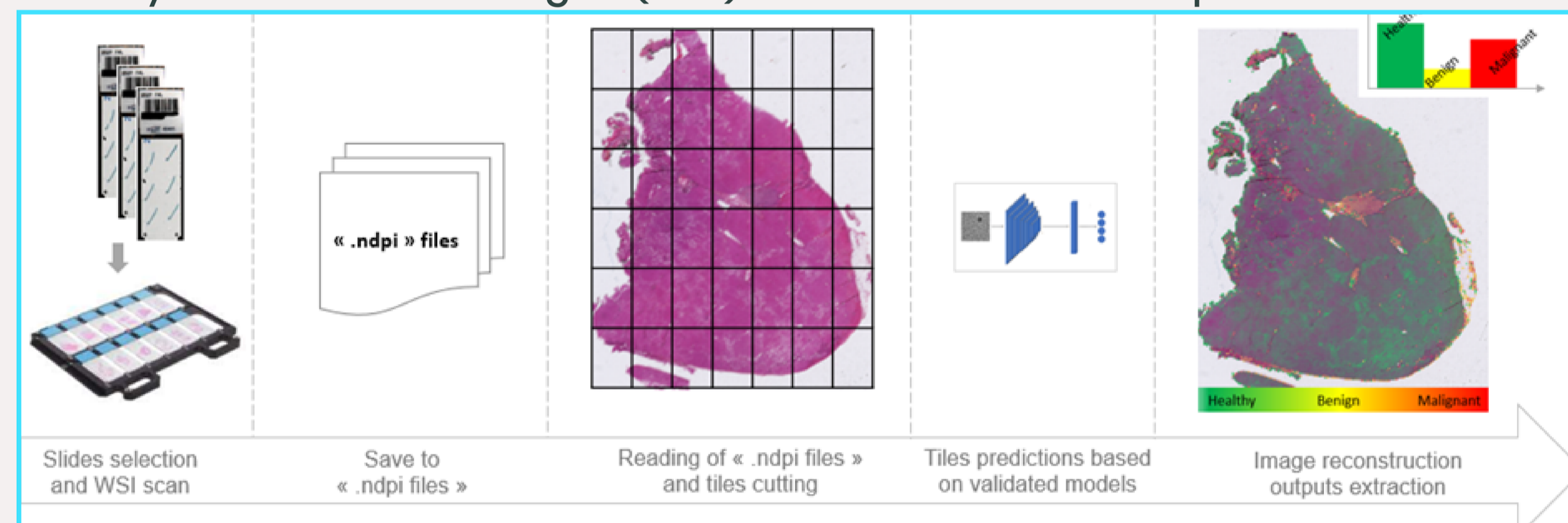


FIG 1: AUTOMATED PIPELINE FOR SLIDES CLASSIFICATION. FROM SLIDES SELECTION TO IMAGE PREDICTION.

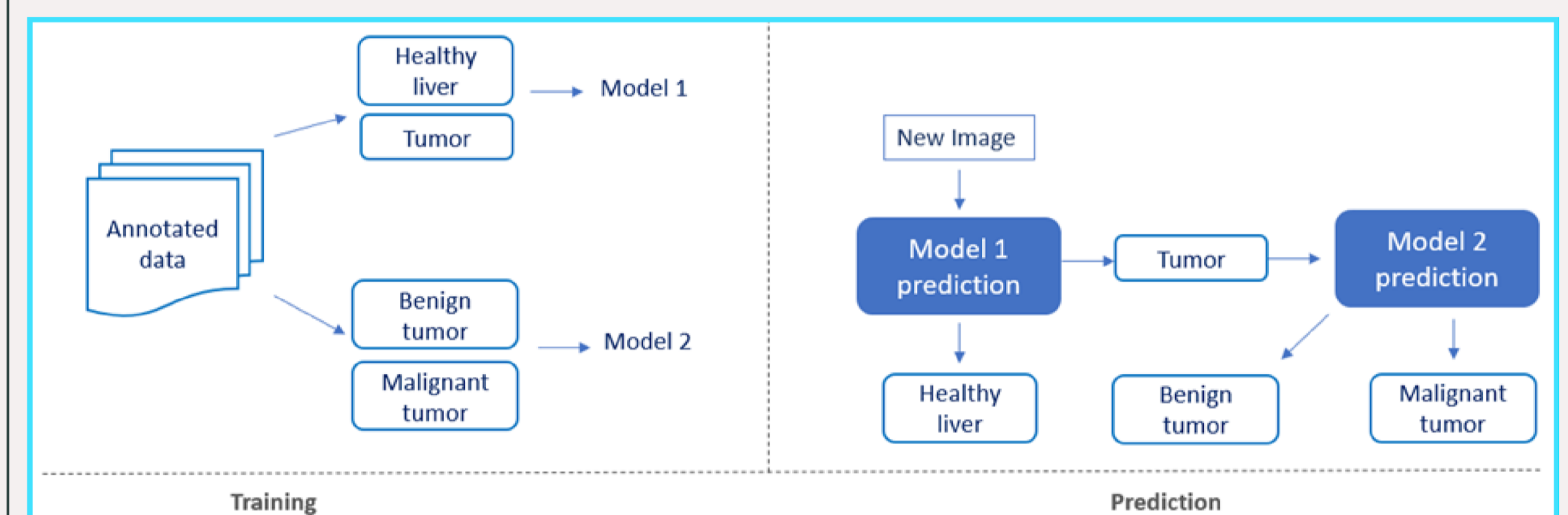


FIG 2: CLASSIFICATIONS APPROACH.

LEFT: TRAINING PART (MODEL 1) CLASSIFY HEALTHY LIVER AND TUMOR. RIGHT: PREDICTION PART (MODEL 2) CLASSIFY BENIGN TUMORS AND MALIGNANT TUMORS.

	Models	epochs	Batch size	Learning rate	Patience	trainable
Occurrences	Vgg16, Vgg19, MobileNet v2, Inception v3, Xception, ResNet-50, DenseNet	Fixed	100, 150, 200	1e-3, 1e-5, 1e-6, 1e-7	4, 5, 7, 20	True, False
Total number	7	1	3	4	4	2
7 x 1 x 3 x 4 x 4 x 2 = 672 training						

TABLE 1: GRIDSEARCH PARAMETERS.

RESULTS

The best accuracy was achieved with multi-class classification and reached 90% with VGG19, VGG16, MobileNetV2, Xception and DenseNet169 at tile level. The "malignant tumor" class was the best predicted class compared to the other classes, with an accuracy reaching 94%. At slide Level, predictions made by VGG16 and histological features were consistent.

Healthy liver (N= 23645) and Tumor B (N= 15910) and tumor M (N = 73735)							
Vgg 19 (accuracy = 0.90)				Vgg 16 (accuracy = 0.90)			
	Precision	Recall	F1 score		Precision	Recall	F1 score
Healthy liver	0.84	0.94	0.89	Healthy liver	0.83	0.94	0.88
Tumor B	0.78	0.60	0.68	Tumor B	0.78	0.62	0.69
Tumor M	0.94	0.95	0.94	Tumor M	0.95	0.94	0.94
ResNet 50 (accuracy = 0.89)				MBN v2 (accuracy = 0.90)			
Healthy liver	0.82	0.92	0.87	Healthy liver	0.83	0.92	0.87
Tumor B	0.75	0.60	0.67	Tumor B	0.77	0.65	0.70
Tumor M	0.93	0.94	0.94	Tumor M	0.94	0.94	0.94
DenseNet 169 (accuracy = 0.90)				Xception (accuracy = 0.90)			
Healthy liver	0.86	0.93	0.89	Healthy liver	0.86	0.92	0.89
Tumor B	0.74	0.66	0.70	Tumor B	0.75	0.65	0.70
Tumor M	0.94	0.94	0.94	Tumor M	0.94	0.95	0.94
Inception v3 (accuracy = 0.89)							
Healthy liver	0.85	0.91	0.88				
Tumor B	0.73	0.60	0.66				
Tumor M	0.93	0.94	0.94				

TABLE 2: MODEL CLASSIFICATION REPORT FOR THE MULTICLASS APPROACH; ACCURACY, PRECISION, RECALL AND F1-SCORE BY CLASS.

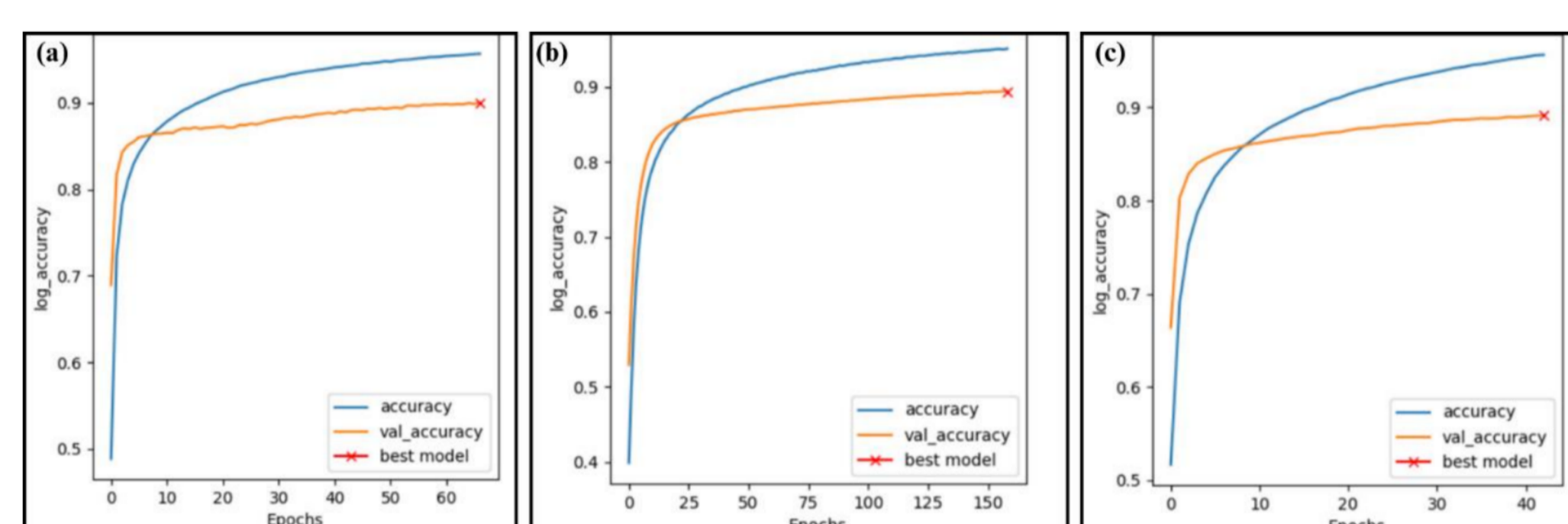


FIG 3: ACCURACY CURVES OF MULTI-CLASS CLASSIFICATION. A) MULTI-CLASS CLASSIFICATION ACCURACY 90% OF THE VGG16 MODEL. B) MULTI-CLASS CLASSIFICATION ACCURACY 89 % OF THE MOBILENETV2 MODEL. C) MULTI-CLASS CLASSIFICATION ACCURACY 89 % OF THE RESNET50 MODEL.

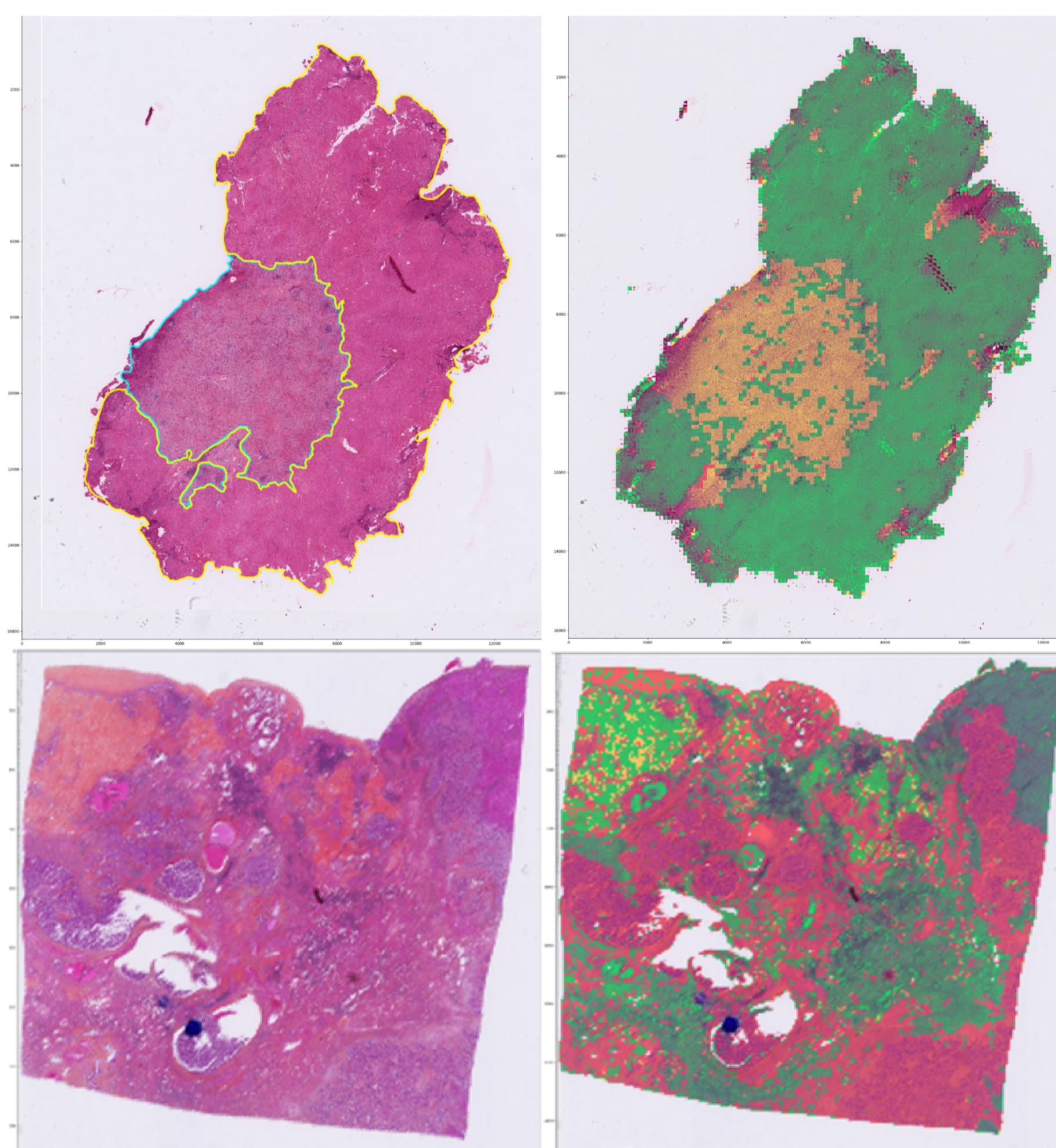


FIG 4: EXAMPLE OF HES STAINED WSI (LEFT) AND CORRESPONDING PREDICTED SLIDE AFTER PIPELINE EXECUTION (RIGHT). TOP LINE: BILIARY ADENOMA CORRECTLY PREDICTED BENIGN (YELLOW) IN A BACKGROUND OF NORMAL LIVER (GREEN). BOTTOM LINE: INTRAHEPATIC CHOLANGIOCARCINOMA CORRECTLY PREDICTED MALIGNANT (RED) WITH INTERMIXED RESIDUAL NORMAL LIVER PARENCHYMA (GREEN).

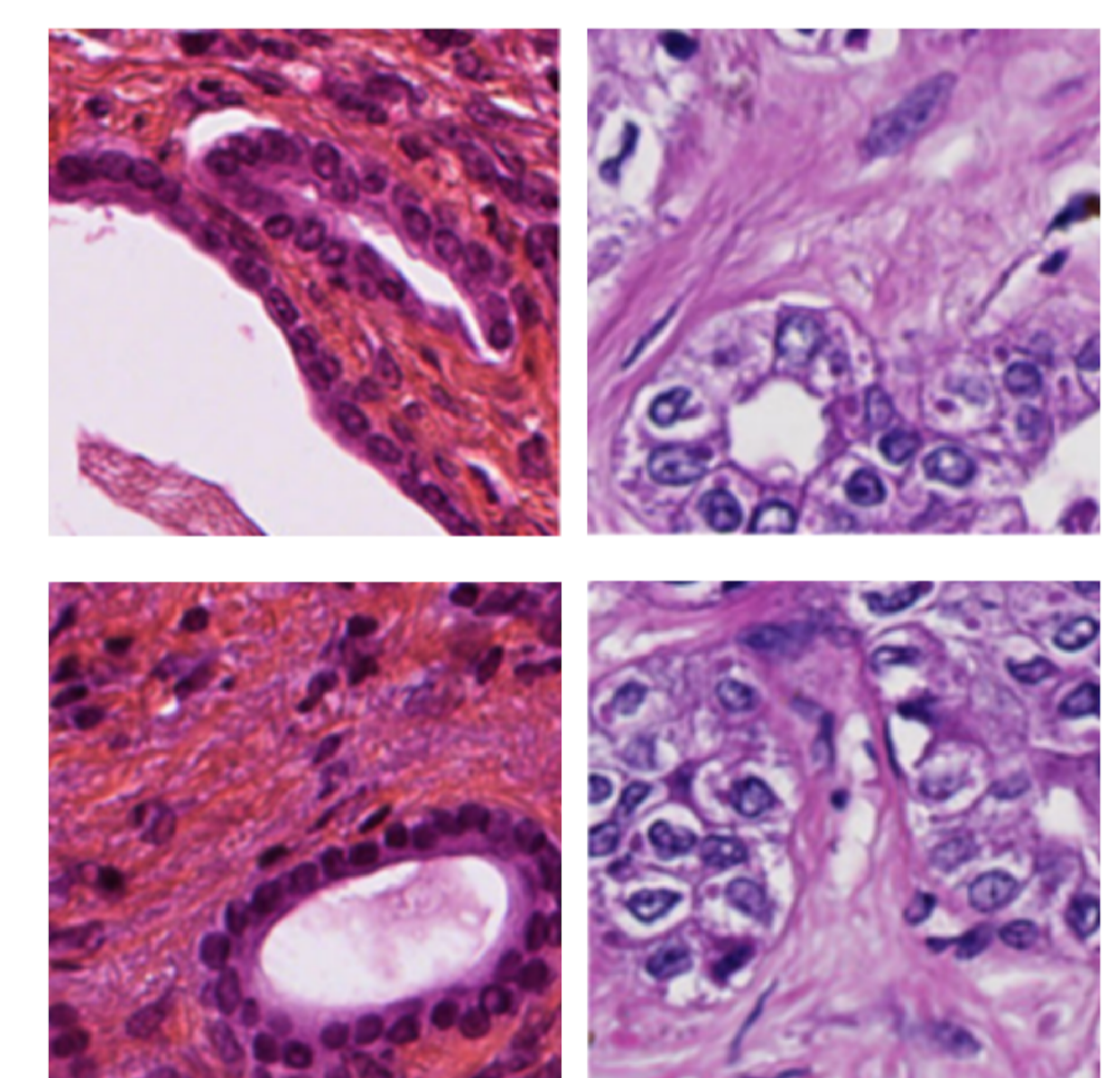


FIG 5: EXAMPLES OF WRONGLY PREDICTED TILES. WRONG PREDICTIONS WITH THE MOST IMPORTANT CONFOUNDING ELEMENTS, NAMELY CONNECTIVE TISSUE AND DUCTAL STRUCTURES.

LEFT COLUMN REPRESENTS BENIGN TUMOR TILES PREDICTED AS NORMAL LIVER.

RIGHT COLUMN SHOWS MALIGNANT TUMOR TILES PREDICTED AS BENIGN TUMOR (TOP) AND AS NORMAL LIVER (BOTTOM).

CONCLUSION

In this study, we demonstrated that CNN models were able to predict the "normal liver", "benign tumor" and "malignant tumor" classes with good performance. The "malignant tumor" class was the best predicted, with an accuracy of 94%. Spatial superposition between model predictions and HES images was almost perfect, enabling us to envisage the use of our pipeline in routine medical practice.

RELATED LITERATURE

- [1] El-Diwany R, Pawlik TM, Ejaz A. Intrahepatic Cholangiocarcinoma. Surg Oncol Clin N Am. oct 2019;28(4):587-99.
- [2] Tyson GL, Ilyas JA, Duan Z, Green LK, Younes M, El-Serag HB, et al. Secular trends in the incidence of cholangiocarcinoma in the USA and the impact of misclassification. Dig Dis Sci. déc 2014;59(12):3103-10.
- [3] Pujals A, Bioulac-Sage P, Castain C, Charpy C, Zafrani ES, Calderaro J. BRAF V600E mutational status in bile duct adenomas and hamartomas. Histopathology. oct 2015;67(4):562-7.