



HAL
open science

A dedicated Y-shaped percutaneous ECMO cannula for femoral 2-in-1 vascular access during high-risk procedures

Thomas Modine, Flavien Vincent, Cédric Delhaye, Eric van Belle

► **To cite this version:**

Thomas Modine, Flavien Vincent, Cédric Delhaye, Eric van Belle. A dedicated Y-shaped percutaneous ECMO cannula for femoral 2-in-1 vascular access during high-risk procedures. *Catheterization and Cardiovascular Interventions*, 2020, 97 (5), pp.959-961. 10.1002/ccd.29299 . hal-04404144

HAL Id: hal-04404144

<https://hal.science/hal-04404144v1>

Submitted on 18 Jan 2024

HAL is a multi-disciplinary open access archive for the deposit and dissemination of scientific research documents, whether they are published or not. The documents may come from teaching and research institutions in France or abroad, or from public or private research centers.

L'archive ouverte pluridisciplinaire **HAL**, est destinée au dépôt et à la diffusion de documents scientifiques de niveau recherche, publiés ou non, émanant des établissements d'enseignement et de recherche français ou étrangers, des laboratoires publics ou privés.

CASE REPORT

Full Access

A dedicated Y-shaped percutaneous ECMO cannula for femoral 2-in-1 vascular access during high-risk procedures

Thomas Modine MD, PhD, Flavien Vincent MD, PhD, Cédric Delhay MD, Eric Van Belle MD, PhD

First published: 01 October 2020

Abstract

High-risk transcatheter procedures requiring hemodynamic support are growing and require multiple vascular access that may be challenging in cases of peripheral artery disease or lack of radial access and exposure to a higher risk of vascular complications. We report the novel utilization of a Y-shaped arterial extracorporeal membrane oxygenation (ECMO) cannula used as a single femoral access to perform percutaneous coronary intervention (PCI) and aortography during high-risk transcatheter aortic valve replacement (TAVR). The utilization of this 2-in-1 ECMO cannula may simplify vascular access and reduce vascular and bleeding complications during high-risk ECMO-supported transcatheter procedures.

1 INTRODUCTION

With the development of mechanical circulatory support and transcatheter aortic valve replacement (TAVR), efficient therapeutic solutions can be proposed to patients with severe aortic stenosis and unstable hemodynamic conditions.^{1,2} Given the high prevalence of coronary artery disease in patients with aortic stenosis (40%-75% of those undergoing TAVR), combined percutaneous coronary intervention (PCI) and structural procedures requiring mechanical circulatory support are increasingly being performed.^{3,4} Since these procedures require multiple arterial access, it can be challenging to perform them in cases of peripheral artery disease or lack of radial access, exposing patients to vascular complications. A Y-shaped peripheral arterial cannula for extracorporeal membrane oxygenation (ECMO) with a side arm branch allowing the introduction of an occlusion balloon has been developed for two main purposes—intraluminal aortic clamping in minimally invasive cardiothoracic surgery or selective perfusion of the organs that should be transplanted (compartmental ECMO) in a nonheart-beating donor.

We have reported a case in which the ECMO cannula was used in a novel way to perform PCI and aortography with a single access during a high-risk TAVR procedure requiring hemodynamic support.

2 CASE REPORT

A 67-year-old male patient was referred to our institution for cardiogenic shock. Transthoracic echocardiography indicated severe biventricular dysfunction and severe low-output low-gradient aortic stenosis. The coronary angiogram revealed a long calcified left anterior descending artery (LAD stenosis) ([Supplemental Video 1](#)). Cardiac magnetic resonance imaging confirmed myocardial viability. After hemodynamic stabilization with medical inotrope therapy, this case was discussed by the cardiology team. Owing to the high risk of hemodynamic collapse during the procedure, combined PCI and TAVR were planned under ECMO circulatory support. As the preprocedural evaluation revealed no possibility of radial access, an arterial Y-shaped cannula was used (EndoReturn, Edwards Lifescience). The procedure was performed in a hybrid operating room by an interventional cardiologist and a cardiac surgeon. A mixture of lidocaine and naropaine was injected subcutaneously for local anesthesia. After echo-guided puncture, both the femoral arteries were preclosed with a suture-based system (Perclose Proglide, Abbott). A 21-French (Fr) ECMO arterial cannula was inserted into the left femoral common artery and a 23-Fr venous cannula was inserted into the left femoral vein ([Figure 1](#)). After circulatory support initiation, percutaneous coronary angioplasty of the LAD was successfully performed via the side branch of the arterial cannula with drug-eluting stent implantation ([Supplemental Video 2](#)). Subsequently, the delivery sheath was inserted via the right femoral access, and the side branch of the arterial cannula implanted in the contralateral groin was used again to perform aortography with the pigtail catheter during the deployment of balloon-expandable 23-mm SAPIEN 3 (Edwards Lifescience) ([Supplemental Video 3](#)). ECMO was immediately weaned and explanted at the end of the procedure, and vascular access was percutaneously closed. Hemodynamic parameters remained stable throughout the procedure. The patient recovered rapidly and was discharged 10 days after defibrillator implantation and medical treatment optimization.

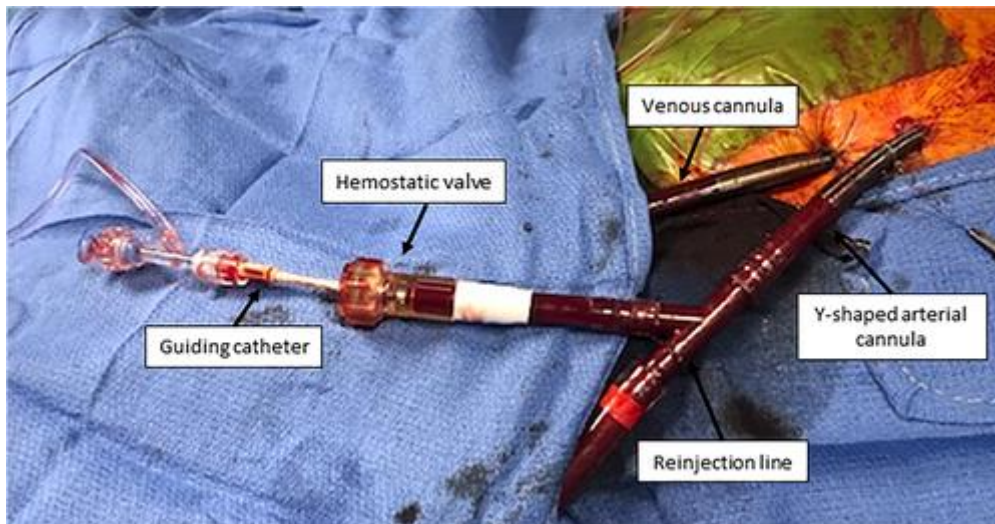


FIGURE 1

Y-shaped arterial cannula inserted into the left femoral artery with guiding catheter inserted via the side branch

3 DISCUSSION

The implementation of a Y-connector to a standard arterial ECMO cannula has been previously described,⁵⁻⁷ but it has several drawbacks. The connector is a source of friction and it is difficult to manipulate the guiding catheter.⁸ The additional length of the connector may preclude easy access to coronary catheterization with a regular length-guiding catheter, especially in tall patients. The Y-connector implementation requires sequential arterial cannula clamping to add and remove the connector and necessitates the replacement of the arterial cannula at the end of the procedures. These multiple manipulations are time consuming and may increase the risk of bleeding or infectious complications. All these drawbacks could compromise the success of the procedure and explain why this technique is not being adopted routinely in clinical practice.

We have reported a more straightforward technique for two-in-one arterial access by using a Y-shaped ECMO cannula in a modified way from its original intended use. The Y-shaped ECMO cannula was initially developed to insert and inflate an occlusion balloon in the abdominal aorta to confine the recirculation and maintain a longer and proper perfusion and oxygenation of the abdominal organs until donation or to perform endoaortic balloon occlusion in minimally invasive cardiac surgery.⁹ This cannula has the unique feature of having a Y-shaped proximal portion, with one branch for the arterial backflow line and a second short branch with a large inner diameter equipped with a rotating hemostatic valve not requiring additional connectors. The latter has a large inner diameter (21 or 23 Fr), facilitating the insertion and manipulation of the guiding catheter without compromising the ECMO flow

(Figure 2). The short length of the system allows catheterization of most of the anatomy with a regular length-guiding catheter. Moreover, this approach avoids an additional arterial puncture and could decrease the time of the procedure and risk of vascular access complications.

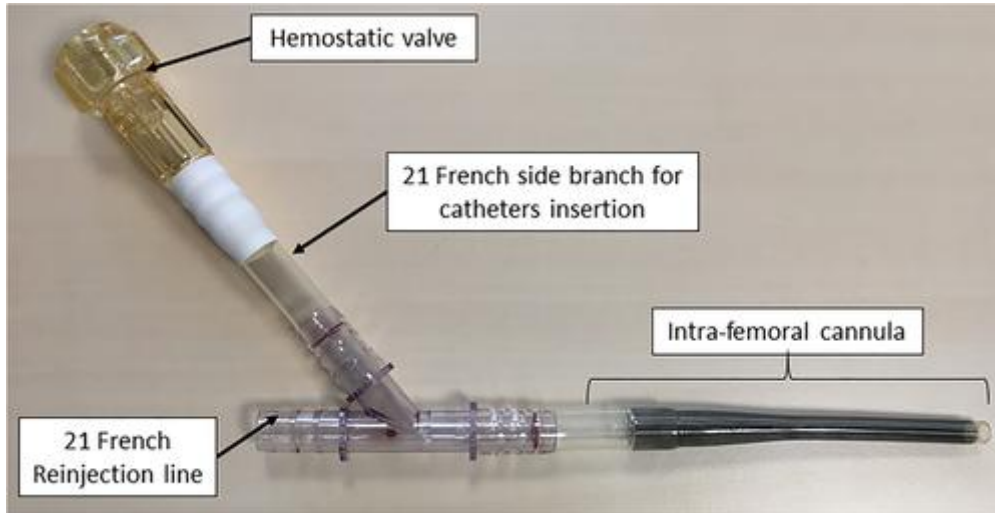


FIGURE 2

Characteristics of the Y-shaped arterial cannula

Another technique to obviate the need for additional arterial access has been specifically proposed with the Impella percutaneous microaxial catheter-mounted ventricular assist device. It consists of a brief puncture through the hemostasis valve of the 14-Fr Impella insertion sheath, followed by successive dilatations, allowing accommodation of a long 7-Fr sheath beside the Impella catheter.¹⁰

Overall, as there is a growing need to perform combined transcatheter procedures under circulatory support, a dedicated ECMO cannula could be developed with a shorter side arm and a smaller diameter to facilitate this high-risk and complex procedure.

Further studies are needed to evaluate how the two-in-one ECMO cannula can help reduce vascular complications during high-risk ECMO-supported PCI.

4 CONCLUSION

Overall, the utilization of a Y-shaped ECMO cannula is a simple, sophisticated, and easily feasible percutaneous method to obtain two-in-one arterial access in high-risk PCI or structural ECMO-supported procedures.

We encourage its use to reduce the number of vascular puncture and in cases in which the vascular access are limited.

ACKNOWLEDGMENTS

We thank the nursing staff of the hemodynamic center, the cardiac intensive care unit, and the surgery departments. We also thank Dr. Mouhammed Moussa, anesthesiologist, and Dr. Hugues Spillemaecker and Dr. Basile Verdier, interventional cardiologists for their contributions to the clinical case.

AUTHOR CONTRIBUTIONS

Flavien Vincent: contributed to the clinical case, performed data interpretation, drafted the manuscript, and approved the final manuscript as submitted. Cédric Delhaye: contributed to the clinical case and data interpretation and approved the final manuscript as submitted. Eric Van Belle: contributed to the clinical case and data interpretation and approved the final manuscript as submitted. Thomas Modine contributed to the clinical case and approved the final manuscript as submitted.

DISCLOSURES

Dr. Delhaye has served as a proctor and received speaker fees from Medtronic.

Dr Modine is a consultant for Boston Scientific, Medtronic, Edwards, Cephea, Microport, GE, and Abbott and has served as a proctor and received speaker fees from Medtronic. The other authors have nothing to disclose.

REFERENCES

- 1Drews T, Pasic M, Buz S, et al. Elective femoro-femoral cardiopulmonary bypass during transcatheter aortic valve implantation: a useful tool. *J Thorac Cardiovasc Surg.* 2013; **145**: 757-763.
- 2Singh V, Patel SV, Savani C, et al. Mechanical circulatory support devices and transcatheter aortic valve implantation (from the National Inpatient Sample). *Am J Cardiol.* 2015; **116**: 1574-1580.
- 3Seco M, Forrest P, Jackson SA, et al. Extracorporeal membrane oxygenation for very high-risk transcatheter aortic valve implantation. *Heart Lung Circ.* 2014; **23**: 957-962.
- 4Alkhouli M, Mustafa AA, Chaker Z, Alqahtani F, Aljohani S, Holmes DR. Mechanical circulatory support in patients with severe aortic stenosis and left ventricular dysfunction undergoing percutaneous coronary intervention. *J Card Surg.* 2017; **32**: 245-249.
- 5Endemann DH, Philipp A, Hengstenberg C, et al. A simple method of vascular access to perform emergency coronary angiography in patients with veno-arterial extracorporeal membrane oxygenation. *Intensive Care Med.* 2011; **37**: 2046-2049.
- 6Sulimov DS, Meyer A, Thiele H, Abdel-Wahab M. Rescue peripheral intervention using a peripheral ECMO-cannula as vascular access. *JACC Cardiovasc Interv.* 2020; **13**: e67-e68.

- 7Kapur NK, Hirst CS, Davila CD, Garcia R. Single stick access using a VA-ECMO arterial return cannula for coronary intervention in cardiogenic shock. *Catheter Cardiovasc Interv.* 2020. <https://doi.org/10.1002/ccd.29073>. [Epub ahead of print]
- 8Ücer E, Fredersdorf S, Jungbauer C, et al. A unique access for the ablation catheter to treat electrical storm in a patient with extracorporeal life support. *Europace.* 2014; **16**: 299-302.
- 9Miñambres E, Suberviola B, Dominguez-Gil B, et al. Improving the outcomes of organs obtained from controlled donation after circulatory death donors using abdominal normothermic regional perfusion. *Am J Transplant.* 2017; **17**: 2165-2172.
- 10Wollmuth J, Korngold E, Croce K, Pinto DS. The single-access for hi-risk PCI (SHiP) technique. *Catheter Cardiovasc Interv.* 2020; **96**: 114-116.
- 11Vincent F, Spillemaecker H, Kyheng M. Ultrasound Guidance to Reduce Vascular and Bleeding Complications of Percutaneous Transfemoral Transcatheter Aortic Valve Replacement: A Propensity Score–Matched Comparison. *Journal of the American Heart Association.* 2020; **9**(6):e014916. <http://dx.doi.org/10.1161/jaha.119.014916>.