



HAL
open science

Toward a robust swallowing detection for an implantable active artificial larynx: a survey

Adrien Mialland, Ihab Atallah, Agnès Bonvilain

► To cite this version:

Adrien Mialland, Ihab Atallah, Agnès Bonvilain. Toward a robust swallowing detection for an implantable active artificial larynx: a survey. *Medical and Biological Engineering and Computing*, 2023, Springer, 61 (6), pp.1299-1327. 10.1007/s11517-023-02772-8 . hal-04403433

HAL Id: hal-04403433

<https://hal.science/hal-04403433v1>

Submitted on 30 May 2024

HAL is a multi-disciplinary open access archive for the deposit and dissemination of scientific research documents, whether they are published or not. The documents may come from teaching and research institutions in France or abroad, or from public or private research centers.

L'archive ouverte pluridisciplinaire **HAL**, est destinée au dépôt et à la diffusion de documents scientifiques de niveau recherche, publiés ou non, émanant des établissements d'enseignement et de recherche français ou étrangers, des laboratoires publics ou privés.

Toward a robust swallowing detection for an implantable active artificial larynx: A survey

Adrien Mialland ^{*,a}, Ihab Atallah^b, and Agnès Bonvilain^a

^aUniv. Grenoble Alpes, CNRS, Grenoble INP, Gipsa-lab, 38000 Grenoble, France ¹

^bOtorhinolaryngology, CHU Grenoble Alpes, 38700 La Tronche, France ¹

¹Institute of Engineering and Management Univ. Grenoble Alpes

*Corresponding author: adrien.mialland@grenoble-inp.fr

Abstract

Total laryngectomy consist in the removal of the larynx and is intended as a curative treatment for laryngeal cancer, but it leaves the patient with no possibility to breathe, talk and swallow normally anymore. A tracheostomy is created to restore breathing through the throat, but the aero-digestive tracts are permanently separated and the air no longer passes through the nasal tracts, which allowed filtration, warming, humidification, olfaction and acceleration of the air for better tissue oxygenation. As for phonation restoration, various techniques allow the patient to talk again. The main one consists of a tracheo-esophageal valve prosthesis that makes the air passes from the esophagus to the pharynx, and makes the air vibrate to allow speech through articulation. Finally, swallowing is possible through the original tract as it is now isolated from the trachea. Yet, many methods exist to detect and assess a swallowing, but none is intended as a definitive restoration technique of the natural airway, which would permanently close the tracheostomy and avoid its adverse effects. In addition, these methods are non-invasive and lack detection accuracy. The feasibility of an effective early detection of swallowing would allow to further develop an implantable active artificial larynx and therefore restore the aero-digestive tracts. A previous attempt has been made on an artificial larynx implanted in 2012, but no active detection was included and the system was completely mechanic. This led to residues in the airway because of the imperfect sealing of the mechanism. An active swallowing detection coupled with indwelling measurements would thus likely add a significant reliability on such a system as it would allow to actively close an artificial larynx. So, after a brief explanation of the swallowing mechanism, this survey intends to first provide a detailed consideration of the anatomical region involved in swallowing, with a detection perspective. Second, the swallowing mechanism following total laryngectomy surgery is detailed. Third, the current non-invasive swallowing detection technique and their limitations are discussed. Finally, the previous points are explored with regard to the inherent requirements for the feasibility of an effective swallowing detection for an artificial larynx.

Keywords - swallowing detection, total Laryngectomy, implantable medical devices, artificial larynx, deglutition

1 Introduction

Total laryngectomy is the standard for surgical treatment of advanced laryngeal cancer [1]. It consists in the resection of the larynx and is indicated for locally advanced tumors that are not suitable for open or endoscopic partial laryngectomy. While this is by far the main reason that leads to a total laryngectomy, it is also suitable for non-functioning larynx either post-traumatic or due to neurological diseases. Globocan evaluates the laryngeal cancer incidence to 185000 in 2020 worldwide with a possible increase estimated to 284000 in 2040 [2].

In normal conditions, the primary roles of the larynx are to keep the airway open during breathing, to close it during swallowing, and to allow the phonation as it holds the vocal cords (Figure 1). When a total laryngectomy is performed, the larynx is resected along with the hyoid bone. Muscles that partly attach to the hyo-laryngeal structure are dissociated and left in place if the tumor

spread allows it. The larynx is also divided from the trachea under the cricoid cartilage, which requires a tracheostomy to ensure breathing [4] (the trachea is sewn on the throat, Figure 2A). In addition, since the first total laryngectomy conducted by *Theodore Billroth* in 1873 [5], improvements mainly came from treatments, medications and the creation of less invasive alternative methods such as partial laryngectomy [6, 7], but the essential part of a total laryngectomy has not substantially changed. Consequently, the total laryngectomy leaves the aero-digestive tracts permanently separated, no more phonation is possible, the loss of cough increases tracheo-bronchial infection incidence, swallowing is achieved through the isolated pharynx and no air passes through nasal tracts anymore, which allowed sense of taste and smell, filtration, warming, humidification, olfaction and acceleration of the air for better tissue oxygenation. However, the voice can be restored with various techniques [8]. The most effective approach consists in implanting a valve through a fistula between the esophagus and the trachea to allow the air to pass. Doing so, the prosthesis makes the air

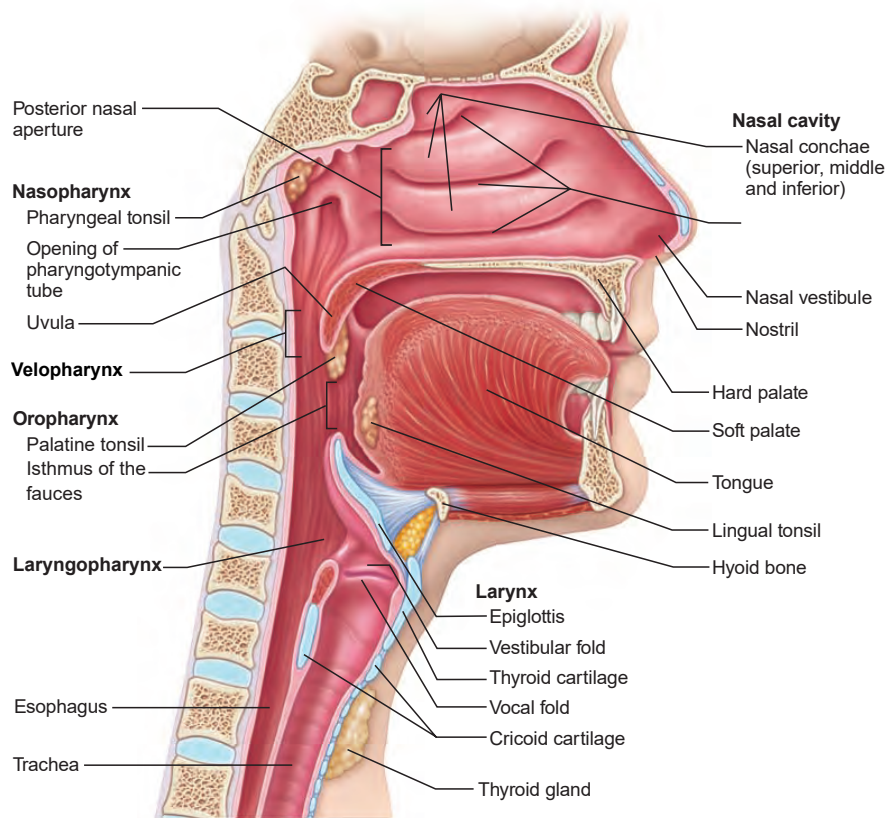


Fig. 1. Head and neck anatomy from Marieb et al. [3].

vibrate and the phonation is possible with a relatively natural articulation (Figure 2B). However, the valve has to frequently be replaced, the voice sounds low and little modulation is possible [9]. Another solution consists in making the air vibrate with an electro-larynx (Figure 2C). Its usage requires little to no training, but the voice sounds robotic [10]. Finally, it is also possible to use an esophageal voice, which consists in controlled eructation in order to pronounce vowels one after another (Figure 2D). This can lead to a relatively satisfactory phonation, but requires lots of training [11].

Even though patients report satisfactory conditions after the surgery, total laryngectomy is a life changing and impacts overall quality of life and subsequent areas, such as social functioning and physical integrity [12]. While tracheo-esophageal voice helps [13], partial laryngectomy may reduce the impact on quality of life as it partially preserves the aero-digestive tract functions [14]. Indeed, the voice may be impaired depending on the type of partial laryngectomy, but the original tracts allows the air to flow through the nose and no tracheostomy is required. So, this suggests the need in rehabilitation techniques to better restore breathing during total laryngectomy surgery and avoid the mentioned drawbacks of the tracheostomy. Yet, no readily available methods exist to permanently close the tracheostomy. On one hand, in the past decades, human laryngeal transplantation showed 3 published successful attempts [15–18]. The first one was performed in 1998 and showed promising results [18], but the graft had to be explanted after 14 years of viable functioning, because of chronic rejection [19]. Following attempts are also encouraging, but laryngeal transplantation needs carefully

chosen donors, still shows sub optimal recovery [20], and the need of immunosuppression has been estimated to increase up to 400 times the relative risk of developing a malignancy, compared to the general population [21]. Despite this risks, laryngeal transplantation may lead to an increase in post-surgery quality of life [18] and 75% of surveyed laryngectomy patient would accept a transplantation if it is offered [22]. On the other hand, the development and the implantation of an artificial larynx have first been performed in 2012 by *Debry et al.* [23, 24]. The prosthesis was exclusively passive and formed of 2 mechanical parts: (1) an irremovable tracheal prosthesis with a porous titanium junction with the trachea, which was implanted in the first step to ensure its colonization by tissues, and (2) a removable part composed of concentric valves that enables inhalation and exhalation. The patient could breathe and eat in a natural manner under medical control, for several months and even a year. But no permanent closure of the tracheostomy was possible due to the imperfect sealing of the valves, leading to food residues in the trachea. In addition, a lack of integration of the irremovable part could cause obstruction [25] and the rigidity of the material resulted in the partial compression of the trachea [26].

But this relative success still brings new possibilities in laryngeal function rehabilitation. It has the advantage to compensate for the possible lack of donor encounters with laryngeal transplantation, and the rapidly growing field of bio-engineering could provide more reliable and suitable solutions, without the need of immunosuppression [26–28]. But despite these ongoing research areas, no active implantable solution is proposed in other to predict a swallowing and to close any mechanism

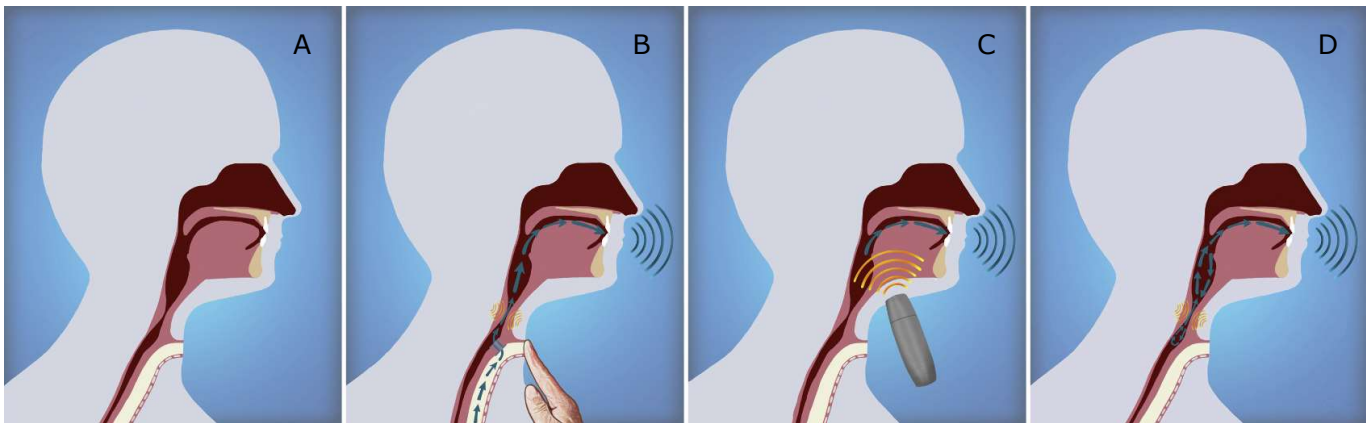


Fig. 2. Anatomy and voice production following total laryngectomy from Tang et al. [8]. **A)** The tracheostomy leaves the aero-digestive tract separated as the trachea is sewn on the throat to restore breathing. **B, C, D)** Voice restoration techniques with **B)** a tracheo-esophageal prosthesis, which allows the air to pass from the trachea to the esophagus and makes it vibrate, **C)** an electro-larynx, which makes the air vibrate with a vibrating membrane from under the jaw, **D)** the esophageal voice which consist in controlled eructations.

that would emulate the sphincter function of the larynx. This would, however, significantly increase the robustness of an artificial larynx, provided that an indwelling detection scheme meets some critical criteria: (1) Swallowing detection must be performed early enough so that any additional time for the closure of the airway does not exceed a critical time point. (2) No false negative detection should be allowed to provide a secure detection and airway closure. (3) Any measure has to be considered with regard to the anatomy post total laryngectomy surgery and must not further impair the head and neck area to ensure the remaining swallowing mechanism functioning. (4) The detection system should seek as little power consumption as possible to ensure long-term implantation.

Swallowing detection has long been studied in order to analyse the dysphagia in a clinical practice. Thereby, most research intended to detect it in a non-invasive manner. In case of invasive measurements, studies did not inherently seek for a robust detection, but rather muscle activity and swallowing mechanism analysis. So, this survey intends to analyse the feasibility of such a robust swallowing detection system. Therefore, detailed explanation will be given of the relevant head and neck area, but for a general understanding of the anatomy, please refer to the following books [3, 29]. The paper is organized as follow: section 2 gives a brief explanation of the swallowing mechanism. Section 3 provides a detailed consideration of the anatomical regions involved in swallowing, with a detection perspective. Section 4, details the swallowing mechanism after a total laryngectomy. Section 5 explores the current non-invasive swallowing detection techniques and their limitations are discussed. Finally, section 6 develops the previous points with regard to the inherent requirements for the feasibility of an effective swallowing detection, for an artificial larynx.

2 Swallowing mechanism

Swallowing is performed more than a thousand times a day with the coordinated sequence of more than 25 pairs of muscles acting in synergy. The primary goal of swallowing is to carry the bolus

from the oral cavity to the stomach and is commonly divided into 4 discrete but sequential stages. The first 2 stages are primarily under voluntary control, and are sometimes grouped into a unique oral stage as they both occur in the oral cavity, whereas the 2 later stages are mostly reflex [30–36]:

Preparatory stage: the food is broken down via mastication and many muscles helps to contain the liquid or the food and to move the jaw. The soft palate is depressed against the posterior part of the tongue, with the contraction of the palatoglossus muscles, to seal off the oral cavity posteriorly and avoid premature spillage into the pharynx.

Propulsion stage: Once a cohesive bolus is formed, this stage moves the bolus posteriorly and propels it into the pharynx. The bolus is first hold in a groove formed by the tongue and the oral cavity is still seals off by the soft palate. The groove is then displaced posteriorly by a wave-like movement of the tongue to guide the bolus toward the pharynx. This specific action of the tongue is often described as the "squeezing movement", where the tongue presses against the hard palate in a posterior direction and the floor of the mouth strengthens to support the motion. At the same time, the soft palate elevates against the velopharynx, which seals off the nasal cavity from regurgitation and open the oropharynx. When the bolus reaches the back of the oral cavity, the base of the tongue drops to facilitate its entry into the oropharynx.

Pharyngeal stage: At that moment, the bolus crosses the area of the faucial pillars and the reflex part of swallowing starts and last approximately 1 second. Within that time frame, two critical objectives have to be achieved: (1) To carry the bolus through the pharynx and the upper esophageal sphincter (UES), to reach the esophagus. (2) To protect the airway via insulation of the larynx and the trachea from the pharynx, to prevent any food aspiration. At the beginning of this stage, the Pharynx elevates and widens to receive the bolus, and the base of the tongue retracts in a relatively typical posterior-superior movement. The tongue presses the bolus against the pharyngeal wall and the pharyngeal constrictors contract sequentially in a downward stripping wave (also called pharyngeal peristalsis) that follows the tail of the bolus. Concurrently, the vocal cords abduct

and the respiration ceases to close the airway. Also, the UES relaxes and the larynx elevates under the action of the suprahyoid muscles (which pulls the hyoid bone antero-superiorly) and the thyrohyoid muscle (which brings the thyroid cartilage closer to the hyoid bone). This particular movement of the larynx causes the posterior inversion of the epiglottis against the laryngeal inlet to definitively seal the airway. In addition, It pulls the UES open to allow the bolus to access the esophagus. Finally, this whole elevation mechanism produces a negative pressure below the bolus which, along with the pharyngeal stripping wave, safely guides the bolus to the esophagus.

Esophageal stage: The bolus is now in the esophagus. The larynx reverses back to its neutral position under the contraction of the infra-hyoid muscles and the UES contracts again. Simultaneously, the esophageal peristalsis begins to drive the bolus toward the stomach and the lower esophageal sphincter (LES) relaxes. When the bolus reaches the stomach, the LES contracts again and the swallowing process ends. It should be noted, however, that the neutral position of the larynx is achieved before the end of the swallowing process. First to resume breathing when possible and also because the esophageal peristalsis does not rely on the laryngeal conditions.

This simplified description of the swallowing stages hides the inherent timings and muscles strength variability of such a complex process. The physiological aspects, the nature of the bolus or the swallowing conditions may all act on those stages. Moreover, the beginning of the reflex swallowing may occur while the bolus is already largely entered in the pharynx and some description consider the elevation of the soft palate as part of the pharyngeal stage. Yet, whilst the chewing stage may be mostly random, the subsequent events are quite typical. But whether or not the added variability makes these stages robustly predictable remains an open question. In addition, since Doty et al. [37] in 1956, which established a solid basis and constitutes one of the most frequently cited study on pharyngeal swallowing, the precise description of some anatomical events, such as laryngeal elevation or tongue base reflex movements, are still in debate. In any case, the actual knowledge allows to extract some relevant information with regard to the feasibility of an implantable active artificial larynx. The propulsive movement of the tongue is largely described as a quite typical step and the subsequent reflex stages are thought to be controlled by a "*central pattern generator*" in the brainstem, guided by sensory inputs along the pharyngeal tract [35].

As a side note, it should be specified that the term peristalsis is primarily defined as a sequential and involuntary contraction-relaxation of circular smooth muscles that propagate down a tube. While the esophagus is a tube mostly composed of smooth muscles, the pharynx is, however, semi-circular with striated muscles. Even though we cannot voluntarily alter pharyngeal muscles contraction, striated muscles are commonly associated with voluntary movements. For these reasons, the term *pharyngeal peristalsis* tends to be abandoned in favor of *stripping wave*, *progressive compression* and even *squeezing wave*, which may be confused with the *squeezing movement* of the tongue during the propulsion stage. We chose to stick with the *stripping wave* term because of its fundamental utility to strip any residues off the pharynx.

3 Anatomical considerations.

There is an inherent complexity in the swallowing process which comes from the need to keep the airway and the digestive tract separated. The prime keeper of this separation is the larynx and it is operated through several anatomical regions in the neck that can functionally be classify into four groups: the suprahyoid muscles, (2) the pharyngeal muscles, (3) the tongue muscles, (4) The infrahyoid muscles. The larynx acts as a switching mechanism between the airway and the digestive tract in a precise and sequenced interaction with these regions. Therefore, The following will describe these regions and the role they have in the swallowing process, from the most relevant to the least relevant, with regard to their potential to provide useful information to study the feasibility of a robust detection strategy. The figure 3 gives an brief overview of the interaction of these regions.

3.1 Suprahyoid muscles

One way to classify muscles in the neck is relative to their position to the hyoid bone. Suprahyoid muscles are 4 muscles located above the hyoid bone and that attach to it. They are the mylohyoid, the geniohyoid, the digastric and the stylohyoid muscles. One particular feature of the digastric muscle is that it separates in tow bellies that run anteriorly and posteriorly from the hyoid bone. The Suprahyoid muscles each participate in various proportions in chewing, swallowing, phonation and are the main contributor to the spacial fixation of the hyoid bone, which does not articulate with any other bone.

3.1.1 Submental muscles

The submental muscles are the suprahyoid muscles that run anteriorly from the hyoid bone and attach to the mandible. They are the mylohyoid and the geniohyoid muscles, that constitute the floor of the mouth, and the anterior belly of the digastric muscle, which is the most superficial. Because of their accessibility, it has been well established that the submental area starts its activity in the early swallowing process, to stabilize the tongue during the propulsion stage [32, 35, 37, 39]. Consequently, these muscles have frequently been involved in various studies, either as a group with surface sensors or independently with invasive measurements.

Whether intramuscular or not, electromyography (EMG) is by far the dominant approach to study the submental area. On one hand, with intramuscular approach, the mylohyoid has first been acknowledged to lead the sequential pattern of swallowing in most species [35, 37]. But these muscles independently also exhibit a large variability inter and intra subjects, both in terms of duration and sequence of activation [40–42], and upon different bolus type [43–46]. More study is therefore required to better explore their activation pattern individually, but the submental area remains the primary group of muscle that consistently leads the propulsion stage and the subsequent swallowing reflex [38] (Figure 3). This is explained by their role in the propulsion

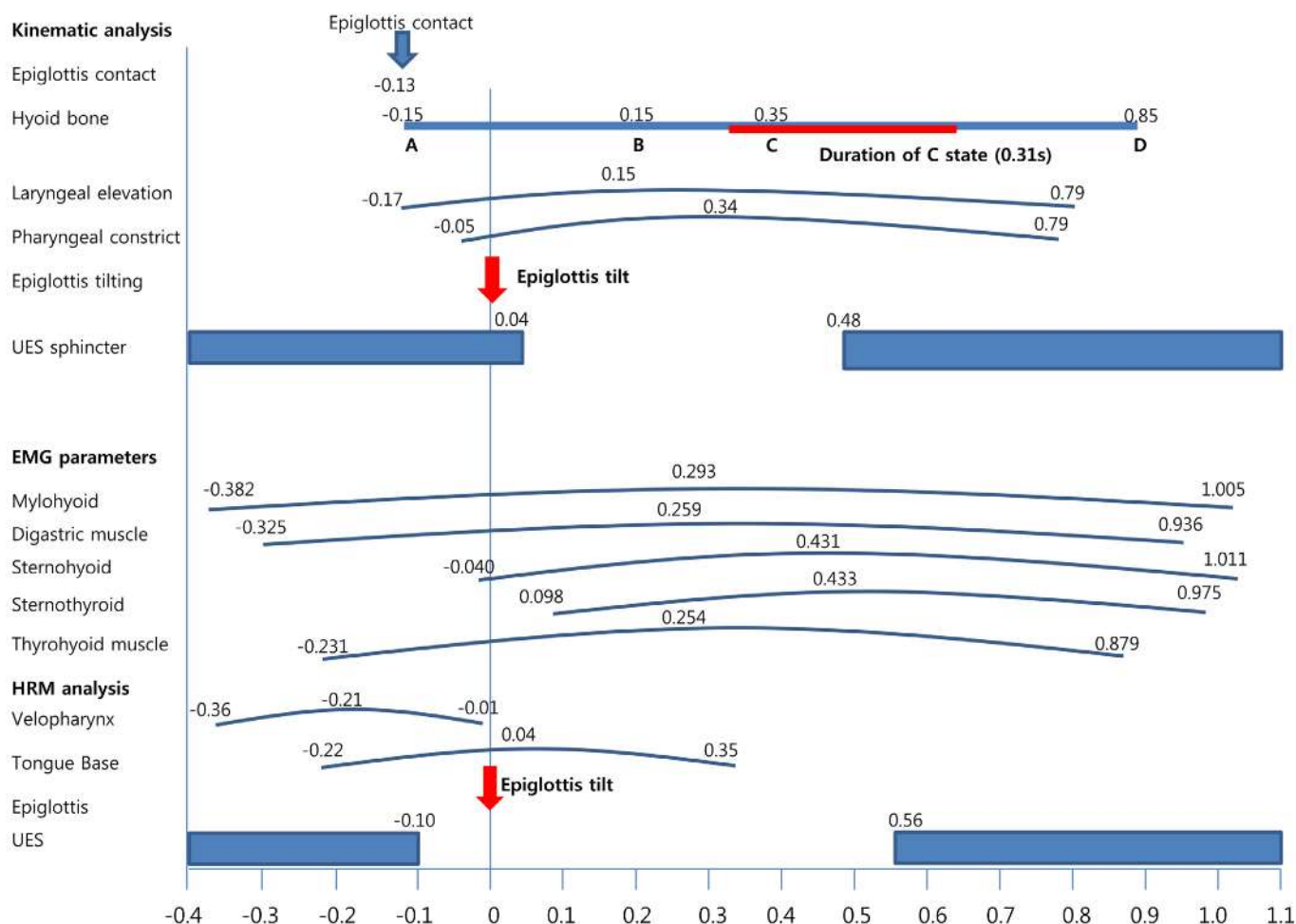


Fig. 3. Swallowing timings examination with HRPM, EMG and videofluoroscopy combination from Park et al. [38]. The timings are related to the epiglottis tilt (red arrows). The hyoid bone movements are reported: Point A is the initial position. Point B is the maximum superior position. Point C is the maximum anterior position. Point D is the maximum inferior position. The red line represents a 2mm area in which the hyoid bone pauses before it initiates its downward movement. More information on hyoid bone movements are shown on Figure 7.

stage that requires early support of the tongue, which also makes them significantly correlated with the pressure exerted in the oral cavity [47, 48]. In another hand, surface electrodes are the favored choice in most studies and records all the muscles as a group. It is usually used to compare the submental activity with other important anatomical events. Especially, the submental area fires early, but continues throughout most of the swallowing. It starts with low amplitude and gradually increases to reach its peak when the bolus has already entering the esophagus [49]. This is because the submental muscles are involved in laryngeal elevation, which in turn act on the opening of the UES. The later thus opens while the submental area has not fully acted on the laryngeal elevation yet. Also, the submental peak activity tends to be delayed with the increase in the volume of the bolus, as the UES has to be wider to accommodate to it [50]. In any case, apart from the timings, the submental area is recognized as a key muscle group to study swallowing tasks [51–53] and is largely representative of the underlying muscles. Indeed, the mylohyoid, the anterior digastric and the geniohyoid are the main contributors of the signal amplitude while the genioglossus and the platysma are negligible. Also, very little cross-talk seems to come from adjacent muscles [54, 55] and the geniohyoid and mylohyoid show the best potential to displace the hyoid bone anteriorly

and superiorly, based on their structural properties [56, 57]. But these findings need to be generalized to a broader scale as several neck muscles are known to strongly activate in various tasks, and may contaminate the submental surface EMG signals [58]. Additionally, the quality of the signals is largely influenced by the position of the electrodes and their distance to the muscles of interest, which directly correlates with subcutaneous fat. Also, these muscles are small, have overlapping fibers running in various directions and no recommendation is available to place the surface electrodes so that the signal is maximized. Yet, the submental area provides useful information and is often used in rehabilitation process [59–63] or to better explore the swallowing sequence [64–68].

3.1.2 Stylohyoid and posterior belly of the digastric muscles.

The stylohyoid muscle and the posterior belly of the digastric muscle are the only suprahyoid muscles that run posteriorly of the hyoid bone. They originate in the styloid process and the mastoid process respectively, and attach to the hyoid bone. They are often described concurrently as they are both innervated by

a branch of the facial nerve. But little has been done to directly study their activity with regards to various tasks and conditions. Their relatively deep-seated position behind the mandible only allows intramuscular EMG to record them independently, which has likely prevented extensive investigations. Also, common swallowing process descriptions report the elevation of the larynx to be mostly driven by the submental muscles and the thyrohyoid muscle (section 2). But the literature moves toward a more thorough definition based on growing evidences. New imaging techniques allow the kinematic analysis of specific muscles and sequences. The stylohyoid and the posterior digastric were shown to significantly activate during swallowing [69], and to start at the same time than the mylohyoid muscle [70], which is part of the submental area and is involved in the beginning of the propulsion stage of swallowing. Regarding their anatomy and orientation, it suggests their basic function as hyoid bone elevators, and the analysis of their structural properties reveals a significant potential to move it [56, 57].

Nevertheless, the relevance of those muscles in swallowing process has to be established with functional data from invasive measures and, in such cases, animal models is often informative. In term of timings, Doty et al. [37], in 1956 on various animals, described their *leading complex* of swallowing and included the stylohyoid, while the posterior belly of the digastric were either delayed or remained silent. But they repeatedly underlined the variability of their recorded signals, which led Thexton et al. [39] in 2007 to revisit their study with a single natural stimulation, and more recent recording techniques. They used eight decerebrate infant pigs to elicit pharyngeal swallowing and record EMG from 16 muscles. The stylohyoid was still considered as part of the *leading complex* but the posterior digastric muscle were not reported, as pigs do not have one. Few studies followed on animals and only included pigs. The previous results were first confirmed [71], and then, Thexton et al. [72] observed amplitude differences in the stylohyoid between suckling and swallowing in infant pigs, with larger burst during swallowing (Figure 4). Mayerl et al. [73] later confirmed the suck and swallow differences and compared 7 day-old and 21 day-old pig groups. Greater muscle length variation during swallowing were observed for the stylohyoid in both groups, and this was further apparent in the older group. It also showed isometric contraction during suckling, probably to stabilize the hyoid bone. With regards to the timings, the stylohyoid was consistently among the first muscles to activate. However, they emphasized regional heterogeneity in firing within the stylohyoid: "by systematically placing electrodes in ventral and dorsal locations, we found that only electrodes placed ventrally (close to the hyoid) registered muscle activity during sucking, with dorsally placed electrodes only showing activity during swallowing". This suggests functionally relevant pattern of motor unit firing.

Regarding human functional studies, few have been reported over the past century. The main difficulties are to localize the stylohyoid and posterior digastric muscles and to confirm the proper placement of the intramuscular electrodes. Early attempts to localize the posterior digastric were based on palpation, and these studies suggested that it activates only during jaw movements [74, 75]. The palpation based method was then further enhanced by Widmalm et al. [76] in 1988, who analyzed

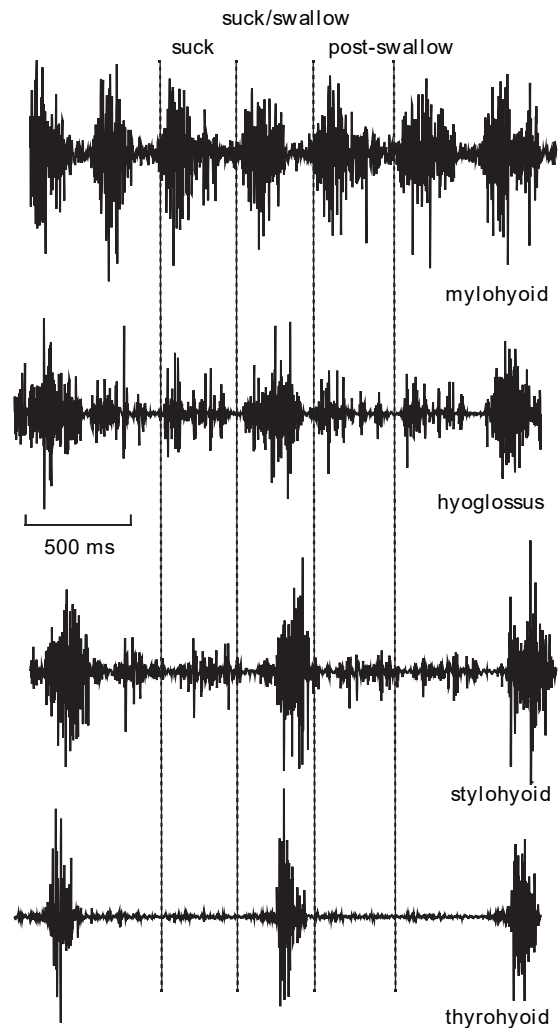


Fig. 4. Stylohyoid muscle activity from Thexton et al. [72] during suck and swallow cycles. It exhibits a net burst of amplitude during the swallowing events.

the neck anatomy from dissected cadavers and from frontally and transversely sectioned specimens. They inferred a new palpation technique and localized the best insertion point to be "approximately 1cm posterior to the tip of the mastoid process, directed upwards and inward at about 30-40° relative to the orbitomeatal plane.". Besides, needle insertion tests on cadavers, at the anterior border of the sternocleidomastoid muscle, were not mentioned to be successful, as they regularly encountered the intermediate tendon of the digastric muscle. Their subsequent measure on healthy subjects showed that the posterior digastric muscle was active during swallowing, with short bursts of high amplitude, and also during jaw opening. Finally, Kurt et al. [77] systematically assessed the position of the electrodes, via the electrical stimulation of the facial nerve. They confirmed the jaw opening and swallowing main activity of the stylohyoid (STH) and posterior digastric (PD) muscles, studied as a unique STH-PD complex. In addition, nerve electrical stimulation allowed them to characterize the compound muscle action potentials (CMAP) latency. They showed that, while the facial nerve also supplies facial muscles involved in mimicry, the stylohyoid and posterior digastric muscles are more akin to the functions of the submental muscles. Therefore, the authors stated that "electrophysiological identification factors may make easier to

work on STH–PD muscles during swallowing or in some other physiological and clinical problems."

These human functional data, along with anatomical evidences, new imaging methods and animal models, advocate for the usefulness of the information these muscles could provide in a swallowing detection strategy. But few recent findings must be kept in mind for further investigations. Palpation methods are subjective and no formalism is established for the stylohyoid and the posterior digastric muscles. In that regard, a systematic review of the reported palpation methods of the posterior digastric advises not to rely on those methods, as it may actually not be palpable [78]. Also, anatomical characteristics are usually largely variable and the stylohyoid and digastric muscles are no exceptions. While no morphometric data is reported for the stylohyoid, the posterior digastric showed great variability [79, 80]. This may explain why Widmalm et al. [76] could not insert the electrodes anteriorly to the sternocleidomastoid muscle without the risk to encounter the intermediate tendon, as it exhibits substantial length variability. In any case, Kurt et al. [77] reported successful work despite these limitations, which highlights the need to develop a reliable insertion method.

3.2 Pharyngeal muscles

The pharynx forms a continuous muscular passage that is highly active during swallowing and is usually divided into three parts: the nasopharynx (also called rhinopharynx), the oropharynx (also called the mesopharynx) and the hypopharynx (also called the laryngopharynx). A fourth anatomical region may be considered in appropriate circumstances, which is the velopharynx, at the level of the contact between the pharyngeal wall and the soft palate (also called the velum). The pharynx contains the longitudinal muscles (stylopharyngeus, palatopharyngeus and salpingopharyngeus) that run supero-inferiorly in the inner posterior wall of the pharynx, and the constrictor muscles (superior, middle and inferior) in a semi-circular shape, localized in the outer posterior wall of the pharynx [81]. It is bordered by the nasal tracts and the esophagus in its upper and lower limits respectively. The junction with the esophagus is made via the UES [82], which acts as a gate. The UES is almost constantly in a tonic state and only relaxes during swallowing, belching and vomiting. During these events, the laryngeal movements pulls the UES open, while the airway closes to prevent aspiration. The muscles that constitute the UES are the cricopharyngeus, the inferior pharyngeal constrictor and the cervical esophagus, but the main contributors to its tonic state is the cricopharyngeus muscle, which inserts in the cricoid cartilage. Because of that, the UES and the cricopharyngeus terms are often used as synonyms [83].

3.2.1 Pharyngeal constrictor muscles

The pharyngeal most external muscles are the superior, middle and inferior pharyngeal constrictors. They are the main contributors to the movements of the bolus during the reflex (pharyngeal) stage of swallowing. When it starts, the soft palate is elevated, the bolus is in the oropharynx, and a rapid

posterior-superior movement of tongue against the pharyngeal wall exerts a high pressure on the velopharynx, and forces the bolus downward. The superior pharyngeal constrictor comes along concurrently, which initiates the pharyngeal *stripping wave* that follows the tail of the bolus, to channel it toward the esophagus. This is done with the sequential contraction of the superior, middle and inferior constrictors that cause the region behind the bolus to decrease in size, and consequently the pressure to increase. Obviously, gravity adds to the effort of the constrictors in normal conditions, but it may also counteract in atypical ones. So, to assist the pharyngeal constrictor muscles, the laryngeal elevation acts on a more robust mechanism. Indeed, the larynx and the UES are linked by the cricoid cartilage. When the larynx elevates, the UES is relaxed and is rapidly wide open. This causes a substantial pressure differential between the tail and the head of the bolus that sucks it down the hole, to facilitate its passage through the UES.

This story only forms the basis of the pharyngeal stage of swallowing and the details are still largely studied. As a standard to analyse muscle activity, EMG has been used to better understand the frame of activity of the pharyngeal muscles. During breathing, they act as pharyngeal dilators to modulate its cross-sectional area that can vary under gravity, fat-loaded tissue mass, and negative air pressure due to inspiration [84]. Also, breathing disorder such as obstructive sleep apnea is a common affection and shows significant activity of the superior pharyngeal constrictor [85]. On the whole, the pharyngeal constrictors are shown to activate for various additional tasks such as speech and head turn, along with swallowing, which seems to consistently provide the greatest amplitude [86–88] but to show regional firing as well, depending on the activity [89]. Regarding timings, the superior pharyngeal constrictor activates a short time after the submental area, and continues during most of the swallowing [68, 90]. In addition, its activity may increase during unusual swallowing to keep up with normal bolus transition time [91].

Despite the valuable information provided by EMG approaches, recent studies lack on pharyngeal muscles electrical activity. Because of the requirement of swallowing assessment in a clinical routine, researchers primarily focused on a way to visualize a swallowing. In that regard, videofluoroscopy is considered the gold standard and requires X-ray exposure to record a radiographic movie. It allows to evaluate the structural displacements and timings of a swallowing with various bolus types [92, 93]. But the use of X-ray limits the number of trials, requires cumbersome equipment, and the video-based swallowing assessment is largely subjective [94]. Moreover, videofluoroscopy allows bolus localization, but a quantitative assessment of the pharyngeal muscle contraction is impossible. Because of this, high-resolution manometry (HRM) is extensively used as an alternative or adjunct choice [95, 96]. It consists in multiple pressure sensors densely spaced on a catheter, inserted via the nose, and that passes through the UES. First dedicated to esophageal assessment [97], it is now being developed for the pharynx and is specifically termed as high-resolution pharyngeal manometry (HRPM). Also, later improvements added impedance sensors so that the localization of the bolus is also possible, and is therefore termed at high-resolution impedance manometry (HRIM). Finally, a three-

dimensional approach is also being developed [98]. Several measurement methods and relevant metrics were recommended in the recent years [99–103], and it finally led to an international working group to establish a formalism on the use of HRPM and HRIM [104].

In normal conditions, pressure information provided by HRPM is the transcript of the forces required to channel the bolus to the esophagus [101]. The pressure is first established at the velopharynx by the elevation of the soft palate and the tongue rapidly adds to it, to force the bolus downward. This is closely temporally linked to the UES relaxation and is followed by the tongue base retraction against the pharyngeal wall. The stripping wave then continues down, and the end of the pharyngeal stage is visible with the UES back in its tonic state. This is usually mapped on a space-time plot, with the time in abscissa and sensors localization in ordinate (Figure 5). With this in mind, one may be tempted to minimize the primary role of the tongue in the bolus transportation, compared to the pharyngeal constrictors. But before the stripping wave, the tongue actually adds its own propulsion forces, instead of simply flowing the bolus in the pharynx [106]. This whole process of bolus transportation was later formerly described as a tow step mechanism [107]: (1) Most of the bolus entered the oropharynx. The tongue accelerates the bolus to force it into the pharynx. The UES relaxes and starts to open. (2) The bolus has fully entered the pharynx and is now driven by the stripping wave through the wide open UES. This mechanism is apparent in the space-time HRPM plot where the velopharyngeal and tongue base pressure are delayed. Indeed, the velopharyngeal pressure starts when the bolus is initiated into the pharynx but the tongue base retraction is postponed to follow the tail of the bolus. Otherwise, HRPM combined with videofluoroscopy allowed Walczak et al. [105] to highlight an effect of bolus elongation, where its head moves faster than its tail. The head traveled through the pharynx in 15ms while the tail may still not be fully entered in the oropharynx. Thus, no stripping wave was started yet. Beside, Park et al. [38] added the EMG as a third measurement to better assess the timing of the whole swallowing process. An average duration of 282ms was reported between the mylohyoid activation and UES relaxation, while the airway protection through tilting of the epiglottis occurred 100ms later. As for the velopharynx, it was again the first pressure to appear, around the same time of the mylohyoid activation (Figure 3). Regarding the known variations, elderly people were found to exhibit lower UES resting pressure and less UES relaxation [108, 109]. Also, various factor influence the recorded pressures, such as body position [110, 111], rehabilitation techniques [60, 112–114] and bolus properties [115–118]. But the pharyngeal stage has recently been found to be optimally attuned for a 10ml volume of liquid bolus. More specifically, Cock et al. [50] showed that the maximum bolus flow through the UES is aligned with the maximum submental activity for that particular volume (figure 6). In other word, as the submental muscles participate in laryngeal elevation and consequently in UES opening, the maximum submental activity coincide with maximum UES opening. Therefore, no particular adaptation of the pharyngeal stripping wave is required and the bolus is nicely guided into the esophagus. Conversely, with another volume, the stripping wave starts to flow the bolus through the UES before or after the maximum activity of the submental area. The UES is

therefore not fully opened yet or already in its closing stage, depending on the volume. The pharyngeal constrictors have then to compensate for the sub-optimally opened UES with an increase in pressure.

3.2.2 Longitudinal muscles and soft palate muscles

The longitudinal muscles are the palatopharyngeus, stylopharyngeus and salpingopharyngeus and they basically elevate the pharynx. The soft palate muscles are the tensor veli palatini, levator veli palatini, and the uvula and they act on soft palate superior-inferior movements. These muscle groups are frequently described together as they interact in the positioning of the pharynx and the soft palate. Indeed, while the stylopharyngeus and the salpingopharyngeus directly act on pharyngeal elevation, the palatopharyngeus requires the soft palate muscles to fire, to fully participate in the movement. This is because the palatopharyngeus originates in the soft palate region and runs downward to insert in the thyroid cartilage. Consequently, its activation with no firing of the soft palate muscles, would bring the soft palate down. During swallowing, they all activate to close the velopharyngeal isthmus and elevate the pharynx, which protects the nasal cavity from regurgitation and prepares the pharynx for the passage of the bolus [119–123].

Beside, the longitudinal muscles are thought to participate in swallowing, respiration and phonation [120]. Their attachments suggest their implication in the hyolaryngeal elevation, and the analysis of their structural properties by Pearson et al. [56] revealed a potential force comparable to that of the submental muscles. In that regard, The same team evaluated the longitudinal muscles activity during swallowing with muscle functional magnetic resonance imaging (mfMRI), which allows to assess the extent of muscle activation following the performance of a task. They confirmed their anatomical results as the longitudinal muscles were shown to activate in an effort comparable to that of some of the submental muscles [69]. Also, they further explored the longitudinal muscles implication in laryngeal elevation and suggest that they may significantly help the thyrohyoid muscle to get the hyoid bone and thyroid cartilage closer [124]. Besides, recent anatomical investigations suggest that the palatopharyngeus blends with the UES and therefore participates in its opening through pharyngeal elevation [125]. In any case, with regard to functional data, Van Daele et al. [90] analyzed the longitudinal muscles with EMG measurements and showed that they fire slightly before the superior pharyngeal constrictor, while older results suggest that the palatopharyngeus is primarily concerned with swallowing [126]. Finally, the palatopharyngeus was further studied in animal and was actually shown to activate early in pigs [39, 71] and with more variability in monkeys [89].

With regard to the soft palate, its basic role is to act as a valve that allows the passage through the nasal tract or the oral cavity. Its muscles have been shown to be active during swallowing, breathing and speech [88, 127–130]. The interplay between those muscles is still in debate, but it is generally agreed that the tensor veli palatini plays a significant part in soft palate tautening and eustachian tube opening, while the levator veli

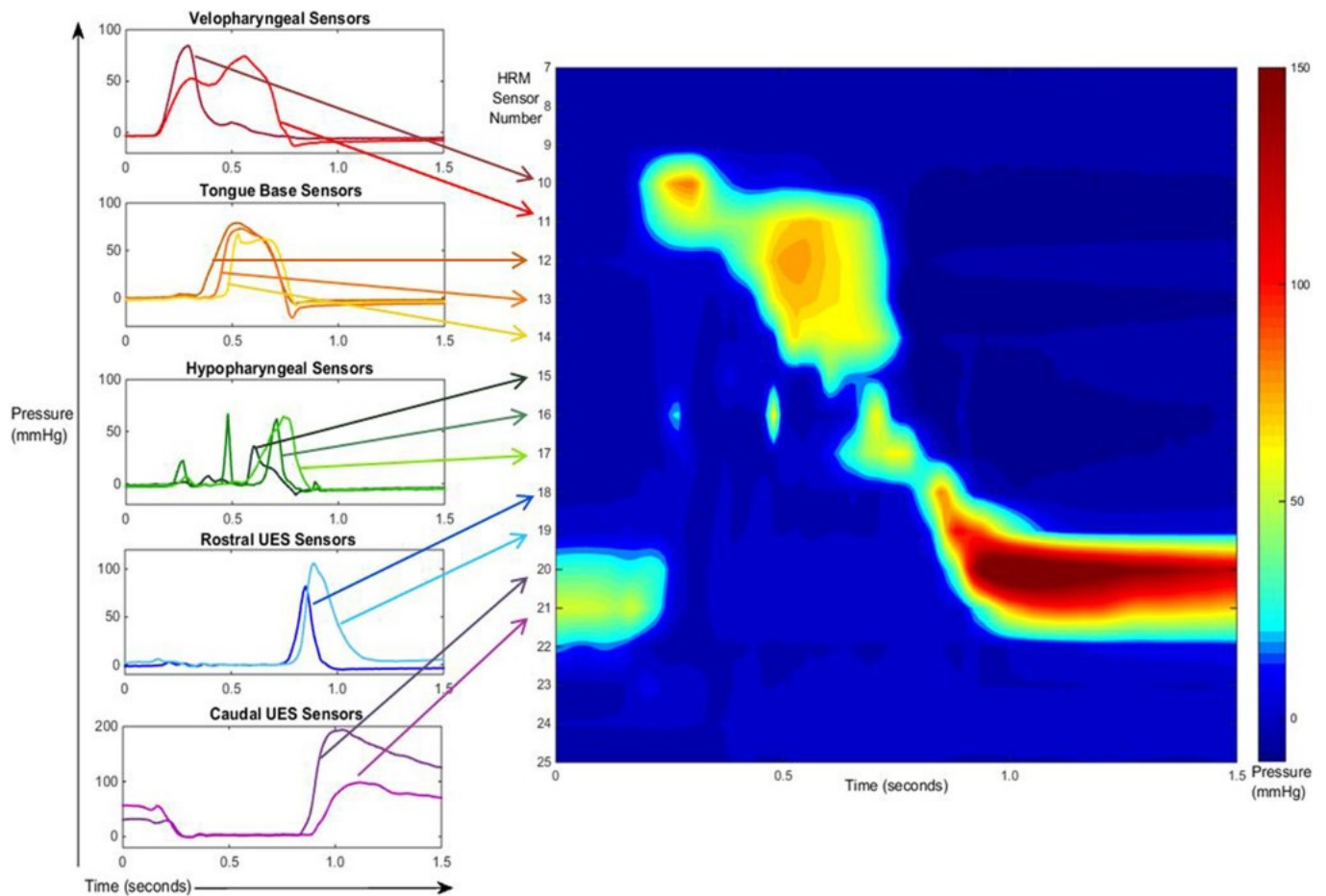


Fig. 5. Swallowing examination with HRPM from Walczak et al. [105] which shows the evolution in time of the pharyngeal forces, during bolus transportation. Ordinate represents the catheter's pressure sensors location in the neck, from the velopharynx to the UES. Abscissa contains time in seconds. The windows on the left exhibit the signals from each pressure sensor independently, while the space-time plot on the right maps the evolution through time. Blue and red are low and high pressure respectively, related to relaxed muscles and maximally contracted muscles.

palatini acts on soft palate elevation [122, 131, 132]. However, the level of activity of these muscles was not shown to be linked to the soft palate position [133] or velopharyngeal isthmus dimensions [134], although the soft palate seems to follow some patterning [135, 136]. Despite these uncertainties, the activity of the levator veli palatini, acquired with EMG, may help to differentiate swallowing from speech in terms of amplitude [137], and swallowing from breathing and speech in terms of frequency content [138]. Moreover, both levator veli palatini and tensor veli palatini may activate slightly before the submental area [40, 139]. But this requires extensive investigations as their activity may vary largely depending on the stimulus [140, 141].

3.3 Tongue muscles

The tongue is thought to fall into the category of muscular hydrostat, which is a biological structure composed of muscles oriented in different directions, with no skeletal support [142]. The connective tissue keeps the volume of the organ constant. Therefore, if a muscle contracts to shorten one part, another part has to widen. These structures are used to manipulate items or move about such as elephant trunks or octopus tentacles. For instance, the contraction of the circular muscles

of octopus tentacles decreases their diameter, which result in their elongation. In humans, it is used during speech and plays a major role in the mastication and the propulsion stages of swallowing. This is accomplished by two categories of muscles: the extrinsic and intrinsic tongue muscles. The extrinsic muscles originate from structures outside of the tongue and are the genioglossus, styloglossus, hyoglossus, palatoglossus, whereas the intrinsic muscles are entirely located within the tongue and are the superior longitudinal, inferior longitudinal, transversal and vertical. Most often, the tongue is also divided into two or more anatomical regions depending on the needs. Basically, the posterior third part is called the tongue base and constitute its pharyngeal part, while the anterior two third are the oral part [143].

The structure of the human tongue is extremely complex. The intrinsic muscles blend together in various directions and the extrinsic muscles add to it as they insert in the intrinsic tongue [144, 145]. Consequently, EMG approach may not be reliable depending on the targeted muscle. In addition, the movements of the tongue are only measurable to a certain extent because of the gag reflex that prevents the sensor placement on the tongue base. This led to the use of imaging methods, such as real-time magnetic resonance imaging (MRI), ultrasonography, videofluoroscopy and articulography, to determine the global

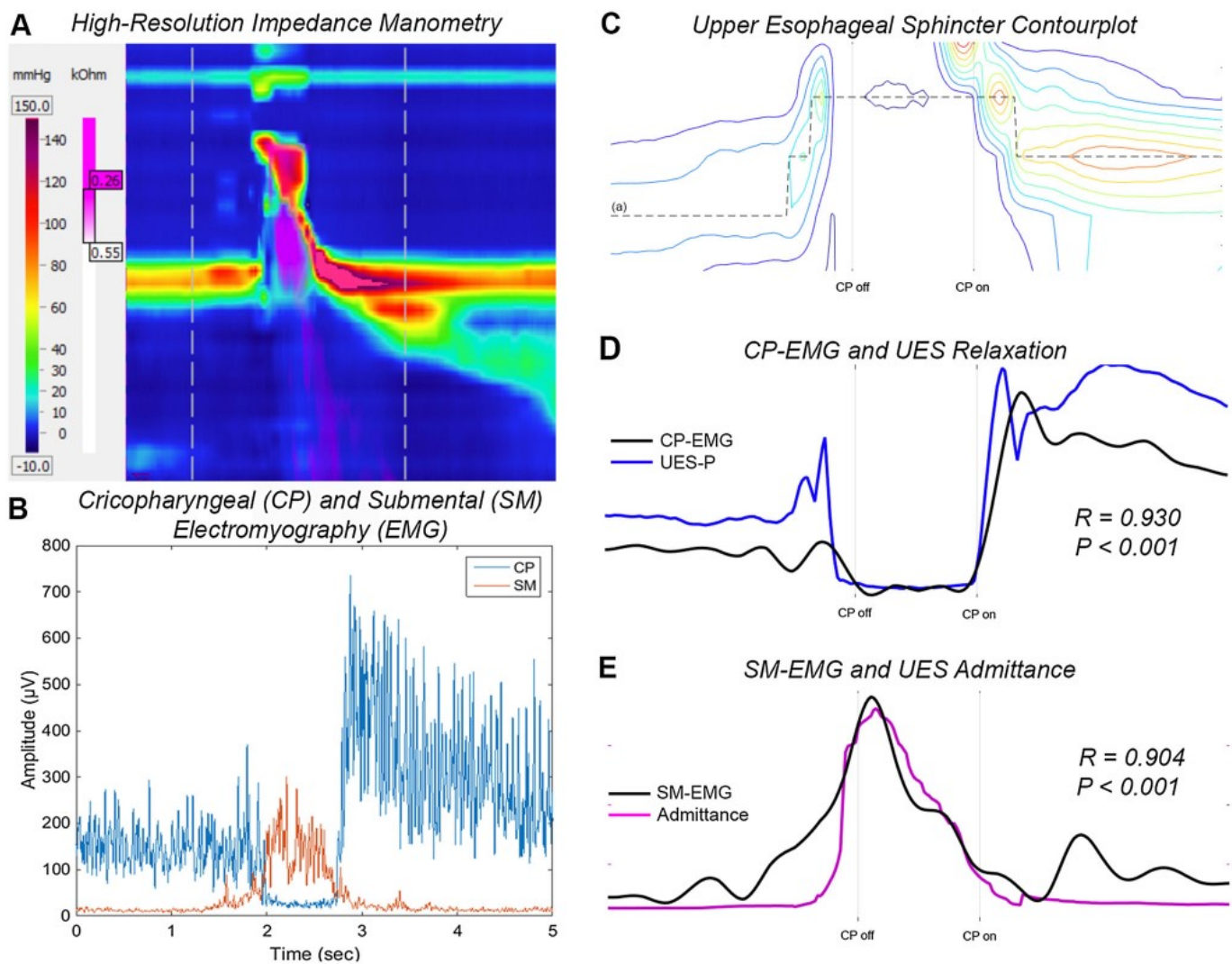


Fig. 6. UES activity examination with HRIM and EMG from Cock et al. [50]. **A)** HRIM space-time plot of a healthy swallowing of 10ml liquid. **B)** Submental surface EMG in comparison to cricopharyngeus intramuscular EMG. **C)** UES contour plot. The dotted line shows the UES vertical movement during hyolaryngeal elevation **D)** Cricopharyngeus intramuscular EMG in correlation to UES pressure. **E)** Submental surface EMG in correlation to admittance (inverse of impedance). Maximum admittance corresponds to maximum UES opening and occurs at submental peak activity.

dynamics and structure contours of the tongue [92, 93, 146, 147]. But these methods do not give access to the muscles activity. Their complex interplay makes hardly feasible to infer their activity from the external geometry of the tongue. Thus, researchers sought for an alternative method to infer the recruited muscles. In particular, tagged-MRI magnetizes the living tissues in a grid-like pattern to generate the main strain directions by measuring local grid deformation. This allows to further determine the intramural muscle dynamics, which showed that the intrinsic and extrinsic muscles work in synergy with no primary contributors [148, 149]. In brief, during swallowing, the bolus is first held in a groove under the action of the genioglossus and hyoglossus muscles that depress the tongue locally, while the transverse and vertical muscle strengthen the surroundings of the bolus. The posterior displacement of their active fibers then squeezes the bolus backward, drops the tongue base and moves the bolus into the pharynx. Finally, the propulsion movement is most likely supported by the styloglossus and hyoglossus that retract the tongue, while the posterior fibers of the transverse and vertical

muscles enlarge the tongue base, due to its hydrostat nature. Variations of the tagged-MRI approach were then developed [150–152], but one may keep in mind, however, that the precise interpretation of the tongue muscles activity, based on strain data, requires good knowledge of tongue physiology. The complex interactions between its muscles actually allows limited correlation with the measured strain [153], and recent research in tongue modeling that combined strain data and muscle fiber types, do not fully support previous results [154]. In addition, the mechanism described here tends to be widely accepted, but a recent and detailed examination of tongue muscles contraction may advocate for a more complicated process [155].

In any case, extrinsic muscles of the tongue still contract during the swallowing process of many species, including human [37, 39, 71, 156, 157], and their study through EMG is more appropriate than intrinsic muscles. However, the activity of the submental area recorded with surface electrode may be tempting to access the genioglossus muscle, but it actually correlated poorly with the signal [55]. Intramuscular electrodes are thus

required for a detailed examination, and the genioglossus has got most of the focus compared to other extrinsic muscles, which is likely due to its relatively accessible position. Besides, because of its implication in tongue movements, it activates for various tasks [91, 158–161] and is among the first muscles during swallowing [41, 42, 90]. The genioglossus activity has also been largely studied during breathing, where it acts as one of the main airway dilator, exhibits proportional activation to negative pressure and shows various patterning related to sleep and wakefulness. In terms of motor unit, it is thought to be constituted of at least six discharge patterns for inspiration, expiration and both, and with or without frequency modulation based on respiratory factors [162]. This Heterogeneity is confirmed with various tasks, were swallowing and inspiration with mouth or nose closed showed maximal activity [158], and with a common functional division into its anterior and posterior part [40, 163, 164]. In any case, during swallowing, the genioglossus muscle has been shown to be relatively characteristic [159, 160, 165] and its posterior part exerts most of the tongue-palate pressure [47]. But no precise comparison has been done between tasks, and there is still a complex synergy between the tongue muscles that requires extensive researches. Even though the relatively typical propulsion stage of swallowing may exert a reproducible contraction pattern, it may also be influenced by various external perturbations [166]. Finally, little is known about the other extrinsic muscles and functional data are only available from the palatoglossus, that shows variations depending on bolus volume [128] and also activates during breathing [129].

3.4 infra-hyoid muscles

The infrahyoid muscles, also called the strap muscles because of their appearance, are located in the anterior neck and run downward from the hyoid bone and the thyroid cartilage. They are the sternohyoid, sternothyroid, omohyoid, and thyrohyoid muscles and their collective contraction basically draws the hyoid bone downward. Independent contraction, however, occurs in various situations. During sound production, the hyoid bone is stabilized by the suprahyoid muscles and the sound is modulated through the sternothyroid and thyrohyoid muscles contraction, which act on the thyroid cartilage position. During swallowing, the thyrohyoid muscle is known to pull the larynx closer to the hyoid bone, which participate in hyolaryngeal complex elevation and UES opening. The sternohyoid, sternothyroid and omohyoid muscles then act on hyolaryngeal complex depression in the final part of swallowing.

The first precise investigation of the infrahyoid muscles during swallowing, came from Doty et al. [37] in 1956, who used EMG measurement on various animals. They showed that the thyrohyoid muscle activates shortly after the *leading complex*. However, the omohyoid muscle was not included and the other infrahyoid muscles were not considered to be activated. But this was later challenged in 2007 by Thexton et al. [39] with the use of pig models and more recent EMG recording equipment. They found that all the infrahyoid muscles activate during swallowing. The omohyoid muscle was the first to activate, closely after the *leading complex*, and rapidly followed by the thyrohyoid muscle.

However, the sternohyoid and sternothyroid muscles fired at the end of the swallowing, almost at the same time. Subsequent studies on pigs confirms and extends these findings [71–73]. Great variability was actually found in the sternohyoid and sternothyroid muscles, which causes a lack of reproducibility, as opposed to the thyrohyoid muscle that showed limited but sharp and high bursts (figure 4). Also, an early and small activity of the sternohyoid and sternothyroid muscles were frequently observed before the rapid increase related to the end of the swallowing. These recordings were hypothesized to be a mixed of various muscle fiber contraction related to concurrent activities such as sucking, licking, vocalization, cervical flexion or respiration, to adapt the posture of the hyoid bone. Finally, the omohyoid and thyrohyoid muscles were not shown to activate during sucking.

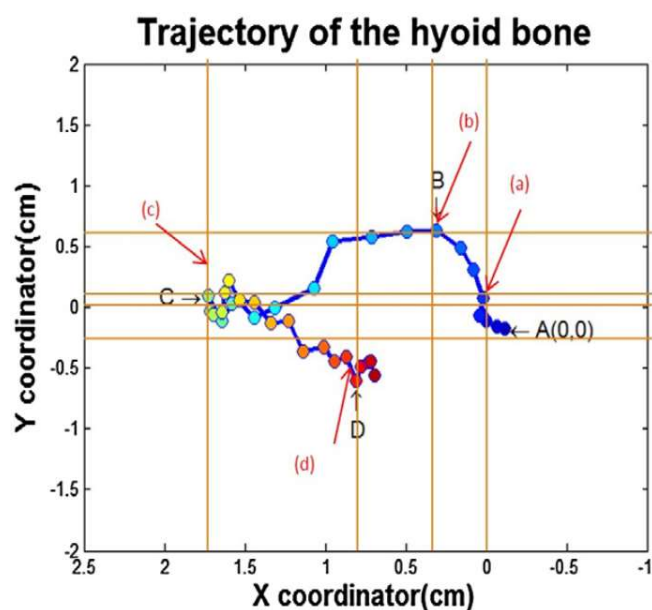


Fig. 7. Motion of the hyoid bone during swallowing from Park et al. [38]. Following points correspond to the position of the hyoid bone: A is the initial position. B is the maximal superior position. C is the maximum anterior position. D is the maximum inferior position. This anti-clockwise and circular-shaped movement is governed by a sequential activation of the suprahyoid and infrahyoid muscles. The suprahyoid muscles first contract to draw the hyoid bone upward and anteriorly from A to B. The infrahyoid muscles then fire, which reduces the upward movement and help the suprahyoid muscles in the anterior movements from B to C. Finally, the swallowing ends, the suprahyoid muscles activity decreases and the hyoid bone is drawn inferiorly and posteriorly from C to D via the infrahyoid muscles. This whole process is thought to prolong the UES opening. Figure 3 shows the related muscle activation.

With regard to human data, very few provides functional information through intramuscular EMG. Early results showed the activation of the sternohyoid muscle during chewing to stabilize the hyoid bone, and the authors reported little activity during swallowing [167]. This is, however, only recently that several studies attempted to precisely investigate the infrahyoid muscles, probably following the impulse of animal findings. This first allowed to confirm the late activation of the sternohyoid muscle, with a low amplitude and at the moment that the submental muscles start to decay. Which is in keeping with the idea that the infrahyoid muscles assist the hyoid bone to get back to its resting position [43, 44]. But one of the broadest

functional data available, that includes most of the infrahyoid muscles (except the omohyoid) and in comparison with the main anatomical events, was recently conducted by Park et al. [38]. First, they showed the great importance of some of the infrahyoid muscles in the motion of the hyoid bone, which adopts an anticlockwise and circular-shaped pattern (figure 7). More specifically, the sternohyoid and sternothyroid muscles activation is delayed, to assist the suprahyoid muscles in the prolonged duration of the hyoid bone anterior movement, which in turn increase the UES opening duration. Otherwise, the thyrohyoid muscle was substantially found to activate before the UES relaxation and the subsequent tilt of the epiglottis, and to last long after the UES has returned to its tonic state (Figure 3). Finally, apart from intramuscular EMG, various new imaging methods allow the precise kinematic analysis of the anatomical structures, to refine the actual understanding. All these studies acknowledge the early activation of the thyrohyoid muscle, but actually tend to mitigate its importance. Indeed, it is shown to activate shortly after the mylohyoid muscle, in line with the geniohyoid [70], but seems to be helped by the longitudinal muscles in the hyolaryngeal approximation [124] and to activate relatively poorly [69]. However, imaging method often requires to lay in a non-upright positions, which may account for the reported variability.

4 Total laryngectomy

The safe passage of the bolus, all the way down the aerodigestive tract, requires the precise coordination of muscles guided by sensory inputs. The removal of the larynx obviously disrupts this mechanism and most often causes dysphagia, which is considered a common but under reported problem after total laryngectomy. Its origins are diverse and are usually assessed with regular methods such as videofluoroscopy or manometry. Indeed, the fundamental function of the larynx to act as a switch between the esophagus and the trachea is lost, the remaining anatomy is impaired and adjuvant therapies, based on irradiation, causes muscle fibrosis and subsequent stricture. In addition, post-operative complications are frequently observed. The voice prosthesis may leak, a fistula may create between the esophagus and the trachea, which also causes leakage, or a pseudoepiglottis may develop because of a bad scarring. In any case, even though adjuvant therapies tend to worsen the long term scenario, the swallowing actually improves over time [168–172].

Early investigation of these adverse effects showed an increase in the pharyngeal resistance, that can have several origins. The surgery removes important tissues and the lack of pharyngeal mucosa reduces the lumen of the pharynx during its surgical closure. In addition, the loss of the larynx suppresses its anterior and superior movement that normally widens the hypopharynx and open the UES. Also, the tissues tend to collapse as they are not held in place anymore. In terms of contractility, several muscle insertion points have been removed from the larynx, the UES is dilated by performing a myotomy, and the sensory inputs from the larynx are lost. Consequently, the sequential activation of the middle and inferior pharyngeal constrictors is disrupted and weak (as they inserted in the larynx), and the UES tonic state falls. These effects are detrimental and affect the quality of

the swallowing. The transit time increases and the patients often require several swallowing to clear the pharynx. Also, they tend to compensate with an increase of the pressure force generated by the tongue, which highlights its importance in bolus transport [106, 173–176].

Maclean et al. [177] later confirmed the insufficient pharyngeal propulsive forces, but also showed that there is a resistance to bolus flow across the UES, and that these findings may be influenced by the surgical techniques. But this is the advent of high resolution manometry (section 3.2.1) that allowed a more thorough examination of swallowing. This relatively new method (and subsequent variations) not only gives access to the precise pressure events all the way down the aerodigestive tract, but researchers also developed relevant metrics to assess a swallowing. It can thus be applied to analyse total laryngectomy consequences, and the effects of rehabilitation methods. With regard to the later point, UES dilation therapy was shown to improve the bolus flow, despite the reduced hypopharyngeal propulsion forces [178]. As for the effects of the surgery, Lippert et al. [179] showed that the mesopharynx last longer with weaker contraction, the UES can exhibit low resting pressure but positive pressure during opening, and a "common cavity pressure" may form, likely caused by the disrupted pharyngeal constrictors sequence (figure 8). Also, the swallowing mechanism is adaptive in nature. So, even though the velopharynx is not altered by the surgery, it compensates for the prolonged transit time with a slower increases in pressure, same pressure peak and longer decrease in pressure, than the control group. Overall, the anatomic regions situated inferior to the velopharynx appear to have inadequate behaviors. As a result, this is relatively common to observe reduced pharyngeal bolus clearance with sometime significant residues [180].

Apart from videofluoroscopy and manometry, few studies investigated total laryngectomy through *cervical auscultation* (section 5.2). This method has grown recently because of its ability to partly characterize a swallowing via the sound it produces. A healthy swallowing has been shown to be composed of three main components of sound, where each one of them is associated with an anatomical event and allows to coarsely locate the bolus. The presence of these components is quite variable and only the second one, which represent the passage of the bolus through the UES, occurs in 100% of the swallowing. Data from total laryngectomees exhibit shorter duration, but higher amplitude and suggest some differences between the various profiles of patient, such as pre and post radiation therapy or esophageal and tracheoesophageal speakers [181]. Morinière et al. [182] later confirmed the decreased duration of the signal, but did not report on amplitude. However, they showed that the second sound component were still occurring in 100% of the swallowing. Also, the last component was absent, as it is normally associated with laryngeal opening at the end of the swallowing, which partly explains the shorter duration of the signal. In some rare cases, a new and more quiet third component was observed anyway. It was linked to the base of the tongue that quickly separates from the posterior pharyngeal wall at the end of the swallowing. Finally, the presence of the first component were even more variable than in healthy swallowing.

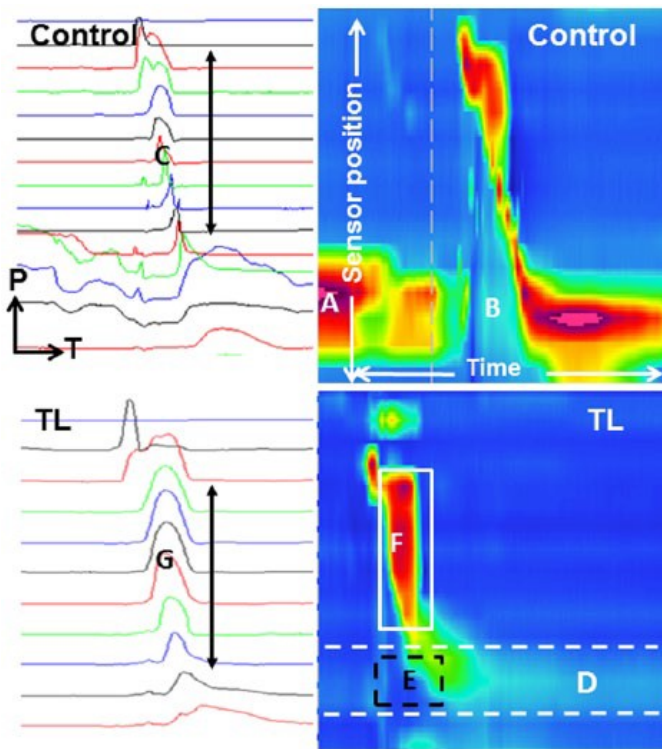


Fig. 8. An example of a HRPM acquisition from Lippert et al. [179]. Plots on the left are the pressures from each sensors where 1 tracing is from 1 sensor. The more caudal is the sensor, the more at the bottom the tracing is. Pressure (P) is on the y-axis, time (T) is on the x-axis. Plots on the right are the space-time representation of the tracings from the left. The sensors position is on the y-axis, time is on the x-axis, and the pressure is represented by the color. The upper plots are from an healthy control subject where A and B are the normal UES resting and opening pressure respectively. The lower plots are from a total laryngectomy (TL) patient, where D is the low resting UES pressure, E the positive UES opening pressure and F, a "common cavity pressure", likely caused by the disrupted pharyngeal constrictors sequence. Each image represents 5 seconds of data collection.

5 Current detection methods

The many muscles involved in swallowing and their complex synergy, along with various anatomical events, make the swallowing process difficult to assess and understand. Also, no unique instrument exists to reveal its subtleties from start to finish and several methods may be used in combination, to better analyse its physiology. But only few can be used on a daily basis or even be implanted. Indeed, imaging methods provide a clear view of the bolus or the anatomical movements, but usually requires cumbersome equipment, lack 3D information or require X-ray exposition. Articulography also helps, but no easily applied method is possible and the tongue base measurement is not feasible because of the gag reflex [183]. The following thus described several approaches, solely applied or in combination, that may prove to be relevant for a robust swallowing detection. However, the field of *food intake monitoring* has not been included as it inherently seeks after the development of non-implementable devices, with no particular focus on swallowing events, and mainly uses already existing modalities described hereafter. But if anyone is willing to dive into this new and growing field to explore various paradigms, such as chewing

detection or wearable sensors, the following reviews are a good start [184–187].

5.1 Electromyography

When it comes to functional data, electromyography (EMG) is by far the most used modality and comes with a large amount of studies in various situations. EMG signals arise from the electrical manifestation of muscle contraction, where a motor unit represents the smallest functional unit. Each motor unit is composed of muscle fibers supplied with ionic current through a dedicated nerve. The contraction of a motor unit is brief and can vary in frequency. Consequently, the force exerted by a muscle depends on the number of motor unit recruited and the frequency recruitment of each one of them. EMG measurement thus records every motor unit activation situated within a volume conductor, where the center is the electrodes. Also, the recorded amplitude rapidly decays with the distance and the radius of that volume can largely vary from one fiber alone to the whole muscle and even more. This depends on the electrode configuration, types and recording area. In any case, the resultant signal is the summation of the seemingly random firing of the whole bunch of motor unit involved in that radius. Which means that the content of an EMG signal is inherently random. But it still provides some useful features, such as the activation time and duration, the frequency content, and the amplitude, that is proportional to the effort. These particularities led to a specific set of signal processing techniques that are largely used in the field. Finally, EMG recording can be routinely applied with surface electrode, but it cannot reach deep muscles, needs careful preparation of the skin to reduce the electrode-skin impedance, and the signal can be easily contaminated with adjacent muscles (cross-talk). Otherwise, intramuscular recording surpasses those limits, but requires the insertion of electrodes directly into the muscles, which has to be done by a healthcare professional [188–191].

Several studies have attempted to perform an automatic swallowing detection based on EMG, but only surface electrodes have been used, and very few used that modality only. Constantinescu et al. [192] had the long term goal to perform swallowing detection on a daily basis. Through submental surface EMG recording, they trained an algorithm with various tasks and aimed at both healthy and head and neck cancer (HNC) survivors detection. The results were remarkably high, especially for HNC patients, but the later showed more variability with surprising results. This highlight the variety of impaired swallowing and suggest that a more individualized detection scheme may potentially be required. Otherwise, no other study precisely aimed at a similar goal, but the submental EMG may still be useful in fields where the biofeedback is at stake. In that regard, Crary et al. [193] studied to which extent the human subjective evaluation is relevant in the detection of swallowing, and compared trained judges and normal judges. The former performs better on average, with great results and high reliability. Besides, various studies used surface EMG on different location, or in combination with other modalities. One approach consisted in the measurement of several key locations on the neck and face to maximize the input information

[194], and the same team also proposed advanced methods to precisely establish the beginning of a muscle burst [195, 196]. Other works aimed at swallowing frequency count [197], tongue movements detection [198, 199] and even at the comparison of detection algorithms [192, 200]. But one notable work, with the best results yet, was achieved with the use of bio-impedance to detect the laryngeal movements. When the larynx goes from a resting state to an elevated state, the air evacuates and the tissues come into contact, which drastically drops the impedance. Obviously, this cannot be strictly applied to a post laryngectomy patient, but it is still enlightening. Also, none of the mentioned study actually sought for an early detection of swallowing.

5.2 Cervical auscultation

For long, swallowing were assessed by physicists with the use of a stethoscope to spot irregularities from the sound it produces. On the basis of clinical experience, they argued that the sound of a normal swallowing is different from the sound of a dysphagic swallowing. Termed as *cervical auscultation*, this approach is largely subjective and is only used as an adjunct method. Instead, videofluoroscopy is preferred as a clinical standard, but it requires cumbersome equipment and the patient has to be exposed to X-ray radiations, which limits the number of evaluations. These disadvantages conducted the researchers to think of cervical auscultation as a substitution. Indeed, early attempts to systematically study the sound showed a reproducible pattern, differences among dysphagic and non dysphagic patients, and changes related to anatomical events [201–203]. Afterward, the use of an accelerometer or a microphone became standards to avoid the inherent limitation of the stethoscope frequency content [204] and extensive researches have been done to better understand the signal [205].

Few studies have investigated the optimal sensor type and placement. Takahashi et al. [206] were the first to carefully compare different locations on the neck with both sensor types. They prescribed for the use of an accelerometer placed over the lateral border of the trachea, immediately inferior to the cricoid cartilage. But a few nearby sites exhibit comparable performances and were later compared [207]. Basically, the authors agreed on the optimal sensor placement, but emphasize the possibility of added noise from the sternocleidomastoid muscle, if the sensor is placed too far laterally. The cricoid cartilage was also presented as a potential resonator of the sound, and the placement at its center or just below were considered as a good choice. However, they did not agree on the adequate sensor to use and no precise guideline could be drawn. Actually, both accelerometer and microphone pick the same physiological phenomena in a different manner and dual-axis accelerometers were shown the provided additional information [208]. This led to their formal comparison and to the conclusion that those two transduction modalities are complementary [209]. Finally, the optimal sensor placement may still be in debate. Even though the previously mentioned sites are now largely adopted, other sites may prove to be relevant [210].

With regard to the origin of the sound, its beginning was shown to occur during laryngeal ascension, after the swallowing apnea,

and to continue throughout the swallowing with a peak activity around the full opening of the UES [211–213]. Besides, the analogy with the cardiac sound further comforted the idea that the swallowing sound is generated by anatomical events, that act as pump and valve systems in a sequencing manner [214]. In that regard, Perlman et al. [215] gave a thorough examination of those events associated with bolus head and tail location. They showed that the opening of the UES mostly occurs with the presence of the bolus head, before the acoustic peak. Besides, the swallowing sound also shows great variability, but still exhibit a repetitive pattern with three main acoustic components [216, 217]. The first component was found to occur during the laryngeal ascension, while the bolus is located along the pharynx. The second component occurred during the passage of the bolus through the UES. And the third component was found when the hyolaryngeal complex comes back to its resting state. Also, the second component exhibits the longest duration and highest amplitude, and was the only one to occur in 100% of the swallowing. Overall, the hyolaryngeal movements seem to be the primary source of sound, with the possibility to coarsely locate the bolus [218–220].

But external measurements are still often limited by the reduced amount of information they can get. It therefore comes naturally to combine the various modalities at hand to take advantage of their complementary content. Both accelerometers and microphones were thus used with that intent, and the new field of *High-Resolution Cervical Auscultation (HRCA)* rapidly substituted to the basic approach, in the recent few years. This is explained by the needs of bedside and routinely applied assessment of swallowing, which led to multiple approaches to automatically detect a swallowing [205, 221]. But no formal correlates between a normal swallowing and the swallowing sound have been established, and the actual assessment methods still rely on experts subjectivity. Therefore, classifiers are largely used, mostly on HRCA signals, with no clear guidelines, but show promising results. Especially, recent advances allowed improvement in the detection of precise anatomical events [222–225], in the screening of abnormal swallowing [226–230], and to establish reference temporal values from healthy adults [231].

5.3 Mechanomyography

Few modalities exist to study muscle activity. Whereas EMG is the standard, the mechanomyography is a growing novel technique that measures the vibrations associated with muscle contraction. The main component of the signal comes from the global deformation of the muscles while its resonance frequency and the muscle fibers contractions add to it [232–234]. Specific transducers are used (mainly accelerometer and microphone) and have the potential to be robust to variations in sensor placement, perspiration, and food spillage. Mechanomyography is presented as the mechanical counterpart of EMG and similarly, careful consideration of some aspects, such as sensor weight and type [235, 236], movement artifacts [237, 238] and cross-talk [239], are of key importance for good signal quality. This makes it complex to use it in a dynamic environment and the settling of a clear formalism is still required [240–242].

Few studies have nevertheless been carried out to analyse the swallowing with mechanomyography. The main contributions analyzed the submental area and the early results showed that the variability of the signals seems to agree with the EMG approach [243]. However, The same team later tried to include this modality in a larger swallowing detection strategy that combined several sensors, and showed that submental mechanomyography resulted in the least improvement in performance [244]. But the direct comparison between submental EMG and mechanomyography has only recently been done by Constantinescu et al. [245]. They recruited healthy subjects and cancer survivors and actually found mixed results in terms of signal-to-noise ratio comparison, but much better test-retest reliability in favor of EMG. This goes against the previous findings on large muscles, but the authors argued that the submental muscles may be too small to generalize. Finally, the feasibility of a swallowing detection with regards to the constraints that are inherent to an implantable active artificial larynx is now under investigation. Mialland et al. [246] measured the interval time between the submental activity and the moment that the bolus passes through the UES. The submental area was recorded with an accelerometer and the bolus was localized via the swallowing sound registered with a microphone (section 5.2). They were able to record a specific mechanomyographic pattern, relative to the propulsion stage of swallowing, and found a significant available time of $324ms$ on average, for a detection strategy.

6 Toward a robust detection

The structure of the aerodigestive tract is of particular complexity. It enables the same set of muscles, cartilages and tissues to act in synergy for three separate activities. Its great versatility allows speech, breathing and swallowing to occur interdependently, in a safe and continuous manner. Especially, swallowing requires breathing to stop, the airway to be protected from food aspiration, and the digestive tract to open. These events occur concurrently, while the bolus is channeled from the oral cavity to the stomach (section 2). Also, the process adapts in accordance to the characteristics of the bolus and its channeling requires the successive contraction of several muscles in about a second. This sequencing can functionally be divided into four anatomical regions (section 3): (1) the suprahyoid muscles, (2) the pharyngeal muscles, (3) the tongue muscles, (4) The infrahyoid muscles. In normal conditions, there is a close interaction between these groups and the larynx, but the total laryngectomy disrupts this mechanism. Indeed, several muscle insertion points are removed, the tissues are damaged and the larynx cannot operate its role in the opening of the UES anymore. In consequence, dysphagia is often observed after total laryngectomy (section 4).

Therefore, the feasibility of a robust swallowing detection requires a thorough consideration of the post-surgery anatomy and the inherent complexity of the swallowing process. Moreover, robustness is usually defined as the ability of a detection algorithm to perform well when it runs into new (unusual) data and anomalies. However, the inherent complexity of an implantable active artificial larynx represent a particular

case. We therefore expand that definition to four identified criteria required to achieve an *effective* and *safe* detection of swallowing: (1) Swallowing detection must be performed early enough so that any additional time for an airway closure mechanism does not exceed a critical time point. (2) No false negative detection should be allowed to provide a secure detection and airway closure. (3) Any measure has to be considered with regard to the anatomy post total laryngectomy surgery and must not further impair the head and neck area to ensure the remaining swallowing mechanism functioning. (4) The detection system should seek as little power consumption as possible to ensure long-term implantation. Therefore, the following will take a closer look at each of these aspects independently, with regard to the actual knowledge described so far.

6.1 Early detection

The requirement of an early detection stems from the fact that the airway must be protected at the moment the bolus passes next to it. Therefore, it is important that the measured anatomical events occur around the beginning of a swallowing. Moreover, there is an irreducible time that is necessary to first acquire, analyse and classify the signals, and then to activate any mechanisms that closes the airway. But these elements depend on several factors, such as the design of the detection algorithm or the quality of the signals, and cannot be known in advance. Also, the precise moment where the airway must be absolutely closed to forbid any aspiration is unclear, and may depend on the type of bolus. Liquid bolus, for instance, is likely to scatter along the pharynx and, even though swallowing reflex initiation occurs most of the time when the bolus enters the oropharynx, it is not uncommon to witness its arrival in the pharynx, and even at the level of the UES, while the swallowing reflex is still not initiated [167, 215, 247–249]. In normal swallowing, this usually does not cause aspiration and is explained by the suitable shape of the larynx, where the bolus is guided around the laryngeal inlet by the valleculae, the epiglottis and the piriform sinus. Yet, the choice of a critical time point where the airway must be closed will guide the subsequent possibilities as it provides the available processing time. One first choice could be the passage of the bolus through the UES. It has the advantage to be easily (but coarsely) measurable through cervical auscultation (section 5.2) and marks the beginning of the physiological event of pharyngeal clearance, through propulsion forces and UES opening. But the UES may start to open before the propulsion forces start to effectively act on the bolus [105, 225]. As a second choice, and perhaps more precise, the closure of the laryngeal vestibule is directly akin to the physiological requirement of the airway to be closed. This event may also be measurable through cervical auscultation [225], but this has to be confirmed. In any case, both events can be visualized with videofluoroscopy, but it requires X-ray exposure and a safer modality would be beneficial. Finally, the mechanical design of any implantable active artificial larynx could also add in the protective aspect, so that it reduces the risks of aspiration anyway. But these two parts must be considered separately, at least in the first place, so that they complement each other.

The submental area is acknowledged to initiate the propulsion stage as it supports the stereotypical *squeezing movement* of the tongue that drives the bolus posteriorly (section 3.1.1). Independently, most studies consider the mylohyoid as the leading muscle. It has been shown to activate 382ms before the airway closure on average [38] and to correlate significantly with the tongue-palate pressure [47]. But every submental muscles actually activate around the same time and may prove to be relevant, since they are primarily involved in hyoid bone movements. Also, several studies suggest that the stylohyoid and the anterior digastric muscles might help the submental muscles as they activate at the same time, both from animal functional data [39, 71] and from human investigations based on recent imaging methods [70]. Concurrently, the velopharyngeal muscles also activate to close the nasal cavity and protect it from regurgitation. But their activity usual arises around the onset of the submental muscles, while the velopharyngeal pressure is apparent around the relaxation of the UES. This means that the velopharyngeal muscle activities begin significantly earlier than the pressure [105, 139]. In any case, the activated muscles mentioned so far form a first group, that fires around the beginning of the swallowing. But then, a second group activates. The thyrohyoid muscle approximates the hyoid bone and the larynx, and the tongue base drops to allow the bolus posteriorly [38]. This latter movement partly originates from the contraction of the genioglossus, and is directly followed by the palatopharyngeus and the superior pharyngeal constrictor, likely to accommodate for the arrival of the bolus into the oropharynx [39, 68, 90]. Also, some fibers of the palatopharyngeus blend with the UES [125], which may participates in its opening and further hint toward its early firing. But the superior pharyngeal constrictor activity is actually still modest, as no *stripping wave* has started yet. It requires the subsequent opening of the UES and closure of the airway, to fully fire and guide the bolus down the pharynx [105, 107]. But this hazy time window cannot precisely be defined because of the inherent variability of the swallowing process. The size of the bolus, for instance, requires the UES to widen accordingly, and the viscosity seems to primarily act on pharyngeal constrictor activity. This can therefore shuffle the precise ordering of the related events [50]. In any case, this means that the full activity of the superior pharyngeal constrictor and the subsequent events cannot be used as the main contributors to swallowing detection but only as a potential adjunct measurement.

6.2 No false detection

Detection algorithms come in numerous types, complexity and purpose and will not be covered here, but their efficiency ultimately always falls down to the quality of the information it has about the tasks to discriminate. The more dedicated and stable the signal from a task is, the easier it is to detect it. Yet, there is an inherent variability in swallowing. Several successive swallowing, with the same bolus, will still show substantial variations, both inter and intra subjects. In addition, most muscles show important activity for various tasks, which can occur separately or concurrently with swallowing and make the signals more complex. It is thus important to inherently seek

for signals that contain as repeatable and discernible patterns as possible.

The submental muscles recorded as a group, could provide substantial information as it tends to be free of cross-talk [54], and to be representative of the underlying muscles [55]. But it activates for various activities, and each muscle independently may provide more dedicated information. The mylohyoid and the geniohyoid are structurally suited to exert most of the forces required to move the hyoid bone [57], and the mylohyoid and anterior digastric significantly correlate with the tongue-palate pressure during the propulsion stage [47]. Actually, the posterior part of the genioglossus also adds to the effort, but it is highly involved in tongue movements, is the main airway dilator and activates proportionally to negative airway pressure [162]. Also, the stereotypical mechanical movement of the tongue base, during the propulsion stage, might add relevant information, at least as an adjunct measurement. But there is no reliable way to measure it, because of the gag reflex (section 3.3). Otherwise, investigations on pig models showed promising results. The stylohyoid and the thyrohyoid were found to provide a repeatable, stable and distinguishable pattern of activity and to significantly shorten. Those results have, however, to be mitigated as the study only investigated sucking and swallowing sequences [71–73]. But the stylohyoid and the posterior digastric were studied in humans, as a muscle group, by Kurt et al. [77]. They showed that these muscles primarily fire during swallowing and jaw opening, whereas they are innervated by the facial nerve, which is primarily involved in mimicry and facial movements. Thereby, they emphasized that these muscles may have a significant potential in the electrophysiological identification of swallowing. Besides, the velopharyngeal region is of great importance in nasal cavity protection. The soft palate moves superiorly and presses against the pharyngeal wall, which generates a net and repeatable pressure pattern [105]. This is caused by the activation of the soft palate muscles, that also play a role in breathing and speech. But pressure data seem to allow, at least for simple tasks, to discriminate between swallowing and vocalization [250], while muscle activities may only allow to differentiate from breathing and speech in a subset of healthy swallowing [137]. Then, apart from these regions, the pharyngeal muscles may prove to be relevant. The superior pharyngeal constrictor has been shown to exert most of its activity during swallowing [87]. Also, the longitudinal muscles have been studied with recent imaging methods, and seem to activate in an effort comparable to that of the submental muscles [69]. In any case, the muscles described so far also activate for other tasks. So, none one of them is guaranteed to provide a truly dedicated firing pattern. And even though some may be particularly akin to swallowing, there is still a lack of cross-tasks comparison and, ultimately, it may be beneficial to add an adjunct measurement. The tongue as been proposed for its particular movement in swallowing, but there might exist some suitable combinations. For instance, the swallowing and jaw opening main activities of the stylohyoid and posterior digastric, could potentially be discriminated with the help of the infrahyoid muscles. Indeed, they are required in jaw opening to stabilize the hyoid bone, but fire later in swallowing [38]. But this type of strategy has to be further explored.

6.3 Post surgery anatomy and implantation

Total laryngectomy removes the larynx along with the hyoid bone, and every muscle that insert to them are separated. The thyrohyoid muscle can also be resected as it originates and inserts on the hyolaryngeal complex, and most of the infrahyoid muscles may be removed as well, if the spread of the tumor requires it. This leaves the swallowing process impaired, the UES functioning is poor, and the pharyngeal propulsive forces are often inadequate (section 4). But several anatomical regions can provide a relevant activity as they are likely left with little to no alteration. Basically, as every muscle left in place are only separated from their insertion point from the hyolaryngeal complex, their electrical activity should still be relevant. This has however to be cautiously considered. Important sensory inputs from the larynx are lost and the surrounding tissues are damaged, which may alter the proper sequencing of the various muscles involved. Besides, whatever the measurement modality, the implantation of a detection system ultimately requires the positioning of the sensors and the tunneling of the cables. This could actually further impair the head and neck area and the swallowing process, which cannot be allowed. Therefore, the chosen anatomical areas should be easily accessible.

The pressure measured in the pharynx has been shown to be very consistent in healthy swallowing, but only its upper part ends up with little variation post surgery. The velopharyngeal region has no change in peak intensity and the mesopharynx is likely to exhibit a repetitive and reliable pattern [179] (Figure 8). Also, the surgery leaves the soft palate muscles untouched. But these regions would typically require the undesired tunneling of cables through the neck and the soft palate region is not adequate for sensor implantation. The same goes for most of the external tongue muscles, which are not easily accessible. But the genioglossus, along with the submental muscles, are easier to access and may be good candidates, as the oral propulsion forces are conserved and are usually used to compensate for the lack of pharyngeal integrity (section 4). In addition, the stereotypical movement of the tongue during this stage would likely provide relevant information, but there is no easy and implantable way to measure it (section 3.3). Beside, the longitudinal pharyngeal muscles, especially the palatopharyngeus, are easily accessible during surgery, but only their lower part would not require cable tunneling. And even though the palatopharyngeus seems to exhibit regional firing [89], extensive research is required. Finally, the most accessible muscles are obviously the infrahyoid muscles, because of their position on the anterior neck, as well as the stylohyoid and posterior digastric. They are directly uncovered during the surgery and they only have their insertion point removed from the larynx.

However, one can argue about the possible removal of all the infrahyoid muscles that makes them an irrelevant choice. But their accessibility makes them good candidates anyway. The solution may come from the field of *peripheral nerve interface* that have recently been through considerable advanced. A wide range of methods has been developed to access the information provided by a nerve, but the most effective one so far, with regard to the topic of this paper, is called *Regenerative Peripheral Nerve Interface* (RPNI) [251]. It basically uses a graft muscle to replace the resected one. The nerve grows into it and ends

up being able to activate the graft in a significant manner. This method has shown great promises in the command of artificial prosthetic limbs. Both in terms of signal quality and durability [252].

6.4 Power consumption

The implementation of an active artificial larynx requires the development of an autonomous, self powered and enduring system that ensures the safety of the patient. This kind of system is part of the group of *embedded systems*, which are computing systems designed for specific control functions. As opposed to general purpose computers, the tasks are predefined and limited, and may need to be achieved in a required amount of time. In the recent past, the growing demand of effective embedded systems led to their increase in capabilities and consequently their consumption. Yet, the consumption of such a system is of major importance to limit the maintenance, save energy and, therefore, avoid unnecessary surgery in case of implanted devices. The consumption is usually divided into two major components: (1) *the dynamic power*, which is the power consumes during the functioning of the system. (2) *The leakage power*, which is an unwanted minimum power consumed when no part of the system is used, and refers to the inherent imperfection of the hardware. Besides, when the system is running a task, it is considered *active* and its consumption is the sum of these tow components. Otherwise, it waits in *idle* state and mostly consumes leakage power. Therefore, their precise impact depends on the hardware and the software architecture and their reduction enables the use of reduced battery size. This later point not only reduce the size of the system, but can also reduce heating, which may act on the patient safety and the system reliability. Finally, lots of researches are done to reduce the leakage power, either from a hardware perspective or with an effective hardware management from the software. But the anatomical considerations of this paper only allows to have an impact on the dynamic power. As a simplified rule of thumb, the simpler the signals to analyse, the simpler the detection algorithm and the lower the dynamic power consumption [253].

Indeed, detection algorithms basically analyse the signals continuously. The first approach would be to run the whole detection strategy at any time, but it would result in a huge dynamic power consumption, even when there is no particular signal activity. Therefore, an effective approach often implies at least tow stages of detection to discriminate between the needs to run the whole strategy or not. This can be as simple as the use of a threshold to detect a rise in activity, or can also implies the use of a dedicated scheme. But the energy efficiency of such an approach can only be as good as the signals at hands. Yet, there is an inherent variability in swallowing. Several successive swallowing, with the same bolus, will still show substantial variations, both inter and intra subject. In addition, most muscles show important activity for various tasks along with swallowing, which can make the signals more complex. So, to make an efficient use of dynamic power, the signals must not provide a seemingly random pattern of activity, which translate in signals with as sparse, repeatable and dedicated activity as possible.

In that regard, the submental area, as a group, is likely to be one of the worst muscles to rely on, as it supports the tongue and the jaw in their numerous behaviors. But measured independently, the underlying muscles may provide a more reliable activity as they each participate in a specific aspect of swallowing [57] and correlate significantly with the propulsion stage [47]. Otherwise, the velopharyngeal pressure is a quit specific event. Even though it occurs in various tasks such as speech, it shows a very stable pattern during swallowing as it requires a particular sealing [105]. Beside, animal studies highlighted the large variability in the sternohyoid and sternothyroid muscles while the thyrohyoid and stylohyoid muscles exhibited a repetitive behavior [71, 72] (Figure 4). In addition, Kurt et al. [77] provided a detailed analysis of the stylohyoid and posterior digastric activity. They highlighted the relationship of these muscles with the submental area, whereas they exhibit a more dedicated activity. The authors emphasized the importance that these muscles may have in electrophysiological identification. In any case, other anatomical areas may be relevant, but there is a lack of objective tasks comparison. While some muscles are obviously active in most tasks, like the genioglossus [158, 162], others may be more subtle. Actually, the quality of the signals is important for power consumption, but one may keep in mind that a detection algorithm may also lead to less power consumption with apparently more complicated signals.

7 Conclusion

The total laryngectomy still represents the most effective treatment for laryngeal cancer. But it leaves the aerodigestive tract heavily impaired, the tracheostomy comes with several adverse effects and the patients report an impact on their self-esteem. There is, however, no solution that allows to restore the natural pathway of the airway, and the subsequent definitive closure of the tracheostomy. This would require to emulate the switching mechanism, primarily akin to the larynx, that protect the airway from bolus aspiration during swallowing. Yet, the ease of the somewhat unconscious every day swallowing hides the considerable complexity of such a mechanism. It involves the coordinated activation of more than 25 pairs of muscles that channel the bolus from the oral cavity to the stomach. This is accomplished through the command of the central pattern generator, composed of several neural networks located in the brain stem. It modulates the swallowing process according to the various situations and bolus characteristics encountered, which virtually makes no swallowing the same. But the protective mechanism of the airway ultimately falls down to an on-off closure that must be accomplished before the arrival of the bolus. In addition, the observations from the first ever implanted valve-based artificial larynx in 2012, by Debry et al. [23], highlighted the limitations of an entirely passive approach, as residues were found in the trachea [25]. An active and early detection of swallowing would therefore considerably improve the reliability of such a system, since the airway could be forcibly closed beforehand. But this would require the real-time measurement of the swallowing process and the management of its inherent variability, to be able to robustly detect its onset. The attempt of this paper was therefore to provide an overview of the elements

that would pave the way toward a robust swallowing detection following total laryngectomy.

Until now, the attempts to detect a swallowing only focused on the development of assessment tools for a clinical practice. But these approaches are non invasive and cannot access all the details of the entire process, which limits the detection performances. Recent works from Mialland et al. [246], however, marks the beginning of investigations that inherently seeks to build the foundations of a robust swallowing detection. And even though the precise requirements are not fixed, several possible lines of research can be mentioned. The most important aspect might be the needs in systematic investigation of relevant muscles, with regard to their timing of activation and signal content, in various situations and tasks. This would provide a set of potentially useful muscles that activate around the onset of a swallowing. Therefore, this also requires the use of an ultimate time point where the airway has to be closed. That would define the available detection time and form a basis for the design of a detection algorithm. But there is no safe and easily applied method to define that point. Also, a safe and effective detection system would ideally use only one sensor, but the cross-tasks activation of the muscles might require to take advantage of the combined information from more than one measurement. A precise comparison of the available signals would therefore be beneficial. Finally, these have first to be investigated in healthy subjects, to get basis muscle activities, but the same investigation will have to be performed on post-laryngectomy patients, to challenge the initial hypothesis.

Also, this paper did not mentioned several other aspects as we only considered the swallowing mechanism without the corner cases. In the event of premature spillage or delayed swallowing onset, no early activity is available to detect the arrival of the bolus. Vomiting and sneezing are also of particular importance as they required the airway to be closed, but the related muscles activates in an unusual way [254, 255]. Also, there might be some disorders that have to be considered, like obstructive sleep apnea, or the sometime pernicious decay in swallowing ability with age [108]. Then, a detailed neurological investigation could help to find a dedicated and reliable information from the nerves [35], and the field of peripheral nerve interfaces shows promising results that might provide an appropriate measurement modality [251]. Besides, the precise aspect of the airway protective mechanism as yet to be investigated and the research on biomaterials is of prime importance [256]. A particular focus also have to be placed in the security aspects, to mechanically forbid any definitive closure of the airway. Otherwise, the detection algorithm has to be effective, safe and of low consumption. The rapidly growing field of embedded systems provides an increasing number of solutions [257]. Finally, we aimed at the rehabilitation of the aerodigestive tracts following total laryngectomy, through the indwelling measurement of *unaltered* anatomical events. This means that present investigation might prove to be useful for a broader perspective. For instance, in case of severe dysphagia without the removal of the larynx, one could investigate the same aspects but aim at a dedicated closure mechanism. This has however to be thoroughly studied as both cases are specifically altered. Actually, whatever the origin of the aerodigestive tract disruption, there is still the possibility that every alteration tends

to be unique, and that a somewhat dedicated approach might be required.

References

- [1] Antoine Eskander et al. “Decision making in advanced larynx cancer: An evidenced based review”. In: *Oral Oncology* (2018). DOI: [10.1016/j.oraloncology.2018.09.019](https://doi.org/10.1016/j.oraloncology.2018.09.019).
- [2] Globocan. *Cancer tomorrow. A tool that predicts the future cancer incidence and mortality burden worldwide from the current estimates up until 2040*. <https://gco.iarc.fr/tomorrow/home>. 2008.
- [3] Elaine Nicpon Marieb et al. *Human Anatomy & Physiology*. Pearson Education, 2012.
- [4] Thomas K. Hoffmann. “Total Laryngectomy—Still Cutting-Edge?” In: *Cancers* (2021). DOI: [10.3390/cancers13061405](https://doi.org/10.3390/cancers13061405).
- [5] P. M. Stell. “The first laryngectomy”. In: *The Journal of Laryngology & Otolaryngology* (1975). DOI: [10.1017/S0022215100080488](https://doi.org/10.1017/S0022215100080488).
- [6] Dimitrios Assimakopoulos et al. “Highlights in the Evolution of Diagnosis and Treatment of Laryngeal Cancer”. In: *The Laryngoscope* (2003). DOI: [10.1097/00005537-200303000-00030](https://doi.org/10.1097/00005537-200303000-00030).
- [7] W. Alberti Peter. “The History of Laryngology: A Centennial Celebration”. In: *Otolaryngology—Head and Neck Surgery* (1996). DOI: [10.1016/S0194-59989670202-4](https://doi.org/10.1016/S0194-59989670202-4).
- [8] Christopher G. Tang et al. “Voice Restoration After Total Laryngectomy”. In: *Otolaryngologic Clinics of North America* (2015). DOI: [10.1016/j.otc.2015.04.013](https://doi.org/10.1016/j.otc.2015.04.013).
- [9] A. SERRA et al. “Post-laryngectomy voice rehabilitation with voice prosthesis: 15 years experience of the ENT Clinic of University of Catania. Retrospective data analysis and literature review”. In: *Acta Otorhinolaryngologica Italica* (2015). DOI: [10.14639/0392-100X-680](https://doi.org/10.14639/0392-100X-680).
- [10] Rachel Kaye et al. “The electrolarynx: voice restoration after total laryngectomy”. In: *Medical Devices (Auckland, N.Z.)* (2017). DOI: [10.2147/MDER.S133225](https://doi.org/10.2147/MDER.S133225).
- [11] Krzysztof Izdebski et al. “Problems With Tracheoesophageal Fistula Voice Restoration in Totally Laryngectomized Patients: A Review of 95 Cases”. In: *Archives of Otolaryngology—Head & Neck Surgery* (1994). DOI: [10.1001/archotol.1994.01880320042010](https://doi.org/10.1001/archotol.1994.01880320042010).
- [12] Susanne Singer et al. “Quality of life before and after total laryngectomy: Results of a multicenter prospective cohort study”. In: *Head & Neck* (2014). DOI: [10.1002/hed.23305](https://doi.org/10.1002/hed.23305).
- [13] Stuart M. Robertson et al. “Voice, swallowing, and quality of life after total laryngectomy—Results of the west of Scotland laryngectomy audit”. In: *Head & Neck* (2012). DOI: [10.1002/hed.21692](https://doi.org/10.1002/hed.21692).
- [14] Gregory S. Weinstein et al. “Laryngeal Preservation With Supracricoid Partial Laryngectomy Results in Improved Quality of Life When Compared With Total Laryngectomy”. In: *The Laryngoscope* (2001). DOI: [10.1097/00005537-200102000-00001](https://doi.org/10.1097/00005537-200102000-00001).
- [15] Giri Krishnan et al. “The current status of human laryngeal transplantation in 2017: A state of the field review”. In: *The Laryngoscope* (2017). DOI: [10.1002/lary.26503](https://doi.org/10.1002/lary.26503).
- [16] Maciej Grajek et al. “First Complex Allotransplantation of Neck Organs: Larynx, Trachea, Pharynx, Esophagus, Thyroid, Parathyroid Glands, and Anterior Cervical Wall: A Case Report”. In: *Annals of Surgery* (2017). DOI: [10.1097/SLA.0000000000002262](https://doi.org/10.1097/SLA.0000000000002262).
- [17] D. Gregory Farwell et al. “Laryngotracheal transplantation”. In: *The Laryngoscope* (2013). DOI: [10.1002/lary.24053](https://doi.org/10.1002/lary.24053).
- [18] Marshall Strome et al. “Laryngeal Transplantation and 40-Month Follow-up”. In: *New England Journal of Medicine* (2001). DOI: [10.1056/NEJM200105313442204](https://doi.org/10.1056/NEJM200105313442204).
- [19] Robert R. Lorenz et al. “Total Laryngeal Transplant Explanted: 14 Years of Lessons Learned”. In: *Otolaryngology—Head and Neck Surgery* (2014). DOI: [10.1177/0194599813519748](https://doi.org/10.1177/0194599813519748).
- [20] Arnaud F. Bewley et al. “Laryngeal Transplantation”. In: *Advances in Neurology* (2020). DOI: [10.1159/000456691](https://doi.org/10.1159/000456691).
- [21] David G. Lott et al. “Aggressive Behavior of Nonmelanotic Skin Cancers in Solid Organ Transplant Recipients”. In: *Transplantation* (2010). DOI: [10.1097/TP.0b013e3181ec7228](https://doi.org/10.1097/TP.0b013e3181ec7228).
- [22] C. P. S. Potter et al. “Laryngectomees’ views on laryngeal transplantation”. In: *Transplant International* (1998). DOI: [10.1111/j.1432-2277.1998.tb00832.x](https://doi.org/10.1111/j.1432-2277.1998.tb00832.x).
- [23] Christian Debry et al. “Laryngeal replacement with an artificial larynx after total laryngectomy: The possibility of restoring larynx functionality in the future”. In: *Head & Neck* (2014). DOI: [10.1002/hed.23621](https://doi.org/10.1002/hed.23621).
- [24] Christian Debry et al. “Implantation of an Artificial Larynx after Total Laryngectomy”. In: *New England Journal of Medicine* (2017). DOI: [10.1056/NEJMc1611966](https://doi.org/10.1056/NEJMc1611966).
- [25] Luca D’Ascanio et al. *More on Implantation of an Artificial Larynx after Total Laryngectomy*. 2017. DOI: [10.1056/NEJMc1701193](https://doi.org/10.1056/NEJMc1701193).
- [26] E. Brenet et al. “Évolution du larynx artificiel vers le biologique : réhabilitation laryngée par allogreffe aortique chez la brebis”. In: *Bulletin de l’Académie Nationale de Médecine* (2020). DOI: [10.1016/j.banm.2020.02.002](https://doi.org/10.1016/j.banm.2020.02.002).
- [27] Jingjing Chen et al. “Tissue engineering of the larynx: A contemporary review”. In: *Journal of Clinical Laboratory Analysis* (2021). DOI: [10.1002/jcla.23646](https://doi.org/10.1002/jcla.23646).
- [28] Emmanuel Martinod et al. “Feasibility of Bioengineered Tracheal and Bronchial Reconstruction Using Stented Aortic Matrices”. In: *JAMA* (2018). DOI: [10.1001/jama.2018.4653](https://doi.org/10.1001/jama.2018.4653).
- [29] Richard Drake et al. *Gray’s anatomy for students E-book*. Elsevier Health Sciences, 2009.
- [30] Jenny Walton et al. “Physiology of swallowing”. In: *Surgery (Oxford)* (2018). DOI: [10.1016/j.mpsur.2018.08.010](https://doi.org/10.1016/j.mpsur.2018.08.010).
- [31] Ashwini M. Namasivayam-MacDonald et al. “A review of swallow timing in the elderly”. In: *Physiology & Behavior* (2018). DOI: [10.1016/j.physbeh.2017.10.023](https://doi.org/10.1016/j.physbeh.2017.10.023).
- [32] Stephanie M. Shaw et al. “The Normal Swallow: Muscular and Neurophysiological Control”. In: *Otolaryngologic Clinics of North America* (2013). DOI: [10.1016/j.otc.2013.09.006](https://doi.org/10.1016/j.otc.2013.09.006).
- [33] Koichiro Matsuo et al. “Anatomy and Physiology of Feeding and Swallowing: Normal and Abnormal”. In: *Physical Medicine and Rehabilitation Clinics of North America* (2008). DOI: [10.1016/j.pmr.2008.06.001](https://doi.org/10.1016/j.pmr.2008.06.001).
- [34] Cumhur Ertekin et al. “Neurophysiology of swallowing”. In: *Clinical Neurophysiology* (2003). DOI: [10.1016/S1388-2457\(03\)00237-2](https://doi.org/10.1016/S1388-2457(03)00237-2).
- [35] André Jean. “Brain Stem Control of Swallowing: Neuronal Network and Cellular Mechanisms”. In: *Physiological Reviews* (2001). DOI: [10.1152/physrev.2001.81.2.929](https://doi.org/10.1152/physrev.2001.81.2.929).
- [36] W J Dodds et al. “Physiology and radiology of the normal oral and pharyngeal phases of swallowing.” In: *American Journal of Roentgenology* (1990). DOI: [10.2214/ajr.154.5.2108569](https://doi.org/10.2214/ajr.154.5.2108569).
- [37] Robert W. Doty et al. “An electromyographic analysis of reflex deglutition”. In: *Journal of Neurophysiology* (1956). DOI: [10.1152/jn.1956.19.1.44](https://doi.org/10.1152/jn.1956.19.1.44).
- [38] Donghwi Park et al. “Normal contractile algorithm of swallowing related muscles revealed by needle EMG and its comparison to videofluoroscopic swallowing study and high resolution manometry studies: A preliminary study”. In: *Journal of Electromyography and Kinesiology* (2017). DOI: [10.1016/j.jelekin.2017.07.007](https://doi.org/10.1016/j.jelekin.2017.07.007).
- [39] A. J. Thexton et al. “Electromyographic activity during the reflex pharyngeal swallow in the pig: Doty and Bosma (1956) revisited”. In: *Journal of Applied Physiology* (2007). DOI: [10.1152/jappphysiol.00456.2006](https://doi.org/10.1152/jappphysiol.00456.2006).
- [40] Thomas Gay et al. “Oral and laryngeal muscle coordination during swallowing”. In: *The Laryngoscope* (1994). DOI: [10.1288/00005537-199403000-00017](https://doi.org/10.1288/00005537-199403000-00017).
- [41] Alan W. Hrycyszyn et al. “Electromyography of the oral stage of swallowing in man”. In: *American Journal of Anatomy* (1972). DOI: [10.1002/aja.1001330307](https://doi.org/10.1002/aja.1001330307).
- [42] Donald P. Cunningham et al. “Electromyography of genioglossus and geniohyoid muscles during deglutition”. In: *The Anatomical Record* (1969). DOI: doi.org/10.1002/ar.1091650309.

- [43] Haruhi Inokuchi et al. "Electromyography of Swallowing with Fine Wire Intramuscular Electrodes in Healthy Human: Amplitude Difference of Selected Hyoid Muscles". In: *Dysphagia* (2016). DOI: 10.1007/s00455-015-9655-9.
- [44] Haruhi Inokuchi et al. "Electromyography of Swallowing with Fine Wire Intramuscular Electrodes in Healthy Human: Activation Sequence of Selected Hyoid Muscles". In: *Dysphagia* (2014). DOI: 10.1007/s00455-014-9566-1.
- [45] Y. Miura et al. "Effects of Taste Solutions, Carbonation, and Cold Stimulus on the Power Frequency Content of Swallowing Submental Surface Electromyography". In: *Chemical Senses* (2009). DOI: 10.1093/chemse/bjp005.
- [46] Phyllis M. Palmer et al. "Effects of a Sour Bolus on the Intramuscular Electromyographic (EMG) Activity of Muscles in the Submental Region". In: *Dysphagia* (2005). DOI: 10.1007/s00455-005-0017-x.
- [47] Palmer Phyllis M. et al. "Quantitative Contributions of the Muscles of the Tongue, Floor-of-Mouth, Jaw, and Velum to Tongue-to-Palate Pressure Generation". In: *Journal of Speech, Language, and Hearing Research* (2008). DOI: 10.1044/1092-4388(2008/060).
- [48] Maggie-Lee Huckabee et al. "Submental Surface Electromyographic Measurement and Pharyngeal Pressures During Normal and Effortful Swallowing". In: *Archives of Physical Medicine and Rehabilitation* (2005). DOI: 10.1016/j.apmr.2005.05.005.
- [49] Cumhuri Ertekin et al. "An electrophysiological investigation of deglutition in man". In: *Muscle & Nerve* (1995). DOI: 10.1002/mus.880181014.
- [50] Charles Cock et al. "Modulation of Upper Esophageal Sphincter (UES) Relaxation and Opening During Volume Swallowing". In: *Dysphagia* (2017). DOI: 10.1007/s00455-016-9744-4.
- [51] E. Zaretsky et al. "Identification of the most significant electrode positions in electromyographic evaluation of swallowing-related movements in humans". In: *European Archives of Oto-Rhino-Laryngology* (2017). DOI: 10.1007/s00405-016-4288-7.
- [52] Mingxing Zhu et al. "Evaluation of normal swallowing functions by using dynamic high-density surface electromyography maps". In: *BioMedical Engineering OnLine* (2017). DOI: 10.1186/s12938-017-0424-x.
- [53] Stepp Cara E. "Surface Electromyography for Speech and Swallowing Systems: Measurement, Analysis, and Interpretation". In: *Journal of Speech, Language, and Hearing Research* (2012). DOI: 10.1044/1092-4388(2011/11-0214).
- [54] Martin J McKeown et al. "Non-invasive monitoring of functionally distinct muscle activations during swallowing". In: *Clinical Neurophysiology* (2002). DOI: 10.1016/S1388-2457(02)00007-X.
- [55] Palmer Phyllis M. et al. "Contributions of Individual Muscles to the Submental Surface Electromyogram During Swallowing". In: *Journal of Speech, Language, and Hearing Research* (1999). DOI: 10.1044/js1hr.4206.1378.
- [56] William G. Pearson et al. "Structural Analysis of Muscles Elevating the Hyolaryngeal Complex". In: *Dysphagia* (2012). DOI: 10.1007/s00455-011-9392-7.
- [57] William G. Pearson et al. "Evaluating the Structural Properties of Suprahyoid Muscles and their Potential for Moving the Hyoid". In: *Dysphagia* (2011). DOI: 10.1007/s00455-010-9315-z.
- [58] O'Dwyer Nicolas J. et al. "Procedures for Verification of Electrode Placement in EMG Studies of Orofacial and Mandibular Muscles". In: *Journal of Speech, Language, and Hearing Research* (1981). DOI: 10.1044/jshr.2402.273.
- [59] Koji Hara et al. "Treatment and evaluation of dysphagia rehabilitation especially on suprahyoid muscles as jaw-opening muscles". In: *Japanese Dental Science Review* (2018). DOI: 10.1016/j.jdsr.2018.06.003.
- [60] Katherine A. Hutcherson et al. "Expiratory muscle strength training evaluated with simultaneous high-resolution manometry and electromyography". In: *The Laryngoscope* (2017). DOI: 10.1002/lary.26397.
- [61] Evelyne Van Houtte et al. "An Examination of Surface EMG for the Assessment of Muscle Tension Dysphonia". In: *Journal of Voice* (2013). DOI: 10.1016/j.jvoice.2011.06.006.
- [62] Mitsuyoshi Yoshida et al. "Comparison of surface electromyographic (sEMG) activity of submental muscles between the head lift and tongue press exercises as a therapeutic exercise for pharyngeal dysphagia". In: *Gerodontology* (2007). DOI: 10.1111/j.1741-2358.2007.00164.x.
- [63] Yiu Edwin M-L et al. "Electromyographic Study of Motor Learning for a Voice Production Task". In: *Journal of Speech, Language, and Hearing Research* (2005). DOI: 10.1044/1092-4388(2005/087a).
- [64] Annalisa Monaco et al. "Surface electromyography pattern of human swallowing". In: *BMC Oral Health* (2008). DOI: 10.1186/1472-6831-8-6.
- [65] Michael A. Crary et al. "Biomechanical Correlates of Surface Electromyography Signals Obtained During Swallowing by Healthy Adults". In: *Journal of Speech, Language, and Hearing Research* (2006). DOI: 10.1044/1092-4388(2006/015).
- [66] Ding Ruiying et al. "The Effects of Taste and Consistency on Swallow Physiology in Younger and Older Healthy Individuals". In: *Journal of Speech, Language, and Hearing Research* (2003). DOI: 10.1044/1092-4388(2003/076).
- [67] Kellie Filter Sciortino et al. "Effects of Mechanical, Cold, Gustatory, and Combined Stimulation to the Human Anterior Faucial Pillars". In: *Dysphagia* (2003). DOI: 10.1007/s00455-002-0076-1.
- [68] A. L. Perlman et al. "Electromyographic activity from human laryngeal, pharyngeal, and submental muscles during swallowing". In: *Journal of Applied Physiology* (1999). DOI: 10.1152/jappl.1999.86.5.1663.
- [69] William G. Pearson et al. "Evaluating Swallowing Muscles Essential for Hyolaryngeal Elevation by Using Muscle Functional Magnetic Resonance Imaging". In: *International Journal of Radiation Oncology*Biophysics* (2013). DOI: 10.1016/j.ijrobp.2012.07.2370.
- [70] Takeshi Okada et al. "Dynamic change in hyoid muscle length associated with trajectory of hyoid bone during swallowing: analysis using 320-row area detector computed tomography". In: *Journal of Applied Physiology* (2013). DOI: 10.1152/jappphysiol.00467.2013.
- [71] Rebecca Z. German et al. "Integration of the Reflex Pharyngeal Swallow Into Rhythmic Oral Activity in a Neurologically Intact Pig Model". In: *Journal of Neurophysiology* (2009). DOI: 10.1152/jn.00100.2009.
- [72] A. J. Thexton et al. "EMG activity in hyoid muscles during pig suckling". In: *Journal of Applied Physiology* (2012). DOI: 10.1152/jappphysiol.00450.2011.
- [73] C. J. Mayerl et al. "The contractile patterns, anatomy and physiology of the hyoid musculature change longitudinally through infancy". In: *Proceedings of the Royal Society B: Biological Sciences* (2021). DOI: 10.1098/rspb.2021.0052.
- [74] R.R. Munro. "Activity of the Digastric Muscle in Swallowing and Chewing". In: *Journal of Dental Research* (1974). DOI: 10.1177/00220345740530030401.
- [75] R.R. Munro. "Coordination of Activity of the two Bellies of the Digastric Muscle in Basic Jaw Movements". In: *Journal of Dental Research* (1972). DOI: 10.1177/00220345720510062801.
- [76] S.-E. Widmalm et al. "Anatomical and electromyographic studies of the digastric muscle". In: *Journal of Oral Rehabilitation* (1988). DOI: 10.1111/j.1365-2842.1988.tb00142.x.
- [77] Tülay Kurt et al. "Electrophysiologic identification and evaluation of stylohyoid and posterior digastricus muscle complex". In: *Journal of Electromyography and Kinesiology* (2006). DOI: 10.1016/j.jelekin.2005.06.014.
- [78] J. C. Türp et al. "Is the posterior belly of the digastric muscle palpable? A qualitative systematic review of the literature". In: *Clinical Anatomy* (2005). DOI: 10.1002/ca.20104.
- [79] Sung Deuk Kim et al. "Anatomy and variations of digastric muscle". In: *Anatomy & Cell Biology* (2019). DOI: 10.5115/acb.2019.52.1.1.

- [80] B. De-Ary-Pires et al. "The human digastric muscle: Patterns and variations with clinical and surgical correlations". In: *Annals of Anatomy - Anatomischer Anzeiger* (2003). DOI: [10.1016/S0940-9602\(03\)80110-3](https://doi.org/10.1016/S0940-9602(03)80110-3).
- [81] Martin W. Donner et al. "Anatomy and physiology of the pharynx". In: *Gastrointestinal Radiology* (1985). DOI: [10.1007/BF01893103](https://doi.org/10.1007/BF01893103).
- [82] D. V. Sivarao et al. "Functional anatomy and physiology of the upper esophageal sphincter". In: *The American Journal of Medicine* (2000). DOI: [10.1016/S0002-9343\(99\)00337-X](https://doi.org/10.1016/S0002-9343(99)00337-X).
- [83] I. J. Cook et al. "Opening mechanisms of the human upper esophageal sphincter". In: *American Journal of Physiology-Gastrointestinal and Liver Physiology* (1989). DOI: [10.1152/ajpgi.1989.257.5.G748](https://doi.org/10.1152/ajpgi.1989.257.5.G748).
- [84] Indu Ayappa et al. "The upper airway in sleep: physiology of the pharynx". In: *Sleep Medicine Reviews* (2003). DOI: [10.1053/smr.2002.0238](https://doi.org/10.1053/smr.2002.0238).
- [85] Samuel T. Kuna et al. "Superior Pharyngeal Constrictor Activation in Obstructive Sleep Apnea". In: *American Journal of Respiratory and Critical Care Medicine* (1997). DOI: [10.1164/ajrccm.156.3.9702053](https://doi.org/10.1164/ajrccm.156.3.9702053).
- [86] S T Kuna et al. "Respiratory-related pharyngeal constrictor muscle activity in normal human adults." In: *American Journal of Respiratory and Critical Care Medicine* (1997). DOI: [10.1164/ajrccm.155.6.9196107](https://doi.org/10.1164/ajrccm.155.6.9196107).
- [87] Perlman Adrienne L. et al. "Electrical Activity from the Superior Pharyngeal Constrictor During Reflexive and Nonreflexive Tasks". In: *Journal of Speech, Language, and Hearing Research* (1989). DOI: [10.1044/jshr.3204.749](https://doi.org/10.1044/jshr.3204.749).
- [88] J. V. Basmajian et al. "Electromyography of the pharyngeal constrictors and levator palati in man". In: *The Anatomical Record* (1961). DOI: [10.1002/ar.1091390414](https://doi.org/10.1002/ar.1091390414).
- [89] Lee D. Rowe et al. "Adaptation in the Function of Pharyngeal Constrictor Muscles". In: *Otolaryngology-Head and Neck Surgery* (1984). DOI: [10.1177/019459988409200404](https://doi.org/10.1177/019459988409200404).
- [90] Douglas J. Van Daele et al. "Timing of Glottic Closure during Swallowing: A Combined Electromyographic and Endoscopic Analysis". In: *Annals of Otolaryngology, Rhinology & Laryngology* (2005). DOI: [10.1177/000348940511400610](https://doi.org/10.1177/000348940511400610).
- [91] Michael J. Hammer et al. "Evaluating the Tongue-Hold Maneuver Using High-Resolution Manometry and Electromyography". In: *Dysphagia* (2014). DOI: [10.1007/s00455-014-9545-6](https://doi.org/10.1007/s00455-014-9545-6).
- [92] Rebecca J. Leonard et al. "Structural Displacements in Normal Swallowing: A Videofluoroscopic Study". In: *Dysphagia* (2000). DOI: [10.1007/s004550010017](https://doi.org/10.1007/s004550010017).
- [93] Katherine A. Kendall et al. "Timing of Events in Normal Swallowing: A Videofluoroscopic Study". In: *Dysphagia* (2000). DOI: [10.1007/s004550010004](https://doi.org/10.1007/s004550010004).
- [94] Sandro J. Stoeckli et al. "Interrater Reliability of Videofluoroscopic Swallow Evaluation". In: *Dysphagia* (2003). DOI: [10.1007/s00455-002-0085-0](https://doi.org/10.1007/s00455-002-0085-0).
- [95] Molly A. Knigge et al. "Implementation of High-resolution Manometry in the Clinical Practice of Speech Language Pathology". In: *Dysphagia* (2014). DOI: [10.1007/s00455-013-9494-5](https://doi.org/10.1007/s00455-013-9494-5).
- [96] Taher I. Omari et al. "Reproducibility and Agreement of Pharyngeal Automated Impedance Manometry With Videofluoroscopy". In: *Clinical Gastroenterology and Hepatology* (2011). DOI: [10.1016/j.cgh.2011.05.026](https://doi.org/10.1016/j.cgh.2011.05.026).
- [97] P. J. Kahrilas et al. "The Chicago Classification of esophageal motility disorders, v3.0". In: *Neurogastroenterology & Motility* (2015). DOI: [10.1111/nmo.12477](https://doi.org/10.1111/nmo.12477).
- [98] Sarah P. Rosen et al. "Pharyngeal swallowing pressures in the base-of-tongue and hypopharynx regions identified with three-dimensional manometry". In: *The Laryngoscope* (2017). DOI: [10.1002/lary.26483](https://doi.org/10.1002/lary.26483).
- [99] Katharina Winiker et al. "A systematic review of current methodology of high resolution pharyngeal manometry with and without impedance". In: *European Archives of Oto-Rhino-Laryngology* (2019). DOI: [10.1007/s00405-018-5240-9](https://doi.org/10.1007/s00405-018-5240-9).
- [100] Corinne A. Jones et al. "Methods for Measuring Swallowing Pressure Variability Using High-Resolution Manometry". In: *Frontiers in Applied Mathematics and Statistics* (2018). DOI: [10.3389/fams.2018.00023](https://doi.org/10.3389/fams.2018.00023).
- [101] Taher Omari et al. "High-resolution manometry: what about the pharynx?" In: *Current Opinion in Otolaryngology & Head and Neck Surgery* (2018). DOI: [10.1097/MOO.0000000000000491](https://doi.org/10.1097/MOO.0000000000000491).
- [102] Charles Cock et al. "Diagnosis of Swallowing Disorders: How We Interpret Pharyngeal Manometry". In: *Current Gastroenterology Reports* (2017). DOI: [10.1007/s11894-017-0552-2](https://doi.org/10.1007/s11894-017-0552-2).
- [103] Jason D. Mielen et al. "Automated Analysis of Pharyngeal Pressure Data Obtained with High-Resolution Manometry". In: *Dysphagia* (2011). DOI: [10.1007/s00455-010-9320-2](https://doi.org/10.1007/s00455-010-9320-2).
- [104] Taher I. Omari et al. "High-Resolution Pharyngeal Manometry and Impedance: Protocols and Metrics—Recommendations of a High-Resolution Pharyngeal Manometry International Working Group". In: *Dysphagia* (2020). DOI: [10.1007/s00455-019-10023-y](https://doi.org/10.1007/s00455-019-10023-y).
- [105] Chelsea C. Walczak et al. "Pharyngeal Pressure and Timing During Bolus Transit". In: *Dysphagia* (2017). DOI: [10.1007/s00455-016-9743-5](https://doi.org/10.1007/s00455-016-9743-5).
- [106] Fred M. S. McConnel. "Analysis of pressure generation and bolus transit during pharyngeal swallowing". In: *The Laryngoscope* (1988). DOI: [10.1288/00005537-198801000-00015](https://doi.org/10.1288/00005537-198801000-00015).
- [107] Anupam Pal et al. "Intrabolus pressure gradient identifies pathological constriction in the upper esophageal sphincter during flow". In: *American Journal of Physiology-Gastrointestinal and Liver Physiology* (2003). DOI: [10.1152/ajpgi.00030.2003](https://doi.org/10.1152/ajpgi.00030.2003).
- [108] Charles Cock et al. "Systematic Review of Pharyngeal and Esophageal Manometry in Healthy or Dysphagic Older Persons (>60 years)". In: *Geriatrics* (2018). DOI: [10.3390/geriatrics3040067](https://doi.org/10.3390/geriatrics3040067).
- [109] Pere Clavé et al. "Dysphagia: current reality and scope of the problem". In: *Nature Reviews Gastroenterology & Hepatology* (2015). DOI: [10.1038/nrgastro.2015.49](https://doi.org/10.1038/nrgastro.2015.49).
- [110] Sarah P. Rosen et al. "Effect of Body Position on Pharyngeal Swallowing Pressures Using High-Resolution Manometry". In: *Dysphagia* (2018). DOI: [10.1007/s00455-017-9866-3](https://doi.org/10.1007/s00455-017-9866-3).
- [111] Timothy M. McCulloch et al. "High-Resolution Manometry of Pharyngeal Swallow Pressure Events Associated with Head Turn and Chin Tuck". In: *Annals of Otolaryngology, Rhinology & Laryngology* (2010). DOI: [10.1177/000348941011900602](https://doi.org/10.1177/000348941011900602).
- [112] Yoichiro Aoyagi et al. "Effect of Tongue-Hold Swallow on Pharyngeal Contractile Properties in Healthy Individuals". In: *Dysphagia* (2021). DOI: [10.1007/s00455-020-10217-9](https://doi.org/10.1007/s00455-020-10217-9).
- [113] Matthew R. Hoffman et al. "High-Resolution Manometry of Pharyngeal Swallow Pressure Events Associated with Effortful Swallow and the Mendelsohn Maneuver". In: *Dysphagia* (2012). DOI: [10.1007/s00455-011-9385-6](https://doi.org/10.1007/s00455-011-9385-6).
- [114] Hiroshi Umeki et al. "Effects of a tongue-holding maneuver during swallowing evaluated by high-resolution manometry". In: *Otolaryngology-Head and Neck Surgery* (2009). DOI: [10.1016/j.otohns.2009.01.025](https://doi.org/10.1016/j.otohns.2009.01.025).
- [115] Mana Hasegawa et al. "Differential Response Pattern of Oropharyngeal Pressure by Bolus and Dry Swallows". In: *Dysphagia* (2018). DOI: [10.1007/s00455-017-9836-9](https://doi.org/10.1007/s00455-017-9836-9).
- [116] Tuo Lin et al. "Effect of bolus volume on pharyngeal swallowing assessed by high-resolution manometry". In: *Physiology & Behavior* (2014). DOI: [10.1016/j.physbeh.2014.01.030](https://doi.org/10.1016/j.physbeh.2014.01.030).
- [117] Roger Newman et al. "Effect of Bolus Viscosity on the Safety and Efficacy of Swallowing and the Kinematics of the Swallow Response in Patients with Oropharyngeal Dysphagia: White Paper by the European Society for Swallowing Disorders (ESSD)". In: *Dysphagia* (2016). DOI: [10.1007/s00455-016-9696-8](https://doi.org/10.1007/s00455-016-9696-8).
- [118] Matthew R. Hoffman et al. "Pharyngeal swallow adaptations to bolus volume measured with high-resolution manometry". In: *The Laryngoscope* (2010). DOI: [10.1002/lary.21150](https://doi.org/10.1002/lary.21150).
- [119] Ewa Olszewska et al. "Palatal anatomy for sleep apnea surgery". In: *Laryngoscope Investigative Otolaryngology* (2019). DOI: [10.1002/liv.2.238](https://doi.org/10.1002/liv.2.238).

- [120] Da-Yae Choi et al. "Anatomical Considerations of the Longitudinal Pharyngeal Muscles in Relation to their Function on the Internal Surface of Pharynx". In: *Dysphagia* (2014). DOI: [10.1007/s00455-014-9568-z](https://doi.org/10.1007/s00455-014-9568-z).
- [121] Jae Hoon Cho et al. "Surgical anatomy of human soft palate". In: *The Laryngoscope* (2013). DOI: [10.1002/lary.24067](https://doi.org/10.1002/lary.24067).
- [122] Jamie Perry. "Anatomy and Physiology of the Velopharyngeal Mechanism". In: *Seminars in Speech and Language* (2011). DOI: [10.1055/s-0031-1277712](https://doi.org/10.1055/s-0031-1277712).
- [123] Shinpei Okuda et al. "Morphologic Characteristics of Palatopharyngeal Muscle". In: *Dysphagia* (2008). DOI: [10.1007/s00455-007-9133-0](https://doi.org/10.1007/s00455-007-9133-0).
- [124] William G. Pearson et al. "Visualising hyolaryngeal mechanics in swallowing using dynamic MRI". In: *Computer Methods in Biomechanics and Biomedical Engineering: Imaging & Visualization* (2014). DOI: [10.1080/21681163.2013.846231](https://doi.org/10.1080/21681163.2013.846231).
- [125] Keiko Fukino et al. "Anatomy of inferior end of palatopharyngeus: its contribution to upper esophageal sphincter opening". In: *European Archives of Oto-Rhino-Laryngology* (2021). DOI: [10.1007/s00405-020-06437-2](https://doi.org/10.1007/s00405-020-06437-2).
- [126] Trigos I. et al. "The San Venero Roselli pharyngoplasty: an electromyographic study of the palatopharyngeus muscle". In: *The Cleft palate journal* 25.4 (1988), pp. 385–388.
- [127] Björn Schönmeier et al. "A review of the tensor veli palatine function and its relevance to palatoplasty". In: *Journal of Plastic Surgery and Hand Surgery* (2014). DOI: [10.3109/2000656X.2013.793603](https://doi.org/10.3109/2000656X.2013.793603).
- [128] Takashi Tachimura et al. "Change in Palatoglossus Muscle Activity in Relation to Swallowing Volume During the Transition from the Oral Phase to the Pharyngeal Phase". In: *Dysphagia* (2005). DOI: [10.1007/s00455-004-0022-5](https://doi.org/10.1007/s00455-004-0022-5).
- [129] D. J. Tangel et al. "Respiratory-related control of palatoglossus and levator palatini muscle activity". In: *Journal of Applied Physiology* (1995). DOI: [10.1152/jappl.1995.78.2.680](https://doi.org/10.1152/jappl.1995.78.2.680).
- [130] Sandra L. Hamlet et al. "Velar activity and timing of eustachian tube function in swallowing". In: *Dysphagia* (1992). DOI: [10.1007/BF02493474](https://doi.org/10.1007/BF02493474).
- [131] I. Honjo et al. "Role of the Tensor Veli Palatini Muscle in Movement of the Soft Palate". In: *Acta Oto-Laryngologica* (1979). DOI: [10.3109/00016487909137152](https://doi.org/10.3109/00016487909137152).
- [132] Bell-Berti Fredericka. "An Electromyographic Study of Velopharyngeal Function in Speech". In: *Journal of Speech and Hearing Research* (1976). DOI: [10.1044/jshr.1902.225](https://doi.org/10.1044/jshr.1902.225).
- [133] David P. Kuehn et al. "Relationships Between Muscle Activity and Velar Position". In: *The Cleft Palate Journal* 19.1 (1982), pp. 25–35.
- [134] S. H. Launois et al. "Relationship between velopharyngeal dimensions and palatal EMG during progressive hypercapnia". In: *Journal of Applied Physiology* (1996). DOI: [10.1152/jappl.1996.80.2.478](https://doi.org/10.1152/jappl.1996.80.2.478).
- [135] R. J. Shprintzen et al. "A three dimensional cinefluoroscopic analysis of velopharyngeal closure during speech and nonspeech activities in normals". In: *The Cleft Palate Journal* 11 (1974), pp. 412–428.
- [136] Alison Perry et al. "Elevation of the soft palate in speech and swallowing in normal female participants and females with motor neuron disease: an innovative procedure for measuring palatal elevation". In: *International Journal of Language & Communication Disorders* (2002). DOI: [10.1080/13682820110116857](https://doi.org/10.1080/13682820110116857).
- [137] Kuehn David P. et al. "Levator Veli Palatini Muscle Activity in Relation to Intraoral Air Pressure Variation". In: *Journal of Speech, Language, and Hearing Research* (1994). DOI: [10.1044/jshr.3706.1260](https://doi.org/10.1044/jshr.3706.1260).
- [138] Kanji Nohara et al. "Power Spectra Analysis of Levator Veli Palatini Muscle Electromyogram During Velopharyngeal Closure for Swallowing, Speech, and Blowing". In: *Dysphagia* (2007). DOI: [10.1007/s00455-006-9066-z](https://doi.org/10.1007/s00455-006-9066-z).
- [139] Cuneyt M. Alper et al. "Relationship Between the Electromyographic Activity of the Paratubal Muscles and Eustachian Tube Opening Assessed by Sonotubometry and Videendoscopy". In: *Archives of Otolaryngology-Head & Neck Surgery* (2012). DOI: [10.1001/archoto.2012.1293](https://doi.org/10.1001/archoto.2012.1293).
- [140] K. Okuno et al. "Influences of swallowing volume and viscosity on regulation of levator veli palatini muscle activity during swallowing". In: *Journal of Oral Rehabilitation* (2013). DOI: [10.1111/joor.12071](https://doi.org/10.1111/joor.12071).
- [141] Takashi Tachimura et al. "Change in Levator Veli Palatini Muscle Activity in Relation to Swallowing Volume During the Transition from the Oral Phase to Pharyngeal Phase". In: *Dysphagia* (2006). DOI: [10.1007/s00455-005-9005-4](https://doi.org/10.1007/s00455-005-9005-4).
- [142] William M. Kier et al. "Tongues, tentacles and trunks: the biomechanics of movement in muscular-hydrostats". In: *Zoological Journal of the Linnean Society* (1985). DOI: [10.1111/j.1096-3642.1985.tb01178.x](https://doi.org/10.1111/j.1096-3642.1985.tb01178.x).
- [143] Ira Sanders et al. "A Three-Dimensional Atlas of Human Tongue Muscles". In: *The Anatomical Record* (2013). DOI: [10.1002/ar.22711](https://doi.org/10.1002/ar.22711).
- [144] Samuel M. Felton et al. "Associating the mesoscale fiber organization of the tongue with local strain rate during swallowing". In: *Journal of Biomechanics* (2008). DOI: [10.1016/j.jbiomech.2008.01.030](https://doi.org/10.1016/j.jbiomech.2008.01.030).
- [145] Terry A. Gaige et al. "Three dimensional myoarchitecture of the human tongue determined in vivo by diffusion tensor imaging with tractography". In: *Journal of Magnetic Resonance Imaging* (2007). DOI: [10.1002/jmri.21022](https://doi.org/10.1002/jmri.21022).
- [146] Shuo Zhang et al. "Real-time magnetic resonance imaging of normal swallowing". In: *Journal of Magnetic Resonance Imaging* (2012). DOI: [10.1002/jmri.23591](https://doi.org/10.1002/jmri.23591).
- [147] Maureen Stone. "A three-dimensional model of tongue movement based on ultrasound and x-ray microbeam data". In: *The Journal of the Acoustical Society of America* (1990). DOI: [10.1121/1.399188](https://doi.org/10.1121/1.399188).
- [148] Vitaly J. Napadow et al. "Biomechanical basis for lingual muscular deformation during swallowing". In: *American Journal of Physiology-Gastrointestinal and Liver Physiology* (1999). DOI: [10.1152/ajpgi.1999.277.3.G695](https://doi.org/10.1152/ajpgi.1999.277.3.G695).
- [149] Vitaly J. Napadow et al. "Intramural mechanics of the human tongue in association with physiological deformations". In: *Journal of Biomechanics* (1999). DOI: [10.1016/S0021-9290\(98\)00109-2](https://doi.org/10.1016/S0021-9290(98)00109-2).
- [150] Richard J. Gilbert et al. "Anatomical basis of lingual hydrostatic deformation". In: *Journal of Experimental Biology* (2007). DOI: [10.1242/jeb.007096](https://doi.org/10.1242/jeb.007096).
- [151] Samuel M Felton et al. "Mechanical basis for lingual deformation during the propulsive phase of swallowing as determined by phase-contrast magnetic resonance imaging". In: *J Appl Physiol* (2007). DOI: [10.1152/jappphysiol.01070.2006](https://doi.org/10.1152/jappphysiol.01070.2006).
- [152] Vitaly J. Napadow et al. "A Biomechanical Model of Sagittal Tongue Bending". In: *Journal of Biomechanical Engineering* (2002). DOI: [10.1115/1.1503794](https://doi.org/10.1115/1.1503794).
- [153] Stéphanie Isabelle Buchaillard et al. "To what extent does Tagged-MRI technique allow to infer tongue muscles' activation pattern? A modelling study". In: *Interspeech 2008 - 9th Annual Conference of the International Speech Communication Association*. ISCA, 2008, pp. 2839–2842.
- [154] Yikun Wang et al. "Identification of Tongue Muscle Fibre Group Contraction from MR Images". In: *Computational Biomechanics for Medicine*. 2013. DOI: [10.1007/978-1-4614-6351-1_16](https://doi.org/10.1007/978-1-4614-6351-1_16).
- [155] Courtney P. Orsbon et al. "XROMM and diceCT reveal a hydraulic mechanism of tongue base retraction in swallowing". In: *Scientific Reports* (2020). DOI: [10.1038/s41598-020-64935-z](https://doi.org/10.1038/s41598-020-64935-z).
- [156] Robert B. Gassert et al. "Evaluating muscles underlying tongue base retraction in deglutition using muscular functional magnetic resonance imaging (mfMRI)". In: *Magnetic Resonance Imaging* (2016). DOI: [10.1016/j.mri.2015.10.029](https://doi.org/10.1016/j.mri.2015.10.029).
- [157] A. J. Thexton et al. "Transition from suckling to drinking at weaning: A kinematic and electromyographic study in miniature pigs". In: *Journal of Experimental Zoology* (1998). DOI: [10.1002/\(SICI\)1097-010X\(19980401\)280:5<327::AID-JEZ2>3.0.CO;2-Q](https://doi.org/10.1002/(SICI)1097-010X(19980401)280:5<327::AID-JEZ2>3.0.CO;2-Q).
- [158] Peter R. Eastwood et al. "Heterogeneous activity of the human genioglossus muscle assessed by multiple bipolar fine-wire electrodes". In: *Journal of Applied Physiology* (2003). DOI: [10.1152/jappphysiol.01017.2002](https://doi.org/10.1152/jappphysiol.01017.2002).

- [159] Tetsu Tsukada et al. "Effects of food texture and head posture on oropharyngeal swallowing". In: *Journal of Applied Physiology* (2009). DOI: [10.1152/japapophysiol.91295.2008](https://doi.org/10.1152/japapophysiol.91295.2008).
- [160] Y. Ishiwata et al. "Human jaw-tongue reflex as revealed by intraoral surface recording". In: *Journal of Oral Rehabilitation* (1997). DOI: [10.1111/j.1365-2842.1997.tb00286.x](https://doi.org/10.1111/j.1365-2842.1997.tb00286.x).
- [161] A.A. Lowe et al. "Regulation of genioglossus and masseter muscle activity in man". In: *Archives of Oral Biology* (1977). DOI: [10.1016/0003-9969\(77\)90069-3](https://doi.org/10.1016/0003-9969(77)90069-3).
- [162] Jennifer M Cori et al. "Sleeping tongue: current perspectives of genioglossus control in healthy individuals and patients with obstructive sleep apnea". In: *Nature and Science of Sleep* (2018). DOI: [10.2147/NSS.S143296](https://doi.org/10.2147/NSS.S143296).
- [163] Wataru Ofusa et al. "Use of barometric pressure and electromyography measurement techniques to elucidate the mechanisms by which bolus passes from the oral cavity to the oropharynx during swallowing". In: *Physiology & Behavior* (2020). DOI: [10.1016/j.physbeh.2020.113115](https://doi.org/10.1016/j.physbeh.2020.113115).
- [164] Jennifer R. Vranish et al. "A comprehensive assessment of genioglossus electromyographic activity in healthy adults". In: *Journal of Neurophysiology* (2015). DOI: [10.1152/jn.00975.2014](https://doi.org/10.1152/jn.00975.2014).
- [165] S. Takahashi et al. "Breathing modes, body positions, and suprahyoid muscle activity". In: *Journal of Orthodontics* (2002). DOI: [10.1093/ortho/29.4.307](https://doi.org/10.1093/ortho/29.4.307).
- [166] Lora J. Pittman et al. "Genioglossus and Intrinsic Electromyographic Activities in Impeded and Unimpeded Protrusion Tasks". In: *Journal of Neurophysiology* (2009). DOI: [10.1152/jn.91065.2008](https://doi.org/10.1152/jn.91065.2008).
- [167] Jeffrey B. Palmer et al. "Coordination of mastication and swallowing". In: *Dysphagia* (1992). DOI: [10.1007/BF02493469](https://doi.org/10.1007/BF02493469).
- [168] Emilien Lemaire et al. "Risk Factors for Pharyngocutaneous Fistula After Total Pharyngolaryngectomy". In: *Ear, Nose & Throat Journal* (2021). DOI: [10.1177/0145561319901035](https://doi.org/10.1177/0145561319901035).
- [169] Arun Balaji et al. "The results of sequential swallowing assessments after total laryngectomy for laryngeal and hypopharyngeal malignancies". In: *European Archives of Oto-Rhino-Laryngology* (2020). DOI: [10.1007/s00405-020-06105-5](https://doi.org/10.1007/s00405-020-06105-5).
- [170] Beatriz Arenaz Búa et al. "Voice and swallowing after total laryngectomy". In: *Acta Oto-Laryngologica* (2018). DOI: [10.1080/00016489.2017.1384056](https://doi.org/10.1080/00016489.2017.1384056).
- [171] Margaret Coffey et al. "Swallowing after laryngectomy". In: *Current Opinion in Otolaryngology & Head and Neck Surgery* (2015). DOI: [10.1097/MOO.000000000000162](https://doi.org/10.1097/MOO.000000000000162).
- [172] Julia Maclean et al. "Post-Laryngectomy: It's Hard to Swallow". In: *Dysphagia* (2009). DOI: [10.1007/s00455-008-9189-5](https://doi.org/10.1007/s00455-008-9189-5).
- [173] Roberto Oliveira Dantas et al. "Proximal Esophageal Contractions in Laryngectomized Patients". In: *Dysphagia* (2005). DOI: [10.1007/s00455-004-0027-0](https://doi.org/10.1007/s00455-004-0027-0).
- [174] Dennis M. Balfe. "Dysphagia after laryngeal surgery: Radiologic assessment". In: *Dysphagia* (1990). DOI: [10.1007/BF02407390](https://doi.org/10.1007/BF02407390).
- [175] Fred M. S. McConnel et al. "Examination of swallowing after total laryngectomy using manofluorography". In: *Head & Neck Surgery* (1986). DOI: [10.1002/hed.2890090103](https://doi.org/10.1002/hed.2890090103).
- [176] Richard W. Welch et al. "Manometry of the Normal Upper Esophageal Sphincter and its Alterations in Laryngectomy". In: *The Journal of Clinical Investigation* (1979). DOI: [10.1172/JCI109372](https://doi.org/10.1172/JCI109372).
- [177] Julia Maclean et al. "Impact of a Laryngectomy and Surgical Closure Technique on Swallow Biomechanics and Dysphagia Severity". In: *Otolaryngology-Head and Neck Surgery* (2011). DOI: [10.1177/0194599810390906](https://doi.org/10.1177/0194599810390906).
- [178] Teng Zhang et al. "Biomechanics of Pharyngeal Deglutitive Function following Total Laryngectomy". In: *Otolaryngology-Head and Neck Surgery* (2016). DOI: [10.1177/0194599816639249](https://doi.org/10.1177/0194599816639249).
- [179] Dylan Lippert et al. "Preliminary Evaluation of Functional Swallow After Total Laryngectomy Using High-Resolution Manometry". In: *Annals of Otolaryngology, Rhinology & Laryngology* (2016). DOI: [10.1177/0003489416629978](https://doi.org/10.1177/0003489416629978).
- [180] Margaret M. Coffey et al. "An Investigation of the Post-laryngectomy Swallow Using Videofluoroscopy and Fiberoptic Endoscopic Evaluation of Swallowing (FEES)". In: *Dysphagia* (2018). DOI: [10.1007/s00455-017-9862-7](https://doi.org/10.1007/s00455-017-9862-7).
- [181] Sandra L. Hamlet et al. "Sounds of swallowing following total laryngectomy". In: *Dysphagia* (1992). DOI: [10.1007/BF02493450](https://doi.org/10.1007/BF02493450).
- [182] Sylvain Morinière et al. "Pharyngeal Swallowing Sound Profile Assessed after Partial and Total Laryngectomy". In: *Dysphagia* (2011). DOI: [10.1007/s00455-010-9322-0](https://doi.org/10.1007/s00455-010-9322-0).
- [183] Catriona M. Steele. "The Blind Scientists and the Elephant of Swallowing: A Review of Instrumental Perspectives on Swallowing Physiology". In: *Journal of Texture Studies* (2015). DOI: [10.1111/jtxs.12101](https://doi.org/10.1111/jtxs.12101).
- [184] N. A. Selamat et al. "Automatic Food Intake Monitoring Based on Chewing Activity: A Survey". In: *IEEE Access* (2020). DOI: [10.1109/ACCESS.2020.2978260](https://doi.org/10.1109/ACCESS.2020.2978260).
- [185] Enrique Moguel et al. "Systematic Literature Review of Food-Intake Monitoring in an Aging Population". In: *Sensors* (2019). DOI: [10.3390/s19153265](https://doi.org/10.3390/s19153265).
- [186] Tri Vu et al. "Wearable Food Intake Monitoring Technologies: A Comprehensive Review". In: *Computers* (2017). DOI: [10.3390/computers6010004](https://doi.org/10.3390/computers6010004).
- [187] Vivian Brian Lobo et al. "A review of devices using modern dietary assessment methods for reducing obesity". In: *2017 International Conference on Computing, Communication and Automation (ICCCA)*. 2017. DOI: [10.1109/CCAA.2017.8229804](https://doi.org/10.1109/CCAA.2017.8229804).
- [188] Rubana H. Chowdhury et al. "Surface Electromyography Signal Processing and Classification Techniques". In: *Sensors* (2013). DOI: [10.3390/s130912431](https://doi.org/10.3390/s130912431).
- [189] Carlo De Luca. "Electromyography". In: *Encyclopedia of Medical Devices and Instrumentation*. 2006. DOI: [10.1002/0471732877.emd097](https://doi.org/10.1002/0471732877.emd097).
- [190] Hermie J Hermens et al. "Development of recommendations for SEMG sensors and sensor placement procedures". In: *Journal of Electromyography and Kinesiology* (2000). DOI: [10.1016/S1050-6411\(00\)00027-4](https://doi.org/10.1016/S1050-6411(00)00027-4).
- [191] Carlo J. De Luca. "The Use of Surface Electromyography in Biomechanics". In: *Journal of Applied Biomechanics* (1997). DOI: [10.1123/jab.13.2.135](https://doi.org/10.1123/jab.13.2.135).
- [192] Gabriela Constantinescu et al. "Evaluation of an Automated Swallow-Detection Algorithm Using Visual Biofeedback in Healthy Adults and Head and Neck Cancer Survivors". In: *Dysphagia* (2018). DOI: [10.1007/s00455-017-9859-2](https://doi.org/10.1007/s00455-017-9859-2).
- [193] Michael A. Crary et al. "Identification of Swallowing Events from sEMG Signals Obtained from Healthy Adults". In: *Dysphagia* (2007). DOI: [10.1007/s00455-006-9059-y](https://doi.org/10.1007/s00455-006-9059-y).
- [194] Sebastian Roldan-Vasco et al. "Automatic detection of oral and pharyngeal phases in swallowing using classification algorithms and multichannel EMG". In: *Journal of Electromyography and Kinesiology* (2018). DOI: [10.1016/j.jelekin.2018.10.004](https://doi.org/10.1016/j.jelekin.2018.10.004).
- [195] Sebastian Roldan-Vasco et al. "Continuous Wavelet Transform for Muscle Activity Detection in Surface EMG Signals During Swallowing". In: *Applied Computer Sciences in Engineering*. 2018. DOI: [10.1007/978-3-030-00353-1_22](https://doi.org/10.1007/978-3-030-00353-1_22).
- [196] Sebastian Restrepo-Agudelo et al. "Improving surface EMG burst detection in infrahyoid muscles during swallowing using digital filters and discrete wavelet analysis". In: *Journal of Electromyography and Kinesiology* (2017). DOI: [10.1016/j.jelekin.2017.05.001](https://doi.org/10.1016/j.jelekin.2017.05.001).
- [197] Sohail Afkari. "Measuring Frequency of Spontaneous Swallowing". In: *Australasian Physical & Engineering Sciences in Medicine* 30.4 (2007).
- [198] M. Sasaki et al. "Real-time estimation of tongue movement based on suprahyoid muscle activity". In: *2013 35th Annual International Conference of the IEEE Engineering in Medicine and Biology Society (EMBC)*. 2013. DOI: [10.1109/EMBC.2013.6610573](https://doi.org/10.1109/EMBC.2013.6610573).
- [199] Makoto Sasaki et al. "Estimation of tongue movement based on suprahyoid muscle activity". In: *2011 International Symposium on Micro-NanoMechatronics and Human Science*. 2011. DOI: [10.1109/MHS.2011.6102222](https://doi.org/10.1109/MHS.2011.6102222).

- [200] O. Amft et al. "Methods for Detection and Classification of Normal Swallowing from Muscle Activation and Sound". In: *2006 Pervasive Health Conference and Workshops*. 2006. DOI: [10.1109/PCTHEALTH.2006.361624](https://doi.org/10.1109/PCTHEALTH.2006.361624).
- [201] N. P. Reddy et al. "Noninvasive acceleration measurements to characterize the pharyngeal phase of swallowing". In: *Journal of Biomedical Engineering* (1991). DOI: [10.1016/0141-5425\(91\)90018-3](https://doi.org/10.1016/0141-5425(91)90018-3).
- [202] Sandra L. Hamlet et al. "Interpreting the Sounds of Swallowing: Fluid Flow through the Cricopharynx". In: *Annals of Otolaryngology, Rhinology & Laryngology* (1990). DOI: [10.1177/000348949009900916](https://doi.org/10.1177/000348949009900916).
- [203] Robert C. Mackowiak et al. "Acoustic Profile of Deglutition". In: *Proceedings of the Society for Experimental Biology and Medicine* (1967). DOI: [10.3181/00379727-125-32300](https://doi.org/10.3181/00379727-125-32300).
- [204] Sandra Hamlet et al. "Stethoscope acoustics and cervical auscultation of swallowing". In: *Dysphagia* (1994). DOI: [10.1007/BF00262761](https://doi.org/10.1007/BF00262761).
- [205] Joshua M. Dudik et al. "Dysphagia Screening: Contributions of Cervical Auscultation Signals and Modern Signal-Processing Techniques". In: *IEEE Transactions on Human-Machine Systems* (2015). DOI: [10.1109/THMS.2015.2408615](https://doi.org/10.1109/THMS.2015.2408615).
- [206] Koji Takahashi et al. "Methodology for detecting swallowing sounds". In: *Dysphagia* (1994). DOI: [10.1007/BF00262760](https://doi.org/10.1007/BF00262760).
- [207] Julie A.Y. Cichero et al. "Detection of Swallowing Sounds: Methodology Revisited". In: *Dysphagia* (2002). DOI: [10.1007/s00455-001-0100-x](https://doi.org/10.1007/s00455-001-0100-x).
- [208] J. Lee et al. "Time and time-frequency characterization of dual-axis swallowing accelerometry signals". In: *Physiological Measurement* (2008). DOI: [10.1088/0967-3334/29/9/008](https://doi.org/10.1088/0967-3334/29/9/008).
- [209] Joshua M. Dudik et al. "A comparative analysis of swallowing accelerometry and sounds during saliva swallows". In: *BioMedical Engineering OnLine* (2015). DOI: [10.1186/1475-925X-14-3](https://doi.org/10.1186/1475-925X-14-3).
- [210] Q. Pan et al. "Validation of the optimal site in the neck region for detecting swallowing sounds". In: *Journal of Oral Rehabilitation* (2016). DOI: [10.1111/joor.12440](https://doi.org/10.1111/joor.12440).
- [211] Adrienne L. Perlman et al. "Respiratory and Acoustic Signals Associated with Bolus Passage during Swallowing". In: *Dysphagia* (2000). DOI: [10.1007/s004550010006](https://doi.org/10.1007/s004550010006).
- [212] Matthew S. Klahn et al. "Temporal and Durational Patterns Associating Respiration and Swallowing". In: *Dysphagia* (1999). DOI: [10.1007/PL00009594](https://doi.org/10.1007/PL00009594).
- [213] W. G. Selley et al. "The synchronization of respiration and swallow sounds with videofluoroscopy during swallowing". In: *Dysphagia* (1994). DOI: [10.1007/BF00341260](https://doi.org/10.1007/BF00341260).
- [214] Julie A.Y. Cichero et al. "The Physiologic Cause of Swallowing Sounds: Answers from Heart Sounds and Vocal Tract Acoustics". In: *Dysphagia* (1998). DOI: [10.1007/PL00009548](https://doi.org/10.1007/PL00009548).
- [215] Adrienne L. Perlman et al. "Bolus Location Associated With Videofluoroscopic and Respirodeglutometric Events". In: *Journal of Speech, Language, and Hearing Research* (2005). DOI: [10.1044/1092-4388\(2005/003\)](https://doi.org/10.1044/1092-4388(2005/003)).
- [216] Sylvain Morinière et al. "Sound Component Duration of Healthy Human Pharyngoesophageal Swallowing: A Gender Comparison Study". In: *Dysphagia* (2006). DOI: [10.1007/s00455-006-9023-x](https://doi.org/10.1007/s00455-006-9023-x).
- [217] Scott R. Youmans et al. "An Acoustic Profile of Normal Swallowing". In: *Dysphagia* (2005). DOI: [10.1007/s00455-005-0013-1](https://doi.org/10.1007/s00455-005-0013-1).
- [218] Tsuyoshi Honda et al. "Characterization of Swallowing Sound: Preliminary Investigation of Normal Subjects". In: *PLOS ONE* (2016). DOI: [10.1371/journal.pone.0168187](https://doi.org/10.1371/journal.pone.0168187).
- [219] D. C. B. Zoratto et al. "Hyolaryngeal excursion as the physiological source of swallowing accelerometry signals". In: *Physiological Measurement* (2010). DOI: [10.1088/0967-3334/31/6/008](https://doi.org/10.1088/0967-3334/31/6/008).
- [220] Sylvain Morinière et al. "Origin of the Sound Components During Pharyngeal Swallowing in Normal Subjects". In: *Dysphagia* (2008). DOI: [10.1007/s00455-007-9134-z](https://doi.org/10.1007/s00455-007-9134-z).
- [221] James L. Coyle et al. "High-Resolution Cervical Auscultation and Data Science: New Tools to Address an Old Problem". In: *American Journal of Speech-Language Pathology* (2020). DOI: [10.1044/2020_AJSLP-19-00155](https://doi.org/10.1044/2020_AJSLP-19-00155).
- [222] Yassin Khalifa et al. "Upper Esophageal Sphincter Opening Segmentation With Convolutional Recurrent Neural Networks in High Resolution Cervical Auscultation". In: *IEEE Journal of Biomedical and Health Informatics* (2021). DOI: [10.1109/JBHI.2020.3000057](https://doi.org/10.1109/JBHI.2020.3000057).
- [223] Aliaa Sabry et al. "Automatic Estimation of Laryngeal Vestibule Closure Duration Using High-Resolution Cervical Auscultation Signals". In: *Perspectives of the ASHA Special Interest Groups* (2020). DOI: [10.1044/2020_PERSP-20-00073](https://doi.org/10.1044/2020_PERSP-20-00073).
- [224] Shitong Mao et al. "Neck sensor-supported hyoid bone movement tracking during swallowing". In: *Royal Society Open Science* (2020). DOI: [10.1098/rsos.181982](https://doi.org/10.1098/rsos.181982).
- [225] Atsuko Kurosu et al. "Detection of Swallow Kinematic Events From Acoustic High-Resolution Cervical Auscultation Signals in Patients With Stroke". In: *Archives of Physical Medicine and Rehabilitation* (2019). DOI: [10.1016/j.apmr.2018.05.038](https://doi.org/10.1016/j.apmr.2018.05.038).
- [226] Yassin Khalifa et al. "Non-invasive identification of swallows via deep learning in high resolution cervical auscultation recordings". In: *Scientific Reports* (2020). DOI: [10.1038/s41598-020-65492-1](https://doi.org/10.1038/s41598-020-65492-1).
- [227] Shigeyuki Miyagi et al. "Classifying Dysphagic Swallowing Sounds with Support Vector Machines". In: *Healthcare* (2020). DOI: [10.3390/healthcare8020103](https://doi.org/10.3390/healthcare8020103).
- [228] Laura F. Santoso et al. "Applying Machine Learning Algorithms for Automatic Detection of Swallowing from Sound". In: 2019. DOI: [10.1109/EMBC.2019.8857937](https://doi.org/10.1109/EMBC.2019.8857937).
- [229] Caroline Yu et al. "Silent Aspiration Detection in High Resolution Cervical Auscultations". In: *2019 IEEE EMBS International Conference on Biomedical Health Informatics (BHI)*. 2019. DOI: [10.1109/BHI.2019.8834576](https://doi.org/10.1109/BHI.2019.8834576).
- [230] Joshua M. Dudik et al. "Deep learning for classification of normal swallows in adults". In: *Neurocomputing* (2018). DOI: [10.1016/j.neucom.2017.12.059](https://doi.org/10.1016/j.neucom.2017.12.059).
- [231] Cara Donohue et al. "Establishing Reference Values for Temporal Kinematic Swallow Events Across the Lifespan in Healthy Community Dwelling Adults Using High-Resolution Cervical Auscultation". In: *Dysphagia* (2021). DOI: [10.1007/s00455-021-10317-0](https://doi.org/10.1007/s00455-021-10317-0).
- [232] Claudio Orizio et al. "Mechanomyography". In: *Wiley Encyclopedia of Biomedical Engineering*. 2006. DOI: [10.1002/9780471740360.ebs0731](https://doi.org/10.1002/9780471740360.ebs0731).
- [233] Claudio Orizio et al. "Surface mechanomyogram reflects muscle fibres twitches summation". In: *Journal of Biomechanics* (1996). DOI: [10.1016/0021-9290\(95\)00063-1](https://doi.org/10.1016/0021-9290(95)00063-1).
- [234] C. Orizio. "Muscle sound: bases for the introduction of a mechanomyographic signal in muscle studies". In: *Muscle sound: bases for the introduction of a mechanomyographic signal in muscle studies* 21.3 (1993), pp. 201-243.
- [235] I. Talib et al. "Choice of Mechanomyography Sensors for Diverse Types of Muscle Activities". In: *Journal of Telecommunication, Electronic and Computer Engineering (JTEC)* (2018).
- [236] M. Watakabe et al. "Reliability of the mechanomyogram detected with an accelerometer during voluntary contractions". In: *Medical and Biological Engineering and Computing* (2003). DOI: [10.1007/BF02344888](https://doi.org/10.1007/BF02344888).
- [237] A. O. Posatskiy et al. "The effects of motion artifact on mechanomyography: A comparative study of microphones and accelerometers". In: *Journal of Electromyography and Kinesiology* (2012). DOI: [10.1016/j.jelekin.2011.09.004](https://doi.org/10.1016/j.jelekin.2011.09.004).
- [238] Natasha Alves et al. "Mechanomyography as an access pathway: corporeal contraindications". In: *Disability and Rehabilitation: Assistive Technology* (2011). DOI: [10.3109/17483107.2010.541323](https://doi.org/10.3109/17483107.2010.541323).
- [239] Irsa Talib et al. "A review on crosstalk in myographic signals". In: *European Journal of Applied Physiology* (2019). DOI: [10.1007/s00421-018-3994-9](https://doi.org/10.1007/s00421-018-3994-9).
- [240] Emiliano Cè et al. "Novel insights into skeletal muscle function by mechanomyography: from the laboratory to the field". In: *Sport Sciences for Health* (2015). DOI: [10.1007/s11332-015-0219-z](https://doi.org/10.1007/s11332-015-0219-z).

- [241] Morufu Olusola Ibitoye et al. "Mechanomyography and muscle function assessment: A review of current state and prospects". In: *Clinical Biomechanics* (2014). DOI: [10.1016/j.clinbiomech.2014.04.003](https://doi.org/10.1016/j.clinbiomech.2014.04.003).
- [242] Md. Anamul Islam et al. "Mechanomyography Sensor Development, Related Signal Processing, and Applications: A Systematic Review". In: *IEEE Sensors Journal* (2013). DOI: [10.1109/JSEN.2013.2255982](https://doi.org/10.1109/JSEN.2013.2255982).
- [243] Joon Lee et al. "Effects of Age and Stimulus on Submental Mechanomyography Signals During Swallowing". In: *Dysphagia* (2009). DOI: [10.1007/s00455-008-9200-1](https://doi.org/10.1007/s00455-008-9200-1).
- [244] Joon Lee et al. "Swallow segmentation with artificial neural networks and multi-sensor fusion". In: *Medical Engineering & Physics* (2009). DOI: [10.1016/j.medengphy.2009.07.001](https://doi.org/10.1016/j.medengphy.2009.07.001).
- [245] Gabriela Constantinescu et al. "Electromyography and Mechanomyography Signals During Swallowing in Healthy Adults and Head and Neck Cancer Survivors". In: *Dysphagia* (2017). DOI: [10.1007/s00455-016-9742-6](https://doi.org/10.1007/s00455-016-9742-6).
- [246] A. Mialland et al. "Submental MechanoMyoGraphy (MMG) to Characterize the Swallowing Signature". In: *IRBM* (2021). DOI: [10.1016/j.irbm.2021.05.001](https://doi.org/10.1016/j.irbm.2021.05.001).
- [247] Eiichi Saitoh et al. "Chewing and Food Consistency: Effects on Bolus Transport and Swallow Initiation". In: *Dysphagia* (2007). DOI: [10.1007/s00455-006-9060-5](https://doi.org/10.1007/s00455-006-9060-5).
- [248] Harris Bonnie Martin et al. "Delayed Initiation of the Pharyngeal Swallow: Normal Variability in Adult Swallows". In: *Journal of Speech, Language, and Hearing Research* (2007). DOI: [10.1044/1092-4388\(2007/041\)](https://doi.org/10.1044/1092-4388(2007/041)).
- [249] Jennifer R. Stephen et al. "Bolus Location at the Initiation of the Pharyngeal Stage of Swallowing in Healthy Older Adults". In: *Dysphagia* (2005). DOI: [10.1007/s00455-005-0023-z](https://doi.org/10.1007/s00455-005-0023-z).
- [250] Kenji Takasaki et al. "Investigation of Pharyngeal Swallowing Function Using High-Resolution Manometry". In: *The Laryngoscope* (2008). DOI: [10.1097/MLG.0b013e31817dfd02](https://doi.org/10.1097/MLG.0b013e31817dfd02).
- [251] Kadir A. Yildiz et al. "Interfaces with the peripheral nervous system for the control of a neuroprosthetic limb: a review". In: *Journal of NeuroEngineering and Rehabilitation* (2020). DOI: [10.1186/s12984-020-00667-5](https://doi.org/10.1186/s12984-020-00667-5).
- [252] Philip P. Vu et al. "A regenerative peripheral nerve interface allows real-time control of an artificial hand in upper limb amputees". In: *Science Translational Medicine* (2020). DOI: [10.1126/scitranslmed.aay2857](https://doi.org/10.1126/scitranslmed.aay2857).
- [253] Sparsh Mittal. "A survey of techniques for improving energy efficiency in embedded computing systems". In: *International Journal of Computer Aided Engineering and Technology* (2014). DOI: [10.1504/IJCAET.2014.065419](https://doi.org/10.1504/IJCAET.2014.065419).
- [254] Murat Songu et al. "Physiology and Pathophysiology of Sneezing and Itching: Mechanisms of the Symptoms". In: *Nasal Physiology and Pathophysiology of Nasal Disorders*. 2013. DOI: [10.1007/978-3-642-37250-6_11](https://doi.org/10.1007/978-3-642-37250-6_11).
- [255] Ivan M. Lang et al. "Mechanisms of airway protection during retching, vomiting, and swallowing". In: *American Journal of Physiology-Gastrointestinal and Liver Physiology* (2002). DOI: [10.1152/ajpgi.00062.2002](https://doi.org/10.1152/ajpgi.00062.2002).
- [256] Lea Fath et al. "18 - Respiratory tissue replacement and regeneration: from larynx to bronchi". In: *Biomaterials for Organ and Tissue Regeneration*. 2020. DOI: [10.1016/B978-0-08-102906-0.00012-x](https://doi.org/10.1016/B978-0-08-102906-0.00012-x).
- [257] Massimo Merenda et al. "Edge Machine Learning for AI-Enabled IoT Devices: A Review". In: *Sensors* (2020). DOI: [10.3390/s20092533](https://doi.org/10.3390/s20092533).