



HAL
open science

Pharmacological coronary spasm provocative testing in clinical practice: A French Coronary Atheroma and Interventional Cardiology Group (GACI) position paper

Fabien Picard, Julien Adjedj, Jean-Philippe Collet, Eric van Belle, Jacques Monsegu, Bernard Karsenty, Patrick Dupouy, Marine Quillot, Guillaume Bonnet, Alexandre Gautier, et al.

► To cite this version:

Fabien Picard, Julien Adjedj, Jean-Philippe Collet, Eric van Belle, Jacques Monsegu, et al.. Pharmacological coronary spasm provocative testing in clinical practice: A French Coronary Atheroma and Interventional Cardiology Group (GACI) position paper. Archives of cardiovascular diseases, 2023, 116 (12), pp.590-596. 10.1016/j.acvd.2023.10.002 . hal-04380263

HAL Id: hal-04380263

<https://hal.science/hal-04380263>

Submitted on 8 Jan 2024

HAL is a multi-disciplinary open access archive for the deposit and dissemination of scientific research documents, whether they are published or not. The documents may come from teaching and research institutions in France or abroad, or from public or private research centers.

L'archive ouverte pluridisciplinaire **HAL**, est destinée au dépôt et à la diffusion de documents scientifiques de niveau recherche, publiés ou non, émanant des établissements d'enseignement et de recherche français ou étrangers, des laboratoires publics ou privés.

Pharmacological coronary spasm provocative testing in clinical practice: A French Coronary Atheroma and Interventional Cardiology Group (GACI) position paper★

Fabien Picard ^{a 1}, Julien Adjedj ^b, Jean-Philippe Collet ^c, Eric Van Belle ^d, Jacques Monsegu ^e, Bernard Karsenty ^f, Patrick Dupouy ^g, Marine Quillot ^h, Guillaume Bonnet ⁱ, Alexandre Gautier ^j, Guillaume Cayla ^k, Hakim Benamer ^{1 m n}

^aDepartment of Cardiology, Cochin Hospital, Hôpitaux Universitaire Paris Centre, AP-HP, 75014 Paris, France

^bDepartment of Cardiology, Institut Arnault-Tzanck, 06700 Saint-Laurent-du-Var, France

^cSorbonne Université, ACTION Study Group, INSERM UMRS 1166, Institut de Cardiologie, AP-HP, 75013 Paris, France

^dCHU Lille, Department of Cardiology, Department of Interventional Cardiology for Coronary, Valves and Structural Heart Diseases, Institut Coeur Poumon, INSERM U1011, Institut Pasteur de Lille, EGID, Université de Lille, 59000 Lille, France

^eDepartment of Interventional Cardiology, Institut Cardio-Vasculaire, Groupe Hospitalier Mutualiste Grenoble, 38000 Grenoble, France

^fHôpital privé Saint-Martin, ELSAN, 33600 Pessac, France

^gPôle Cardio-Vasculaire Interventionnel, Clinique les Fontaines, 77000 Melun, France

^hDepartment of Interventional Cardiology, Centre Hospitalier Henri-Duffaut, 84000 Avignon, France

ⁱHaut-Lévêque Cardiology Hospital, Bordeaux University, 33600 Pessac, France

^jDepartment of Cardiology, Hôpital Bichat, AP-HP, 75018 Paris, France

^kCardiology Department, Nîmes University Hospital, Montpellier University, 30900 Nîmes, France

¹ICPS Jacques Cartier, Ramsay Générale de Santé, 91300 Massy, France

^mICV-GVM La Roseraie, 93300 Aubervilliers, France

ⁿHôpital Foch, 92150 Suresnes, France

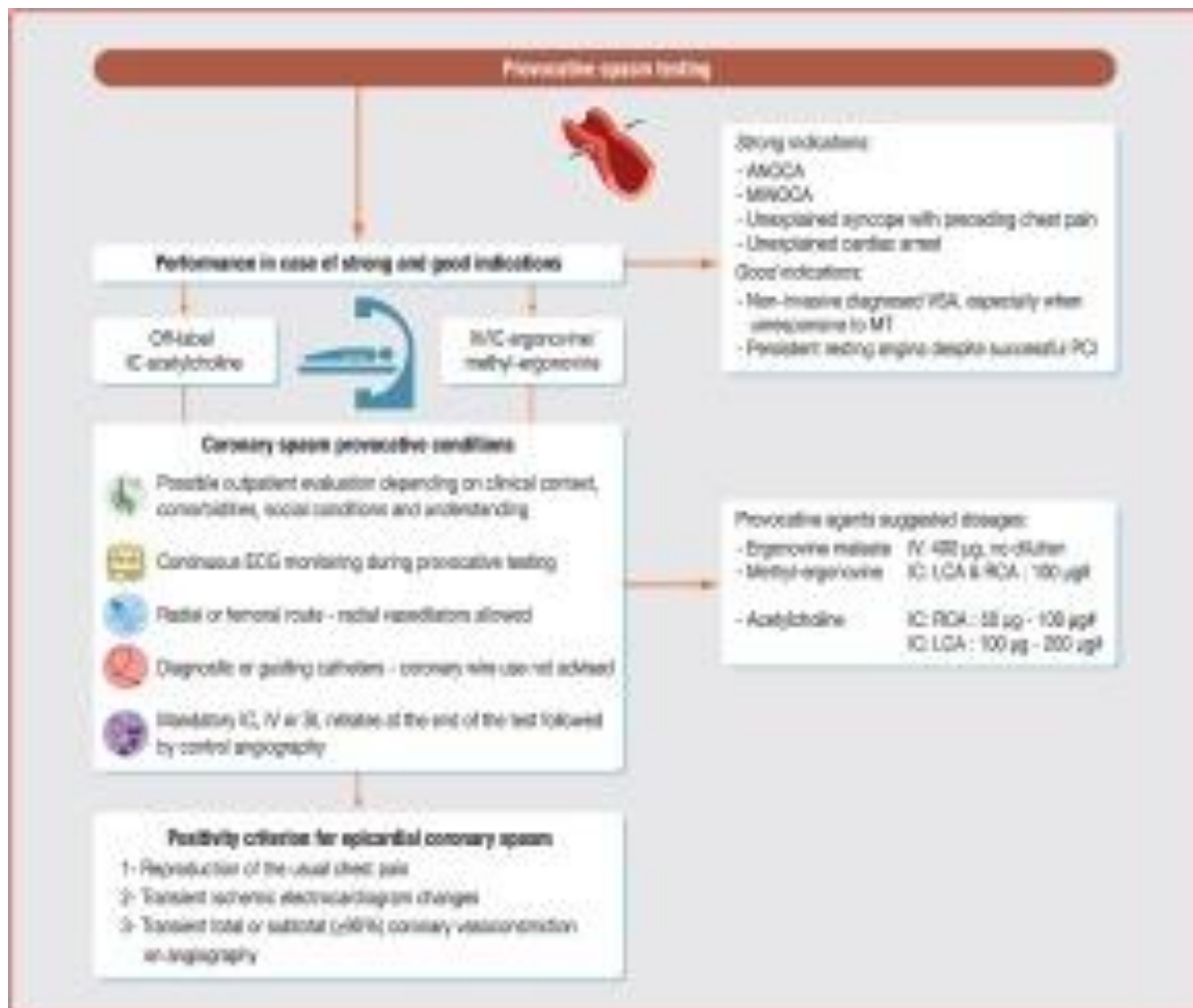
Highlights

- VSA is common and is involved in many clinical scenarios.
- These include chronic and acute coronary syndromes, SCD, arrhythmia and syncope.
- VSA is underdiagnosed and provocative tests are rarely performed.
- A lack of uniform protocol decreases the use and performance of provocative tests.
- This accounts for VSA underestimation.
- This GACI position paper gives clear indications for provocative tests.
- The paper also addresses testing conditions, drug protocols and positivity criteria.

Abstract

Vasospastic angina, also described as Prinzmetal angina, was first described as a variant form of angina at rest with transient ST-segment elevation; it is common and present in many clinical scenarios, including chronic and acute coronary syndromes, sudden cardiac death, arrhythmia and syncope. However, vasospastic angina remains underdiagnosed, and provocative tests are rarely performed. The gold-standard diagnostic approach uses invasive coronary angiography to induce coronary spasm using ergonovine, methylegonovine or acetylcholine as provocative stimuli. The lack of uniform protocol decreases the use and performance of these tests, accounting for vasospastic angina underestimation. This position paper from the French Coronary Atheroma and Interventional Cardiology Group (GACI) aims to review the indications for provocative tests, the testing conditions, drug protocols and positivity criteria.

Graphical abstract



Keywords

Coronary spasm
 Vasospastic angina
 Provocative testing
 Ergonovine
 Prinzmetal angina

1. Abbreviations

COVADIS Coronary Vasomotor Disorders International Study
 ESC European Society of Cardiology
 LCA left coronary artery
 RCA right coronary artery
 TIMI Thrombolysis in Myocardial Infarction
 VSA vasospastic angina

2. Introduction

More than 60 years ago, Prinzmetal first described a variant of angina occurring at rest associated with electrocardiogram modifications. This condition, called vasospastic angina (VSA), is a heterogeneous phenomenon that can occur in patients with or without coronary atherosclerosis, can be focal or diffuse and can affect epicardial or microvasculature coronary arteries. VSA is caused by an intrinsic anomaly of coronary vasomotricity, which may be responsible for resting chest pain with concomitant electrocardiogram changes, such as

transient ST-segment elevation; it can classically result in angina or myocardial infarction with no obstructive coronary arteries [1], [2], [3].

Many centres have been unwilling to perform routine provocative testing for multiple reasons, including longer procedural time, the lack of definitive provocative spasm protocol and reported deaths related to provocative testing [4]. Initially performed at the bedside, with intermittent electrocardiogram monitoring and administration of nitrates, catheterization laboratory-based provocative testing, in which short half-life provocative drugs are administered, has become the standard of care. Nevertheless, the drugs and protocols available for coronary spasm diagnosis are heterogenous [5], and VSA is still a frequently overlooked diagnosis. Timely diagnosis of VSA is mandatory to prevent further life-threatening events [6], [7].

This position paper from the French Coronary Atheroma and Interventional Cardiology Group (GACI) aims to review the indications for provocative tests, the testing conditions, drug protocols and positivity criteria.

3. Coronary vasospasm pathophysiology

Coronary spasm most often affects 50-year-old smokers, but its physiopathology is multifactorial, including extrinsic (smoking) and intrinsic (genetic) factors. Several studies have highlighted the role of coronary endothelial dysfunction, coronary smooth muscle hypercontractility with Rho-kinase as a key player and neurohormonal abnormalities as triggering factors [5]. The incidence of coronary spasm varies greatly depending on screening policies at each centre. Approximately 10% of patients presenting with symptoms at rest and with no evidence of obstructive coronary artery disease display evidence of coronary artery spasm when systematic screening is implemented [2], [8]. Identification of VSA is important, as it may lead to acute coronary syndromes, ventricular arrhythmias, conduction disorders and sudden death [9], [10]. Guidelines from Europe, the USA and Japan emphasize that coronary spasm provocative testing should be applied in routine practice in patients with angina or myocardial infarction with no obstructive coronary arteries [1], [2], [3].

4. Indications for provocative testing

Patients with VSA have a higher risk of major adverse cardiovascular events (MACE) compared with the general population. Identification of VSA is of utmost importance given that smoking cessation, calcium channel blockers and long-acting nitrates have been demonstrated to drastically reduce symptoms and the occurrence of subsequent cardiac events [11].

If a definitive diagnosis can be made in a typical case of spontaneous episodes of nitrate-responsive angina with either transient ischaemic electrocardiogram changes or coronary artery spasm, defined as transient total or subtotal coronary artery occlusion (> 90% vasoconstriction), this situation is deemed very rare, and provocative testing is necessary to rule in/out suspected VSA. In addition, provocative testing should be undertaken after cardiac life-threatening events without evident underlying cause (Table 1).

Table 1. Indications for provocative coronary artery spasm testing.

Strong indications	ANOCA, especially if: <ul style="list-style-type: none">– resting angina– nitrate responsive– important diurnal variation in symptoms and exercise tolerance (more pronounced at night and early morning)– MINOCA in the absence of a culprit lesion
---------------------------	---

	– unexplained syncope with preceding chest pain
	– unexplained cardiac arrest
Good indications	Non-invasive diagnosed VSA, especially when unresponsive to medical therapy
	Persistent resting angina despite successful percutaneous coronary revascularization
Controversial/contraindications	Acute phase of resuscitated cardiac arrest
	Acute phase of acute coronary syndrome
	Severe multivessel coronary artery disease or left main coronary artery stenosis
	Severe myocardial dysfunction, unless dysfunction might be a consequence of coronary spasm (controversial)
	No symptoms suggestive of VSA

ANOCA: angina with no obstructive coronary arteries; MINOCA: myocardial infarction with no obstructive coronary arteries; VSA: vasospastic angina.

Few contraindications exist, such as the acute phase of resuscitated cardiac arrest or acute coronary syndrome, because induction of coronary vasospasm could induce severe ventricular arrhythmia or provoke ischaemia, which can be life-threatening at the acute phase. For the same reasons and because the VSA diagnosis might not be retained, provocative tests should not be performed in case of severe multivessel coronary artery disease or left main coronary artery stenosis, as well as when the patient presents with severe myocardial dysfunction, unless this dysfunction might be a consequence of coronary spasm (controversial). Last, patients without symptoms suggestive of VSA should not undergo systematic provocative testing, as its performance and safety to diagnose asymptomatic patients has not been evaluated. In case of acute coronary syndrome or resuscitated cardiac arrest with no obstructive coronary artery disease or alternative cause, delayed provocative spasm testing should be performed after the decrease of cardiac troponin peak, although no specific data are available.

Specific triggers of coronary artery vasospasm should be known, such as illicit drug abuse (mainly cocaine and amphetamines), medications (including sumatriptan and derivatives, pseudoephedrine and leukotriene modifiers for asthma), systemic inflammatory conditions, physical and mental stress, cold pressor via sympathetic activation, hyperventilation syndrome, hormonal fluctuations (e.g. variations during menstrual cycle or menopause), alcohol withdrawal, Kounis syndrome (where an allergic or hypersensitivity reaction triggers a coronary artery spasm) and hypereosinophilia (Table 2).

Table 2. Specific triggers of coronary vasospasm.

Hyperventilation syndrome (alkalosis)

Valsalva manoeuvre

Physical and mental stress

Smoking

Alcohol consumption or withdrawal

Illicit drug abuse (cocaine, amphetamines)

Medications (triptans and derivatives, pseudoephedrine, leukotriene modifiers, sympathomimetic agents [adrenaline, noradrenaline], beta-blockers, parasympathomimetic agents [acetylcholine, pilocarpine], ergot alkaloid [ergonovine, ergotamine], 5-fluorouracil)

Sympathetic activation (cold pressor)

Kounis syndrome (allergic or hypersensitivity reaction)

Hypereosinophilia

5. Provocative testing methods

Although consensus papers on the diagnostic criteria for microvascular angina and VSA during provocative test have been published by the Coronary Vasomotor Disorders International Study (COVADIS) working group [12], consensus on a standardized provocative protocol remains to be established. Although a large variety of provocative test protocols exists, they are used routinely in only a few specialized centres [13]. This lack of consensus on a uniform functional testing protocol hampers widespread adoption in clinical practice. Provocative methods and agents are summarized in Table 3.

Table 3. Proposed provocative coronary artery spasm testing protocols.

Coronary spasm**provocative test conditions****Continuous electrocardiogram monitoring**

Radial or femoral route

Radial vasodilators allowed

Baseline angiogram without intracoronary nitrates

Diagnostic or guiding catheters; coronary wire use is not advised

Provocative testing using either acetylcholine, ergonovine or methylegonovine

Control angiography if chest pain with electrocardiogram modifications or 3–5 minutes after the last dose of provocative agent

Intracoronary, intravenous or sublingual nitrates are administered at the end of the test, followed by control angiography

Temporary right ventricle stimulation is not mandatory

Provocative agent**Proposed dosage****Proposed protocol**

Ergonovine maleate/methylegonovine

Intravenous:
400 µg (no dilution)

400 µg ergonovine/methylegonovine intravenous bolus administration followed by LCA and RCA angiography 3~5 minutes after completion of the injection^b

Intracoronary (LCA):
100 µg^a

100 µg of intracoronary ergonovine/methylegonovine over a period of 3 minutes, followed by LCA angiography 3~5 minutes after completion of the injection^b

Intracoronary

100 µg of intracoronary

Provocative agent	Proposed dosage	Proposed protocol
Acetylcholine	(RCA): 100 µg ^a	ergonovine/methylergonovine over a period of 3 minutes, followed by RCA angiography 3~5 minutes after completion of the injection ^b
	Intracoronary (RCA): 50– 100 µg ^a	50 µg of intracoronary acetylcholine over a minimal period of 20 seconds, followed by RCA angiography 3 minutes after completion of the injection ^b ; if no spasm occurs, then administer 100 µg of intracoronary acetylcholine over a minimal period of 20 seconds, followed by RCA angiography 3 minutes after completion of the injection ^b
	Intracoronary (LCA): 100– 200 µg ^a	100 µg of intracoronary acetylcholine over a minimal period of 20 seconds, followed by LCA angiography 3 minutes after completion of the injection ^b ; if no spasm occurs, then administer 200 µg of intracoronary acetylcholine over a minimal period of 20 seconds, followed by LCA angiography 3 minutes after completion of the injection ^b

LCA: left coronary artery; RCA: right coronary artery.

A Diluted in 20 mL of saline solution.

B In the event of an ischaemic change on the electrocardiogram or chest symptom, perform angiography at the time of its onset.

5.1. Provocative testing conditions

Electrocardiogram monitoring is mandatory. Radial or femoral routes can be used, and vasodilator administration is allowed to prevent radial spasm [14], [15]. After angiography of the left coronary artery (LCA) and right coronary artery (RCA) with either a diagnostic or guiding catheter without wires, acetylcholine, ergonovine or methylergonovine is given. The intracoronary route is used for acetylcholine, whereas the intracoronary or intravenous route can be used for ergonovine and methylergonovine (Table 3). Control angiography should be performed immediately when chest pain with ST-segment elevation or depression occurs or within 3–5 minutes after the last dose of provocative agent. Sublingual, intravenous or intracoronary nitrates should be then administered, irrespective of the presence of an induced spasm. A final angiogram of the LCA and RCA is mandatory. Ergonovine and acetylcholine provocation tests can be undertaken in an ambulatory setting [14], [16]. Right ventricle temporary pacing is not required.

5.2. Ergonovine and methylergonovine

Ergonovine and its analogue methylergonovine are synthetic ergot alkaloids, which act on smooth muscle, mainly by the activation of serotonergic receptors (5-HT_{2A}), to produce vasoconstriction [17], [18]. Adverse reactions to ergot alkaloids are diverse, and include coronary vasospasm, arrhythmia, nausea, allergic reaction and ergotism. Various testing protocols using intracoronary and intravenous administration of ergonovine and methylergonovine have been described.

For intravenous ergonovine/methylergonovine, we propose the use of the most commonly described protocol, consisting of a direct bolus injection of 400 µg of ergonovine/methylergonovine. For intracoronary ergonovine/methylergonovine, we propose the slow injection (over 3 minutes) of 100 µg sequentially into the LCA and RCA.

Although no randomized controlled studies have compared intravenous versus intracoronary testing, one small-scale observational retrospective study showed that the intracoronary route may lead to a higher rate of positive testing [19]. In addition, European Society of Cardiology (ESC) and Japanese Circulation Society guidelines recommend intracoronary over intravenous ergonovine testing for safety reasons (i.e. to avoid delayed coronary vasospasm) [2]. In case of a positive ergonovine/methylergonovine test, long-term oral calcium channel inhibitors should be given.

5.3. Acetylcholine

Acetylcholine is a parasympathetic nervous system transmitter that binds to both nicotinic and muscarinic receptors, playing a central role in vascular tone regulation. In the case of a healthy vascular system, a predominant role of the endothelium over smooth muscle cells is responsible for endothelial-dependent vasodilation, whereas, in the case of vascular dysfunction, the cell-mediated vasoconstriction of smooth muscle overcomes vasodilation [3]. Intracoronary administration of acetylcholine is the most common method for assessing vascular reactivity, although safety concerns persist, limiting its widespread use. Its use as provocative agent for coronary spasm is still off-label in several western countries, including France.

Acetylcholine has to be administered via the intracoronary route, as summarized in Table 3; this route is not specified in the drug instructions, leading to a discouraging situation for many catheterization laboratories.

For testing with acetylcholine we propose the following protocol: slowly (over > 20 seconds) administer 50 µg diluted in 20 mL of saline solution into the RCA, wait for 3 minutes and control the angiography; if no spasm occurs, then administer 100 µg diluted in 20 mL of saline solution into the RCA, wait for 3 minutes and control the angiography. Thereafter, administer 100 µg of acetylcholine diluted in 20 mL of saline solution into the LCA, wait for 3 minutes and control the angiography; if no spasm occurs, administer 200 µg of acetylcholine diluted in 20 mL of saline solution into the LCA, with a final control at 3 minutes. After performing the acetylcholine test, always administer intracoronary nitrates and perform a final angiogram. In case of a positive acetylcholine test, long-term oral calcium channel inhibitors should be given.

5.4. Provocative testing protocol choice

For France, as acetylcholine coronary use is still off-label, we recommend the use of intracoronary over intravenous methylergonovine in order to reduce the risk of delayed vasospasm. Nevertheless, intravenous methylergonovine according to local protocol, experience and follow-up can also be given, as no clear data exist on the increased risk and performance of intravenous over intracoronary administration.

In case of negative methylergonovine provocative testing and high suspicion of VSA, an off-label acetylcholine provocative test might be undertaken in order to increase provocative test performance.

6. Positivity criteria

The diagnosis of coronary artery spasm is made, according to the COVADIS [12] and ESC recommendations [3], if all of the following criteria are obtained in response to the provocative stimulus: reproduction of the usual chest pain; transient ischaemic electrocardiogram changes; and transient total or subtotal ($\geq 90\%$) coronary vasoconstriction on angiography.

The test result is considered equivocal if the provocative stimulus does not induce all three components (Fig. 1). Catheter-induced spasms, frequent on the proximal segment of the RCA, should not be classified as positive provocative tests. Focal spasm is defined as a focal transient vessel narrowing of $\geq 90\%$ compared with the proximal segment of one isolated coronary artery, whereas diffuse spasm is defined as a diffuse transient vessel narrowing of

≥ 90% compared with basal angiography, and which extends into at least two adjacent coronary segments in one of the three major coronary arteries and branches (Fig. 1).

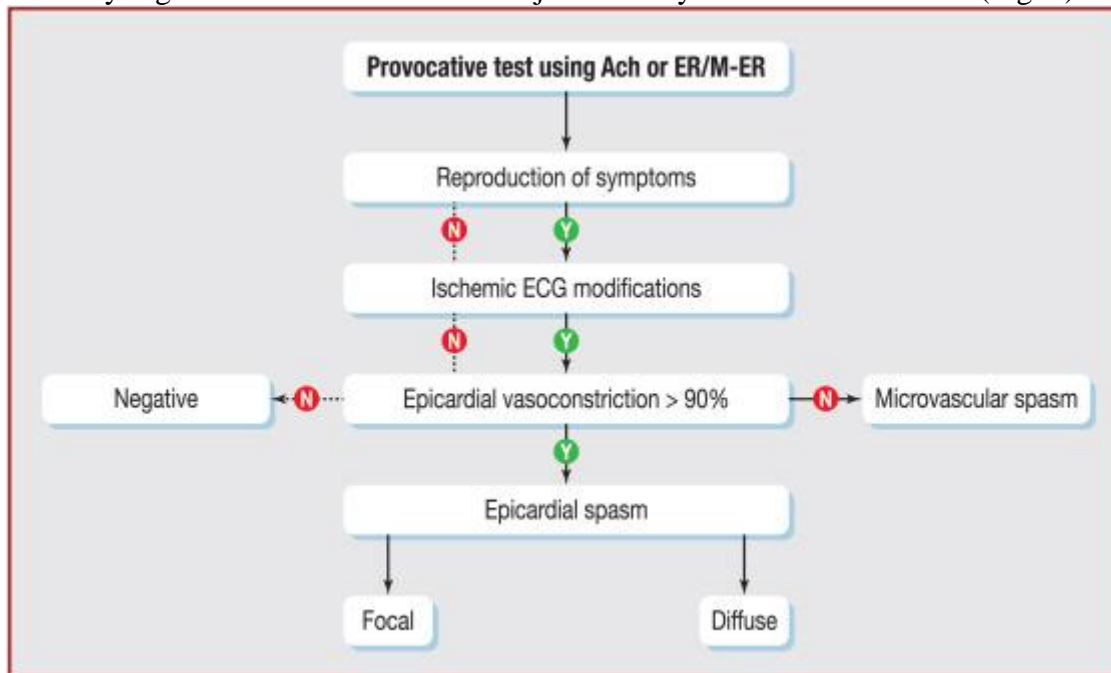


Fig. 1. Spasm provocative test diagnosis algorithm. If only two of the three components of diagnosis are provoked, the test is considered equivocal, except if microvascular spasm is diagnosed. ACh: acetylcholine; ECG: electrocardiogram; ER: ergonovine maleate; M-ER: methylergonovine.

7. Combined testing

Acetylcholine and ergonovine/methylergonovine interact with muscarinic cholinergic and serotonergic receptors, respectively, and may have different coronary responses. Some patients may be responsive to only acetylcholine or only ergonovine, inducing potential false negative responses [20]. Acetylcholine provokes spasm more distally and diffusely, whereas ergonovine provokes spasm more proximally and focally. Ergonovine testing after a negative acetylcholine test documented spasm in approximately 9% of cases. Another investigation with a limited sample size demonstrated the potential utility of adding acetylcholine to ergonovine in patients with a negative provocative test [21].

8. Provocative testing risks

Serious major complications, including acute myocardial infarction, sustained ventricular tachycardia or fibrillation and death have been described when non-invasive administration of provocative agents was performed. When provocative tests are performed during coronary angiography, reported major complication rates are low, ranging from 0.2% to 4.7% with intravenous ergonovine, 0.4% to 0.8% with intracoronary ergonovine and 0% to 4.9% with intracoronary acetylcholine, with a mean complication rate of 0.62% [22].

As serious major complications, such as death, were reported only with intravenous administration of ergonovine [4], whereas no deaths were reported with intracoronary administration of ergonovine, a selective intracoronary ergonovine provocative test is perceived as safer. Isogai et al. [23] reported in 21,512 participants that an acetylcholine provocative test was associated with a higher rate of serious cardiac complications (defined as the composite of cardiac complications requiring urgent procedures or death) than ergonovine (0.9% vs 0.4%; $P = 0.003$ after propensity score matching). Contemporary reports suggest that provocative testing is a safe procedure that should be performed in a catheterization laboratory with dedicated protocols and trained personnel.

9. Outpatient approach and postprocedural observation after provocative testing

In 1981, intravenous ergonovine provocative testing was reported in 61 ambulatory participants, 10% of whom had a positive test without reported complications [24]. The radial approach for intracoronary ergonovine testing was more recently reported in 174 patients, 45% of whom were ambulatory, with same-day discharge in 76 out of 78, without major complications [14]. An intracoronary acetylcholine provocative test was also performed in a cohort of 323 patients, 38% of whom were in an outpatient group [16]. The study protocol mandated observation for 4 hours without monitoring in a dedicated outpatient unit. Coronary angiography was performed mostly through the radial approach using a 4F sheath. There were two cases of cardiac complications in the hospitalization group and one in the outpatient group, which led to unexpected hospitalization. Although there is no clear consensus on such an approach, given the lack of robust data, outpatient management with a minimum of 4 hours of uneventful observation seems reasonable. Continuous monitoring after provocative testing is not mandatory, and an electrocardiogram should be performed before discharge.

10. Provocative test under medical therapy

Provocative tests can be repeated to assess the efficacy of preventive pharmacological therapy and adjust the subsequent treatment strategy. If chest pain continues while provocative testing is negative, the patient may be reassured. In contrast, if patients still exhibit vasospasticity, dose escalation and refinement of vasoactive drugs should be performed and adjusted according to testing, to alleviate symptoms and prevent future ischaemic events [5]; this is especially relevant after sudden cardiac death, to determine the need for an implantable cardioverter-defibrillator [7], [25]. Therefore, this strategy could help to identify high-risk individuals who may require closer monitoring, more aggressive treatment strategies or consideration for invasive interventions.

11. Microvascular spasm diagnosis

Abnormal vasomotion can also affect the coronary microvasculature, which cannot be directly visualized because of the limitation of the spatial resolution of coronary angiography. Diagnosis of microvascular spasm is therefore based on the reproduction of symptoms associated with electrocardiogram changes in the absence of epicardial spasm during a provocative test. Both acetylcholine and ergonovine/methylergonovine can be used, although acetylcholine is the drug most studied. The same protocols apply for microvascular and epicardial spasm detection.

Microvascular spasm may also lead to an increase in microvascular resistances, inducing decreased blood velocity, assessed invasively by thermodilution or the index of microvascular resistance (defined as the ratio of distal coronary pressure [P_d] and the thermodilution-derived mean transit time during maximal hyperaemia, measured with a pressure/temperature wire) [26]. This index is specific for the coronary microcirculation, with some degree of variability as a result of the manual injection of an intracoronary bolus of saline at room temperature [27]. The need for the administration of a hyperaemic agent concomitant with a spasm-provoking agent complicates the evaluation of this method.

More recently, the use of maximal absolute coronary flow (L/min) and minimal resistances (Woods units) has been introduced as a novel method to diagnose microvascular spasm without the need for a hyperaemic agent. This technique uses an infusion microcatheter (RayFlow; Hexacath, Rueil-Malmaison, France) placed in the proximal part of the vessel, with a pressure/temperature wire that is advanced distally. A saline solution at room temperature is infused at a fixed flow rate (called Q_i) through the catheter side holes, creating haemolysis and release of adenosine diphosphate, producing hyperaemia. The mixture between blood and saline reaches a steady state (called T) in a few seconds. Thereafter, the pressure/temperature wire is pulled back at the side-hole level to measure the temperature of saline at the exit of the infusion catheter (called T_i). Coronary flow (called Q) is simply

calculated as the ratio between T_i and T multiplied by Q_i and a constant of blood of 1.08. The pressure/temperature wire gives pressure and temperature simultaneously. As pressure equals the flow multiplied by the resistances, microvascular resistances can be calculated as the ratio between P_d and Q [26], [28] before and after the provocative test in case of high suspicion of microvascular spasm.

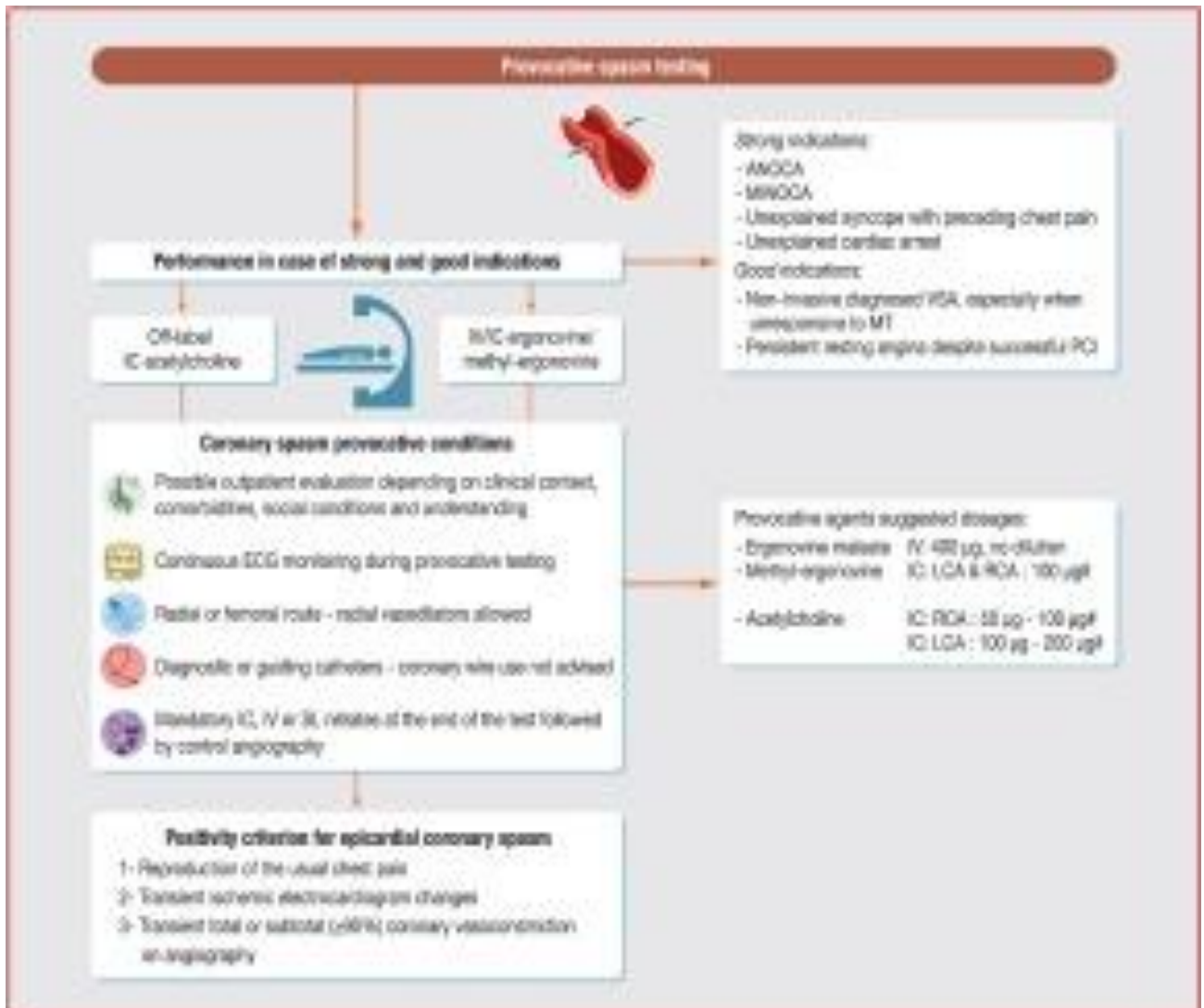Microvascular spasm can be assessed by other methods; it can cause angiographic slow-flow phenomenon associated with reduced Thrombolysis in Myocardial Infarction (TIMI) flow assessed by TIMI frame count [26], [29], [30]. Additionally, lactate concentration in the coronary sinus, myocardial lactate extraction ratio or desaturation of coronary sinus blood can be used to diagnose microvascular spasm in equivocal provocative tests, such as reproduction of symptoms without ischaemic electrocardiogram changes and vice versa [31]. However, this diagnostic method requires selective catheterization of the coronary sinus, which limits broad and routine utilization. In practice, lactate levels are sampled simultaneously in the LCA and the coronary sinus during spasm provocation testing, and the net production of lactate across the coronary circulation is then calculated as coronary sinus concentration minus LCA concentration divided by LCA concentration. A positive value favours pathological production or release, whereas a negative value favours physiological uptake of lactate in the coronary circulation. The diagnostic algorithm for microvascular coronary spasm is shown in Fig. 1, and VSA phenotypes are described in Table 4.

Table 4. Vasospastic angina phenotypes according to clinical, electrocardiographic and angiographic results.

Empty Cell	Reproducible symptoms	Ischaemic electrocardiogram changes	Coronary diameter reduction > 90%	Microvascular dysfunction
Epicardial spasm	+	+	+	–
Microvascular spasm	+	+	–	±
Negative spasm	–	–	–	±
Equivocal	±	±	–	±
Mixed angina	+	+	+	+

12. Conclusions

Spasm provocative testing remains underperformed, resulting in an underestimation of VSA. Simple and user-friendly acetylcholine and ergonovine/methylergonovine protocols with clear testing conditions and diagnostic criteria should increase spasm provocative testing in France, resulting in a higher proportion of symptomatic patients with an accurate diagnosis and appropriate treatment (Central illustration).



Central illustration. Spasm provocative testing in France. ANOCA: angina with no obstructive coronary arteries; ECG: electrocardiogram; IC: intracoronary; IV: intravenous; LCA: left coronary artery; MT: medical therapy; MINOCA: myocardial infarction with no obstructive coronary arteries; PCI: percutaneous coronary intervention; RCA: right coronary artery; SL: sublingual; VSA: vasospastic angina; †Diluted in 20 mL of saline solution.

References

1. E.A. Amsterdam, N.K. Wenger, R.G. Brindis, D.E. Casey Jr., T.G. Ganiats, D.R. Holmes Jr., *et al.*
2014 AHA/ACC guideline for the management of patients with non-ST-elevation acute coronary syndromes: executive summary: a report of the American College of Cardiology/American Heart Association Task Force on Practice Guidelines
Circulation, 130 (2014), pp. 2354-2394
2. JCS Joint Working Group
Guidelines for diagnosis and treatment of patients with vasospastic angina (Coronary Spastic Angina) (JCS 2013)
Circ J, 78 (2014), pp. 2779-2801
3. J. Knuuti, W. Wijns, A. Saraste, D. Capodanno, E. Barbato, C. Funck-Brentano, *et al.*

2019 ESC Guidelines for the diagnosis and management of chronic coronary syndromes

Eur Heart J, 41 (2020), pp. 407-477

CrossRefView in ScopusGoogle Scholar

4. A. Buxton, S. Goldberg, J.W. Hirshfeld, J. Wilson, T. Mann, D.O. Williams, *et al.*
Refractory ergonovine-induced coronary vasospasm: importance of intracoronary nitroglycerin
Am J Cardiol, 46 (1980), pp. 329-334
5. F. Picard, N. Sayah, V. Spagnoli, J. Adjedj, O. Varenne
Vasospastic angina: a literature review of current evidence
Arch Cardiovasc Dis, 112 (2019), pp. 44-55
6. G.A. Lanza, A. Sestito, G.A. Sgueglia, F. Infusino, M. Manolfi, F. Crea, *et al.*
Current clinical features, diagnostic assessment and prognostic determinants of patients with variant angina
Int J Cardiol, 118 (2007), pp. 41-47
7. C. Meune, L.M. Joly, J.D. Chiche, J. Charpentier, A. Leenhardt, A. Rozenberg, *et al.*
Diagnosis and management of out-of-hospital cardiac arrest secondary to coronary artery spasm
Resuscitation, 58 (2003), pp. 145-152
8. H. Aelion, F. Picard, A. Jegou, P. Allouch, O. Varenne
Abnormal epicardial coronary vasomotor reactivity is associated with altered outcomes
Arch Cardiovasc Dis, 116 (2023), pp. 33-40
9. B. Ibanez, S. James, S. Agewall, M.J. Antunes, C. Bucciarelli-Ducci, H. Bueno, *et al.*
2017 ESC Guidelines for the management of acute myocardial infarction in patients presenting with ST-segment elevation: The Task Force for the management of acute myocardial infarction in patients presenting with ST-segment elevation of the European Society of Cardiology (ESC)
Eur Heart J, 39 (2018), pp. 119-177
10. M. Rodriguez-Manero, T. Oloriz, J.B. le Polain de Waroux, H. Burri, B. Kreidieh, C. de Asmundis, *et al.*
Long-term prognosis of patients with life-threatening ventricular arrhythmias induced by coronary artery spasm
Europace, 20 (2018), pp. 851-858
11. S.E. Kim, S.H. Jo, S.H. Han, K.Y. Lee, S.H. Her, M.H. Lee, *et al.*
Comparison of calcium-channel blockers for long-term clinical outcomes in patients with vasospastic angina
Korean J Intern Med, 36 (2021), pp. 124-134
12. J.F. Beltrame, F. Crea, J.C. Kaski, H. Ogawa, P. Ong, U. Sechtem, *et al.*
International standardization of diagnostic criteria for vasospastic angina
Eur Heart J, 38 (2017), pp. 2565-2568

13. [13]
R.G.T. Feenstra, A. Seitz, C.K.M. Boerhout, L.H. Bukkems, V.E. Stegehuis, P.J.I. Teeuwisse, *et al.*
Principles and pitfalls in coronary vasomotor function testing
EuroIntervention, 17 (2022), pp. 1271-1280
14.
K.J. Lee, S.H. Lee, K.P. Hong, J.E. Park, J.D. Seo, H.C. Gwon
Feasibility and safety of the transradial approach for the intracoronary spasm provocation test
Catheter Cardiovasc Interv, 65 (2005), pp. 240-246
15.
S. Sueda, K. Fujimoto, Y. Sasaki, T. Sakaue, H. Habara, H. Kohno
Acetylcholine spasm provocation test by trans-radial artery and brachial vein approach
Catheter Cardiovasc Interv, 94 (2019), pp. 38-44
16.
Y. Saito, H. Kitahara, T. Shoji, S. Tokimasa, T. Nakayama, K. Sugimoto, *et al.*
Feasibility and safety of outpatient cardiac catheterization with intracoronary acetylcholine provocation test
Heart Vessels, 33 (2018), pp. 846-852
17.
P.L. Schiff
Ergot and its alkaloids
Am J Pharm Educ, 70 (2006), p. 98
18.
A. Suyama, H. Kuriyama
Mechanisms of the ergonovine-induced vasoconstriction in the rabbit main coronary artery
Naunyn Schmiedebergs Arch Pharmacol, 326 (1984), pp. 357-363
19.
H. Benamer, M. Saighi Bouaouina, A. Masri, G. Sarkis, N. El Beze, V. Millien
[Vasospastic angina: An under-diagnosed pathology]
Ann Cardiol Angeiol (Paris), 68 (2019), pp. 341-346
20.
S. Sueda, K. Fujimoto, Y. Sasaki, T. Sakaue, T. Yoshii, H. Habara, *et al.*
Differential incidence and morphology of provoked spasm between intracoronary acetylcholine and ergonovine testing: recommendation of supplementary use
Heart Vessels, 34 (2019), pp. 745-754
21.
A. Goto, S. Ito, H. Kondo, Y. Nomura, N. Yasue, H. Suzumura, *et al.*
Evaluation of adjunctive intracoronary administration of acetylcholine following intravenous infusion of ergonovine to provoke coronary artery spasm
J Cardiol, 34 (1999), pp. 309-316
22.
S. Sueda, H. Kohno
Overview of complications during pharmacological spasm provocation tests
J Cardiol, 68 (2016), pp. 1-6
23.
T. Isogai, H. Yasunaga, H. Matsui, H. Tanaka, T. Ueda, H. Horiguchi, *et al.*

- Serious cardiac complications in coronary spasm provocation tests using acetylcholine or ergonovine: analysis of 21 512 patients from the diagnosis procedure combination database in Japan
Clin Cardiol, 38 (2015), pp. 171-177
24.
R. Ginsburg, I.H. Lamb, M.R. Bristow, J.S. Schroeder, D.C. Harrison
Application and safety of outpatient ergonovine testing in accurately detecting coronary spasm in patients with possible variant angina
Am Heart J, 102 (1981), pp. 698-702
25.
S. Sueda, T. Sakaue, T. Okura
Sequential spasm provocation tests under medications are indispensable in patients with aborted sudden cardiac death due to coronary spasm
Intern Med, 59 (2020), pp. 2211-2212
26.
J. Adjedj, F. Picard, G. Durand-Viel, A. Sigal-Cinqualbre, D. Daou, B. Diebold, *et al.*
Coronary microcirculation in acute myocardial ischaemia: From non-invasive to invasive absolute flow assessment
Arch Cardiovasc Dis, 111 (2018), pp. 306-315
27.
F. Picard, O. Alansari, S. Mogi, M. Van't Veer, O. Varenne, J. Adjedj
In vitro test-retest repeatability of invasive physiological indices to assess coronary flow
Catheter Cardiovasc Interv, 94 (2019), pp. 677-683
28.
J. Adjedj, F. Picard, S. Mogi, A. Bize, L. Sambin, O. Muller, *et al.*
Accurate assessment of coronary blood flow by continuous thermodilution technique: Validation in a swine model
Catheter Cardiovasc Interv, 99 (2022), pp. 836-843
29.
G. Fragasso, S.L. Chierchia, F. Arioli, O. Carandente, S. Gerosa, M. Carlino, *et al.*
Coronary slow-flow causing transient myocardial hypoperfusion in patients with cardiac syndrome X: long-term clinical and functional prognosis
Int J Cardiol, 137 (2009), pp. 137-144
30.
V. Martinez
Pereyra, A. Seitz, A. Hubert, H. Mahrholdt, R. Bekeredjian, U. Sechtem, *et al.*
Coronary microvascular spasm as the underlying cause of the angiographic slow flow phenomenon
JACC Case Rep, 2 (2020), pp. 35-39
31.
J. Takahashi, A. Suda, S. Yasuda, H. Shimokawa
Measurement of myocardial lactate production for diagnosis of coronary microvascular spasm
J Vis Exp, 175 (2021)