



HAL
open science

Correspondence between scalp-EEG and SEEG seizure onset patterns in patients with MRI-negative drug-resistant focal epilepsy

Anna Bolzan, Jeanne Benoit, Francesca Pizzo, Julia Makhalova, Nathalie Villeneuve, Romain Carron, Didier Scavarda, Fabrice Bartolomei, Stanislas Lagarde

► To cite this version:

Anna Bolzan, Jeanne Benoit, Francesca Pizzo, Julia Makhalova, Nathalie Villeneuve, et al.. Correspondence between scalp-EEG and SEEG seizure onset patterns in patients with MRI-negative drug-resistant focal epilepsy. *Epilepsia Open*, In press, 10.1002/epi4.12886 . hal-04370365

HAL Id: hal-04370365

<https://hal.science/hal-04370365v1>

Submitted on 3 Jan 2024

HAL is a multi-disciplinary open access archive for the deposit and dissemination of scientific research documents, whether they are published or not. The documents may come from teaching and research institutions in France or abroad, or from public or private research centers.

L'archive ouverte pluridisciplinaire **HAL**, est destinée au dépôt et à la diffusion de documents scientifiques de niveau recherche, publiés ou non, émanant des établissements d'enseignement et de recherche français ou étrangers, des laboratoires publics ou privés.



Distributed under a Creative Commons Attribution - NonCommercial 4.0 International License

Benoit Jeanne (Orcid ID: 0000-0002-3781-8442)
 Pizzo Francesca (Orcid ID: 0000-0001-6345-1288)
 Makhalova Julia (Orcid ID: 0000-0001-7962-2942)
 Scavarda Didier (Orcid ID: 0000-0001-9344-8071)
 Bartolomei Fabrice (Orcid ID: 0000-0002-1678-0297)
 Lagarde Stanislas (Orcid ID: 0000-0003-2916-1302)

Correspondence between scalp-EEG and SEEG seizure onset patterns in patients with MRI-negative drug-resistant focal epilepsy

Authors: Anna Bolzan¹, Jeanne Benoit³, Francesca Pizzo^{1,2}, Julia Makhalova^{1,2,4}, Nathalie Villeneuve⁵, Romain Carron^{2,6}, Didier Scavarda^{2,7}, Fabrice Bartolomei^{1,2°}, Stanislas Lagarde^{1,2,8°*}

° co last authors

Affiliations:

- 1- APHM, Timone Hospital, Epileptology and Cerebral Rhythmology, Marseille, France
- 2- Aix Marseille Univ, INSERM, INS, Inst Neurosci Syst, Marseille, France
- 3- CHU de Nice, Epileptology Department, Université Côte d'Azur, UMR2CA (URRIS), Nice, France
- 4- APHM, Timone Hospital, CEMEREM, Marseille, France
- 5- APHM, Timone Hospital, Paediatric Neurology, Marseille, France
- 6- APHM, Timone Hospital, Stereotactic and Functional Neurosurgery, Gamma Unit, Marseille, France
- 7- APHM, Timone Hospital, Paediatric Neurosurgery, Marseille, France
- 8- University Hospitals of Geneva (HUG), University of Geneva (UNIGE), Geneva, Switzerland

Emails:

- bolzan.anna92@gmail.com
- benoit.j@chu-nice.fr
- francesca.pizzo@ap-hm.fr
- julia.scholly@ap-hm.fr
- nathalie.villeneuve@ap-hm.fr
- romain.carron@ap-hm.fr

This article has been accepted for publication and undergone full peer review but has not been through the copyediting, typesetting, pagination and proofreading process which may lead to differences between this version and the [Version of Record](#). Please cite this article as doi: [10.1002/epi4.12886](https://doi.org/10.1002/epi4.12886)

- didier.scavarda@ap-hm.fr
- fabrice.bartolomai@ap-hm.fr
- stanislas.lagarde@ap-hm.fr

*** Corresponding Author:**

Dr Stanislas LAGARDE; Service de Rythmologie Cérébrale et d'Epileptologie, Hôpital La Timone, 264 Rue Saint-Pierre, 13005, Marseille, France; stanislas.lagarde@ap-hm.fr

ACKNOWLEDGMENTS

We thank all colleagues involved in our epilepsy centre (Neurology: Agnes Trebuchon, Francesca Bonini, Geraldine Daquin, Lisa Vaugier, Marie Arthuis, Maxime Guye, Isabelle Lambert, Angela Marchi, Nada El Youssef, Sandrine Aubert; Neuropaediatrics: Anne Lépine, Mathieu Milh, Beatrice Desnous; all paramedical staff of the above departments). We thank Serge Vulliemoz and Nicolas Roehri for suggestions and comments on this work. We thank the patients.

FUNDINGS

SL is supported by grants from the LFCE (*Ligue Française Contre l'Épilepsie*, french chapter of the ILAE) and PHOCEO.

CONFLICT OF INTEREST

None of the authors has any conflict of interest to disclose. We confirm that we have read the Journal's position on issues involved in ethical publication and affirm that this report is consistent with those guidelines.

DATA AVAILABILITY STATEMENT

The data that support the findings of this study are available from the corresponding author upon reasonable request.

ETHICS

The study was approved by the Institutional Review Board of the APHM (NHLS4Y), and the included patients provided written informed consent.

Correspondence between scalp-EEG and SEEG seizure onset patterns in patients with MRI-negative drug-resistant focal epilepsy

Authors: Anna Bolzan¹, Jeanne Benoit^{2,3}, Francesca Pizzo^{1,2}, Julia Makhalova^{1,2,4}, Nathalie Villeneuve⁵, Romain Carron^{2,6}, Didier Scavarda^{2,7}, Fabrice Bartolomei^{1,2,°}, Stanislas Lagarde^{1,2,8,°*}

° co last authors

* corresponding author: Dr Stanislas LAGARDE, Service d'épileptologie et de rythmologie cérébrale, Hôpital La Timone, Assistance-Publique Hôpitaux de Marseille, 264 Rue Saint-Pierre, 13005 MARSEILLE, France ; stanislas.lagarde@ap-hm.fr or stanislas.lagarde@univ-amu.fr . Tel : +33491384990.

Affiliations:

- 9- APHM, Timone Hospital, Epileptology and Cerebral Rhythmology, Marseille, France
- 10- Aix Marseille Univ, INSERM, INS, Inst Neurosci Syst, Marseille, France
- 11- CHU de Nice, Epileptology Department, Université Côte d'Azur, UMR2CA (URRIS), Nice, France
- 12- APHM, Timone Hospital, CEMEREM, Marseille, France
- 13- APHM, Timone Hospital, Paediatric Neurology, Marseille, France
- 14- APHM, Timone Hospital, Stereotactic and Functional Neurosurgery, Gamma Unit, Marseille, France
- 15- APHM, Timone Hospital, Paediatric Neurosurgery, Marseille, France
- 16- University Hospitals of Geneva (HUG), University of Geneva (UNIGE), Geneva, Switzerland

Keywords: focal epilepsy, drug resistant epilepsy, epilepsy surgery, SEEG, scalp-EEG, seizure onset pattern

Number of text page: 25; **Number of words:** 4624; **Number of references:** 50; **Number of figures:** 4; **Number of tables:** 2.

SUMMARY

Objective: Our objective was to evaluate the relationship between scalp EEG and stereoelectroencephalography (SEEG) seizure onset patterns (SOPs) in patients with MRI-negative drug-resistant focal epilepsy.

Methods: We analysed retrospectively 41 patients without visible lesion on brain MRI who underwent video-EEG followed by SEEG. We defined five types of SOPs on scalp EEG and eight types on SEEG. We examined how various clinical variables affected scalp EEG SOPs.

Results: The most prevalent scalp SOPs were rhythmic sinusoidal activity (56.8%), repetitive epileptiform discharges (22.7%), and paroxysmal fast activity (15.9%). The presence of paroxysmal fast activity on scalp EEG was always seen without delay from clinical onset and correlated with the presence of low-voltage fast activity in SEEG (sensitivity = 22.6%, specificity = 100%). The main factor explaining the discrepancy between the scalp and SEEG SOPs was the delay between clinical and scalp EEG onset. There was a correlation between the scalp and SEEG SOPs when the scalp onset was simultaneous with the clinical onset ($p=0.026$). A significant delay between clinical and scalp discharge onset was observed in 25% of patients and featured always with a rhythmic sinusoidal activity on scalp, corresponding to similar morphology of the discharge on SEEG. The presence of repetitive epileptiform discharges on scalp was associated with an underlying focal cortical dysplasia (sensitivity = 30%, specificity = 90%). There was no significant association between the scalp SOPs and the epileptogenic zone location (deep or superficial), or surgical outcome.

Significance: In patients with MRI-negative focal epilepsies, scalp SOP could suggest the SEEG SOP and some aetiology (focal cortical dysplasia) but has no correlation with surgical prognosis. Scalp SOP correlates with the SEEG SOP in cases of simultaneous EEG and clinical onset, otherwise scalp SOP reflects the propagation of the SEEG discharge.

PLAIN LANGUAGE SUMMARY

We looked at the correspondence between the electrical activity recorded during the start of focal seizure using scalp or intracerebral electrodes in patients with no visible lesion on MRI. If there is a fast activity on scalp, it reflects similar activity inside the brain. We found a good correspondence between scalp and intracerebral electrical activity for cases without significant delay between clinical and scalp electrical onset (seen in 75% of the cases we studied). Visualizing repetitive epileptic activity on scalp could suggest a particular cause of the epilepsy: a subtype of brain malformation called focal cortical dysplasia.

Keyword: focal epilepsy, drug resistant epilepsy, epilepsy surgery, SEEG, scalp-EEG, seizure onset pattern

KEY POINTS

- The most prevalent scalp SOPs were rhythmic sinusoidal activity, repetitive epileptiform discharges, and paroxysmal fast activity
- Paroxysmal fast activity on scalp was always seen without delay from clinical onset and was highly specific of low-voltage fast activity in SEEG
- There was a significant delay between clinical and scalp onset in 25% of patients with always a rhythmic sinusoidal activity on scalp
- There was a correlation between the scalp and SEEG SOPs when the scalp onset was simultaneous with the clinical onset
- Repetitive epileptiform discharges on scalp suggested an underlying focal cortical dysplasia

MAIN BODY

1. INTRODUCTION

For patients with focal epilepsy who do not respond to antiseizure medication, epilepsy surgery is the most effective treatment. To achieve a successful surgical outcome, it is important to accurately identify the epileptogenic zone (EZ) through a comprehensive pre-surgical evaluation that includes clinical, electrophysiological, and imaging data. During this evaluation, video-EEG recording of seizures is crucial for building hypotheses about the EZ, based on the analyses of ictal semiology and associated EEG changes. Several factors can influence the detectability of ictal discharges on scalp EEG: size, depth and orientation of the cortical sources of ictal activity, level of synchronization of neuronal populations, features of physiological background activity, and skull conductivity¹⁻⁵. Thus, the diagnostic and localizing performances of scalp EEG are limited. Conversely, intracerebral electrodes can directly record local field potentials from the brain structures generating and propagating seizures. The SEEG thus provides a high spatial resolution and a more precise detection of spatially limited discharges, as well as an improved signal-to-noise ratio thanks to considerable reduction of artefacts (e.g., ictal movements which often obscure scalp EEG recording). However, unlike the non-invasive whole-brain electrophysiological approaches such as electro-magnetic source imaging, SEEG ability to detect the EZ is limited by the number and position of the implanted electrodes (incomplete spatial sampling). To optimize the EZ localization through scalp EEG in a given patient, it is thus essential to take the advantages of both techniques and search for correlations between the electrical activities recorded on SEEG and on the scalp during seizures.

In recent decades, increasing attention has been drawn to the scalp⁶⁻¹⁰ and SEEG¹¹⁻¹³ seizure onset pattern (SOP). However, only a few studies have examined the relationships between them¹⁴⁻¹⁸, mostly in cases of temporal lobe epilepsy. One study assessed such correlations in patients with MRI-visible lesion¹⁷, showing that the scalp SOP could inform on the SEEG SOP, the underlying lesion, as well as the depth of the EZ location. In the present work, we aimed to assess the correlations between the scalp and SEEG SOPs in patients with negative MRI,

known to be particularly challenging candidates for epilepsy surgery. Additionally, we aimed to identify factors that explain cases of discrepancy between scalp and SEEG SOP.

2. MATERIALS AND METHODS

2.1 Patients selection

We retrospectively analysed all patients with a brain MRI without visible lesion (reviewed in multidisciplinary meeting) who underwent SEEG in our department as part of their presurgical evaluation for focal drug-resistant epilepsy from March 2011 to September 2021. All patients had a complete presurgical work-up, including medical history, neurological examination, brain MRI, cerebral positron emission tomography, and scalp video-EEG recording. We included patients with at least one typical spontaneous seizure recorded on both scalp EEG and SEEG. The study was approved by the Institutional Review Board of the APHM (NHLS4Y), and the included patients provided written informed consent.

2.2 Scalp and SEEG recordings

Scalp EEGs were recorded using the international 10-20 system with additional electrodes exploring the basal temporal regions and temporal poles (FT9, TP9, FT10, and TP10). SEEG recordings were performed using intracerebral multiple contact electrodes (DIXI© or Alcis©, 10–15 contacts with length 2 mm, diameter 0.8 mm, and 1.5 mm apart¹⁹). SEEG electrodes were implanted for each patient based on EZ localization hypotheses inferred from non-invasive evaluation. Pre-implantation MRI and post-implantation CT were fused to locate each electrode contact within the brain²⁰. Signals were recorded on a 128- or 256-channel Natus© system, sampled at 256, 512, or 1024 Hz depending on EEG/SEEG modalities and year of recording. Partial or complete antiseizure medication withdrawal was performed to facilitate the recording of seizures.

2.3 Matching scalp and intracerebral ictal recordings

Only spontaneous clinical and electrographic seizures were analysed, and not those induced by electrical stimulation in SEEG. The SOP was considered as the first sustained electrographic

change clearly distinguishable from background activity. All recorded seizures were evaluated by two trained electroencephalographers blinded to patients' clinical data (AB, SL). Since scalp and intracerebral EEG were not recorded simultaneously, we used previously published methodology to match scalp EEG and SEEG recorded seizures¹⁷. For each individual seizure, whether recorded with scalp-EEG or SEEG, we defined three main features 1) topography (with lobar precision (e.g., temporal) in EEG and sublobar precision (e.g., mesio-temporal) in SEEG), 2) morphology of the SOP (see paragraph 2.4) and 3) semiology. Subsequently, for each patient we compared these criteria across all seizures of a same modality (scalp-EEG or SEEG). If these seizures did not present the exact same features, we defined different seizure types (specific to a modality). For instance, if a patient exhibited independent multifocal EZ, seizures arising from distinct EZ were considered as different seizure types due to their localization. Additionally significant differences in semiology between two seizures, even without clear difference in topography, resulted in their classification as different seizure types. Finally, seizure types between scalp-EEG and SEEG were matched based on the comparison of two criteria: 1) topography and 2) semiology. A match required similar semiology and a scalp-EEG projection that concurred with the SEEG data. This matching process was relatively straightforward in cases with bilateral EZ or multiple seizure semiology. However, it was more challenging in other scenarios such as a patient with a posterior EZ identified on SEEG but exhibiting a projection on anterior temporal in scalp-EEG; in such instances, a mismatch was acknowledged. Disagreements between experts were solved by discussion and seizure types that could not be confidently matched were excluded from subsequent analyses (details about matching procedure can be found in supplementary figure 1).

2.4 Seizure onset pattern analysis

For each scalp and SEEG seizure type, the SOP was determined through visual and time-frequency analysis.

For scalp recordings we found five SOPs (*Figure 1*):

1. Rhythmic Sinusoidal Activity (RSA) <13 Hz
2. Repetitive Epileptiform Discharges (RED): (pseudo-)periodic spike-and-wave or sharp-and-wave or spikes <13 Hz, without rhythmic sinusoidal activity
3. Paroxysmal Fast Activity (PFA): low amplitude fast discharges \geq 13 Hz

4. Attenuation: reduction of > 50 % of the background activity with a voltage $\leq 10 \mu\text{V}$
5. Obscured: no visible EEG pattern because of artifacts at seizure onset

For the statistical analysis, we excluded scalp seizures categorized as obscured SOP.

For SEEG recordings we used the eight previously published SOP¹²:

1. Low-voltage fast activity (LVFA): rhythmic fast oscillations (>14 Hz) of low amplitude (<30 μV) starting without other initial apparent changes
2. Preictal spiking with rhythmic spikes of low frequency (classically ≤ 3 Hz), high amplitude, and prolonged duration (>5 seconds, median = 20 seconds) followed by LVFA (usually of lower frequency than isolated LVFA)
3. Burst of polyspikes of high frequency (typically >12Hz) with high amplitude and short duration (<5 seconds) followed by LVFA
4. Slow wave or baseline shift (equal to DC shift) followed by LVFA
5. Rhythmic spikes or spike-waves, of low frequency (usually >6 Hz and constantly <14 Hz) and with high amplitude
6. Sharp theta/alpha activity with sinusoidal activity of low frequency (lower than LVFA, median = 9.5 Hz), median initial amplitude (higher than LVFA), and progressively increasing amplitude
7. Sharp beta activity with sinusoid activity of beta-band frequency (lower than LVFA), median initial amplitude (higher than LVFA), and progressively increasing amplitude
8. Delta-brush, with bursts of low-amplitude rapid activity (within gamma frequency bands) superimposed upon low-frequency (delta) sinusoidal activity

For patients presenting different SOPs for the same seizure type, we retained the predominant SOP both for scalp EEG and SEEG. In patients with a scalp EEG SOP occurring after clinical onset (delay = t), we additionally analysed the morphology of the SEEG ictal discharge at the time t , equal to the delay between clinical and scalp EEG onset.

2.5 Clinical variables

The EZ was defined using visual analysis of SEEG seizures, complemented by a quantitative method (epileptogenicity index²¹). We classified patients in ten subgroups, according to their EZ location: mesio-temporal, temporal lateral, mesio-lateral temporal, temporal plus,

bitemporal, frontal, frontal plus, operculo-insular, parietal, and occipital plus. Each patient's EZ was further defined as deep (mesial part of the brain hemispheres, orbitofrontal region, and insula) or superficial (other locations or association of both deep and superficial EZ). The neuropathological diagnosis of patients who underwent resective surgery was reported according to current International League Against Epilepsy classifications^{22,23}. Surgical outcome was assessed regularly during post-operative follow-up and rated according to Engel classification²⁴. Engel score from the last available follow-up was used for statistical analyses.

2.6 Statistical analysis

We computed sensitivity and specificity for some specific scalp SOP to assess their predictive value for certain variables (e.g., SEEG SOP, depth of EZ, aetiology). We started by testing the significance for the overall association between scalp-EEG and SEEG SOP. Then, we focused on this association 1) for patients without delay between clinical and scalp-EEG onset, and 2) between the scalp SOP and the morphology of the discharge on SEEG after a time equal to the delay between clinical and scalp EEG onset. We also looked for any statistically significant differences between patients with / without such delay. Additionally, we examined the influence of the depth of the EZ on the scalp SOP, and whether there was any significant association between scalp-EEG and SEEG SOP in the subgroups with deep and superficial EZ. Finally, we tested the association between scalp-EEG SOP and others clinical variables: aetiology, patients' eligibility for surgery, Engel's scores, age at SEEG, duration of epilepsy before SEEG, EZ localisation, and sex. Fisher's exact test was used for categorical data, and Kruskal-Wallis test for continuous data. Statistical significance was set at p-value < 0.05. Statistical analyses were performed with the software SPSS Statistics for Mac, version 22 (IBM).

3. RESULTS

3.1 Population

We identified 59 patients fitting our inclusion criteria. Among those, 16 were excluded because their scalp EEG was performed outside our centre. Two more patients were excluded as they did not present spontaneous seizure on SEEG and/or scalp EEG monitoring. A final number of 41 patients (20 women, median age at scalp EEG = 27 years), with 279 habitual seizures (136 on scalp EEG, 143 on SEEG) were analysed. Patients' demographic data are summarized in Table 1. Almost all EZ localization were represented. Twenty patients underwent surgery with histology being focal cortical dysplasia (FCD) type I in six cases (30%), FCD type II in three (15%), FCD type III in one (5%), hippocampal sclerosis in one (5%), aspecific in four (20%) and gliosis in five (25%). At the latest available follow-up (mean = 66 months, SD = 44), seven patients were Engel class I, two Engel class II, three Engel class III and eight Engel class IV. The remaining 21 patients (51%) did not undergo surgery after SEEG because of contraindications (bilateral EZ or involving eloquent structures, n=15, 36.6%) or other reasons (personal preference, improvement after thermocoagulation).

3.2 Matching scalp and intracerebral SOP

Forty-nine seizure types were identified on scalp-EEG (47 clinical and two electrographic), and 53 on SEEG (48 clinical and five electrographic). Eight SEEG-recorded seizure types showed SOP variation from one seizure to another. The predominant SOP was retained for further analysis. Four scalp-EEG seizure types (three clinical and one electrographic) and eight SEEG seizure types (four clinical and four electrographic) could not be matched and were excluded from the analysis. A total of 45 pairs of SOPs were matched between scalp EEG and SEEG seizures. One of the remaining scalp SOP was categorized as an obscured pattern (corresponding to a sharp beta activity as SOP on SEEG), precluding it from further analysis (*Figure 2A*).

3.3 Association between Scalp-EEG and SEEG SOP

The most frequent scalp SOP was RSA (56.8 %), followed by RED (22.7 %), PFA (15.9 %), and attenuation (4.5 %) (*Figure 2B*). The most frequent SEEG SOP was slow wave or baseline shift followed by LVFA (34.1 %), followed by rhythmic spikes or spike-waves and LVFA (18.2% both), preictal spiking followed by LVFA (13.6 %), sharp theta-alpha activity (1.4 %), burst of

polyspikes followed by LVFA and delta brush (2.3 % both). Associations between matched scalp and SEEG SOPs are shown in *Figure 3A*. Scalp PFA was only observed when a LVFA was visible on SEEG SOP, but some cases with LVFA on SEEG SOP did not exhibit a PFA SOP on scalp EEG ($p=0.086$, sensitivity = 22.6%, specificity = 100%). Only 68% of RSA and 40% of RED on scalp were associated with SEEG SOP including an LVFA. Scalp RSA and RED further matched with almost all types of SEEG SOPs. Overall, scalp SOPs were not significantly associated with SEEG SOPs ($p = 0.161$).

3.4 Impact of the delay of appearance of the scalp SOP

Ten patients (24.4%) presented a delay between clinical and scalp EEG onset. The time t equal to the delay between clinical and scalp EEG onset was in median of 9.75 seconds (range 5-32.5 seconds). All these patients featured RSA as scalp EEG SOP ($p=0.03$, sensitivity = 100% and specificity = 70% to predict the existence of a delay). All types of SEEG SOP were observed in these patients, except burst of polyspikes followed by LVFA. Regarding patients without such delay, all types of scalp-EEG SOP (14 RSA, 10 RED, 7 PFA and 2 attenuation), and SEEG SOP, except delta-brush (10 slow-wave followed by LVFA, 7 rhythmic spikes, 6 LVFA, 5 pre-ictal spiking, 5 sharp theta-alpha activity and 1 burst of polyspikes) were observed. The existence of a delay between clinical and scalp EEG onset was not significantly associated with the following factors: SEEG SOP, depth of the EZ, type of epilepsy, histology, or surgical outcome. However, we found that 80% of patients with delayed scalp EEG SOP had a SEEG SOP including LVFA (compared to 68% in those without delayed scalp SOP). At the time t , most patients ($n=8$, 80%) showed slow SEEG ictal discharge (theta-alpha activity in five patients, rhythmic spikes in three). In six of these eight patients (75%), the initial SEEG SOP involved LVFA (preceded by a slow wave or baseline shift for five of these patients), which slowed down and increased in amplitude at the time t . For the two patients whose LVFA was still visible on SEEG at the time t , the LVFA was spatially limited to only a few SEEG contacts (Heschl gyrus for one, planum temporal and amygdala for the other), with concomitant slowing of background activity on the surrounding contacts. In patients with scalp SOP starting without delay from clinical onset, we found a statistically significant association between scalp and SEEG SOPs ($p = 0.026$, *Figure 3B*). Then, paroxysmal fact activity on scalp was associated in more than 70% of cases with slow wave followed by LVFA on SEEG. Repetitive

epileptiform discharge on scalp was associated in 40% with rhythmic spikes and spikes-waves on SEEG. The distribution was more balanced for rhythmic sinusoidal activity (associated with SEEG SOP including or not LVFA) and attenuation as scalp-EEG SOP (always associated with SEEG SOP including LVFA). We also found a statistically significant association between the scalp SOP and the morphology of the SEEG ictal discharge at the time t ($p = 0.003$).

3.5 Impact of the depth of the EZ

Among the 44 matching seizure types, the EZ had a superficial location in 22 and deep locations in 22. A scalp EEG onset starting after the clinical onset was seen in 21.7% of seizures with a deep EZ and in 27.2% of those with a superficial EZ. Attenuation SOP on scalp EEG was only observed in seizures with a superficial EZ ($n=2$). A slight majority of PFA on scalp was seen in the cases with superficial EZ (57.1%, sensitivity = 13.6%, specificity = 81.8%), most of RED were seen in the cases with deep EZ (70%, sensitivity = 31.8%, specificity = 86.3%), and RSA was seen as often in case of deep or superficial EZ (48/52%, sensitivity = 54.6%, specificity = 40.9% for superficial) (*supplementary figure 2*). Statistically, scalp SOPs were not significantly associated with the depth of the EZ ($p=0.32$).

The distribution of the SEEG SOPs matched to the scalp SOP depending on the depth of the EZ is shown in *supplementary figures 3*. Among the 22 pairs of matched seizure types with a superficial EZ: attenuation on scalp matched with slow wave followed by LVFA and LVFA patterns on SEEG; PFA with pre-ictal spiking and slow wave followed by LVFA; RED with pre-ictal spiking, rhythmic spikes and sharp theta alpha activity; and RSA with all types of SEEG SOPs. Among the 22 analysed pairs of matching seizure types with a deep EZ: PFA on scalp matched only with slow wave followed by LVFA on SEEG; RED with rhythmic spikes, slow wave followed by LVFA, pre-ictal spiking and sharp theta alpha activity; and RSA with slow wave followed by LVFA, LVFA, rhythmic spikes and sharp theta alpha. Statistically, there was no significant association between scalp and SEEG SOPs, neither within the superficial ($p = 0.82$) nor the deep ($p = 0.45$) EZ sub-groups.

3.6 Association with other variables

Out of the 20 patients operated, it was observed that scalp EEG REDs were mostly found in patients with an underlying FCD (75% of patients with RED, sensitivity = 30%, specificity = 90%, $p=0.228$). However, it is worth noting that some patients with FCD also had other types of scalp SOPs. The other scalp EEG SOPs were not explicitly linked to specific histological subgroups (*Figure 4*). There was no significant association between scalp SOPs and the following variables: patients' eligibility for surgery (conclusion of multidisciplinary meeting following SEEG, $p=0.246$, *supplementary figure 4*), Engel scores ($p=0.378$, *supplementary figures 5*), age at SEEG ($p=0.659$), duration of epilepsy before SEEG ($p=0.352$), EZ localisation ($p=0.227$), and sex ($p=0.216$). Conversely, SEEG SOPs were associated with the patients' Engel scores: patterns involving LVFA were associated with better outcomes (41.7% of seizure-freedom vs. 25% in patients with SOPs without LVFA, $p=0.017$).

4. DISCUSSION

The purpose of this study was to assess the correlation between the scalp and SEEG SOPs in patients with focal drug-resistant epilepsy and negative MRI. This research builds upon previously published data about lesional epilepsy¹⁷. Our main findings are:

1. The most frequently observed scalp SOP is RSA (less than 13 Hz), which is consistent with findings in patients with lesional MRI¹⁷ and temporal lobe epilepsies^{14–16}.
2. There is a correlation between scalp EEG and SEEG SOPs in patients without delay between clinical and scalp EEG onset.
3. PFA is seen in about 16% of the patients on scalp, always simultaneous to clinical onset, and always reflecting a SEEG SOP including an LVFA.
4. In a quarter of patients there is a delay between clinical and scalp EEG onset (always presenting with RSA) corresponding to the evolution of the SEEG ictal discharge.
5. RED on scalp are evocative of an underlying FCD.

Our analyses suggest that scalp SOP is correlated with the morphology of the ictal discharge on SEEG at the time t equal to the delay between clinical and scalp EEG onset. Not surprisingly, we also found that PFA could be seen on scalp EEG in about 16% of the patients, simultaneously to clinical onset and was associated with SEEG SOPs including an LVFA. We did not find a significant over-representation of PFA on scalp in case of superficial

EZ, conversely to previous studies ^{5,6,8,10}. This could be explained by the relatively low number of PFA in our cohort (n=7). Indeed, the amplitude of the EEG signal is inversely proportional to the square of the source-to-surface distance ¹ and low frequencies increase while high frequencies decrease with this distance ². It is essential to pay attention to the timing of scalp SOP appearance from clinical onset in patients with scalp SOPs other than PFA, because some delayed scalp SOP might reflect the evolution of the intracerebral discharge to slower frequencies and higher amplitudes. In our cohort, a significant delay was found in about a quarter of the patients without PFA, with a mean lag of 10 seconds. These delayed scalp discharges were always RSA on scalp and mostly correlated with similar discharges on SEEG, possibly reflecting a propagation from the EZ. Actually, theta/alpha activity is a frequent propagation pattern in SEEG, observed in more than 50% of cases ^{11,27}. It has been explained in computational models by the combination of gradual recruitment of the local cortex (ictal wavefront) and sensor-to-source projection ²⁸. This delayed appearance reflects the intracerebral dynamic and is probably due to several factors influencing the visibility of the electrical brain activity on the scalp. First, a sufficient cortical area (6-10 cm²) needs to be activated by the ictal discharge ^{2,5}, as largely described for mesio-temporal seizures propagating to basal and lateral temporal areas ^{6,16,17,29-33}. Second, the magnitude of the ictal discharge, particularly the ratio over the background amplitude, significantly impacts its visibility due to the attenuation by the skull and scalp, especially for fast, low-voltage activities ^{2,34}. Third, high synchrony is needed to generate ictal patterns visible on scalp EEG ^{2,5,16}. Conversely, decreased synchrony has been demonstrated through functional connectivity analysis during intracerebral LVFA ^{35,36}, which might explain the "attenuation" scalp discharge sometimes correlated with intracerebral LVFA on the neocortex ^{16,18,26}. Other factors influencing the delayed appearance of the scalp ictal discharges may be the difficulties in distinguishing small PFA on the scalp from physiological (e.g. rhythms of frontocentral area) or muscular activities, as well as the curved geometry of some generators such as hippocampus, amygdala or bottom of sulcus, that could lead to electrical field cancellation ³. All these factors explain how some electrical seizures of short duration and confined to limited brain volume may be missed on scalp recordings in a significant number of cases ^{15,16,18,37}. This delayed appearance should be considered as an important confounding factor for ictal electrical source imaging (i.e., proceeding to signal analysis before the visible scalp discharge) ³⁸.

Another interesting finding is the association between RED and an underlying FCD. Despite improvements in imaging techniques and computer-assisted postprocessing^{39–41}, a significant percentage of FCD (especially type I) remains undetected in clinically used imaging. Because some FCD subtypes (particularly type II) are associated with favourable surgical outcome^{42,43}, the effort to find a neurophysiological biomarker that could suggest their presence in patients with negative MRI is essential. Some studies have suggested evocative interictal EEG patterns^{44–47} but less is known about their scalp SOPs. Tanaka and colleagues have suggested that fast-frequency scalp SOPs could help the clinician suspect a cortical development malformation (not limited to FCD)¹⁷. This RED SOP probably corresponds to the pre-ictal spiking or burst of polyspikes prior to LVFA patterns observed in SEEG⁴⁸. This scalp SOP should help clinicians to motivate SEEG because of a high suspicion of FCD and a potentially favourable surgical outcome.

In contrast to SEEG, scalp SOPs showed no significant association with our patients' surgical eligibility and outcome. Similar findings were reported in temporal lobe epilepsy⁸. Indeed, scalp SOPs are not very specific to a particular EZ localization¹⁸, and other more critical factors might have a more significant impact on the outcome⁴⁹. Another explanation may be low statistical power due to the limited number of patients operated on in our study (n=20).

Our study has some limitations, the first being that scalp EEG and SEEG were recorded separately. Given a certain intra-individual variability in electrical seizure organization, the scalp SOP that would have been recorded simultaneously during SEEG monitoring might differ from the one recorded during video-EEG monitoring. However, a previous study has shown that scalp SOPs do not vary significantly between scalp-EEG only and simultaneous scalp-SEEG recordings in the same patient¹⁶. Our mean delay between clinical and scalp EEG onset may also be an underestimation of the delay between SEEG and scalp EEG discharge onset (that could only be estimated using simultaneous recordings), and we may have underestimated the number of patients with such a delay between SEEG and scalp EEG onset (higher in another study³⁷). That could lead to underestimating the concordance between scalp and SEEG ictal discharge morphology at the time of scalp visibility. However, the delay of appearance of the scalp SOP in our study is similar to previous studies using simultaneous recordings^{16,37}. A recent study on SEEG correlates of scalp EEG ictal discharges used simultaneous recordings¹⁸, and described six different clusters that

combine morphology and EZ localization (including “normal” and “blurred” EEG clusters). Theta/delta temporal scalp discharges were mainly associated with prolonged mesio-temporal discharges (starting with or without LVFA on SEEG) but more rarely with frontal, parietal, or insulo-opercular EZ (reflecting propagation). Alpha/slow waves posterior scalp discharges were associated mainly with LVFA coming from temporal, parietal and occipital EZ (but also seen in multilobar and insulo-opercular EZ). Paroxysmal fast activity and pre-ictal spiking over frontal scalp electrodes were associated with LVFA originating mainly from frontal dorsal EZ (although also seen in temporal or parietal EZ). Finally, diffuse suppression on the scalp was associated with LVFA on SEEG and was particularly frequent in the case of temporal or insulo-opercular, mesial and/or ventral EZ. Overall, the scalp SOP frequently reflected the propagation of the ictal discharge and lacked specificity concerning EZ localization, which is in concordance with our findings.

Secondly, a subset of our patients either did not undergo resective surgery or did not achieve seizure-freedom after SEEG-guided resection. Several factors may account for these outcomes, including an excessively broad EZ or its overlap with eloquent cortices. Notably, it cannot be excluded that in some of these patients, the EZ was not perfectly delineated by the SEEG, especially in this population of patients with negative MRI. This could explain the observed absence of significant association between scalp-EEG SOP and the depth of the EZ, and may have influenced our analysis of SEEG ictal activity at the delay between clinical and scalp-EEG onset. A third limitation is the relatively small sample size of our cohort due to our focus on the challenging population of patients with negative MRI aiming to complement previous findings on MRI-visible lesional epilepsy¹⁷. It limits the statistical power of our analyses, and might explain the low prevalence of attenuation as scalp SOP in our cohort compared to others, particularly concerning mesio-temporal seizures¹⁶. For instance, we only analysed seven patients with frontal epilepsy that could explain the low prevalence of attenuation as scalp SOP, and the absence of significant association between deep EZ and these SOP. Additionally, we only found three patients with FCD and RED as scalp SOP. Consequently, the association between these two variables necessitates validation through subsequent investigations involving a larger patient cohort. To ensure a thorough characterization of electrophysiological data, we opted for a detailed categorization of both scalp-EEG and SEEG SOP. This approach resulted in limited numbers of observations in some subcategories, thereby limiting statistical power. To overcome this

limitation, potential strategies include adopting a simpler classification scheme or focusing on specific SOP subtypes in larger cohort. Finally, the added value of signal analysis methods such as independent component analysis might be worth future investigation, to improve the relevance of scalp SOP⁵⁰.

5. CONCLUSION

Low frequency RSA are the most frequent scalp SOPs in patients with focal MRI-negative epilepsy. A good correlation exists between the scalp and the SEEG SOP if there is no significant delay between clinical and scalp EEG onset. However, in about a quarter of patients, RSA appeared on the scalp several seconds after clinical onset, reflecting the evolution and/or propagation of the SEEG discharge at that time. REDs on the scalp may be evocative of an underlying FCD even in patients with negative MRI. Our findings may help clinicians facing the challenging population of patients with negative MRI. They may be the premise of future studies on ictal electrical source imaging with an improved methodology.

ACKNOWLEDGMENTS

We thank all colleagues involved in our epilepsy centre (Neurology: Agnes Trebuchon, Francesca Bonini, Geraldine Daquin, Lisa Vaugier, Marie Arthuis, Maxime Guye, Isabelle Lambert, Angela Marchi, Nada El Youssef, Sandrine Aubert; Neuropaediatrics: Anne Lépine, Mathieu Milh, Beatrice Desnous; all paramedical staff of the above departments). We thank Serge Vulliemoz and Nicolas Roehri for suggestions and comments on this work. We thank the patients.

SL is supported by grants from the LFCE (*Ligue Française Contre l'Épilepsie*, french chapter of the ILAE) and PHOCEO.

DISCLOSURE OF CONFLICT OF INTEREST

None of the authors has any conflict of interest to disclose. We confirm that we have read the Journal's position on issues involved in ethical publication and affirm that this report is consistent with those guidelines.

REFERENCES

1. Cosandier-Rimélé D, Badier JM, Chauvel P, et al. A physiologically plausible spatio-temporal model for EEG signals recorded with intracerebral electrodes in human partial epilepsy. *IEEE Trans Biomed Eng.* 2007; 54:380–8.
2. Cosandier-Rimélé D, Bartolomei F, Merlet I, et al. Recording of fast activity at the onset of partial seizures: Depth EEG vs. scalp EEG. *Neuroimage.* 2012; 59:3474–87.
3. Lagarde S, Bartolomei F. Focal epilepsies and focal disorders. In: *Handbook of Clinical Neurology.* 1st ed. Elsevier B.V.; 2019. p. 17–43.
4. Tao JX, Baldwin M, Hawes-Ebersole S, et al. Cortical substrates of scalp EEG epileptiform discharges. *J Clin Neurophysiol.* 2007; 24:96–100.
5. Tao JX, Baldwin M, Ray A, et al. The impact of cerebral source area and synchrony on recording scalp electroencephalography ictal patterns. *Epilepsia.* 2007; 48:2167–76.
6. Foldvary N, Klem G, Hammel J, et al. The localizing value of ictal EEG in focal epilepsy. *Neurology.* 2001; 57:2022–8.
7. Lee SK, Kim J-Y, Hong K-S, et al. The Clinical Usefulness of Ictal Surface EEG in Neocortical Epilepsy. *Epilepsia.* 2000; 41:1450–5.
8. Pelliccia V, Mai R, Francione S, et al. Ictal EEG modifications in temporal lobe epilepsy. *Epileptic Disord.* 2013; 15:392–9.
9. Risinger MW, Engel J, Van Ness PC, et al. Ictal localization of temporal lobe seizures with scalp/sphenoidal recordings. *Neurology.* 1989; 39:1288–1288.
10. Worrell GA, So EL, Kazemi J, et al. Focal ictal β discharge on scalp EEG predicts excellent outcome of frontal lobe epilepsy surgery. *Epilepsia.* 2002; 43:277–82.
11. Perucca P, Dubeau F, Gotman J. Intracranial electroencephalographic seizure-onset patterns: Effect of underlying pathology. *Brain.* 2014; 137:183–96.
12. Lagarde S, Buzori S, Trebuchon A, et al. The repertoire of seizure onset patterns in human focal epilepsies: Determinants and prognostic values. *Epilepsia.* 2019; 60:85–95.

13. Singh S, Sandy S, Wiebe S. Ictal onset on intracranial EEG: Do we know it when we see it? State of the evidence. *Epilepsia*. 2015; 56:1629–38.
14. Ebersole JS, Pacia S V. Localization of temporal lobe foci by ictal EEG patterns. *Epilepsia*. 1996; 37:386–99.
15. Lieb JP, Walsh GO, Babb TL, et al. A Comparison of EEG Seizure Patterns Recorded with Surface and Depth Electrodes in Patients with Temporal Lobe Epilepsy. *Epilepsia*. 1976; 17:137–60.
16. Pacia S V., Ebersole JS. Intracranial EEG substrates of scalp ictal patterns from temporal lobe foci. *Epilepsia*. 1997; 38:642–54.
17. Tanaka H, Khoo HM, Dubeau F, et al. Association between scalp and intracerebral electroencephalographic seizure-onset patterns: A study in different lesional pathological substrates. *Epilepsia*. 2018; 59:420–30.
18. Ferrand M, Baumann C, Aron O, et al. Intracerebral Correlates of Scalp EEG Ictal Discharges Based on Simultaneous Stereo-EEG Recordings. *Neurology*. 2023; Publish Ah.
19. Lagarde S, Roehri N, Lambert I, et al. Interictal stereotactic-EEG functional connectivity in refractory focal epilepsies. *Brain*. 2018; :1–15.
20. Medina Villalon S, Paz R, Roehri N, et al. EpiTools, A software suite for presurgical brain mapping in epilepsy: Intracerebral EEG. *J Neurosci Methods*. 2018; 303:7–15.
21. Bartolomei F, Chauvel P, Wendling F. Epileptogenicity of brain structures in human temporal lobe epilepsy: A quantified study from intracerebral EEG. *Brain*. 2008; 131:1818–30.
22. Blümcke I, Thom M, Aronica E, et al. The clinicopathologic spectrum of focal cortical dysplasias: A consensus classification proposed by an ad hoc Task Force of the ILAE Diagnostic Methods Commission. *Epilepsia*. 2011; 52:158–74.
23. Blümcke I, Thom M, Aronica E, et al. International consensus classification of hippocampal sclerosis in temporal lobe epilepsy: A Task Force report from the ILAE Commission on Diagnostic Methods. *Epilepsia*. 2013; 54:1315–29.
24. Engel J. Update on surgical treatment of the epilepsies. Summary of the Second International Palm Desert Conference on the Surgical Treatment of the Epilepsies (1992). *Neurology*. 1993; 43:1612–7.
25. Lagarde S, Scholly J, Popa I, et al. Can histologically normal epileptogenic zone share

- common electrophysiological phenotypes with focal cortical dysplasia ? SEEG - based study in MRI - negative epileptic patients. *J Neurol.* 2019; .
26. Sakai Y, Nagano H, Sakata A, et al. Localization of epileptogenic zone in temporal lobe epilepsy by ictal scalp EEG. *Seizure.* 2002; 11:163–8.
 27. Schiller Y, Cascino GD, Busacker NE, et al. Characterization and comparison of local onset and remote propagated electrographic seizures recorded with intracranial electrodes. *Epilepsia.* 1998; 39:380–8.
 28. Sip V, Schollyl J, Guye M, et al. Evidence for spreading seizure as a cause of theta-Alpha activity electrographic pattern in stereo-EEG seizure recordings. *PLoS Comput Biol.* 2021; 17:1–25.
 29. Caboclo LOSF, Garzon E, Oliveira PAL, et al. Correlation between temporal pole MRI abnormalities and surface ictal EEG patterns in patients with unilateral mesial temporal lobe epilepsy. *Seizure.* 2007; 16:8–16.
 30. Ebner A, Hoppe M. Noninvasive electroencephalography and mesial temporal sclerosis. *J Clin Neurophysiol.* 1995; 12:23–31.
 31. Patariaia E, Lurger S, Serles W, et al. Ictal scalp EEG in unilateral mesial temporal lobe epilepsy. *Epilepsia.* 1998; 39:608–14.
 32. Sirin NG, Gurses C, Bebek N, et al. A Quadruple Examination of Ictal EEG Patterns in Mesial Temporal Lobe Epilepsy With Hippocampal Sclerosis. *J Clin Neurophysiol.* 2013; 30:329–38.
 33. Ray A, Tao JX, Hawes-Ebersole SM, et al. Localizing value of scalp EEG spikes: A simultaneous scalp and intracranial study. *Clin Neurophysiol.* 2007; 118:69–79.
 34. Koessler L, Cecchin T, Colnat-Coulbois S, et al. Catching the Invisible: Mesial Temporal Source Contribution to Simultaneous EEG and SEEG Recordings. *Brain Topogr.* 2015; 28:5–20.
 35. Wendling F, Bartolomei F, Bellanger JJ, et al. Epileptic fast intracerebral EEG activity: Evidence for spatial decorrelation at seizure onset. *Brain.* 2003; 126:1449–59.
 36. Bartolomei F, Wendling F, Régis J, et al. Pre-ictal synchronicity in limbic networks of mesial temporal lobe epilepsy. *Epilepsy Res.* 2004; 61:89–104.
 37. Casale MJ, Marcuse L V., Young JJ, et al. The Sensitivity of Scalp EEG at Detecting Seizures-A Simultaneous Scalp and Stereo EEG Study. *J Clin Neurophysiol.* 2022; 39:78–84.

38. van Mierlo P, Vorderwülbecke BJ, Staljanssens W, et al. Ictal EEG source localization in focal epilepsy: Review and future perspectives. *Clin Neurophysiol.* 2020; 131:2600–16.
39. Huppertz HJ, Grimm C, Fauser S, et al. Enhanced visualization of blurred gray-white matter junctions in focal cortical dysplasia by voxel-based 3D MRI analysis. *Epilepsy Res.* 2005; 67:35–50.
40. Hong SJ, Bernhardt BC, Caldairou B, et al. Multimodal MRI profiling of focal cortical dysplasia type II. *Neurology.* 2017; 88:734–42.
41. Desarnaud S, Mellerio C, Semah F, et al. 18F-FDG PET in drug-resistant epilepsy due to focal cortical dysplasia type 2: additional value of electroclinical data and coregistration with MRI (*European Journal of Nuclear Medicine and Molecular Imaging*, (2018), 45, 8, (1449-1460), 10. Eur J Nucl Med Mol Imaging. 2018; 45:1465.
42. Baud MO, Perneger T, Rácz A, et al. European trends in epilepsy surgery. *Neurology.* 2018; 91:e96–106.
43. Lamberink HJ, Otte WM, Blumcke I, et al. Seizure outcome and use of antiepileptic drugs after epilepsy surgery according to histopathological diagnosis: a retrospective cohort study. *Lancet Neurol.* 2020; 19.
44. Bautista JF, Foldvary-Schaefer N, Bingaman WE, et al. Focal cortical dysplasia and intractable epilepsy in adults: Clinical, EEG, imaging, and surgical features. *Epilepsy Res.* 2003; 55:131–6.
45. Epitashvili N, Antonio-Arce VS, Brandt A, et al. Scalp EEG biomarkers in epilepsy patients with focal cortical dysplasia. *Ann Neurol.* 2018; :1–27.
46. Tassi L, Colombo N, Garbelli R, et al. Focal cortical dysplasia: neuropathological subtypes, EEG, neuroimaging and surgical outcome. *Brain.* 2002; 125:1719–32.
47. Noachtar S, Bilgin Ö, Rémi J, et al. Interictal regional polyspikes in noninvasive EEG suggest cortical dysplasia as etiology of focal epilepsies. *Epilepsia.* 2008; 49:1011–7.
48. Lagarde S, Bonini F, McGonigal A, et al. Seizure-onset patterns in focal cortical dysplasia and neurodevelopmental tumors: Relationship with surgical prognosis and neuropathologic subtypes. *Epilepsia.* 2016; 57:1426–35.
49. Kim DW, Lee SK, Moon HJ, et al. Surgical treatment of nonlesional neocortical epilepsy: Long-term longitudinal study. *JAMA Neurol.* 2017; 74:324–31.
50. Barborica A, Mindruta I, Sheybani L, et al. Extracting seizure onset from surface EEG with independent component analysis: Insights from simultaneous scalp and

intracerebral EEG. *NeuroImage Clin.* 2021; 32.

Accepted Article

TABLES

Table 1. Patients' demographic characteristics

	Total population (n=41)
Gender, male, n	21 (51%)
Age at epilepsy onset, y, median (sd)	12.8 (8.9)
Age at scalp video EEG recording, y, median (sd)	27 (13.8)
Age at SEEG recording, y, median (sd)	28.7 (13.8)
Epilepsy duration before SEEG, y, median (sd)	14.5 (10.3)
Presence of familial history of epilepsy, n (%)	6 (14.6)
Epilepsy type, n (%)	
Mesio-temporal	8 (19.5)
Lateral temporal	6 (14.6)
Mesio-lateral temporal	3 (7.3)
Temporal plus	7 (17.1)
Bitemporal	1 (2.4)
Operculo-insular	5 (12.2)
Frontal	6 (14.6)
Frontal plus	1 (2.4)
Parietal	2 (4.9)
Occipital +	2 (4.9)
Patients who underwent surgery, n (%)	20 (48)
Histology, n/N (%)	
FCD type I	6/20 (30)
FCD type II	3/20 (15)
FCD type III	1/20 (5)
Hippocampal sclerosis	1/20 (5)
Gliosis	5/20 (25)
Aspecific	4/20 (20)
Surgical outcome at last follow-up, n/N (%)	
Engel I	7/20 (35)
Engel II	2/20 (10)
Engel III	3/20 (15)
Engel IV	8/20 (40)

FCD = Focal Cortical Dysplasia

Table 2. Patients with delayed discharge on scalp (n=10)			
SEEG SOP	Delay (t) between clinical and scalp onset (in seconds)	Scalp EEG SOP	Morphology of the SEEG discharge after a time = t
SW	15	RSA	RS
STA	32.5	RSA	STA
LVFA	15	RSA	STA
DB	7.5	RSA	LVFA
SW	9.5	RSA	STA
SW	7.5	RSA	RS
LVFA	5.1	RSA	LVFA
RS	5	RSA	RS
SW	12.1	RSA	STA
SW	10	RSA	STA

SW = Slow wave or baseline shift followed by LVFA; DB = Delta Brush; STA = Sharp theta/alpha activity; RSA = Rhythmic sinusoidal Activity; LVFA = Low Voltage Fast activity; RS = Rhythmic Spikes.

FIGURES LEGENDS

Figure 1. Examples of Scalp EEG SOP:

- A) Rhythmic sinusoidal activity (RSA),
- B) Repetitive epileptiform discharges (RED),
- C) Paroxysmal fast activity (PFA),
- D) Attenuation.

Longitudinal montage, 20 sec per page (1 sec between each orange line), notch filtered (50Hz), high-pass filter (0.53 Hz), low-pass filter 70 Hz). SOP: Seizure Onset Pattern.

Figure 2A. Flow chart showing the inclusion of the patients and the process of defining and matching seizure type on scalp and on SEEG.

Figure 2B. Pie chart representing the prevalence of scalp-EEG SOP.

SOP: Seizure Onset Pattern.

Figure 3A. Histogram showing the overall repartition of the SEEG SOP according to scalp EEG SOP.

LVFA = Low Voltage Fast Activity, SOP: Seizure Onset Pattern.

Figure 3B. Histogram showing the repartition of the SEEG SOP according to scalp EEG only in cases without delay between clinical and scalp onset.

LVFA = Low Voltage Fast Activity.

Figure 4. Histogram showing the repartition of the scalp SOP according to the underlying histology.

FCD = Focal Cortical Dysplasia, SOP: Seizure Onset Pattern.

SUPPORTING INFORMATION

Supplementary Figure 1. Procedure outline for defining seizure types and matching them between scalp-EEG and SEEG.

Supplementary Figure 2. Histogram showing the repartition of the epileptogenic zone (EZ) depth according to the scalp SOP.

SOP: Seizure Onset Pattern.

Supplementary Figure 3. Histogram showing the repartition of the SEEG SOP according to the scalp EEG SOP in the sub-groups of patients with superficial (A) and deep EZ (B).

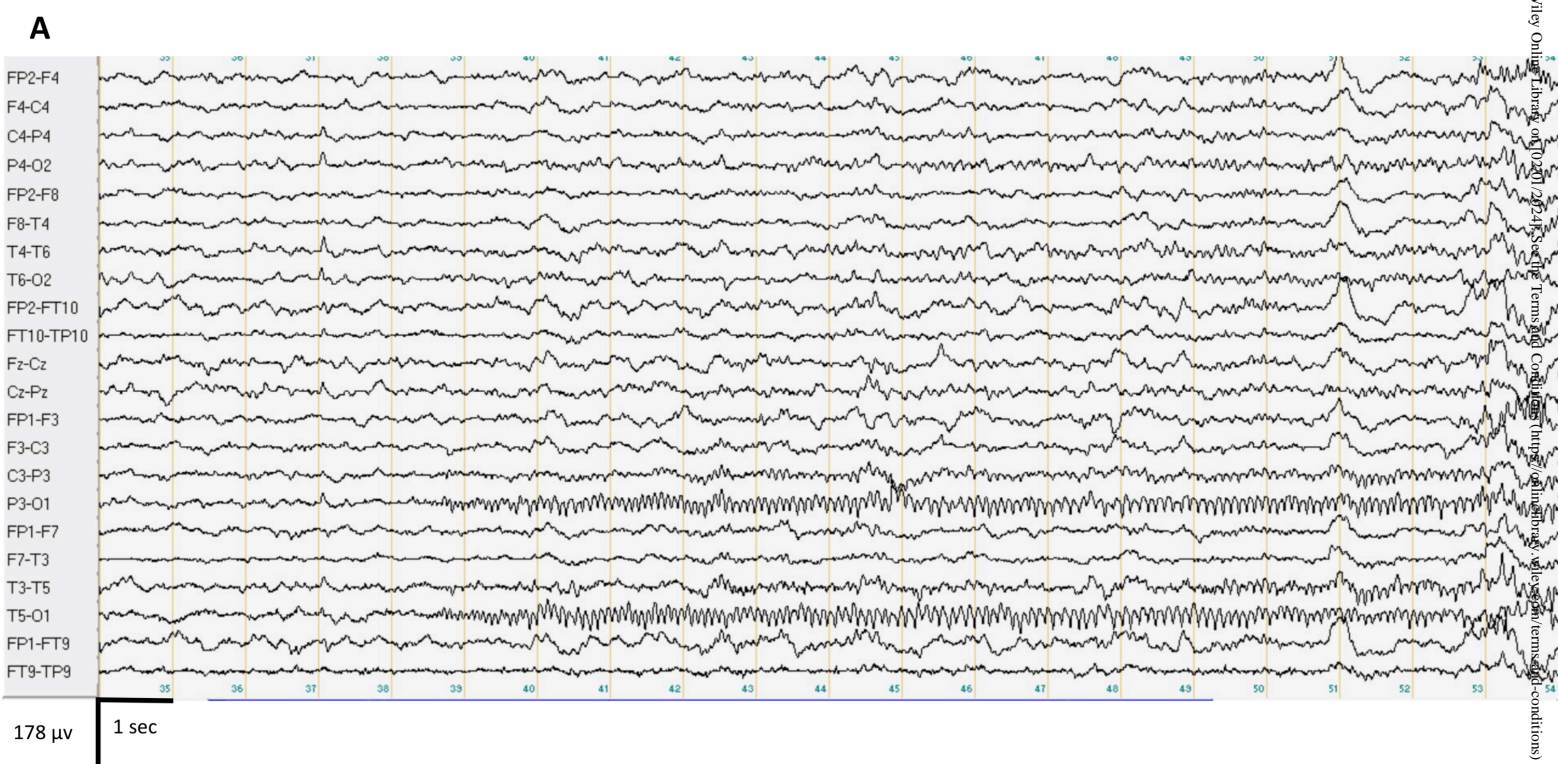
LVFA = Low Voltage Fast Activity, EZ: Epileptogenic Zone, SOP: Seizure Onset Pattern.

Supplementary Figure 4: Histogram showing the repartition of the eligibility to surgery (*contraindicated or not*) according to scalp and SEEG SOP.

SOP: Seizure Onset Pattern.

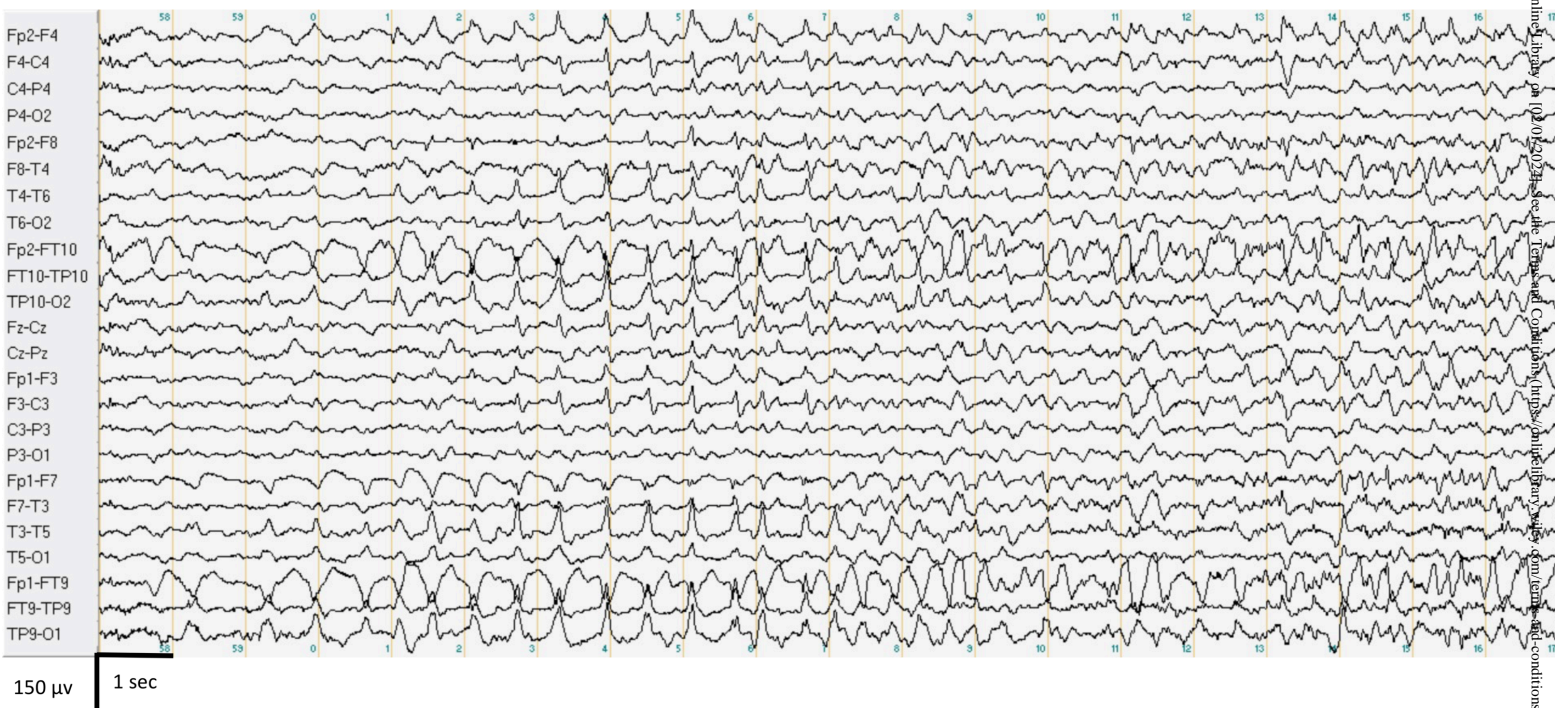Supplementary Figure 5: Histogram showing the repartition of the postsurgical seizure outcome (Engel score) according to scalp and SEEG SOP.

SOP: Seizure Onset Pattern.



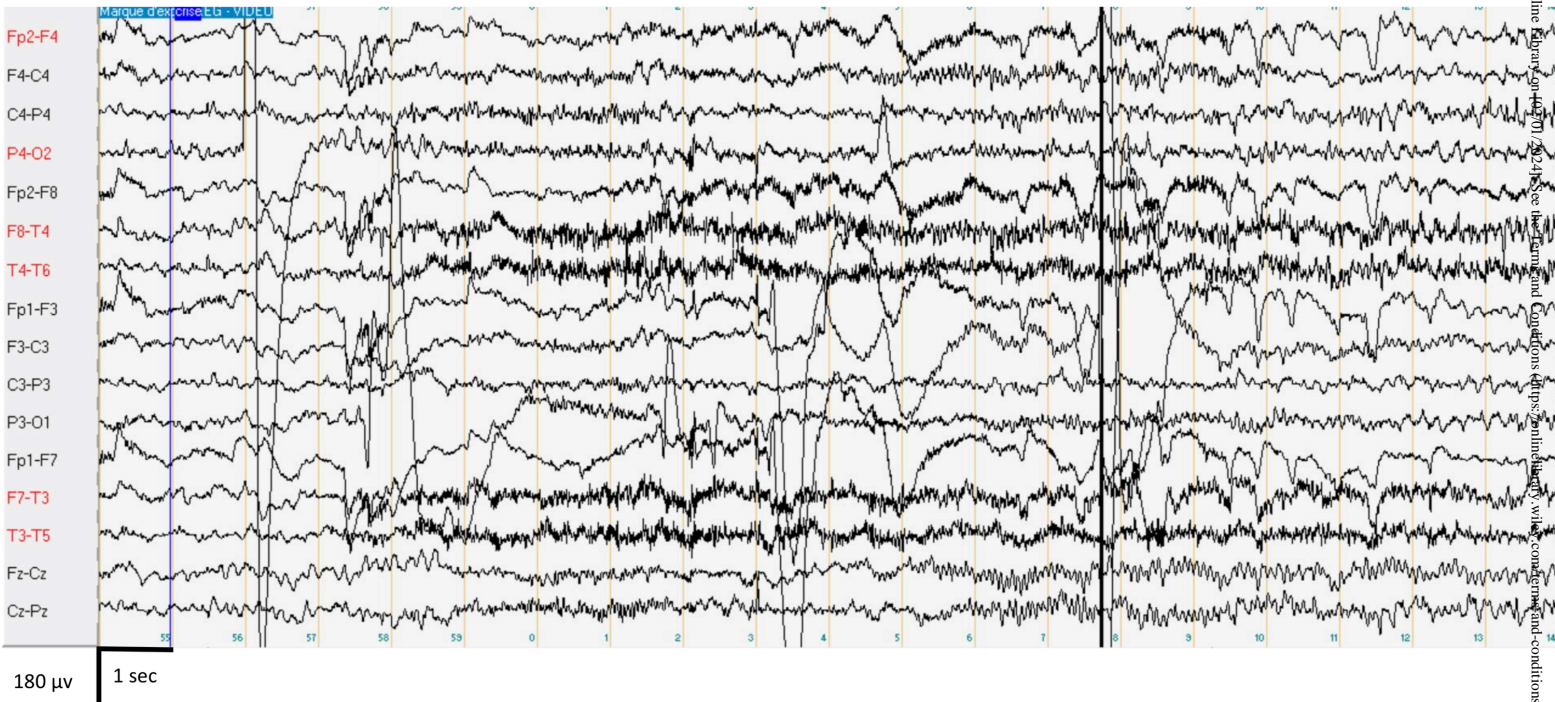
Figures 1A_R1.tiff

B



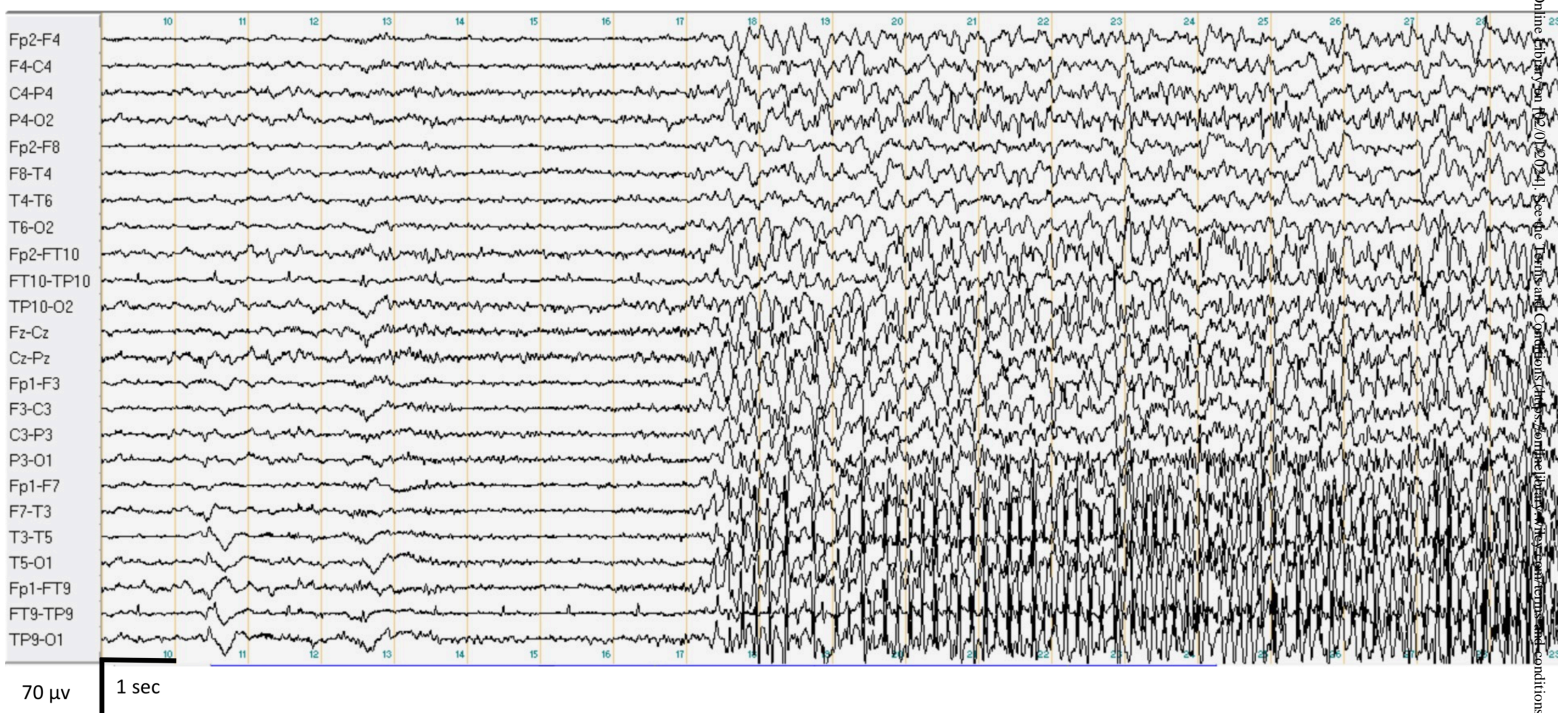
Figures 1B_R1.tiff

C



Figures 1C_R1.tiff

D



Figures 1D_R1.tiff

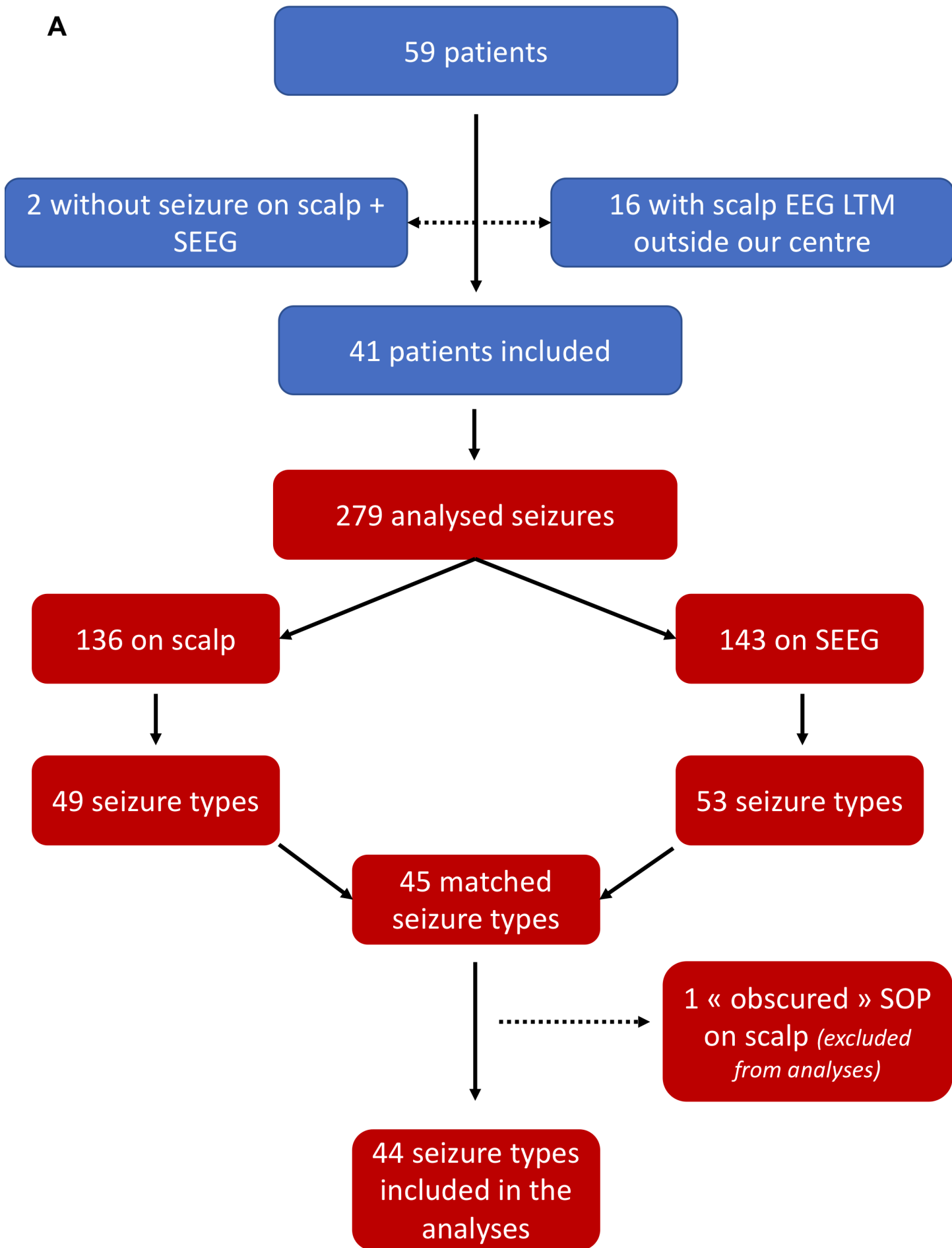
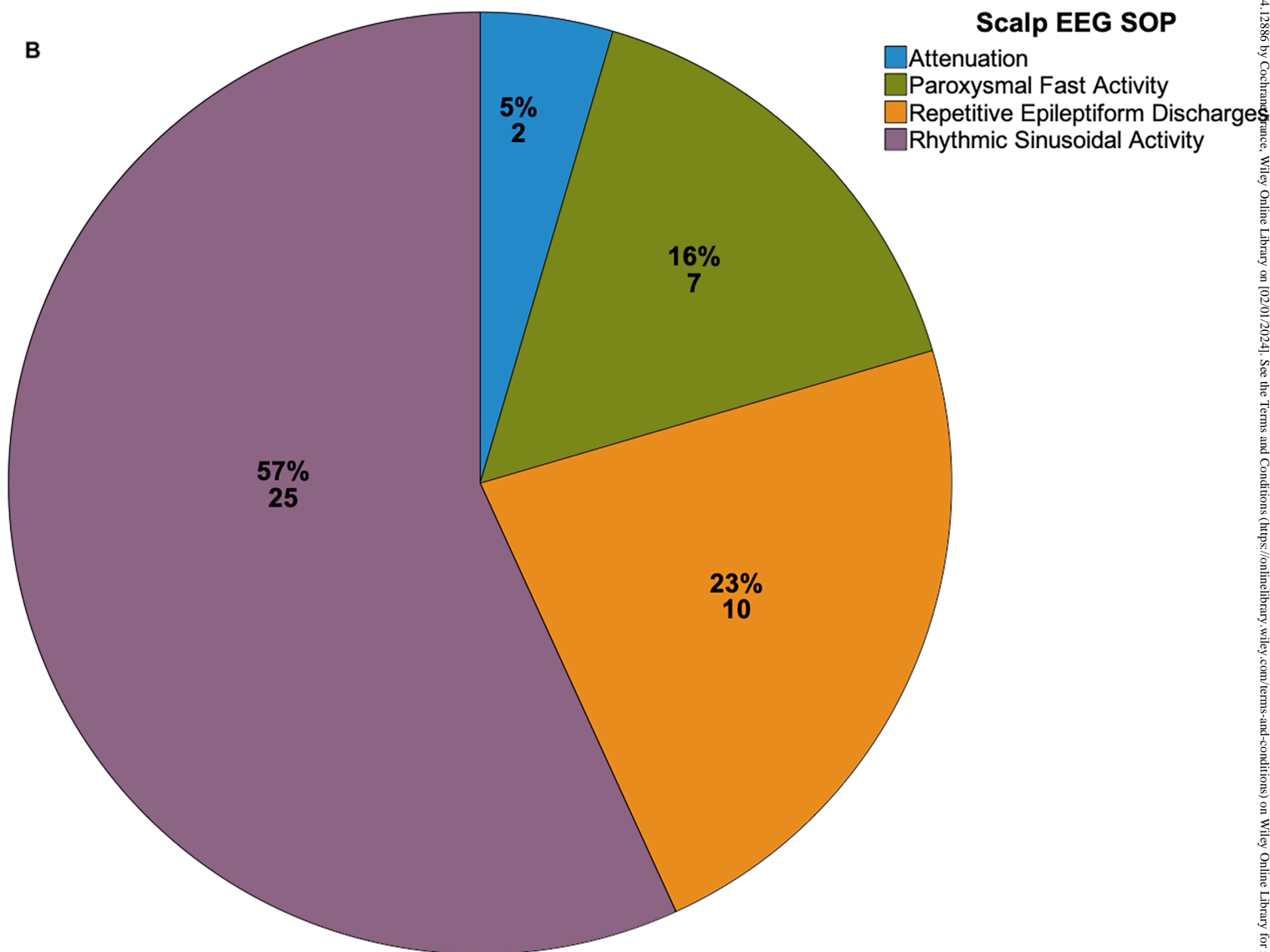
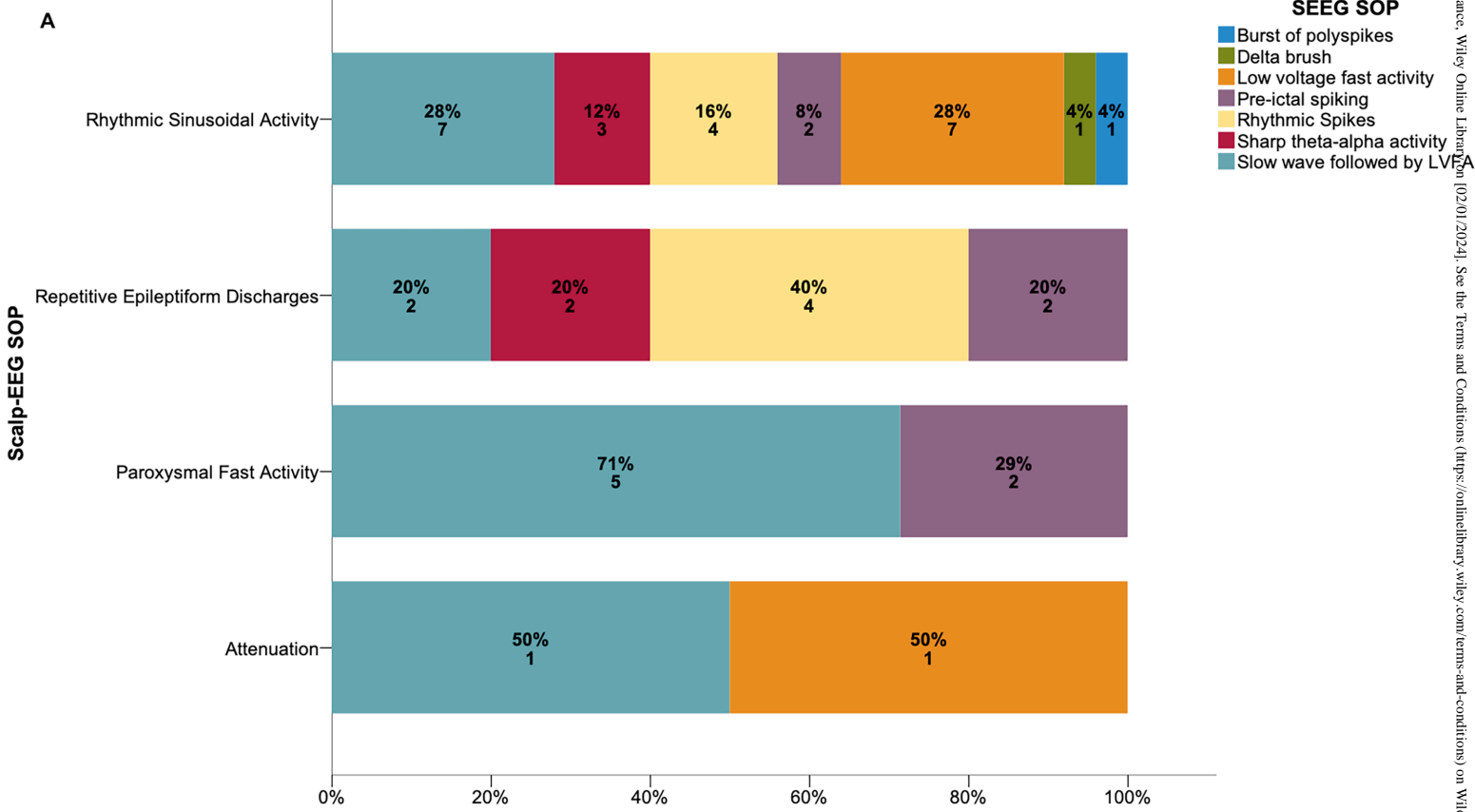


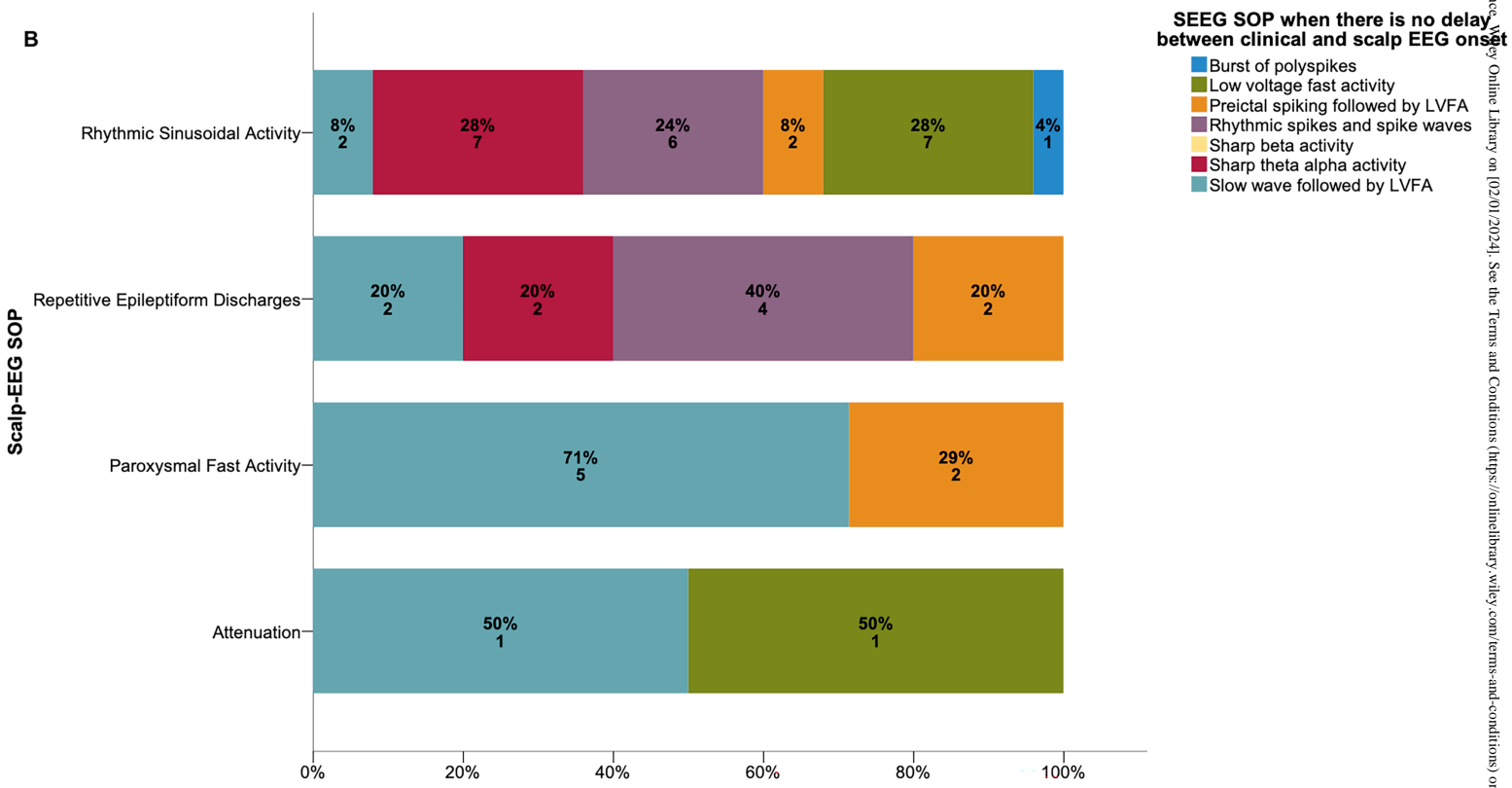
Figure 2A_R1.tiff



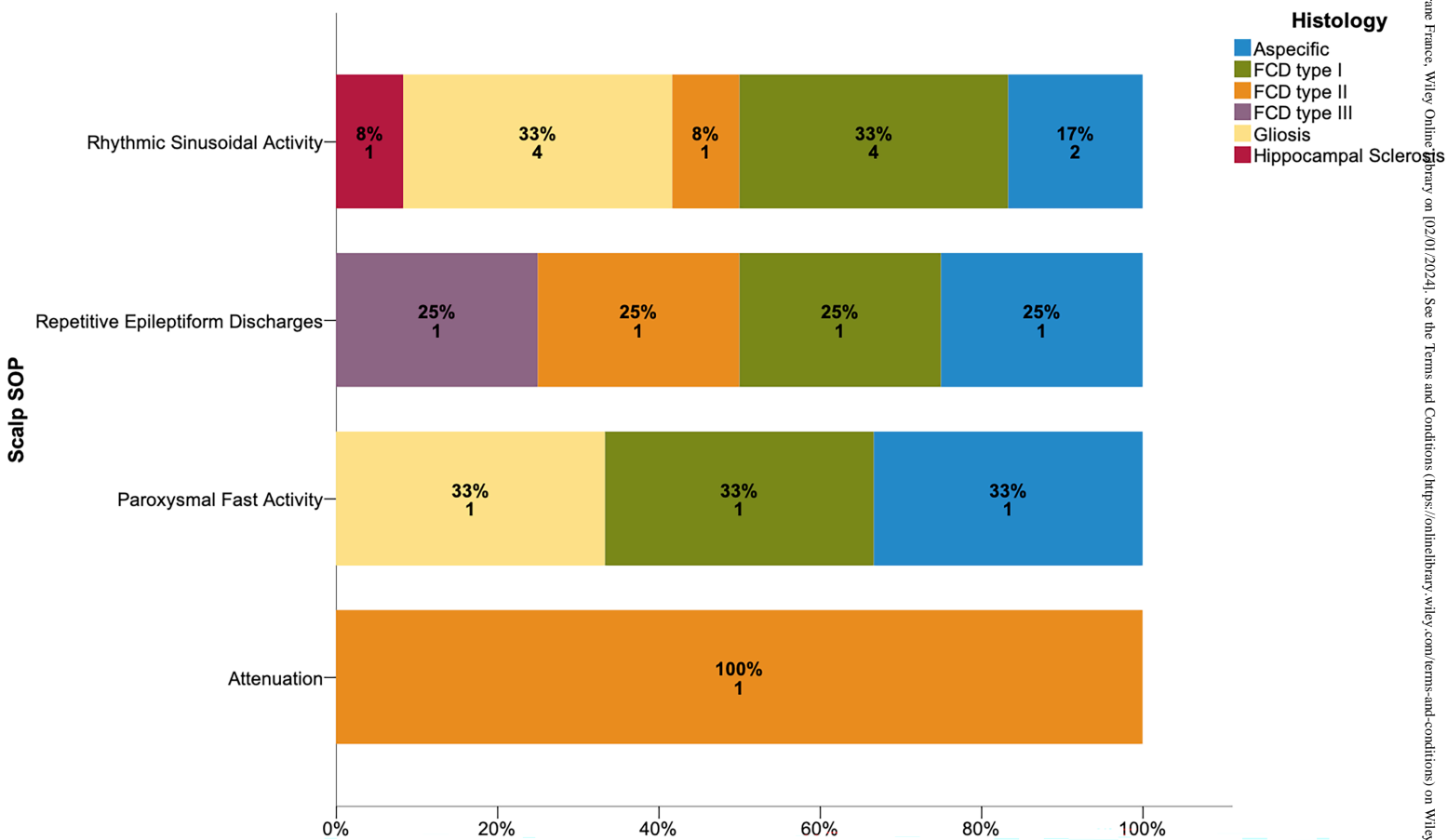
Figure_2B_R1.tiff



Figure_3A_R1.tiff



Figure_3B_R1.tiff



Figure_4_R1.tiff