



HAL
open science

3D inference of the scoliotic spine from depth maps of the back

Nicolas Comte, Sergi Pujades, Aurélien Courvoisier, Olivier Daniel,
Jean-Sébastien Franco, François Faure, Edmond Boyer

► **To cite this version:**

Nicolas Comte, Sergi Pujades, Aurélien Courvoisier, Olivier Daniel, Jean-Sébastien Franco, et al.. 3D inference of the scoliotic spine from depth maps of the back. International Symposium on Computer Methods in Biomechanics and Biomedical Engineering, May 2023, Paris, France. pp.159-168, 10.1007/978-3-031-55315-8_18 . hal-04362152

HAL Id: hal-04362152

<https://hal.science/hal-04362152v1>

Submitted on 22 Dec 2023

HAL is a multi-disciplinary open access archive for the deposit and dissemination of scientific research documents, whether they are published or not. The documents may come from teaching and research institutions in France or abroad, or from public or private research centers.

L'archive ouverte pluridisciplinaire **HAL**, est destinée au dépôt et à la diffusion de documents scientifiques de niveau recherche, publiés ou non, émanant des établissements d'enseignement et de recherche français ou étrangers, des laboratoires publics ou privés.



Distributed under a Creative Commons Attribution - NonCommercial - NoDerivatives 4.0 International License

3D inference of the scoliotic spine from depth maps of the back

Nicolas Comte^{1, 2}, Sergi Pujades², Aurélien Courvoisier^{3, 4}, Olivier Daniel^{3, 4}, Jean-Sébastien Franco², François Faure¹, and Edmond Boyer²

¹*Anatoscope, 38330, Montbonnot-Saint-Martin, France*

²*Univ. Grenoble Alpes, Inria, CNRS, Grenoble INP, LJK, 38000 Grenoble, France*

³*TIMC, University Grenoble Alpes, CNRS, UMR 5525, VetAgro Sup, Grenoble INP, CHU Grenoble Alpes, 38000 Grenoble, France*

⁴*Grenoble Alps Scoliosis and Spine Center, Grenoble Alps University Hospital, Bvd de la Chantourne, CEDEX 09, 38043 Grenoble, France*

Abstract

Recent advances combining outer images and deep-learning algorithms (DLA) show promising results in the detection and the characterization of the Adolescent Idiopathic Scoliosis (AIS). However, these methods are providing a limited 2D characterization while scoliosis is defined in 3D. In this study we propose an inference method that takes as input a depth map of the back of a person and outputs the 3D shape estimation of the thoracolumbar spine. Our DLA method predicts 3D vertebrae positions with an average 3D error of 7.1mm (std: 4.7mm). From the predicted 3D positions, scoliosis can be located and estimated with a mean absolute error (MAE) of 5.5° (std: 6.2°) in the frontal plane. Moreover, sagittal alignments can be estimated with a MAE of 6.4° (std: 5.5°) in kyphosis and 8.3° (std: 6.8°) in lordosis. In addition, our non-ionizing approach can detect scoliosis with an accuracy of 89%.

1 Introduction

Adolescent idiopathic scoliosis (AIS) is a progressive disease mostly affecting young people and evolving during the period of growth [5]. The main recommendation is to use braces to stop scoliosis progression with medical monitoring until the end of the adolescence. Diagnosis and follow-up are usually performed with radiographs by measuring the Cobb Angle at the scoliotic curvature on the coronal plane. This method is highly accurate but it involves multiple radiation exposures which increase the risk of cancer [3][6]. Therefore, there is a strong interest to examine spines using non-invasive and non-ionising methods, especially with young people [10].

In the recent years, deep learning methods based on Convolutional Neural Networks (CNN) showed promising results into the prediction of the Cobb angle from outer images of the back. Yang et al 2019 [16] trained CNN models to classify RGB images of the back according to the scoliosis severity. Kokabu et al 2021 [20] extended the Adam’s forward bend test by the inference of the severity of scoliosis, *i.e.* the main Cobb angle, from depth maps. Watanabe et al. 2019 [17] predicted the coronal spinal alignments from Moiré images and estimate the cobb angles along the predictions. However, these methods are providing a limited 2D characterization of the deformities while scoliosis is inherently a three-dimensional condition [4].

Our hypothesis is that the information present in a depth map of the back of a person has a very strong correlation with the underlying 3D shape of the spine, *i.e.* the 3D location of each vertebra. Thus, a model taking as input a depth map could predict the 3D shape of the spine. The goal of this study is to evaluate such a strategy and its accuracy by comparing the predictions made by the proposed CNN model with real-life measurements of spine positions and curvatures.

2 Data collection and processing

To validate our hypothesis and approach we use two different datasets. One acquired at Grenoble Hospital (GH) and the publicly available NMDID dataset [19].

2.0.1 GH dataset

The study was approved by two Ethical Committees. The GH dataset was collected and published in Courvoisier et al 2019 [18]: CECIC Rhône-Alpes-Auvergne, Clermont-Ferrand, IRB 5891. The IRB for recent cases is CPP Ile de France 2 on the 07/20/2020: no ID RCB: 2020-A01071-38. All parents and patients received an information letter.

Two types of data were collected from 32 patients with AIS (7-16 y. old, 81% females): a 3D surface scan of the back or the torso with an optical scan (ScanGogh II Vorum Research Corporation or the Occipital Structure Sensor Mark II), and the corresponding 3D spine reconstruction obtained from biplanar X-rays with the EOS Imaging systems [7].

As the surface scan and the EOS images were not performed simultaneously, the patient pose can vary between both acquisitions. We therefore added an additional step to adjust the skin surface pose to match the EOS pose. We use a 3D kinematic anatomic model in Sofa [8] which we personalize to the back surface. We then deform the pose of the avatar to match the visual envelope extracted from the biplanar EOS radiographs. The obtained avatar has thus the skin surface in the same pose as the pose observed during the radiographs.

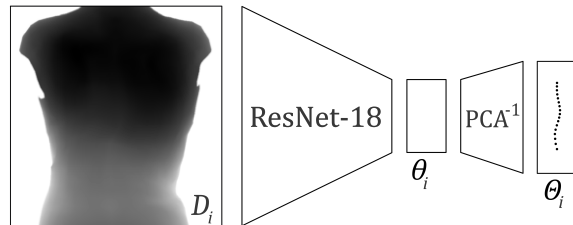


Figure 2: An input depth map D_i is fed into the Resnet that predicts the latent PCA representation θ_i . From θ_i the 3D vertebrae coordinates Θ_i are computed.

2.0.5 Final dataset.

From the NMDID and GH datasets we reconstructed 121 pairs of 3D spines and surfaces of the back: 89 from the NMDID and 32 from GH. The input dataset we consider is therefore composed of 45% females aged between 7 and 30 years old. 38 cases with scoliosis are included in our analysis with different type of curvatures (simple, double curvatures, 10-65°). Fig. 1 illustrates one case of each dataset with the depth map and the 3D characterization of the associated spine.

3 Method

Our method takes as input a depth map of the back of a patient and outputs the 3D location of the thoraco-lumbar vertebrae. To ease the spine prediction we use a low dimensional representation of the spine based on Principal Component Analysis (PCA). Fig. 2 presents the overview of the method.

3.0.1 PCA spine representation.

To ensure that the predicted individual vertebrae create a consistent spine shape, we use a low dimensional representation based on PCA (Principal Component Analysis) [1]. The learned PCA space can produce a compressed latent representation of the spine data, while preserving most of its information and variability. Two main advantages follow. The prediction of the $n_\theta = 20$ PCA coefficients is less complex than the prediction of each of the 17 individual vertebrae 3D locations ($17 \times 3 = 51$). In addition, the compressed latent representation enforces regularization over the estimated spine locations.

3.0.2 Architecture.

We use ResNet-18 [11] model as our backbone CNN architecture, which has been shown to be efficient for regression tasks. It encodes the depth image (224×224 , 1 channel) into the aforementioned latent PCA representation of the spine, which is in turn easily decoded into the 3D vertebrae positions. We train

the network to minimize an L2-loss between the vertebrae coordinates predicted by the neural model, and the annotated coordinates of the training examples. The model is trained using an Adam optimizer with PyTorch [15] with 2000 epochs and a learning rate of 1e-4.

3.0.3 Data Processing.

To structure the dataset and ease the learning task we process the data. Following Choi et al. [12] the depth maps on the spine are centered and cropped according to its length, then resized to a 224×224 resolution. Depth pixel observations are further normalized between $[-1, 1]$, and the antero-posterior positions of the vertebrae are defined with respect to a median vertebra (T08). This 3D transformation allows a simpler representation of the spine while keeping the vertebrae alignment information. It differs from [14] and [21] which are regressing absolute positions.

We augment the dataset applying a random set of different transformations, such as mirroring and rotating the torso in 3D. From the 121 rendered depth maps, the data augmentation raises the amount of images to 10,890.

4 Evaluation

We start by validating the accuracy of the PCA spine representation. Then we evaluate the vertebrae location accuracy by computing the 3D distances between the ground-truth and the predictions as well as 2D distances in the coronal and sagittal planes. We evaluate the spine curvature accuracy by computing the Mean Absolute Error (MAE) in three angles: the main Cobb angle [12], kyphosis (T04-T12) and lordosis (L01-L05). As the 3D predicted spine of our method can also be used for spine classification (main Cobb angle $\geq 10^\circ$) we compute binary classification metrics: sensitivity, specificity, positive predictive value, accuracy and AUC. All our quantitative results are computed using a stratified 20-fold cross-validation (CV) on the full dataset. All metrics are computed by averaging over all test sets.

4.1 PCA dimensional reduction.

A first analysis is dedicated to the PCA and how well the resulting representation is able to encode the vertebra positions. For each fold, the PCA model is learned from the training set and evaluated by comparing the PCA reconstructions of the spines of the test set with their true X-rays reconstructions. Our analysis shows that with 20 components, the spines can be reconstructed with a Mean Absolute Error (MAE) in 3D vertebra location of 0.92mm (std: 0.75 mm) and an MAE in scoliosis severity of 2.71deg (std: 2.49). These values are close to the annotation accuracy (< 1 mm and $< 5^\circ$).

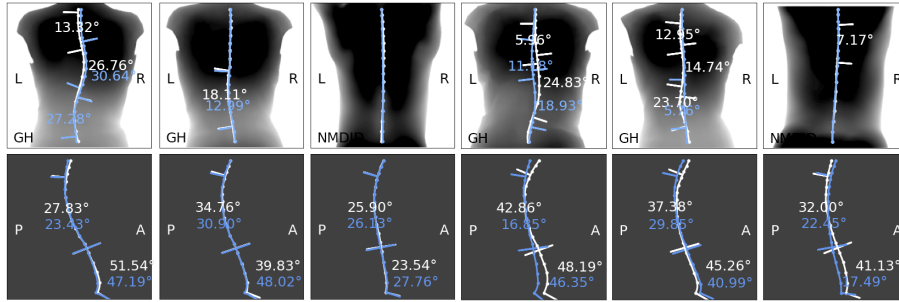


Figure 3: Selection of results. White: ground-truth; blue: predictions. Top row: coronal view for each case, bottom row: sagittal view. GH: institution; NMDID: New Mexico Decedent Image Database; L: Left; R: Right; P: Posterior; A: Anterior.

4.2 3D spine prediction accuracy

4.2.1 Vertebra locations.

MAE of the vertebrae location predictions are reported in Table 1. Our model is able to predict the 3D vertebra positions with an average 3D error below the cm. These predictions allows the characterization of the spinal alignments (scoliosis, kyphosis, lordosis) with automated measurements [12]. Visuals of the predictions are presented in Fig. 3.

4.2.2 Spine 3D characteristics.

Table 1 reports the angle errors between the predicted spine shapes and the ground truth ones. The last three lines of the Table 3) are provided for the comparison with the literature. Note how our approach is the only one predicting kyphosis and lordosis. Numerical results are provided for informative comparison on the range of values, as the considered datasets are different, both in size and population.

4.2.3 Classification.

Classification results are reported in Table 1. Our method is able to discriminate cases with scoliosis with a sensitivity of 64% and a specificity of 99%. We report a positive predictive value of 95%, an accuracy of 89% and an AUC of 90%. Fig. 4 shows the predicted severity against the ground truth one with the 10° classification thresholds. Let us note how several miss-classifications arise near the 10° threshold and the underestimation of moderate and severe scoliosis cases. In conclusions we provide leads to improve these predictions.

Table 1: Spine prediction accuracy. Vertebrae errors in mm of the 3D locations (3D) and 2D coronal (Cor.) and sagittal (Sag.) projections. Angle errors in degrees in the scoliosis severity (Sco. sev.), kyphosis (Kyph.) and lordosis (Lord.). Scoliosis classification ($\geq 10^\circ$) sensitivity (Sens.) and specificity (Spec.).

Study	Locations (mm)			Characteristics ($^\circ$)			Classification	
	3D	Cor.	Sag.	Sco. sev.	Kyph.	Lord.	Sens.	Spec.
Ours	7.07 (4.69)	4.51 (2.99)	5.60 (4.62)	5.46 (6.19)	6.44 (5.49)	8.26 (6.85)	0.64	0.99
[12]	×	5.4 (3.5)	×	3.42 (2.64)	×	×	NA	NA
[16]	×	×	×	×	×	×	0.88	0.84
[20]	×	×	×	[4.4 - 4.7]	×	×	0.99	0.42

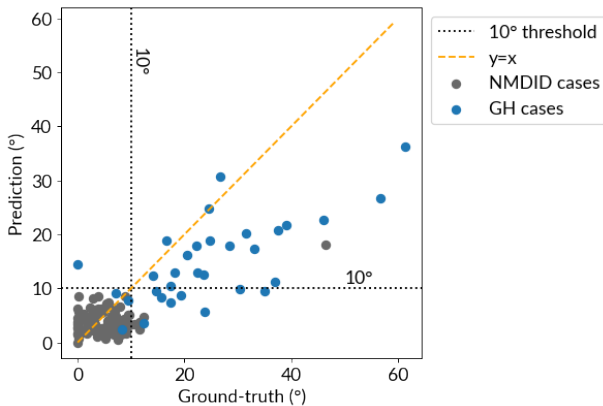


Figure 4: Comparison between predicted scoliosis severity and ground-truth measurements.

4.3 Ablation studies

To further understand the proposed approach we performed two complementary experiments.

Recent work by Klarqvist et al. 2022 [23] has shown that it is possible to estimate body composition from solely body silhouettes. We consider the analogous case for the prediction of the 3D spine: instead to use a depth map as input we consider the case where only the binary silhouette of the back surface is observed.

In addition, we also experiment by training and testing on the two different datasets (GH and NMDID) to see if the imbalance of scoliotic patients in the datasets has an effect on the predictions.

Table 2: Comparison with binarized depth information, i.e. silhouette (silh). MAE (with std.) on locations in 3D, coronal (Cor.) and sagittal (Sag.) plane and the estimated scoliosis severity. Detection is evaluated sensitivity (Sens). and specificity (Spec.).

Type	3D (mm)	Cor. (mm)	Sag. (mm)	Severity (°)	Sens.	Spec.
silh	10.02 (6.96)	4.91 (3.34)	8.55 (7.22)	6.34 (7.86)	0.52	0.98
depth	7.07 (4.69)	4.51 (2.99)	5.60 (4.62)	5.46 (6.19)	0.64	0.99

Table 3: MAE in locations in mm and standard-deviations

Study	Train	Test	3D	Coronal	Sagittal
Ours	GH	GH	8.81 (5.19)	5.87 (3.73)	6.76 (4.97)
Ours	GH+NMDID	GH	8.80 (5.46)	5.90 (3.73)	6.74 (5.26)
Ours	GH+NMDID	NMDID	6.45 (4.21)	4.01 (2.49)	5.19 (4.30)
Ours	GH+NMDID	GH+NMDID	7.07 (4.69)	4.51 (2.99)	5.60 (4.62)

4.3.1 Predictions from binary images.

We tested the impact of depth information by training our model to reconstruct the 3D positions on binary images that show only the silhouette of the torso. The results in Table 2 illustrate that model using depth maps achieves overall better performance. Depth is informative for the network.

It is interesting to note the capability of the silhouette network to reconstruct scoliosis curvatures with a severity error of 6.34°. The biggest difference is obtained in the sagittal plane alignments, which is coherent with the lack of depth information in the binary silhouette image.

4.3.2 Different datasets.

The inclusion of NMDID allows us to validate the approach on asymptomatic cases. However, it could have a negative impact on the prediction of the scoliotic cases by adding bias. We thus evaluate the impact of the NMDID dataset on the network regression performance. We train solely on GH (scoliotic data) and on both GH and NMDID (scoliotic + asymptomatic) data and report the results on Table 3. Including the NMDID cases in the training set does not introduce any bias in the prediction performances (first two lines) on GH subjects and confirms that the inclusion of spines without scoliosis from deceased subjects in supine position does not deteriorate the predictions over living patients acquired with the regular protocol.

5 Conclusion

In this work, we presented an approach to predict the 3D spine shape of a patient from a depth map of the back. This depth map can be obtained with depth sensors, which are usually inexpensive, portable, making them a promising cost-effective, non-ionizing approach to quantify scoliotic deformities. Our approach provides accurate 3D predictions of the vertebrae locations and allows to compute relevant anatomic curvatures along the spine as well as a fast scoliosis diagnosis.

Our presented work predicts 3D vertebrae locations, but does not consider today their individual 3D orientation. It has been studied that the axial vertebra rotation contains information related to the early detection of scoliosis [9] and its evolution [13]. Our approach could be adapted in the future to also predict the orientations of the individual vertebrae. To that end, the PCA representation should be reconsidered, as a linear approach might not be well suited to capture the 3D rotations.

Another venue of improvement of the presented work would be to add more subjects with moderate and severe scoliosis in the training pipeline. As shown in Fig. 4, our model tends to underestimate severe deviations due to the low number of such cases in our dataset. To make this possible, as well as to foster future research in this direction, we make our trained model and training code available for research purposes: https://gitlab.inria.fr/spine/skin_to_spine.

Acknowledgments

This study received support from the ANRT (Association Nationale de la Recherche et de la Technologie) CIFRE No.2019/1197 and the ANR (Agence Nationale de la Recherche) JCJC SEMBA ANR-19-CE23-0003.

References

- [1] Pearson, K.: LIII on lines and planes of closest fit to systems of points in space. The London, Edinburgh, and Dublin Philosophical Magazine and Journal of Science, 2(11), 559-572 (1901). doi:10.1080/14786440109462720
- [2] Lorensen, W.E., Cline, H.E.: Marching cubes: A high resolution 3d surface construction algorithm. ACM SIGGRAPH Computer graphics 21(4), 163-169 (1987). doi:10.1145/37401.37422
- [3] Hoffman, D.A., Lonstein, J.E., Morin, M.M., Visscher, W., Harris III, B.S.H., Boice, J.D. Jr.: Breast Cancer in Women With Scoliosis Exposed to Multiple Diagnostic X Rays. JNCI: Journal of the National Cancer Institute 81(17), 1307-1312 (1989). doi:10.1093/jnci/81.17.1307
- [4] Stokes, I.A.: Three-dimensional terminology of spinal deformity. A report presented to the Scoliosis Research Society by the Scoliosis Research Society

- Working Group on 3-D terminology of spinal deformity. *Spine (Phila Pa 1976)* 19(2), 236-248 (1994).
- [5] Weinstein, S.L., Dolan, L.A., Cheng, J.C., Danielsson, A., Morcuende, J.A.: Adolescent idiopathic scoliosis. *The Lancet* 371(9623), 1527-1537 (2008). doi:10.1016/s0140-6736(08)60658-3
- [6] Ronckers, C.M., Doody, M.M., Lonstein, J.E., Stovall, M., Land, C.E.: Multiple Diagnostic X-rays for Spine Deformities and Risk of Breast Cancer. *Cancer Epidemiol Biomarkers Prev* 17 (3), 605-613. doi:10.1158/1055-9965.EPI-07-2628
- [7] Humbert, L., De Guise, J.A., Godbout, B., Skalli, W.: 3D reconstruction of the spine from biplanar x-rays using parametric models based on transversal and longitudinal inferences. *Medical Engineering & Physics* 31(6), 681-687 (2009). doi:10.1016/j.medengphy.2009.01.003
- [8] Dicko, A.H., Liu, T., Gilles, G., Kavan, L., Faure, F., Palombi, O., Cani, M.P.: Anatomy Transfer. *ACM Transactions on Graphics, ACM SIGGRAPH ASIA*, 32(6), (2013). doi:10.1145/2508363.2508415
- [9] Courvoisier, A., Drevelle, X., Dubousset, J., Skalli, W.: Transverse plane 3D analysis of mild scoliosis. *European Spine Journal* 22(11), 2427-2432 (2013). doi:10.1007/s00586-013-2862-x
- [10] Knott, P., Pappo E., Cameron, M., deMauroy, J.C., Rivard, C., Kotwicki, T., Zaina, F., Wynne, J., Stikeleather, L., Bettany-Saltikov, J., Grivas, T.B., Durmala, J., Maruyama, T., Negrini, S., O'Brien, J.P., Rigo, M.: SOSORT 2012 consensus paper: reducing x-ray exposure in pediatric patients with scoliosis. *Scoliosis* (2014). doi:10.1186/1748-7161-9-4
- [11] He, K., Zhang, X., Ren, S., Sun, J.: Deep residual learning for image recognition. In: *Proceedings of the IEEE Conference on Computer Vision and Pattern Recognition (CVPR)*, 770-778 (2015). doi:10.1109/CVPR.2016.90
- [12] Choi, R., Watanabe, K., Jinguji, H., Fujita, N., Ogura, Y., Demura, S., Kotani, T., Wada, K., Miyazaki, M., Shigematsu, H., Aoki, Y.: CNN-based spine and Cobb angle estimator using moire images. *IEEEJ Trans. Image Electron. Vis. Comput.* 5, 135-144 (2017). doi:10.11371/IEEEJ.5.2_135
- [13] Skalli, W., Vergari, C., Ebermeyer, E., Courtois, I., Drevelle, X., Kohler, R., Abelin-Genevois, K., Dubousset, J.: Early Detection of Progressive Adolescent Idiopathic Scoliosis: A Severity Index. *Spine (Phila Pa 1976)* 42(11), 823-830 (2017). doi:10.1097/BRS.0000000000001961
- [14] Nerot, A., Skalli, W., Wang, X.: Estimation of spinal joint centers from external back profile and anatomical landmarks. *Journal of Biomechanics* 70, 96-101 (2018). doi:10.1016/j.jbiomech.2017.11.013

- [15] Paszke, A., Gross, S., Massa, F., Lerer, A., Bradbury, J., Chanan, G., Killeen, T., Lin, Z., Gimsel, N., Antiga, L., Desmaison, A., Köpf, A., Yang, E., DeVito, Z., Raison, M., Tejani, A., Chilamkurthy, S., Steiner, B., Fang, L., Bai, J., Chintala, S.: Pytorch: An imperative style, high-performance deep learning library (2019). In: Proceedings of the 33rd International Conference on Neural Information Processing Systems, Vancouver, BC, Canada, 8026-8037 (2019). doi:10.48550/arXiv.1912.01703
- [16] Yang, J., Zhang, K., Fan, H., Huang, Z., Xiang, Y., Yang, J., He, L., Zhang, L., Yang, Y., Li, R., Zhu, Y., Chen, C., Liu, F., Yang, H., Deng, Y., Tan, W., Deng, N., Yu, X., Xuan, X., Lin, H. (2019): Development and validation of deep learning algorithms for scoliosis screening using back images. *Communications Biology* 2, 390 (2019). doi:10.1038/s42003-019-0635-8
- [17] Watanabe, K., Aoki, Y., Matsumoto, M.: An application of artificial intelligence to diagnostic imaging of spine disease: Estimating spinal alignment from moiré images. *Neurospine* 16(4), 697-702 (2019). doi:10.14245/ns.1938426.213
- [18] Courvoisier, A., Nesme, M., Gerbelot, J., Moreau-Gaudry, A., Faure, F.: Prediction of brace effect in scoliotic patients: blinded evaluation of a novel brace simulator - an observational cross-sectional study. *Eur. Spine J.* 28, 1277-1285 (2019). doi:10.1007/s00586-019-05948-9
- [19] Edgar, H.J.H., Daneshvari Berry, S., Moes, E., Adolphi, N.L., Bridges, P., Nolte, K.B.: New Mexico Decedent Image Database. Office of the Medical Investigator, University of New Mexico (2020). doi:10.25827/5s8c-n515.
- [20] Kokabu, T., Kanai, S., Kawakami, N., Uno, K., Kotani, T., Suzuki, T., Tachi, H., Abe, Y., Iwasaki, N., Sudo, H.: An algorithm for using deep learning convolutional neural networks with three dimensional depth sensor imaging in scoliosis detection. *Spine Journal* 21, 980-987 (2021). doi:10.1016/j.spinee.2021.01.022
- [21] Caturano, S., Kaiser, M., Bertsch, M., Bassani, T., Taylor, W.R., Ćuković, S.: Prediction of the 3d spinal alignment from external shape of the back in ais patients using regression model. *IEEE 21st Mediterranean Electrotechnical Conference (MELECON)*, 1147-1152 (2022). doi:10.1109/MELECON53508.2022.9843065
- [22] Meng, D., Boyer, E., Pujades, S.: Vertebrae localization, segmentation and identification using a graph optimization and an anatomic consistency cycle. *Comput. Med. Imaging Graph.* 107, 102235 (2023). doi:10.1016/j.compmedimag.2023.102235
- [23] Klarqvist, MDR et al: Silhouette images enable estimation of body fat distribution and associated cardiometabolic risk. *NPJ digital medicine* 5(1), 105 (2022). doi:10.1038/s41746-022-00654-1