



**HAL**  
open science

## Arterial abnormalities identified in kidneys transplanted into children during the COVID-19 pandemic

Laureline Berteloot, Romain Berthaud, Sarah Temmam, Cécile Lozach, Elisa Zanelli, Thomas Blanc, Yves Heloury, Carmen Capito, Christophe Chardot, Sabine Sarnacki, et al.

### ► To cite this version:

Laureline Berteloot, Romain Berthaud, Sarah Temmam, Cécile Lozach, Elisa Zanelli, et al.. Arterial abnormalities identified in kidneys transplanted into children during the COVID-19 pandemic. *American Journal of Transplantation*, 2021, 21 (5), pp.1937-1943. 10.1111/ajt.16464 . hal-04360188

HAL Id: hal-04360188

<https://hal.science/hal-04360188v1>

Submitted on 4 Sep 2024

**HAL** is a multi-disciplinary open access archive for the deposit and dissemination of scientific research documents, whether they are published or not. The documents may come from teaching and research institutions in France or abroad, or from public or private research centers.

L'archive ouverte pluridisciplinaire **HAL**, est destinée au dépôt et à la diffusion de documents scientifiques de niveau recherche, publiés ou non, émanant des établissements d'enseignement et de recherche français ou étrangers, des laboratoires publics ou privés.



Distributed under a Creative Commons Attribution - NonCommercial - NoDerivatives 4.0 International License

## BRIEF COMMUNICATION

# Arterial abnormalities identified in kidneys transplanted into children during the COVID-19 pandemic

Laureline Berteloot<sup>1,2</sup>  | Romain Berthaud<sup>3,4</sup>  | Sarah Temmam<sup>5</sup>  | Cécile Lozach<sup>1,4</sup>  |  
 Elisa Zanelli<sup>1,4</sup> | Thomas Blanc<sup>4,6</sup>  | Yves Heloury<sup>4,6</sup>  | Carmen Capito<sup>6</sup> |  
 Christophe Chardot<sup>4,6</sup> | Sabine Sarnacki<sup>4,6</sup>  | Nicolas Garcelon<sup>7</sup>  | Florence Lacaille<sup>8</sup>  |  
 Marina Charbit<sup>3</sup> | Myriam Pastural<sup>9</sup> | Marion Rabant<sup>4,10,11</sup>  | Nathalie Boddaert<sup>1,2,4</sup>  |  
 Marianne Leruez-Ville<sup>4,12</sup>  | Marc Eloit<sup>5</sup> | Isabelle Sermet-Gaudelus<sup>4,13,14</sup>  |  
 Laurène Dehoux<sup>3</sup> | Olivia Boyer<sup>2,3,4</sup> 

<sup>1</sup>Pediatric Radiology Department, AP-HP, Hôpital Universitaire Necker-Enfants malades, Paris, France

<sup>2</sup>INSERM U1163, Institut Imagine, Paris, France

<sup>3</sup>Pediatric Nephrology Department, MARHEA reference center, AP-HP, Hôpital Universitaire Necker-Enfants malades, Paris, France

<sup>4</sup>Université de Paris, Paris, France

<sup>5</sup>Institut Pasteur, Laboratory of Pathogen Discovery, Paris, France

<sup>6</sup>Pediatric Surgery and Urology Department, AP-HP, Hôpital Universitaire Necker-Enfants malades, Paris, France

<sup>7</sup>Data Science Platform, Paris Descartes—Sorbonne Paris Cite University, Institut Imagine, France

<sup>8</sup>Department of Pediatric Gastroenterology-Hepatology-Nutrition, AP-HP, Hôpital Universitaire Necker-Enfants malades, Paris, France

<sup>9</sup>Agence de la Biomédecine, Saint Denis la Plaine, France

<sup>10</sup>Department of Pathology, APHP, Hôpital Universitaire Necker-Enfants malades, Paris, France

<sup>11</sup>INSERM U1151, Paris, France

<sup>12</sup>Virology Laboratory, APH-HP, Hôpital Universitaire Necker-Enfants malades, Paris, France

<sup>13</sup>EA 7328 University of Paris, Institut Imagine, Paris, France

<sup>14</sup>INSERM U1151, Institut Necker Enfants malades, National Cystic Fibrosis Reference Center, Paris, France

## Correspondence

Laureline Berteloot, Pediatric Radiology Department, Hôpital universitaire Necker Enfants Malades, 149 rue de Sèvres, 75015, Paris, France.  
 Email: laureline.berteloot@aphp.fr

Graft artery stenosis can have a significant short- and long-term negative impact on renal graft function. From the beginning of the COVID-19 pandemic, we noticed an unusual number of graft arterial anomalies following kidney transplant (KTx) in children. Nine children received a KTx at our center between February and July 2020, eight boys and one girl, of median age of 10 years. Seven presented Doppler features suggesting arterial stenosis, with an unusual extensive pattern. For comparison, over the previous 5-year period, persistent spectral Doppler arterial anomalies (focal anastomotic stenoses) following KTx were seen in 5% of children at our center. We retrospectively evidenced severe acute respiratory syndrome coronavirus 2 (SARS-CoV-2) infection in five of seven children with arterial stenosis. The remaining two patients had received a graft from a deceased adolescent donor with a positive serology at D0. These data led us to suspect immune postviral graft vasculitis, triggered

**Abbreviations:** COVID-19, coronavirus disease 2019; eGFR, estimated glomerular filtration rate; KTx, kidney transplant; PSV, peak systolic velocity; RT-PCR, real-time reverse transcriptase polymerase chain reaction; SARS-CoV-2, severe acute respiratory syndrome coronavirus 2.

© 2020 The American Society of Transplantation and the American Society of Transplant Surgeons

by SARS-CoV-2. Because the diagnosis of COVID-19 is challenging in children, we recommend pretransplant monitoring of graft recipients and their parents by monthly RT-PCR and serology. We suggest balancing the risk of postviral graft vasculitis against the risk of prolonged dialysis when considering transplantation in a child during the pandemic.

#### KEYWORDS

clinical research / practice, complication, diagnostic techniques and imaging: ultrasound, infection and infectious agents - viral, infectious disease, kidney disease: immune / inflammatory, kidney transplantation / nephrology, pediatrics, recipient selection

## 1 | INTRODUCTION

The first cases of coronavirus disease 2019 (COVID-19) caused by the severe acute respiratory syndrome coronavirus 2 (SARS-CoV-2) were reported in France at the end of January 2020. The evolution of the pandemic required the lockdown of the population from March 17 to May 11 and reached a first peak around April 8. During the lockdown, nonurgent urological procedures were suspended in children,<sup>1</sup> including transplantation of nonvital organs. Recommendations for donor and recipient selection were gradually implemented and adapted to the epidemic.<sup>2</sup>

Here we report the occurrence of graft vascular anomalies in seven of nine children who received kidney transplant (KTx) at our center since the beginning of the COVID-19 pandemic.

## 2 | MATERIAL AND METHODS

The research was approved by the local Institutional Review Board (IRB registration: #00011928). We included all children aged 0 to 18 years who received a KTx at our center from February to July 2020 ("recent" group). We compared their outcomes to those of pediatric recipients who were transplanted at our center from 2015 to 2019 and presented a vascular complication of their KTx ("historic" group) by querying our local data warehouse, "Dr. Warehouse."<sup>3</sup>

We collected clinical and laboratory data of patients and donors, surgical data, immunosuppressive treatments, imaging features (Doppler-US and angio-CT, if available), and follow-up. We reviewed all Doppler-US examinations from our local Picture Archiving and Communication System (PACS) from the early follow-up (first 3 months post-KTx) and at 2 years, when available. Ultrasound examinations were performed by pediatric radiologists, with General Electric (GE) Healthcare Vivid 5 for bedside ultrasound in continuous care, and GE Logiq E9 in the radiology department. A systematic exploration was performed, including Doppler sampling of the whole graft artery from the anastomosis to the hilum. Arterial stenosis was evidenced by an increase in peak systolic velocity (PSV)  $\geq 250$  cm/sec.<sup>4</sup> The localization and extent of Doppler anomalies were reported. Other ultrasound anomalies were also noted.

In the "recent" group, we retrospectively reviewed the clinical and laboratory data for signs of COVID-19. This included SARS-CoV-2 real-time reverse transcription polymerase chain reaction (RT-PCR) testing from nasopharyngeal and/or throat swabs, which was not systematically performed before the lockdown period. We retrospectively performed SARS-CoV-2 serological testing of recipients and donors, using a luciferase immunoprecipitation assay (LIPS) developed for SARS-CoV-2,<sup>5,6</sup> on sera stored from the day of transplantation, where available. Briefly, recombinant SARS-CoV-2 spike protein (full spike [S] ectodomain, and S1 and S2 subdomains) and nucleoprotein (C-terminal subdomain) were biologically engineered with addition of the nanoluciferase. Recombinant antigens were mixed with patient sera, and immune complexes were immunoprecipitated with protein A/G-coated beads. Preepidemic adult and pediatric sera were used as negative controls to define a positivity threshold for each assay. LIPS sensitivity ranged from 53.3% (LIPS-S1) and 79.8% (LIPS-S2) to 99.4% (LIPS-full S) and 83.1% (LIPS-N), while the positivity threshold was defined to reach 100% of specificity for each LIPS assay.

## 3 | RESULTS

### 3.1 | Case descriptions—"recent" group

From February 2020, nine children received a KTx (8/9) or combined liver-KTx (1/9) at our center. There were eight boys and one girl, with a median [min-max] age of 10 years [3-17]. Five patients received their KTx prior to the lockdown period, between the end of February and mid-March. As shown in Table 1, the underlying diseases that led to KTx were heterogeneous. The median [min-max] age of donors was 16 years [3-39]. Six donors were under 18 years of age. No donor had any underlying disease. Four different surgical teams performed transplantation in these nine children. The teams were the same as in the previous 5-year period and their techniques did not change. The median warm ischemia time was 60 minutes [46-82].

As early as the end of March, we noticed the occurrence of graft vascular anomalies during the systematic early follow-up. Indeed, seven recipients presented spectral Doppler anomalies suggestive of arterial stenosis. The pathologic increase in PSV affected at least

**TABLE 1** Clinical and Doppler data of children who received a kidney transplant (KTx) during the COVID-19 pandemic (1-9) and of children reported to have had spectral Doppler arterial anomalies of their KTx during the previous 5 years (among 79 children who received KTx) (10-16)

Period of KTx	Patient	Etiology	Gender	Age at KTx	Donor	Delay (days)	PSV	Localization	Follow-up / days	Hypertension
2020 postlockdown	1	Urological A	M	10	Deceased	13	260	middle third	resolving / 43	Moderate
	2	HUS	M	12	Deceased	-	197 normal	-	normal / 49	Moderate (preexisting)
	3	CKDu	M	9	Deceased	-	99 normal	-	normal / 143	Moderate (from D1-D60)
	4	Denys-Drash sd	M	4	Deceased	11	280	proximal and middle third	resolving / 104	No
2020 prelockdown	5 <sup>a</sup>	Nephronophthisis	M	5	Deceased	13	250	middle third	persistent / 28	No
	6	HUS - 2nd graft	M	17	Deceased	33	280	proximal third	persistent / 50	No
	7	Nephrotic Sd	M	3	Living-related	8	370	diffuse	persistent / 170	Moderate (preexisting)
	8	CKDu	F	15	Deceased	9	280	middle third	persistent / 82	Severe
	9	Urological A	M	17	Deceased	39	402	diffuse	persistent / 70	Moderate (preexisting)
2015-2019	10	Williams-Beuren sd	M	18	Deceased	2	252	anastomosis	resolving / 2	No
	11	Nephrotic Sd	M	4	Deceased	7	250	anastomosis	persistent / 30 / 90	Moderate
	12	CKDu	F	13	Deceased	1	272	anastomosis	resolving / 2 - recurrence at 2 years	No
	13	Urological A	M	2	Deceased	4	Thrombosis	-	-	Moderate (preexisting)
	14	Denys-Drash sd	F	3	Deceased	1	330	anastomosis	resolving / 2	No
	15	Denys-Drash sd	F	15	Deceased	17	350	anastomosis	persistent / 30 / 90 and at 2 years	Moderate
16	Ciliopathy	F	7	Deceased	3	270	anastomosis	persistent / 30 / 90 and at 2 years	No	

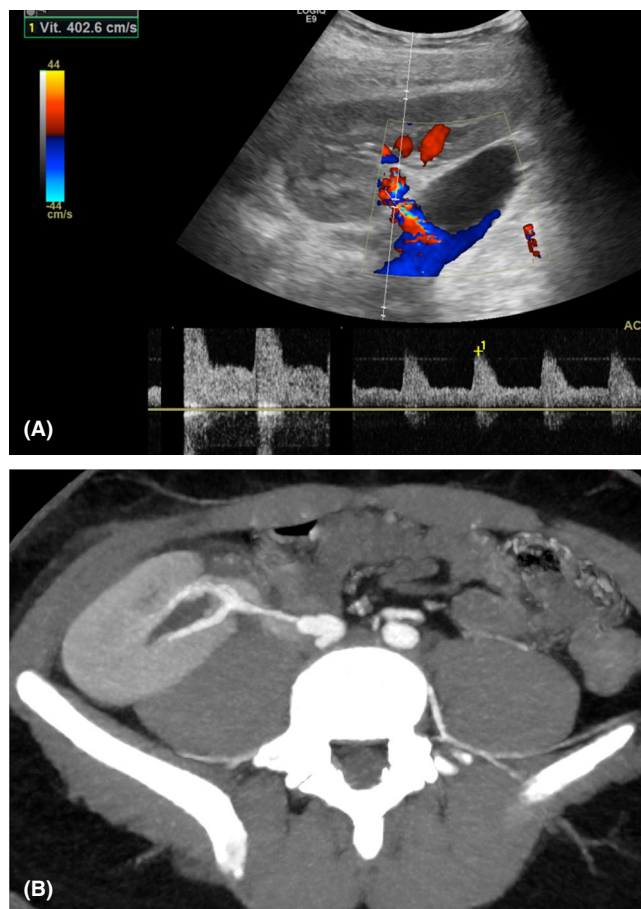
CKDu, chronic kidney disease of unknown etiology; Follow-up/days, follow-up by Doppler since first anomalies were found; HUS, hemolytic and uremic; KTx, kidney transplantation; PSV, maximum peak systolic velocity recorded during follow-up; sd, syndrome; urological A, urological anomalies.

<sup>a</sup>Liver and kidney transplan

one third of the artery, and in three children the anomalies affected more than one third of the artery (Table 1, Figure 1A). We performed an angio-CT scan on five children: patients 5 and 9 presented a thin and irregular artery (Figure 1B), patient 6 had an anastomotic stenosis and an irregular shape of the segmental arteries, and patients 1 and 8 had an irregular shape of the middle third of the artery. Patient 5 also presented Doppler anomalies of his two liver graft arteries, which appeared filiform and irregular on the angio-CT.

In addition, five children had lymphoceles, which required surgical management. No urological anomalies were found. We questioned the French Biomedicines Agency and no vascular anomalies were detected in the deceased donors' contralateral kidneys.

Clinically, six children had arterial hypertension, which was medically controlled. Estimated glomerular filtration rate (eGFR) did not decrease after the onset of the arterial anomaly, except in patient 9 whose eGFR dropped from 52 ml/min/1.73 m<sup>2</sup> at the time of serum creatinine nadir to 45.7 ml/min/1.73 m<sup>2</sup>. None of the patients had significant hematuria or proteinuria. None had signs of rejection on the graft biopsy (Table 2).



**FIGURE 1** Images from the follow-up after KTx in patient 9. (A) The Doppler study shows diffuse aliasing artifacts, with a pathological increase in peak systolic velocity extended throughout the graft artery, including downstream of the zone of contact with the lymphocele. (B) The angio-CT scan confirms the presence of extensive stenosis, with a diffuse, thin and irregular appearance of the artery [Color figure can be viewed at [wileyonlinelibrary.com](http://wileyonlinelibrary.com)]

In the absence of major changes in laboratory findings or resistant arterial hypertension, conservative management of these arterial anomalies was decided. Patients were closely monitored, in particular by a weekly Doppler-US examination during at least the first month following the KTx. Patients 1 and 4 recovered, with normal Doppler-US findings on day 43 and 104, respectively. So far, after a median follow-up of 70 days [28 – 170], none of the other patients has normal Doppler-US findings.

### 3.2 | Comparison with the previous 5-year period—“historic” group

Among the 79 children who received a KTx from January 2015 to January 2020, seven had Doppler-US arterial anomalies during their early follow-up (Table 1). A 2-year-old boy (patient 13) presented with arterial thrombosis and partial graft necrosis 4 days after KTx. The other six patients had a focal increase in PSV at the anastomosis. In three of them, this spontaneously regressed within 24 to 48 hours after it was detected, one with a late recurrence 2 years after KTx (Table 1). Three patients presented persistent anomalies after 1 month of follow-up. None of them had any associated lymphocele. In summary, over the previous 5 years, the rate of persistent arterial stenosis was 5%. Stenosis was focal and localized at the anastomosis and was not associated with lymphocele in any case. During the same 5-year period, our database revealed that only one patient required surgical management for a graft lymphocele.

The median age of donors (17 years [2–52]) and warm ischemia time (1:04 [0:25–1:50]) in the “historic” group were not significantly different from those of the “recent” group,  $p = .52$  and  $p = .56$ , respectively (Wilcoxon rank sum test). Graft-preserving solutions as well as induction and immunosuppression protocols were similar between the two periods (Table 1 in supplementary content).

### 3.3 | Virological and serological assessment of SARS-CoV-2 in the “recent” group

The number and unusual pattern of Doppler anomalies that emerged from March 2020 onward led us to consider a possible relationship with SARS-CoV-2 infection.

None of the patients had reported any symptom suggestive of COVID-19. All children had an elevated CRP peak at D1 or D2 following KTx (18 to 130 mg/L) which decreased within 4 days except for patient 5 who had elevated CRP for 3 weeks following a combined liver-KTx. Ferritin was elevated at D0 in most children and slowly decreased afterward.

Patient 2 had had a positive routine nasopharyngeal-swab SARS-CoV-2 RT-PCR, performed 3.5 months before he received KTx. His RT-PCR was negative 15 days after. Patient 8 had a positive RT-PCR at D7.

The results of serological testing in recipients and donors are shown in Table 2, and detailed in Table 2 in supplementary content.

**TABLE 2** Results of the RT-PCR and serological testing for SARS-CoV-2 of recipients and donors. Laboratory data, associated ultrasound anomalies, and histologic results from renal transplant biopsy in children who received a kidney transplant (KTx) during the COVID-19 pandemic (1–6)

Patient	Stenosis	Lymphocele	RT-PCR		LIPS	CRP	Ferritin	Histology	eGFR (fu)	
			Donor	Recipient						
1	Yes	No	Neg	Pos	Neg	Neg	11	NA	No anomaly	83
2	No	Yes	Neg	Neg	Pos D-105	Pos	43	430	Tubular-interstitial infiltration <10%	89
3	No	No	Neg	Neg	Neg	Pos	27	123	No anomaly except microcalcifications <sup>a</sup>	94
4	Yes	Yes	Neg	Neg	Neg	Pos	22	892	No anomaly	125
5	Yes	No	NA	Neg	Neg	Pos	85	289	No anomaly	111
6	Yes	Yes	NA	Neg	Neg	Pos	131	243	No anomaly	36
7	Yes	Yes	Neg	Neg	Neg	Pos	52	162	ATN moderate, few ischemic glomeruli	128
8	Yes	No	NA	Neg	Pos D7	NA	55	696	No anomaly except microcalcifications <sup>a</sup>	81
9	Yes	Yes	NA	Borderline	Neg	Neg	56	163	No anomaly	46

Abbreviations: ATN, acute tubular necrosis; CRP, C-reactive protein; eGFR (fu), estimated glomerular filtration rate at last follow-up. Dotted line, patients having received their KTx during the pre- and postlockdown period (patients 5–9 and 1–4, respectively); LIPS, luciferase immunoprecipitation assay systems; NA, nonavailable (test not performed or serum not available); Neg, results of the test negative; Pos, results of the test positive; RT-PCR, real-time reverse transcription polymerase chain reaction.

<sup>a</sup>In the setting of transient hypercalciuria and hyperparathyroidism

Patients 2, 3, 4, 5, 6, and 7 developed antibodies against the SARS-CoV-2 S2 subdomain. Patient 2 developed an additional antibody response against the SARS-CoV-2 S1 subdomain and the full S ectodomain. For patient 8, the serum stored on the day of KTx was not sufficient for serological testing. The donors of patients 1 and 9 (who had arterial stenosis and negative SARS-CoV-2 serology at D0) had a positive and borderline serology, respectively, on the day of KTx. These were two asymptomatic adolescent donors.

For clarity, Doppler, RT-PCR, and/or serology results in patients and their donors are schematized in Supplementary Figure 1.

## 4 | DISCUSSION

We report SARS-CoV-2-related graft vascular stenosis, in children who received KTx during the early phase of the COVID-19 pandemic. Although the patients from the present study did not require invasive therapeutic procedures on their arteries, the evolution of their graft function is not yet known. Hence, we want to raise the awareness in the international community about the possible occurrence of these anomalies, while the COVID-19 pandemic is still ongoing.

No child from the present series experienced any symptomatic form or multisystem inflammatory syndrome (MIC-S) of COVID-19. Indeed, the two patients with a positive RT-PCR were completely asymptomatic at the time of sampling performed as part of routine assessment. While adult kidney transplant recipients appear to be at high risk for critical COVID-19 illness and kidney injury,<sup>7–9</sup> such data have not been reported in children. We currently know that the vast majority of children remain asymptomatic or with mild, nonspecific

symptoms. This has also been reported in children receiving immunosuppressive treatments.<sup>10</sup> Moreover, five of the six patients with a positive serology presented an isolated anti-S2 response. In a previous study, this antibody profile, associated with the presence of neutralizing antibodies in 20% of cases, was reported to be more prevalent in asymptomatic or nonspecific forms of COVID-19 in children as compared to MIC-S.<sup>5</sup>

Five of the seven children with arterial anomalies have had a proven SARS-CoV-2 infection as assessed by RT-PCR at D7 in patient 8, and by retrospective serological testing (patients 4–7). No serum was available at D0 for patient 8 and the serum tested at D50 was negative. As the titer of antibodies may decrease in some patients after the KTx, one hypothesis is that immunosuppressive therapies may have altered the reliability of serological tests.<sup>11</sup> The two remaining children (patients 1 and 9) had similar atypical US-Doppler and angio-CT graft arterial anomalies, while sera from D1 and D14 (patient 1) and D55 (patient 9) were negative. Interestingly, the sera of their donors were tested as positive and borderline, respectively.

The mechanisms that could have led to vascular damage in the present series of recent pediatric KTx recipients are not known. COVID-19-related endothelial inflammation has been reported in different organs in adults,<sup>12</sup> in particular in the kidney,<sup>13</sup> with signs of direct viral infection on electron microscopy and diffuse endothelial inflammation on histology, at the acute phase. The phenotype in children seems to be rather different. Indeed, postviral immunological reactions are suspected in formerly asymptomatic children with SARS-CoV-2-related skin vasculitis,<sup>14</sup> and in children with Kawasaki-like MIS-C.<sup>15,16</sup> In most of these children, symptoms develop when RT-PCR is negative and serology is positive.

Similarly, in the present series, antibodies were identified in some children at D0. Moreover, histologic analysis of children's graft in our group did not corroborate with the findings reported in adults with acute COVID-19-related kidney injury.<sup>12,13,17</sup> One hypothesis could be that postviral immunological SARS-CoV-2-related local inflammation may have worsened the postgraft inflammation on the artery, in our group of children. Indeed, they had unusual patterns of stenosis, which were extensive and not limited to anastomosis. Moreover, angio-CT showed a diffuse irregular appearance of the arterial lumens. So, immune vasculitis, triggered by SARS-CoV-2, can be suspected.

The observations of the two seronegative patients with arterial anomalies and seropositive asymptomatic teenage donors may indicate preexisting COVID-19-related endothelial lesions in the donor, not visible at the time of transplantation and which worsened postoperatively in the recipient.

Conversely, two recipients with a positive serology at D0 did not exhibit graft arterial anomalies. It is now known that there is large interindividual variability in SARS-CoV-2-related damage. However, this observation suggests that the interval between SARS-CoV-2 infection and KTx may influence the risk of developing arterial graft stenosis. Indeed, five patients with arterial anomalies received their KTx prior to the mid-March lockdown, less than 2 months after the first local cases were reported in our center's area. At that time, the virus circulation was high in our center's area and decreased drastically after lockdown, as evidenced by RT-PCR analysis of wastewater.<sup>18</sup> Moreover, resources available for diagnosis and protection of health-care workers and patients were insufficient. We believe that frequent visits to the hospital, especially for hemodialysis sessions in open-space rooms,<sup>19</sup> may have increased the risk of exposure to the virus. Furthermore, one of the two children with proven SARS-CoV-2 infection and no arterial anomaly had contracted the virus 3.5 months prior to the transplant, as assessed by positive RT-PCR. For the second child, we have no indication of the time interval between the infection and KTx. However, since he received his transplant after the end of lockdown when the circulation of the virus was low, we may hypothesize that his risk of exposure to the virus was higher more than 2 months earlier, before lockdown.

The diagnosis of COVID-19 is challenging in children. While the false-negative rate of a single nasal swab is reported to be as high as 37% in adults, no study has given a precise indication of the sensitivity of RT-PCR in children.<sup>20</sup> Most studies based on RT-PCR probably underestimate the prevalence of SARS-CoV-2-infection in children, because of issues of timing and nontesting of asymptomatic individuals. This is suggested by comparing studies of similar time periods and populations of children referred for reasons other than suspicion of COVID-19. One study reported a prevalence of positive SARS-CoV-2 RT-PCR in children across the United States of 0.65% (95% CI, 0.47%-0.83%).<sup>21</sup> Conversely, two studies reported seroprevalence ranging from 6.9% in the United Kingdom<sup>22</sup> to 11.7% in our center.<sup>5</sup> A study performed with concomitant RT-PCR and serologic testing reported RT-PCR positivity in 1.8% of cases and positive serology in 10.7% of cases.<sup>23</sup> In these studies, more than 50% of seropositive

children did not report any history consistent with COVID-19 infection. The others reported subtle and nonspecific symptoms. Although there can be a temporal bias, the discrepancy in prevalence between RT-PCR and serologic tests strongly suggests a low sensitivity of clinical history and RT-PCR results in identifying an active infection by SARS-CoV-2 in children. This was demonstrated in two parents with PCR-confirmed symptomatic COVID-19 and their three children, who repeatedly tested negative for SARS-CoV-2 by PCR, even though they developed antibodies.<sup>24</sup> Consistently, a history of contact with a suspected or proven COVID-19 household was the main risk factor for a positive serology in the three abovementioned seroprevalence studies performed in children.<sup>5,22,23</sup> Therefore, assessing all members of the recipient's household could increase the probability of detecting an active or recent infection.

In conclusion, our case series suggests a risk of postviral kidney graft vasculitis in children with a recent SARS-CoV-2 infection. Because the diagnosis of COVID-19 is challenging in children, we recommend viral monitoring of pediatric patients on the transplantation waiting list and of their parents by monthly combined serological and RT-PCR tests. We are now conducting a multicenter prospective study to investigate the prevalence, risk factors, cytokine profile, and outcomes of postviral kidney graft vasculitis. These results are critical for guidance of the management of pediatric KTx during the coronavirus pandemic, especially in the event of recent COVID-19 in the recipient, the parents or the donor. Pending these results, we propose that the decision to perform a KTx in a child during the pandemic should be taken on a case-by-case basis. The prevalence of COVID-19 in the area, the results of the SARS-CoV-2 pretransplant monitoring of the patient and parents, and the benefit-to-risk ratio of prolonged dialysis as compared to potential SARS-CoV-2-related allograft arterial defects should be taken into account. We suggest that KTx should be delayed for at least 2 months after a proven COVID-19 infection in the household. For living donor transplantation, a "shelter-in-place" protocol for recipients and their household for the same time period could be implemented. Supportive therapies against immunological SARS-CoV-2-related inflammation and vascular complications could also be discussed.

#### ACKNOWLEDGMENTS

The authors thank parents and their children who participated to this study. They thank the Institut Pasteur and the virology departments at the University Hospitals of Anger, Créteil, Le Havre, Hospice Civils de Lyon, Montpellier (CHU Lapeyronie), Necker, Rennes, and Tour. They extend their thanks to Dr Dominique Challine, Dr Maude Bouscambet-Duchamp, Dr Anne-Marie Mondain, Tiffany Guillemot, Dr Gisèle Lagathu, and Dr Julien Marlet. And to Pr Riccardo Percudani (University of Parma, Italy).

#### DISCLOSURE

The authors of this manuscript have no conflicts of interest to disclose as described by the *American Journal of Transplantation*.

#### DATA AVAILABILITY STATEMENT

Data available on request due to privacy/ethical restrictions.

## ORCID

Laureline Berteloot  <https://orcid.org/0000-0001-9681-3142>

Romain Berthaud  <https://orcid.org/0000-0003-0165-7947>

Sarah Temmam  <https://orcid.org/0000-0003-3655-9220>

Cécile Lozach  <https://orcid.org/0000-0002-0366-8984>

Thomas Blanc  <https://orcid.org/0000-0002-5829-8167>

Yves Heloury  <https://orcid.org/0000-0003-0843-3970>

Sabine Sarnacki  <https://orcid.org/0000-0003-4304-5578>

Nicolas Garcelon  <https://orcid.org/0000-0002-3326-2811>

Florence Lacaille  <https://orcid.org/0000-0002-5272-4970>

Marion Rabant  <https://orcid.org/0000-0001-5696-6478>

Nathalie Boddaert  <https://orcid.org/0000-0003-0991-7774>

Marianne Leruez-Ville  <https://orcid.org/0000-0001-7513-7894>

Isabelle Sermet-Gaudelus  <https://orcid.org/0000-0001-5537-9482>

Olivia Boyer  <https://orcid.org/0000-0002-3957-1359>

## REFERENCES

- Spinoit A-F, Haid B, Hiess M, et al. Impact of the COVID-19 Pandemic on Paediatric Urology Practice in Europe: A Reflection from the European Association of Urology Young Academic Urologists. *Eur Urol*. 2020;78:122-124.
- Galvan NTN, Moreno NF, Garza JE, et al. Donor and transplant candidate selection for solid organ transplantation during the COVID-19 pandemic. *Am J Transplant* n/a.
- Garcelon N, Neuraz A, Salomon R, et al. A clinician friendly data warehouse oriented toward narrative reports: Dr. Warehouse. *J Biomed Inform*. 2018;80:52-63.
- Granata A, Clementi S, Londrino F, et al. Renal transplant vascular complications: the role of Doppler ultrasound. *J Ultrasound*. 2014;18:101-107.
- Sermet I, Temmam S, Huon C, et al. Prior infection by seasonal coronaviruses does not prevent SARS-CoV-2 infection and associated Multisystem Inflammatory Syndrome in children. *medRxiv*. 2020.06.29.20142596. 2020. <https://doi.org/10.1101/2020.06.29.20142596>
- Grzelak L, Temmam S, Planchais C, et al. A comparison of four serological assays for detecting anti-SARS-CoV-2 antibodies in human serum samples from different populations. *Sci Transl Med*. 2020;12.
- Abrishami A, Samavat S, Behnam B, et al. Clinical Course, Imaging Features, and Outcomes of COVID-19 in Kidney Transplant Recipients. *Eur Urol*. 2020;78(2):281-286. <https://doi.org/10.1016/j.eururo.2020.04.064>
- Akalin E, Azzi Y, Bartash R, et al. Covid-19 and Kidney Transplantation. *N Engl J Med*. 2020;382:2475-2477.
- Cravedi P, Mothi SS, Azzi Y, et al. COVID-19 and kidney transplantation: Results from the TANGO International Transplant Consortium. *Am J Transplant* n/a.
- Marlais M, Wlodkowski T, Vivarelli M, et al. The severity of COVID-19 in children on immunosuppressive medication. *The Lancet Child & Adolescent Health*. 2020;4:e17-e18.
- Abbasi J. The Promise and Peril of Antibody Testing for COVID-19. *JAMA*. 2020;323:1881-1883.
- Varga Z, Flammer AJ, Steiger P, et al. Endothelial cell infection and endotheliitis in COVID-19. *The Lancet*. 2020;395:1417-1418.
- Batlle D, Soler MJ, Sparks MA, et al. Acute Kidney Injury in COVID-19: Emerging Evidence of a Distinct Pathophysiology. *JASN*. 2020;31:1380-1383.
- Bouaziz JD, Duong T, Jachiet M, et al. Vascular skin symptoms in COVID-19: a French observational study. *J European Acad Dermatol Venereol* n/a.
- Toubiana J, Poirault C, Corsia A, et al. Kawasaki-like multisystem inflammatory syndrome in children during the covid-19 pandemic in Paris, France: prospective observational study. *BMJ*. 2020;369.
- Godfred-Cato S, Bryant B, Leung J, et al. COVID-19-Associated Multisystem Inflammatory Syndrome in Children – United States, March–July 2020. *MMWR Morb Mortal Wkly Rep*. 2020;69:1074-1080.
- Akilesh S, Nast CC, Yamashita M, et al. Multicenter Clinicopathologic Correlation of Kidney Biopsies Performed in COVID-19 Patients Presenting With Acute Kidney Injury or Proteinuria. *Am J Kidney Dis*. 2021;77(1):82-93.e1. <https://doi.org/10.1053/j.ajkd.2020.10.001>
- Wurtzer S, Marechal V, Mouchel JM, et al. Evaluation of lockdown impact on SARS-CoV-2 dynamics through viral genome quantification in Paris wastewaters. 2020. <http://medrxiv.org/lookup/doi/10.1101/2020.04.12.20062679>. <https://doi.org/10.1101/2020.04.12.20062679>
- Schwierzeck V, König JC, Kühn J, et al. First reported nosocomial outbreak of severe acute respiratory syndrome coronavirus 2 (SARS-CoV-2) in a pediatric dialysis unit. *Clin Infect Dis*. 2020. <https://doi.org/10.1093/cid/ciaa491>
- Harwood R, Sinha I. Diagnosis of COVID-19 in children: the story evolves. *BMC Med*. 2020;18.
- Sola AM, David AP, Rosbe KW, et al. Prevalence of SARS-CoV-2 Infection in Children Without Symptoms of Coronavirus Disease 2019. *JAMA Pediatr*. 2020. <https://doi.org/10.1001/jamapediatrics.2020.4095>
- Waterfield T, Watson C, Moore R, et al. Seroprevalence of SARS-CoV-2 antibodies in children - A prospective multicentre cohort study. *medRxiv*. 2020.08.31.20183095 2020. <https://doi.org/10.1101/2020.08.31.20183095>
- Cohen R, Jung C, Ouldali N, et al. Assessment of spread of SARS-CoV-2 by RT-PCR and concomitant serology in children in a region heavily affected by COVID-19 pandemic. 2020. <http://medrxiv.org/lookup/doi/10.1101/2020.06.12.20129221>. <https://doi.org/10.1101/2020.06.12.20129221>
- Tosif S, Neeland MR, Sutton P, et al. Immune responses to SARS-CoV-2 in three children of parents with symptomatic COVID-19. *Nat Commun*. 2020;11:5703.

## SUPPORTING INFORMATION

Additional supporting information may be found online in the Supporting Information section.

**How to cite this article:** Berteloot L, Berthaud R, Temmam S, et al. Arterial abnormalities identified in kidneys transplanted into children during the COVID-19 pandemic. *Am J Transplant*. 2021;21:1937–1943. <https://doi.org/10.1111/ajt.16464>