



HAL
open science

Spectrum of brain malformations in fetuses with mild tubulinopathy

R. Hagege, K. Krajden Haratz, G. Malinger, L. Ben-sira, Z. Leibovitz, D. Heron, L. Burglen, R. Birnbaum, S. Valence, B. Keren, et al.

► **To cite this version:**

R. Hagege, K. Krajden Haratz, G. Malinger, L. Ben-sira, Z. Leibovitz, et al.. Spectrum of brain malformations in fetuses with mild tubulinopathy. *Ultrasound in Obstetrics and Gynecology = Ultrasound in Obstetrics & Gynecology*, 2023, 61 (6), pp.740-748. 10.1002/uog.26140 . hal-04351182

HAL Id: hal-04351182

<https://hal.science/hal-04351182>

Submitted on 18 Dec 2023






HAL is a multi-disciplinary open access archive for the deposit and dissemination of scientific research documents, whether they are published or not. The documents may come from teaching and research institutions in France or abroad, or from public or private research centers.

L'archive ouverte pluridisciplinaire **HAL**, est destinée au dépôt et à la diffusion de documents scientifiques de niveau recherche, publiés ou non, émanant des établissements d'enseignement et de recherche français ou étrangers, des laboratoires publics ou privés.



Distributed under a Creative Commons Attribution - NonCommercial - NoDerivatives 4.0 International License

Spectrum of brain malformations in fetuses with mild tubulinopathy

R. HAGEGE^{1,2,3#}, K. KRAJDEN HARATZ^{4,5#} , G. MALINGER^{4,5} , L. BEN-SIRA^{5,6}, Z. LEIBOVITZ^{7,8,9} , D. HERON¹⁰, L. BURGLIN¹¹, R. BIRNBAUM^{4,5} , S. VALENCE¹², B. KEREN¹³, L. BLUMKIN^{5,14}, J.-M. JOUANNIC¹⁵ , T. LERMAN-SAGIE^{5,14} and C. GAREL¹⁶

¹Department of Radiology, Armand Trousseau Hospital, AP–HP, Sorbonne University, Paris, France; ²Department of Obstetrics and Gynecology, Samson Assuta Ashdod Hospital, Ashdod, Israel; ³Faculty of Medicine, Ben Gurion University, Beer Sheva, Israel; ⁴Division of Ultrasound in Obstetrics and Gynecology, Lis Maternity and Women’s Hospital, Tel Aviv Sourasky Medical Center, Tel Aviv, Israel; ⁵Sackler Faculty of Medicine, Tel Aviv University, Tel Aviv, Israel; ⁶Department of Radiology, Division of Pediatric Radiology, Dana Children’s Hospital, Tel Aviv Sourasky Medical Center, Tel Aviv, Israel; ⁷Obstetrics–Gynecology Ultrasound Unit, Bnai-Zion Medical Center, Haifa, Israel; ⁸Rappaport Faculty of Medicine, Technion, Israel Institute of Technology, Haifa, Israel; ⁹Fetal Neurology Clinic, Obstetrics–Gynecology Ultrasound Unit, Department of Obstetrics and Gynecology, Wolfson Medical Center, Holon, Israel; ¹⁰Department of Genetics, Division of Medical Genetics, Reference Center for Rare Diseases and Intellectual Deficiencies of Rare Causes, Pitié-Salpêtrière Hospital, AP–HP, Sorbonne University, Paris, France; ¹¹Department of Genetics, Reference Center for Cerebellar Malformations and Congenital Diseases, Armand Trousseau Hospital, AP–HP, Sorbonne University, Paris, France; ¹²Department of Pediatric Neurology, Reference Center for Rare Diseases and Intellectual Deficiencies of Rare Causes, Armand Trousseau Hospital, AP–HP, Sorbonne University, Paris, France; ¹³Department of Genetics, Pitié-Salpêtrière Hospital, AP–HP, Sorbonne University, Paris, France; ¹⁴Fetal Neurology Clinic, Pediatric Neurology Unit, Magen Center for Rare Diseases, Wolfson Medical Center, Holon, Israel; ¹⁵Fetal Medicine Department, Armand Trousseau Hospital, AP–HP, Sorbonne University, Paris, France; ¹⁶Department of Radiology, Reference Center for Cerebellar Malformations and Congenital Diseases, Armand Trousseau Hospital, AP–HP, Sorbonne University, Paris, France

KEYWORDS: basal ganglia; brainstem; gyration; magnetic resonance; prenatal diagnosis; tubulinopathy; ultrasound

CONTRIBUTION

What are the novel findings of this work?

We present imaging findings in a cohort of fetuses with tubulinopathy at the milder end of the broad spectrum of these malformations of cortical development. In our series of 34 fetuses, around 50% of tubulinopathies were inherited from one of the parents.

What are the clinical implications of this work?

Mild forms of tubulinopathy are a diagnostic challenge, due to the presence of subtle imaging findings. When one of these findings is suspected, a detailed neurosonographic/magnetic resonance imaging examination can provide important clues, not only for diagnosis but also for counseling.

ABSTRACT

Objective To report on a large cohort of fetuses with mild forms of tubulinopathy and to define prenatal ultrasound

and magnetic resonance imaging (MRI) features that can facilitate prenatal diagnosis.

Methods This was a retrospective multicenter study of fetuses diagnosed between January 2007 and February 2022 with a mild tubulinopathy (without lissencephaly or microlissencephaly). We collected and reviewed brain imaging and genetic data, and defined major criteria as findings observed in $\geq 70\%$ of the patients and minor criteria as those observed in $\geq 50\%$ but $< 70\%$ of the patients.

Results Our cohort included 34 fetuses. The mean gestational age at ultrasound screening, when suspicion of a central nervous system anomaly was first raised, was 24.2 (range, 17–33) weeks. Callosal anomalies (n = 19 (56%)) and abnormal ventricles (n = 18 (53%)) were the main reasons for referral. The mean gestational age at neurosonography was 28.3 (range, 23–34) weeks and that at MRI was 30.2 (range, 24–35) weeks. Major ultrasound criteria were midline distortion, ventricular asymmetry, dysmorphic and/or dilated frontal horn(s) and abnormal

Correspondence to: Prof. G. Malinge, Division of Ultrasound in Obstetrics and Gynecology, Lis Maternity and Women’s Hospital, Tel Aviv Sourasky Medical Center, 6 Weizmann St, Tel Aviv 6423906, Israel (e-mail: gmalinge@gmail.com)

#R.H. and K.K.H. contributed equally to this work.

Accepted: 24 November 2022

sulcation. Minor ultrasound criteria were distortion of the cavum septi pellucidi, abnormal corpus callosum, absent or asymmetric olfactory sulci, ventriculomegaly and basal ganglia dysmorphism. Major MRI criteria were midline distortion, distortion of the cavum septi pellucidi, ventricular asymmetry, dilatation (generally unilateral) and/or distortion, dysmorphic and/or dilated frontal horn(s) and abnormal sulcation (mainly dysgyria). Minor MRI criteria were absent or asymmetric olfactory sulci, abnormal bulge of the pons, anteroposterior diameter of the pons $\leq 5^{\text{th}}$ centile and brainstem asymmetry. A mutation was found in TUBB3 (44.1% of cases), TUBB (23.5%), TUBB2B (14.7%) or TUBA1A (17.6%). The mutation was inherited from a parent in 18/34 cases. The pregnancy was terminated in 23/34 cases.

Conclusions Prenatal diagnosis of mild forms of tubulinopathy is possible but challenging. We have defined, in this large series of fetuses, major and minor criteria that can help identify this entity in utero. Most findings can be visualized on ultrasound. This evaluation is also important for prenatal counseling. Once a prenatal diagnosis of mild tubulinopathy is suspected, the family members should be referred for exome sequencing and MRI. © 2022 The Authors. *Ultrasound in Obstetrics & Gynecology* published by John Wiley & Sons Ltd on behalf of International Society of Ultrasound in Obstetrics and Gynecology.

INTRODUCTION

Tubulinopathies comprise a wide and overlapping spectrum of brain malformations and clinical features caused by pathogenic variants in genes encoding different isotypes of tubulin¹. During the past decade, the range of brain malformations related to tubulinopathies has been studied extensively in patients, and the main imaging characteristics have been defined. The most common malformations of cortical development (MCD) include classic lissencephaly, lissencephaly with cerebellar hypoplasia, lissencephaly with agenesis of the corpus callosum, centrally predominant pachygyria, microlissencephaly and dysgyria. Associated anomalies include undefined basal ganglia, hypoplasia of the anterior limbs of the internal capsule, vermian and brainstem hypoplasia, corpus callosal abnormalities and cerebellar cortical dysplasia^{1,2}.

However, the *in-utero* imaging characteristics of the different tubulinopathies have not been elucidated fully. A cohort reported by Fallet-Bianco *et al.*² included 26 fetuses with lissencephaly and microlissencephaly, but the milder forms of tubulinopathy, similar to those described postnatally, have been described by only our groups, in two small series^{3,4}.

With the increase of knowledge on the postnatal presentations of tubulinopathies, these disorders are now suspected more frequently in tertiary-care fetal medicine centers around the world, and an approach to diagnosis has been suggested⁵. When an anomaly is suspected, the patient is usually referred for dedicated neurosonography

followed by fetal magnetic resonance imaging (MRI) and genetic testing. However, fetuses with subtle anomalies remain mostly undiagnosed.

The purpose of this study was to report on a large cohort of fetuses with mild forms of tubulinopathy and comprehensive imaging documentation, and to define imaging (neurosonography and MRI) criteria that can help in their prenatal diagnosis.

METHODS

This was a retrospective multicenter study of fetuses examined between January 2007 and February 2022 in three institutions (Armand Trousseau Hospital, in Paris, France; Tel Aviv Sourasky Medical Center (TASMC), in Tel Aviv, Israel; Wolfson Medical Center, in Holon, Israel) and approved by the respective Institutional Review Boards (CER-2022-01 in Armand Trousseau Hospital; 0704-21-TLV in TASMC; WOMC 0188-18 in Wolfson Medical Center). We retrieved and reviewed systematically the imaging data of fetuses diagnosed with tubulinopathy which did not present initially with lissencephaly or microlissencephaly (i.e. fetuses defined as having mild tubulinopathy). Patients were included when at least one prenatal dedicated neurosonographic examination had been performed and when the diagnosis of tubulinopathy was genetically proven. Most patients had also undergone fetal MRI, but this was not considered an inclusion criterion.

According to the institution, ultrasound examinations were performed using an Aplio 400 or 800 machine (Canon Medical Systems, Otawara, Japan) or a Voluson E8 or E10 machine (GE Healthcare, Zipf, Austria). When the transabdominal approach was not sufficient, depending on the fetal position, a transvaginal approach was used, with the highest-resolution probe available, as described previously^{6,7}. At Armand Trousseau Hospital, fetal MRI examinations were performed using a 1.5-Tesla (T) Achieva unit (Philips Medical Systems, Best, The Netherlands) from 2010 to 2015, and an Optima MR450w unit (GE Healthcare, Waukesha, WI, USA) from 2016 onwards. At TASMC, fetal MRI examinations were performed using a 3-T Skyra (Siemens Healthineers, Malvern, PA, USA) unit. The mothers received sedation (Zopiclone (7.5 mg) in Armand Trousseau Hospital and Diazepam (5–15 mg) in TASMC) prior to MRI, to reduce maternal anxiety, fetal and maternal movements and, therefore, total scan time. In both institutions, a torso phased-array coil was used. Following a localizing gradient echo sequence, ultra T2-weighted single-shot fast spin echo MR images were collected in axial, coronal and sagittal planes. Additional T1-weighted images were acquired in at least one plane. Images were archived on the Carestream PACS platform in all three centers.

Retrieved patient files were reviewed by at least two experts proficient in diagnosis of fetal brain anomalies and specialist in obstetrics and gynecology (K.K.H., G.M., Z.L., R.B.), pediatric radiology (C.G., L.B.-S.) or pediatric neurology (T.L.-S.). The following data were collected:

maternal and family history, year of diagnosis, maternal age at diagnosis, gravidity and parity, consanguinity, known or suspected tubulinopathy in a first-degree relative, gestational age at screening, reason for referral, gestational age at second-line evaluation (neurosonography or MRI) and fetal sex. Ultrasonographic biometric parameters (expressed as centiles) included: fetal weight⁸, head circumference⁸, lateral ventricle width at the level of the atria^{6,7}, transverse cerebellar diameter⁹, vermian height¹⁰ and length of the corpus callosum¹¹. Non-central-nervous-system (CNS) anomalies were noted when present. MRI parameters included: biometric data (values expressed as centiles): cerebral occipitofrontal diameter, cerebral biparietal diameter, transverse cerebellar diameter, vermian height, anteroposterior diameter of the pons and length of the corpus callosum. Different reference charts were used for measurements between 20 and 24 weeks of gestation¹² and those above 26 weeks of gestation¹³. Moreover, for both imaging techniques, some parameters were analyzed qualitatively: presence of midline distortion, presence of cavum septi pellucidi distortion, morphology of the corpus callosum, morphology of olfactory bulbs and sulci, morphology of the frontal horns, presence of subependymal pseudocysts, morphology of

the basal ganglia, sulci and gyri pattern and morphology of the vermis and brainstem (Table 1). Neurosonography and MRI criteria were considered major when present in $\geq 70\%$ of cases and minor when present in $\geq 50\%$ but $< 70\%$ of cases. Outcome data collected included: live birth or termination of pregnancy and the gestational age, and tubulinopathy mutation variant.

Descriptive variables were analyzed using Microsoft Excel 2020 (Microsoft Corp., Redmond, WA, USA).

RESULTS

We identified 34 fetuses (from 26 families) with mild tubulinopathy diagnosed during the study period: five diagnosed before 2016 and 29 diagnosed between 2016 and 2022. Six of these patients (from five families) have been reported previously by our groups and were re-evaluated for the purposes of this study: Case 10⁴, Case 21^{3,14}, Case 26¹⁴, Case 29¹⁵ and Cases 32 and 33³. Nineteen patients were from Trousseau Hospital in Paris, of which three did not undergo MRI, and 15 patients were from Israel, of which one did not undergo MRI. The mean maternal age at diagnosis was 30.8 (range, 19–42) years. Seventeen women were primiparous and 17

Table 1 Imaging morphological parameters considered in qualitative analysis of possible tubulinopathy findings

Morphological parameter	Neurosonography	MRI
Midline distortion	Distortion of anterior part of interhemispheric fissure	Distortion of anterior part of interhemispheric fissure
Distortion of CSP	On axial and coronal views	On axial and coronal views
CC anomaly		
Complete or partial agenesis	Complete or partial CC agenesis	Complete or partial CC agenesis
Short CC	CC length $< 5^{\text{th}}$ centile	CC length $< 3^{\text{rd}}$ centile
Dysgenesis	Thin or thick CC with or without short CC or partial ACC ³⁷	Thin or thick CC with or without short CC or partial ACC ³⁷
Olfactory sulci (presence/absence/asymmetry)	Considered only ≥ 28 gestational weeks ^{23,24}	Considered only ≥ 30 gestational weeks ²⁵
Olfactory bulbs (presence/absence/asymmetry)	NA	Considered only ≥ 30 gestational weeks ²⁵
Ventricular dilatation	≥ 10 mm	≥ 10 mm
Ventricular asymmetry	Difference ≥ 2 mm between right and left atrial widths	Difference ≥ 2 mm between right and left atrial widths
Frontal horn dilatation	Subjective evaluation	Subjective evaluation
Frontal horn dysmorphism	Lateral portion \gg medial portion	Lateral portion \gg medial portion
Ventricular distortion	NA	Axial view: displacement of one ventricle towards midline, bowing with lateral concavity
Frontal subependymal pseudocysts	Anechoic/hypoechoic cystic findings without layering	Hypersignal cystic findings without layering
Asymmetric basal ganglia	Subjective evaluation	Subjective evaluation
Abnormal sulcation		
Asymmetric SF	Present/absent	Present/absent
Delayed gyration	Present/absent	Present/absent
Dysgyria	Irregularities in sulcal depth and organization ²⁹	Irregularities in sulcal depth and organization ²⁹
Dysplastic vermis	Abnormal fastigial point/absent primary fissure/abnormal echogenicity or vermian proportions	Abnormal fastigial point/absent primary fissure/abnormal signal or vermian proportions
Abnormal brainstem	Complete or partial flattening of anterior pons	Complete or partial flattening of anterior pons
Brainstem asymmetry	NA	Defined on axial plane at level of pons and/or cerebral peduncles

\gg , considerably larger (subjective assessment); ACC, agenesis of corpus callosum; CC, corpus callosum; CSP, cavum septi pellucidi; MRI, magnetic resonance imaging; NA, not applicable; SF, Sylvian fissure.

were multiparous. Consanguinity was present in one case (third-degree cousins, Case 26). A relevant family history was reported in eight families. Table S1 summarizes the pooled data of our series.

In 10 families, one of the parents (eight mothers and two fathers) presented with MRI findings consistent with tubulinopathy, and this was subsequently proven genetically in all 10 families. Among these 10 families: in four, tubulinopathy was diagnosed in a single pregnancy (Cases 8, 20, 21 and 22); in four others, there was a recurrence in one further pregnancy (Cases 12 and 13, Cases 28 and 29, Cases 30 and 31, Cases 32 and 33); and in two others, recurrence occurred in two pregnancies (Cases 3–5; Cases 23–25). Overall, the condition was inherited from a parent in 18/34 cases (Table S1).

Table 2 Major and minor biometric and morphological criteria for prenatal diagnosis of tubulinopathy, as demonstrated by neurosonography and magnetic resonance imaging (MRI)

	Neurosonographic criteria	MRI criteria
Major	1. Ventricular asymmetry 2. Abnormal sulcation 3. Frontal horns 3a. Dymorphic frontal horn(s) 3b. Dilated frontal horn(s) 4. Midline distortion	1. Ventricular asymmetry, dilatation and/or distortion 2. Abnormal sulcation 3. Dymorphic and/or dilated frontal horn(s) 4. Midline distortion 5. Distortion of CSP
Minor	5. Distortion of CSP 6. Absence or asymmetry of olfactory sulci 7. Abnormality of corpus callosum 8. Ventricular dilatation 9. Basal ganglia asymmetry	6. Absence or asymmetry of olfactory sulci 7. Anteroposterior diameter of pons \leq 5 th centile 8. Abnormal bulge of pons 9. Brainstem asymmetry

CSP, cavum septi pellucidi.

Of the 34 fetuses, a mutation was found in *TUBB3* in 44.1%, in *TUBB* in 23.5%, in *TUBA1A* in 17.6% and in *TUBB2B* in 14.7%. Of the 10 families in which one of the parents was also affected, a variant in *TUBB3* was found in six, a variant in *TUBB* was found in three and a variant in *TUBB2B* was found in one (Table S1).

Suspicion of the presence of a CNS anomaly was first raised at ultrasound screening, at a mean gestational age of 24.2 (range, 17–33) weeks, due to one or more of the following findings: midline abnormality, including of the corpus callosum ($n=19$ (55.9%)), abnormal ventricles ($n=18$ (52.9%)), abnormal posterior fossa ($n=4$ (11.8%)), abnormal sulcation ($n=4$ (11.8%)) and/or family history ($n=5$ (14.7%)). In 38% of cases, there was more than one of these findings. These patients were then referred for a detailed neurosonographic examination.

Neurosonographic findings

Neurosonography was performed at a mean gestational age of 28.3 (range, 23–34) weeks. There were 20 (58.8%) female fetuses and 14 (41.2%) male fetuses. The findings which qualified as major or minor diagnostic criteria are summarized in Table 2. Biometric data from this examination are reported in Table 3 and morphological data are summarized in Table 4.

Major neurosonographic findings were: midline distortion, ventricular asymmetry, dymorphic frontal horn(s) (generally unilateral), dilated frontal horn(s) (generally unilateral) and abnormal sulcation (suggestive of dysgyria) (Table 2, Figure 1). Minor findings were: distortion of the cavum septi pellucidi, corpus callosal anomalies (mainly dysgenesis or short corpus callosum), absence or asymmetry of the olfactory sulci, ventricular dilatation

Table 3 Fetal biometric findings on ultrasound and magnetic resonance imaging (MRI) in fetuses with mild tubulinopathy

Biometric parameter	Ultrasound	MRI
Estimated fetal weight ⁸	Mean, 46 th centile (range, 7–94 th centile) All cases between 10 th and 94 th centiles, except Case 7 (7 th centile)	NA
Head circumference ⁸	Mean, 47.5 th centile All cases between 5 th and 95 th centiles, except Case 2 (3 rd centile) and Case 34 (5 th centile)	NA
Ventriculomegaly ^{6,7}	19/33 (57.6%) cases Mean atrial width, 11 mm (range, 10–14.9 mm)	23/30 (76.7%) cases Mean ventricular width, 11.9 mm (range, 10–19 mm)
TCD ⁹	Mean, 53 rd centile All cases between 10 th and 90 th centiles, except Case 17 (< 1 st centile) and Case 19 (< 3 rd centile)	All between 10 th and 90 th centiles, except Cases 11 and 12 (5 th centile) and Case 7 (< 5 th centile)
Vermian height ¹⁰	Normal (between -2 and +2 SD) in 29/34 (85.3%) cases < -2 SD in 5/34 (14.7%) cases	Normal in 15/29 (51.7%) cases \leq 5 th centile in 14/29 (48.3%) cases
AP diameter of pons ^{12,13}	NA	\leq 5 th centile in 17/29 (58.6%) cases 5 th centile in 3/29 (10.3%) cases 3 rd centile in 4/29 (13.8%) cases < 3 rd centile in 10/29 (34.5%) cases
OFD ^{12,13}	NA	\leq 3 rd percentile in 6/30 (20.0%) cases
BPD ^{12,13}	NA	\leq 3 rd centile in 5/30 (16.7%) cases

AP, anteroposterior; BPD, biparietal diameter; NA, not applicable; OFD, occipitofrontal diameter; TCD, transverse cerebellar diameter.

Table 4 Morphological findings on neurosonography and magnetic resonance imaging (MRI) in fetuses with mild tubulinopathy

Morphological parameter	Neurosonography	MRI
Midline distortion	22/29 (75.9)*	27/30 (90.0)*
CSP distortion	15/26 (57.7)†	23/29 (79.3)*
Abnormality of CC	19/33 (57.6)†	12/30 (40.0)
Complete ACC	1/19 (5.3)	1/12 (8.3)
Partial ACC	3/19 (15.8)	6/12 (50.0)
Dysgenesis	8/19 (42.1)	3/12 (25.0)
Short CC	7/19 (36.8)	2/12 (16.7)
Olfactory sulci		
Absent	4/17 (23.5)	5/18 (27.8)
Asymmetric	7/17 (41.2)	4/18 (22.2)
Absent or asymmetric	11/17 (64.7)†	9/18 (50.0)†
Normal	6/17 (35.3)	9/18 (50.0)
Olfactory bulbs	NA	
Absent	—	1/24 (4.2)
Asymmetric	—	2/24 (8.3)
Normal	—	21/24 (87.5)
Ventriculomegaly	19/33 (57.6)†	23/30 (76.7)*
Unilateral	15/19 (78.9)	21/23 (91.3)
Bilateral	4/19 (21.1)	2/23 (8.7)
Ventricular asymmetry (≥ 2 mm) +/- dilatation	26/30 (86.7)*	29/30 (96.7)*
Ventricular distortion	NA	27/29 (93.1)*
Dysmorphic frontal horns	26/30 (86.7)*	23/29 (79.3)*
Unilateral	17/26 (65.4)	13/23 (56.5)
Bilateral	9/26 (34.6)	10/23 (43.5)
Dilated frontal horns	27/29 (93.1)*	27/29 (93.1)*
Unilateral	19/27 (70.4)	18/27 (66.7)
Bilateral	8/27 (29.6)	9/27 (33.3)
Subependymal pseudocysts	5/30 (16.7)	3/29 (10.3)
Asymmetric basal ganglia	18/30 (60.0)†	6/28 (21.4)
Abnormal sulcation	23/30 (76.7)*	29/29 (100)*
ASF	18/23 (78.3)	6/29 (20.7)
Dysgyria only	2/23 (8.7)	0/29 (0)
ASF and dysgyria	3/23 (13.0)	23/29 (79.3)
Abnormal vermis	10/30 (33.3)	8/29 (27.6)
Abnormal brainstem	13/28 (46.4)	NA
Abnormal bulge of pons	NA	20/29 (69.0)†
Brainstem asymmetry	NA	20/29 (69.0)†

Data are given as *n/N* (%). *Major criterion. †Minor criterion. +/-, with or without; ACC, agenesis of corpus callosum; ASF, asymmetric Sylvian fissure; CC, corpus callosum; CSP, cavum septi pellucidi; NA, not applicable.

(mainly unilateral) and basal ganglia asymmetry (Table 2, Figures 1 and 2).

Extracerebral findings were uncommon and included a dysplastic pelvic kidney in Case 18 and single umbilical artery in Cases 22 and 23.

MRI findings

MRI was performed in 30 cases. In the other four cases, the neurosonographic findings were deemed sufficiently abnormal that these pregnancies were terminated on this basis. The mean gestational age at MRI was 30.2 (range, 24–35) weeks. Biometric data from this examination are reported in Table 3 and morphological data are summarized in Table 4.

Major MRI findings were: midline distortion, distortion of the cavum septi pellucidi, ventricular asymmetry,

dilatation (generally unilateral) and/or distortion, dysmorphic and/or dilated frontal horn(s) (generally unilateral) and abnormal sulcation (Table 2, Figure 3). Minor findings were: anteroposterior diameter of the pons $\leq 5^{\text{th}}$ centile, absence or asymmetry of the olfactory sulci, abnormal bulge of the pons and brainstem asymmetry.

Pregnancy outcome

Termination of pregnancy was performed in 23/34 cases, at a mean gestational age of 29.1 (range, 25–35) weeks. Eleven patients were liveborn: two preterm, by Cesarean section at 35 weeks for obstetric reasons, one preterm by vaginal delivery after premature rupture of the membranes at 36 weeks and seven by vaginal delivery at term. One liveborn patient was lost to follow-up.

DISCUSSION

We report the imaging findings in a large series of fetuses diagnosed prenatally with genetically proven ‘mild’ tubulinopathy, i.e. presenting without lissencephaly or microlissencephaly. Previous studies reported patients presenting with subtle neurological symptoms, including cognitive ability ranging from moderate intellectual disability to normal cognition, with or without learning disorders, motor impairment, hypotonia, ataxia, nystagmus and occasional seizures^{1–3,16}. *TUBB3* variants were the most frequently found mutations in our group, with *TUBB*, *TUBB2B* and *TUBA1A* variants being less common. Most (29/34) of our cases were diagnosed from 2016 onwards, which highlights the difficulty in prenatal diagnosis before then, when the understanding of the typical phenotypic characteristics of mild forms of tubulinopathy was poor.

To facilitate prenatal identification of the milder forms of tubulinopathy, we defined minor and major imaging criteria, based on their frequency in our patients. These findings were usually observed using neurosonography at the end of the second trimester, and MRI in the third trimester. None of the fetuses had a small head circumference (all were > 2.3 centiles). The vermian height was normal in most fetuses on neurosonography and reduced in almost half of the cases (48%) on MRI. The anteroposterior diameter of the pons was reduced in more than half of the cases on MRI; this was considered a minor criterion, probably as an early sign of brainstem involvement.

Midline abnormalities represented the most common reason for referral. We found that distortion of the anterior part of the interhemispheric fissure was very common, and this was considered a major criterion on both neurosonography and MRI. This important sign has been reported in only one small series⁴. Distortion of the cavum septi pellucidi was also a major criterion on MRI.

Abnormalities of the corpus callosum are frequently present in tubulinopathy, both pre- and postnatally^{2,16–18}. However, in our series, this was found to be a minor criterion on neurosonography and it was observed less commonly on MRI.

Hypoplasia or absence of the olfactory bulbs and sulci are typical findings of tubulinopathy^{2,3,16,17,19–22}. In our series, analysis of these structures was not relevant in many cases due to the early gestational age^{23–25} or to poor visualization in our retrospective analysis. Absence or asymmetry of the olfactory sulci was found to be a minor criterion on both imaging techniques.

Ventricular abnormalities represented the second most common cause of referral and most features related to it were major criteria, except for ventriculomegaly on neurosonography, which was a minor criterion. Severe ventriculomegaly was present in only two cases. In the remaining cases, ventriculomegaly was mild and asymmetrical, as has been observed postnatally¹⁷. Asymmetry has not been observed in severe forms of ventriculomegaly diagnosed prenatally². It is a highly suggestive sign, and is best visualized by MRI on axial planes. Another striking feature was the dilatation and dysmorphism of the frontal horns, which were mostly asymmetric, with the frontal horn displaying a hooked appearance; this was probably due to the spherical shape of the head of the caudate nucleus, protruding into the frontal horn^{16,26}.

Abnormally shaped basal ganglia are another known postnatal sign of tubulinopathy^{17,27}. While some

studies have found enlarged caudate nuclei pre- and postnatally^{3,17,22}, others report hypoplastic basal ganglia^{2,28}. In our series, we show for the first time that prenatal neurosonography can identify this basal ganglia dysmorphism, appearing as abnormally large and asymmetric, hyperechoic structures located below the frontal horns. This finding was a minor criterion on neurosonography, and was less commonly observed on MRI (Figure 2).

MCD, another sign of tubulinopathy, reflect impaired neuronal proliferation, disturbed axonal guidance and migrational or postmigrational abnormalities¹⁸. MCD encompass a wide spectrum of anomalies, ranging from lissencephaly^{2,16} to a polymicrogyria-like pattern. The term ‘tubulinopathy-associated dysgyria’ was first introduced by Oegema *et al.*²⁹ to describe subtle cortical abnormalities, not considered typical pachygyria, polymicrogyria or cortical dysplasia, in which the cortex displays normal thickness, but the sulci are oriented obliquely and narrow gyri are separated by abnormally deep and shallow sulci¹⁷. In our series, dysgyria was a major criterion on MRI while it was observed less commonly on neurosonography³⁰.

Asymmetric Sylvian fissure was a major criterion on neurosonography and a major criterion on MRI

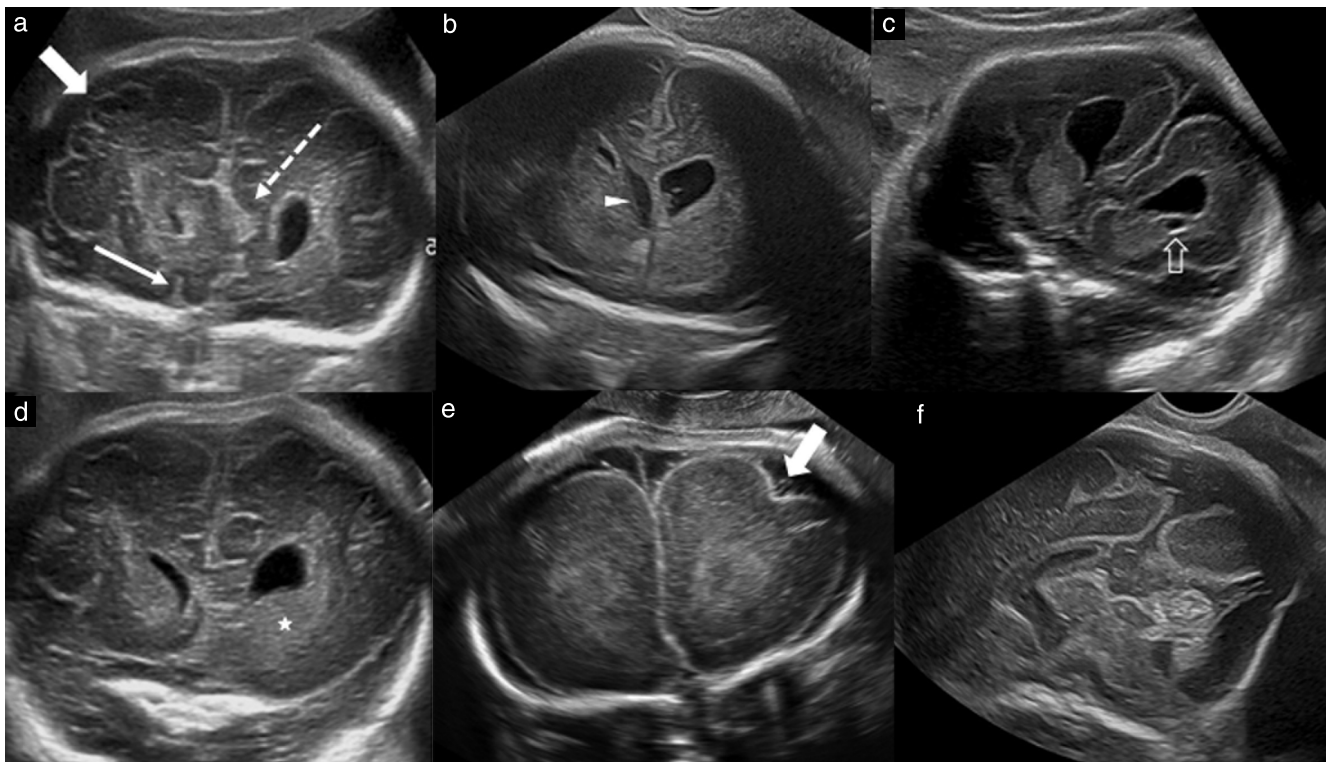


Figure 1 Main morphological abnormalities identified by neurosonography in fetuses with mild tubulinopathy. (a) Case 9 at 31 + 5 weeks: coronal view. Right olfactory sulcus is visible (thin arrow), but left one is absent. Anterior part of interhemispheric fissure is distorted (dashed arrow), and right frontal dysgyria (thick arrow) is visible. (b) Case 5 at 29 + 2 weeks: coronal view. Left frontal horn is dilated but not dysmorphic and cavum septi pellucidi (arrowhead) is deviated and displaced to the right. (c) Case 19 at 26 + 2 weeks: coronal view. Both frontal horns are dysmorphic, with rounded appearance, and medial portion is much thinner than lateral one. Under left horn, a subependymal cyst (arrow) is visible. (d) Case 9 at 31 + 5 weeks: coronal view. Left basal ganglia (★) is markedly enlarged compared to right side. (e) Case 21 at 26 + 3 weeks: coronal view. Dysgyria is well demonstrated, with abnormal sulcus (arrow) of left frontal lobe. (f) Case 1 at 31 + 2 weeks: midsagittal view. Vermis is dysplastic, without identification of primary fissure, and bulge of pons is poorly visualized.

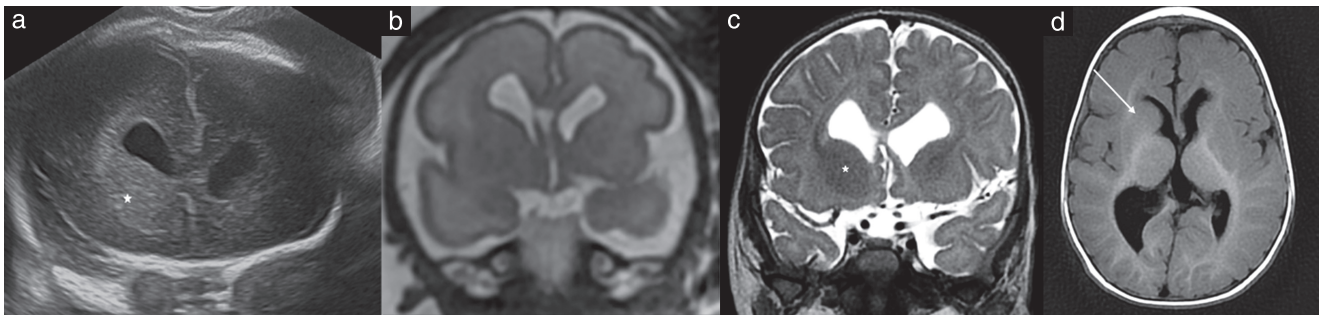


Figure 2 Morphological abnormalities of basal ganglia as shown by neurosonography and magnetic resonance imaging (MRI) in Case 14. (a) Neurosonography (coronal view) at 28 + 6 weeks, showing enlarged right basal ganglia (★) and dysmorphic and dilated frontal horns. (b) T2-weighted MRI (coronal view) at 28 + 6 weeks, showing dysmorphic and dilated frontal horns, without evidence of abnormal basal ganglia. (c,d) Postnatal T2-weighted MRI (coronal view) (c) and T1-weighted MRI (axial view) (d) at 6 months of age, showing enlarged right basal ganglia (★) and dysmorphic and dilated frontal horns. Fusion of lentiform and caudate nuclei is well demonstrated in (d) (arrow).

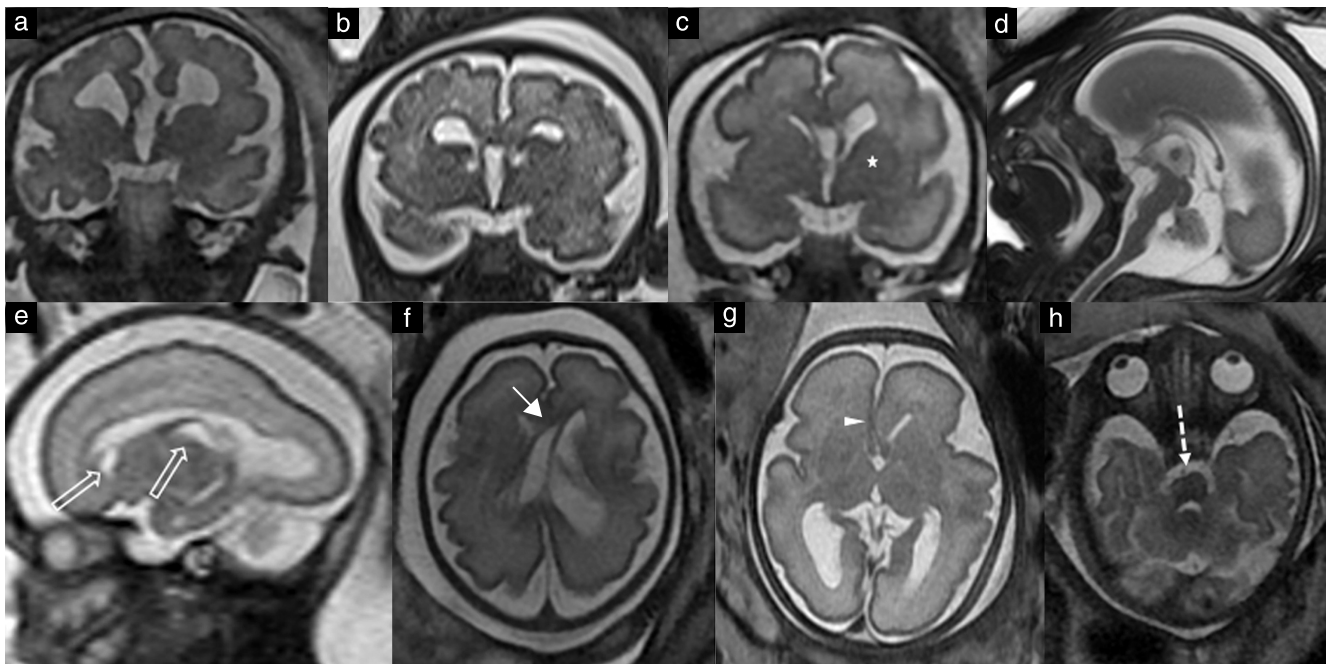


Figure 3 Main morphological abnormalities identified by magnetic resonance imaging (MRI) in fetuses with mild tubulinopathy: T2-weighted images. (a) Case 6 at 34 + 3 weeks: coronal view. Frontal horns are dysmorphic, Sylvian fissures are poorly operculated and, on both sides, frontal cortex displays dysgyria. (b) Case 1 at 31 weeks: coronal view. Frontal horns display typical hooked appearance resulting from abnormal shape of the head of the caudate nucleus. Bilateral small subependymal cysts are visible below the frontal horns. Frontal cortex shows dysgyria. (c) Case 5 at 29 + 2 weeks: coronal view. Cavum septi pellucidi is slightly displaced to right. Left frontal horn is enlarged without dysmorphism and left basal ganglia (★) are markedly enlarged compared to right side. (d) Case 26 at 29 + 4 weeks: midsagittal view. Corpus callosum shows partial agenesis (lack of rostrum and underdeveloped genu) and abnormal thickness, with genu and posterior part of body being too thin. Vermis is dysplastic and pons is underdeveloped. (e) Case 10 at 27 + 3 weeks: sagittal view. Two subependymal cysts are visible (arrows), below frontal horn and in caudothalamic notch. (f) Case 5 at 29 + 2 weeks: axial view. Ventricular and caval distortion (arrow) is visible, with left ventricle enlarged and displaced to the right, bowed and displaying lateral concavity. (g) Case 31 at 30 weeks: axial view. Distortion of anterior part of interhemispheric fissure (arrowhead) is seen, with asymmetric Sylvian fissures and dysgyria of cortex and left hemisphere. (h) Case 11 at 33 + 6 weeks: axial view, showing marked asymmetry of pons (arrow).

when it coexisted with dysgyria. Interestingly this is not mentioned in the postnatal literature. It is possible that the abnormalities of the Sylvian fissures described in our series are preliminary findings of a future MCD⁵.

Posterior fossa abnormalities, including brainstem, vermis and cerebellar hemisphere anomalies, are characteristic of tubulinopathy. In small series of fetuses^{3,4} and in the postnatal literature^{16,17,22,29,31}, the brainstem is described as hypoplastic and asymmetric in cases of

tubulinopathy. In our series, a hypoplastic brainstem with small anteroposterior diameter of the pons was a minor MRI criterion. Overall morphological brainstem abnormalities were depicted on neurosonography in only 46% of the cases, while it qualified as a minor criterion on MRI, with an abnormal bulge of the pons and asymmetry each being depicted in 69% of the cases. Asymmetry between right and left may affect one or more segments of the brainstem, with a homolateral or crossed pattern³².

In the literature, the vermis in fetuses with tubulinopathy is reported to be hypoplastic and dysplastic^{3,15,16,33}, with the anterior vermis being more severely affected^{17,29}. In our study, the vermian height was within the normal range on neurosonography in all except five patients, and it was $\leq 5^{\text{th}}$ centile in nearly half of the patients on MRI.

The cerebellar hemispheres can also be involved in cases of tubulinopathy^{2,29,34}, but, in most fetuses in our series with mild tubulinopathy, the transverse cerebellar diameter was within the normal range.

The majority of tubulinopathy mutations are *de-novo* autosomal dominant heterozygous variants¹⁸. In our cohort, 18/34 fetuses were of families with one parent showing a tubulin variant (*TUBB3*, *TUBB* and *TUBB2B*). In the literature, the proportion of fetuses with an inherited tubulinopathy variant is much lower. The *TUBB3* gene was the most frequently affected gene in our patients (44%) followed by *TUBB*, *TUBA1A* and *TUBB2B*. The high proportion of *TUBB3* variants can be explained by the ability of prenatal imaging to identify subtle anomalies that initiate the diagnostic process, leading to identification of these autosomal dominant conditions, whereas most cases in children and adults are diagnosed in the setting of the investigation of abnormal neurological conditions.

Variants in seven genes, encoding alpha-, beta- and gamma-tubulins, have been identified and their genotype–phenotype correlation has been elucidated^{35,36}. However, various phenotypes have been reported in association with the same affected gene and, conversely, overlapping phenotypes have been reported to arise from different affected genes¹⁶.

We did not perform or analyze novel MRI sequences or perform advanced measurements of the brainstem, since we believe that, in most cases, mild tubulinopathy can be suggested by neurosonography and conventional fetal MRI sequences.

Conclusion

Prenatal diagnosis of mild forms of tubulinopathy is possible but challenging. In this study, we defined major and minor diagnostic criteria suggestive of the diagnosis of a mild tubulinopathy in the fetus. Most findings can be seen on ultrasound. Complementary MRI, genetic counseling and investigation with trio exome sequencing should be offered when this entity is suspected by neurosonography. Mild tubulinopathies are often inherited from a parent who is clinically normal or shows mild clinical presentation and they are not mostly *de novo*, as was previously thought. Our findings are important for family counseling and pregnancy management in affected cases, which generally have a good neurodevelopmental outcome.

ACKNOWLEDGMENT

We would like to thank the patients and their families, the referring physicians and the geneticists in our institutions.

REFERENCES

- Bahi-Buisson N, Maillard C. Tubulinopathies Overview. In *GeneReviews*®, Adam MP, Everman DB, Mirzaa GM, Pagon RA, Wallace SE, Bean LJH, Gripp KW, Amemiya A (eds). University of Washington, Seattle: Seattle (WA), 1993.
- Fallet-Bianco C, Laquerrière A, Poirier K, Razavi F, Guimiot F, Dias P, Loeuillet L, Lascelles K, Beldjord C, Carion N, Toussaint A, Revencu N, Addor MC, Lhermitte B, Gonzales M, Martinovich J, Bessieres B, Marcy-Bonnière M, Jossic F, Marcocelles P, Loget P, Chelly J, Bahi-Buisson N. Mutations in tubulin genes are frequent causes of various foetal malformations of cortical development including microlissencephaly. *Acta Neuropathol Commun* 2014; 2: 69.
- Blumkin L, Leibovitz Z, Krajden-Haratz K, Arad A, Yosovich K, Gindes L, Zerem A, Ben-Sira L, Lev D, Nissenkorn A, Kidron D, Dobyns WB, Malinger G, Bahi-Buisson N, Leventer RJ, Lerman-Sagie T. Autosomal dominant *TUBB3*-related syndrome: Fetal, radiologic, clinical and morphological features. *Eur J Paediatr Neurol* 2020; 26: 46–60.
- Cabet S, Karl K, Garel C, Delius M, Hartung J, Lesca G, Chaoui R, Guibaud L. Two different prenatal imaging cerebral patterns of tubulinopathy. *Ultrasound Obstet Gynecol* 2021; 57: 493–497.
- Lerman-Sagie T, Pogledic I, Leibovitz Z, Malinger G. A practical approach to prenatal diagnosis of malformations of cortical development. *Eur J Paediatr Neurol* 2021; 34: 50–61.
- Malinger G, Paladini D, Haratz KK, Monteagudo A, Pilu GL, Timor-Tritsch IE. ISUOG Practice Guidelines (updated): sonographic examination of the fetal central nervous system. Part 1: performance of screening examination and indications for targeted neurosonography. *Ultrasound Obstet Gynecol* 2020; 56: 476–484.
- Paladini D, Malinger G, Birnbaum R, Monteagudo A, Pilu G, Salomon LJ, Timor-Tritsch IE. ISUOG Practice Guidelines (updated): sonographic examination of the fetal central nervous system. Part 2: performance of targeted neurosonography. *Ultrasound Obstet Gynecol* 2021; 57: 661–671.
- Hadlock FP, Harrist RB, Sharman RS, Deter RL, Park SK. Estimation of fetal weight with the use of head, body, and femur measurements—a prospective study. *Am J Obstet Gynecol* 1985; 151: 333–337.
- Chavez MR, Ananth CV, Smulian JC, Vintzileos AM. Fetal transcerebellar diameter measurement for prediction of gestational age at the extremes of fetal growth. *J Ultrasound Med* 2007; 26: 1167–1171; quiz 1173–1164.
- Leibovitz Z, Shkolnik C, Haratz KK, Malinger G, Shapiro I, Lerman-Sagie T. Assessment of fetal midbrain and hindbrain in mid-sagittal cranial plane by three-dimensional multiplanar sonography. Part 1: comparison of new and established nomograms. *Ultrasound Obstet Gynecol* 2014; 44: 575–580.
- Cignini P, Padula F, Giorlandino M, Brutti P, Alfò M, Giannarelli D, Mastrandrea ML, D'Emidio L, Vacca L, Aloisi A, Giorlandino C. Reference charts for fetal corpus callosum length: a prospective cross-sectional study of 2950 fetuses. *J Ultrasound Med* 2014; 33: 1065–1078.
- Conte G, Milani S, Palumbo G, Talenti G, Boito S, Rustico M, Triulzi F, Righini A, Izzo G, Doneda C, Zolin A, Parazzini C. Prenatal Brain MR Imaging: Reference Linear Biometric Centiles between 20 and 24 Gestational Weeks. *AJNR Am J Neuroradiol* 2018; 39: 963–967.
- Tilea B, Alberti C, Adamsbaum C, Armoogum P, Oury JF, Cabrol D, Sebag G, Kalifa G, Garel C. Cerebral biometry in fetal magnetic resonance imaging: new reference data. *Ultrasound Obstet Gynecol* 2009; 33: 173–181.
- Reches A, Hiersch L, Simchoni S, Barel D, Greenberg R, Ben Sira L, Malinger G, Yaron Y. Whole-exome sequencing in fetuses with central nervous system abnormalities. *J Perinatol* 2018; 38: 1301–1308.
- Nissenkorn A, Yosovich K, Leibovitz Z, Hartman TG, Zelcer I, Hugarit M, Lev D, Lerman-Sagie T, Blumkin L. Congenital Mirror Movements Associated With Brain Malformations. *J Child Neurol* 2021; 36: 545–555.
- Bahi-Buisson N, Poirier K, Fourniol F, Saillour Y, Valence S, Lebrun N, Hully M, Bianco CF, Boddaert N, Elie C, Lascelles K, Souville I, Beldjord C, Chelly J. The wide spectrum of tubulinopathies: what are the key features for the diagnosis? *Brain* 2014; 137: 1676–1700.
- Mutch CA, Poduri A, Sahin M, Barry B, Walsh CA, Barkovich AJ. Disorders of Microtubule Function in Neurons: Imaging Correlates. *AJNR Am J Neuroradiol* 2016; 37: 528–535.
- Romaniello R, Arrigoni F, Fry AE, Bassi MT, Rees MI, Borgatti R, Pilz DT, Cushion TD. Tubulin genes and malformations of cortical development. *Eur J Med Genet* 2018; 61: 744–754.
- Dentici ML, Maglione V, Agolini E, Catena G, Capolino R, Lanari V, Novelli A, Sinibaldi L, Vecchio D, Gonfiantini MV, Macchiaiolo M, Digilio MC, Dallapiccola B, Bartoli A. *TUBB3* E410K syndrome: Case report and review of the clinical spectrum of *TUBB3* mutations. *Am J Med Genet A* 2020; 182: 1977–1984.
- Laquerrière A, Gonzales M, Saillour Y, Cavallin M, Joyè N, Quélin C, Bidat L, Dommergues M, Plessis G, Encha-Razavi F, Chelly J, Bahi-Buisson N, Poirier K. *De novo TUBB2B* mutation causes fetal akinesia deformation sequence with microlissencephaly: An unusual presentation of tubulinopathy. *Eur J Med Genet* 2016; 59: 249–256.
- Poirier K, Saillour Y, Bahi-Buisson N, Jaglin XH, Fallet-Bianco C, Nabbout R, Castelnau-Ptakhine L, Roubertie A, Attie-Bitach T, Desguerre I, Genevieve D, Barnerias C, Keren B, Lebrun N, Boddaert N, Encha-Razavi F, Chelly J. Mutations in the neuronal β -tubulin subunit *TUBB3* result in malformation of cortical development and neuronal migration defects. *Hum Mol Genet* 2010; 19: 4462–4473.
- Schröter J, Döring JH, Garbade SF, Hoffmann GF, Kölker S, Ries M, Syrbe S. Cross-sectional quantitative analysis of the natural history of *TUBA1A* and *TUBB2B* tubulinopathies. *Genet Med* 2021; 23: 516–523.
- Acanfora MM, Stirnemann J, Marchitelli G, Salomon LJ, Ville Y. Ultrasound evaluation of development of olfactory sulci in normal fetuses: a possible role in diagnosis of CHARGE syndrome. *Ultrasound Obstet Gynecol* 2016; 48: 181–184.

24. Cohen-Sacher B, Lerman-Sagie T, Lev D, Malinger G. Sonographic developmental milestones of the fetal cerebral cortex: a longitudinal study. *Ultrasound Obstet Gynecol* 2006; **27**: 494–502.
25. Azoulay R, Fallet-Bianco C, Garel C, Grabar S, Kalifa G, Adamsbaum C. MRI of the olfactory bulbs and sulci in human fetuses. *Pediatr Radiol* 2006; **36**: 97–107.
26. Jansen AC, Oostra A, Desprechins B, De Vlaeminck Y, Verhelst H, Régal L, Verloo P, Bockaert N, Keymolen K, Seneca S, De Meirleir L, Lissens W. TUBA1A mutations: from isolated lissencephaly to familial polymicrogyria. *Neurology* 2011; **76**: 988–992.
27. Romaniello R, Arrigoni F, Bassi MT, Borgatti R. Mutations in α - and β -tubulin encoding genes: implications in brain malformations. *Brain Dev* 2015; **37**: 273–280.
28. Schmidt L, Wain KE, Hajek C, Estrada-Veras JL, Guillen Sacoto MJ, Wentzensen IM, Malhotra A, Clause A, Perry D, Moreno-De-Luca A, Bell M. Expanding the Phenotype of TUBB2A-Related Tubulinopathy: Three Cases of a Novel, Heterozygous TUBB2A Pathogenic Variant p.Gly98Arg. *Mol Syndromol* 2021; **12**: 33–40.
29. Oegema R, Cushion TD, Phelps IG, Chung SK, Dempsey JC, Collins S, Mullins JG, Dudding T, Gill H, Green AJ, Dobyns WB, Ishak GE, Rees MI, Doherty D. Recognizable cerebellar dysplasia associated with mutations in multiple tubulin genes. *Hum Mol Genet* 2015; **24**: 5313–5325.
30. Blondiaux E, Garel C. Fetal cerebral imaging - ultrasound vs. MRI: an update. *Acta Radiol* 2013; **54**: 1046–1054.
31. Tischfield MA, Cederquist GY, Gupta ML, Jr., Engle EC. Phenotypic spectrum of the tubulin-related disorders and functional implications of disease-causing mutations. *Curr Opin Genet Dev* 2011; **21**: 286–294.
32. Arrigoni F, Romaniello R, Peruzzo D, Poretti A, Bassi MT, Pierpaoli C, Valente EM, Nuovo S, Boltshauser E, Huisman T, Triulzi F, Borgatti R. The spectrum of brainstem malformations associated to mutations of the tubulin genes family: MRI and DTI analysis. *Eur Radiol* 2019; **29**: 770–782.
33. Gardner JF, Cushion TD, Niotakis G, Olson HE, Grant PE, Scott RH, Stoodley N, Cohen JS, Naidu S, Attie-Bitach T, Bonnières M, Boutaud L, Encha-Razavi F, Palmer-Smith SM, Mugalaasi H, Mullins JGL, Pilz DT, Fry AE. Clinical and Functional Characterization of the Recurrent TUBA1A p.(Arg2His) Mutation. *Brain Sci* 2018; **8**.
34. Romaniello R, Arrigoni F, Panzeri E, Poretti A, Micalizzi A, Citterio A, Bedeschi MF, Berardinelli A, Cusmai R, D'Arrigo S, Ferraris A, Hackenberg A, Kuechler A, Mancardi M, Nuovo S, Oehl-Jaschkowitz B, Rossi A, Signorini S, Tüttelmann F, Wahl D, Hehr U, Boltshauser E, Bassi MT, Valente EM, Borgatti R. Tubulin-related cerebellar dysplasia: definition of a distinct pattern of cerebellar malformation. *Eur Radiol* 2017; **27**: 5080–5092.
35. Brock S, Stouffs K, Scalais E, D'Hooghe M, Keymolen K, Guerrini R, Dobyns WB, Di Donato N, Jansen AC. Tubulinopathies continued: refining the phenotypic spectrum associated with variants in TUBG1. *Eur J Hum Genet* 2018; **26**: 1132–1142.
36. Yuen YTK, Guella I, Roland E, Sargent M, Boelman C. Case reports: novel TUBG1 mutations with milder neurodevelopmental presentations. *BMC Med Genet* 2019; **20**: 95.
37. Bartholmot C, Cabet S, Massoud M, Massardier J, Fichez A, Des Portes V, Guibaud L. Prenatal Imaging Features and Postnatal Outcome of Short Corpus Callosum: A Series of 42 Cases. *Fetal Diagn Ther* 2021; **48**: 217–226.

SUPPORTING INFORMATION ON THE INTERNET

The following supporting information may be found in the online version of this article:



Table S1 Pooled data of the 34 enrolled fetuses with mild tubulinopathy