



HAL
open science

Focused ultrasounds: What is their future in epileptology? A critical review

M.D. Maliia, A. Nica, John S H Baxter, M V Corniola

► To cite this version:

M.D. Maliia, A. Nica, John S H Baxter, M V Corniola. Focused ultrasounds: What is their future in epileptology? A critical review. *Revue Neurologique*, 2024, *Revue Neurologique*, 180 (4), pp.348-353. 10.1016/j.neurol.2023.10.014 . hal-04350559

HAL Id: hal-04350559

<https://hal.science/hal-04350559>

Submitted on 29 May 2024

HAL is a multi-disciplinary open access archive for the deposit and dissemination of scientific research documents, whether they are published or not. The documents may come from teaching and research institutions in France or abroad, or from public or private research centers.

L'archive ouverte pluridisciplinaire **HAL**, est destinée au dépôt et à la diffusion de documents scientifiques de niveau recherche, publiés ou non, émanant des établissements d'enseignement et de recherche français ou étrangers, des laboratoires publics ou privés.



Distributed under a Creative Commons Attribution 4.0 International License



Available online at
ScienceDirect
www.sciencedirect.com

Elsevier Masson France
EM|consulte
www.em-consulte.com



Updates on epilepsy

Focused ultrasounds: What is their future in epileptology? A critical review



M.D. Maliia ^{a,b}, A. Nica ^{a,b}, J. Baxter ^b, M.V. Corniola ^{b,c,d,e,f,*}

^a “Van Gogh” Epilepsy Surgery Unit, Neurology Department, CIC 1414, University Hospital, Rennes, France

^b Laboratory of Signal and Image Analysis, LTSI, Inserm U1099, University Rennes 1, Rennes, France

^c Neurosurgery Department, Rennes University Hospital, Rennes, France

^d Faculty of Medicine, University of Rennes, Rennes, France

^e Medicis lab, Inserm UMR 1099 LTSI, University of Rennes, Rennes, France

^f Faculty of Medicine, University of Geneva, Geneva, Switzerland

INFO ARTICLE

Article history:

Received 6 September 2023

Received in revised form

26 September 2023

Accepted 8 October 2023

Available online 12 December 2023

Keywords:

HIFU

Drug-resistant epilepsy

Epilepsy surgery

Neurosurgery

Epileptology

ABSTRACT

High intensity focused ultrasounds (HIFU) are being increasingly advocated as a useful tool in the management of focal drug-resistant epilepsy. Our aim was to review current literature on the topic and perform an inventory of open trials assessing HIFU effectiveness and safety in epilepsy management. To do so, a review was conducted and yielded one prospective clinical trials, two case reports and one safety study were retrieved, indicating that HIFU is still in its infancy when it comes to focal drug-resistant epilepsy therapy. Efforts should be made to develop this technology using multicentric prospective data with larger cohorts and prolonged follow-up.

© 2023 The Author(s). Published by Elsevier Masson SAS. This is an open access article under the CC BY license (<http://creativecommons.org/licenses/by/4.0/>).

1. Introduction

Up to 30% of epileptic patients have drug-resistant epilepsy (DRE) [1], rendering surgical resection of the epileptogenic region a valid treatment option in selected focal DRE patients. Alternatives to resection such as stereotactic radiosurgery (SRS) and laser interstitial thermal therapy (LiTT) have shown quite satisfactory outcomes in terms of epilepsy control. Yet,

open surgery focusing on the resection of the epileptogenic zone (EZ) results in up to 80% seizure-freedom and is thus deemed superior in terms of seizure control and long-term reduction of antiepileptic drugs. Furthermore, drawbacks such as the use of ionizing radiation, the latency of effects, and the need for scalp incision in the case of LiTT have been well-recognized limitations so far. Consequently, open surgery targeting the EZ is still considered as the gold standard treatment of DRE whenever possible.

* Corresponding author at: Service de Neurochirurgie, Pôle des Neurosciences, Centre Hospitalier Universitaire de Rennes, rue Henri-le-Guilloux 2, 35000 Rennes, France.

E-mail address: marcocorniola3@gmail.com (M.V. Corniola).

<https://doi.org/10.1016/j.neurol.2023.10.014>

0035-3787/© 2023 The Author(s). Published by Elsevier Masson SAS. This is an open access article under the CC BY license (<http://creativecommons.org/licenses/by/4.0/>).

In the last decade, the emergence of focused ultrasound (FUS), specifically high intensity focused ultrasound (HIFU), as an innovative and cutting-edge technology has been a game-changer in the field of movement disorders (MD) therapy. Its efficiency as a valid alternative to deep brain stimulation (DBS) in essential tremor (ET) and, more recently, Parkinson's disease (PD) is now fully established.

HIFU involves the emission of converging ultrasound waves, which deposit heat in a specific focal region, eventually achieving thermoablation of a targeted region within the brain. Since HIFU does not require a craniotomy, it can potentially shorten the recovery time and certainly reduces the length of hospital stay. Due to the mechanism of action involving heat deposition, intra-operative magnetic resonance thermometry (MRt) is employed during the procedure as a guidance and feedback modality.

While the rapid implementation of HIFU among MD units has been spectacular in the last few years, the use of FUS in the field of DRE is anecdotic, if not rampant. However, FUS could represent an alternative to open surgery since it could enable disconnection of the EZ. Hence, within the next few years, indications for FUS could be revisited due to the increasing number of trials assessing FUS as a safe and effective adjunct to be implemented in the therapeutic arsenal against DRE. Given the small lesional volume provided by HIFU and based on the current knowledge on resection of focal to very focal EZ, the indications in epilepsy surgery would probably be those of a very focal EZ, whereas in temporal lobe surgery, a very careful selection of cases will be required.

Here, the aim was to critically review current literature on the topic and perform an inventory of the open trials assessing the effectiveness and safety of FUS in DRE management. Eventually, we discuss the applications of low-intensity focused ultrasounds (LIFU), which can also be useful in selected cases of DRE.

2. Methods

A comprehensive review was conducted on July 3rd 2023 searching Embase, Cochrane Library, PubMed, Google Scholar, and Web of Science, with no time limit. The following Medical Subject Heading (MeSH) terms were used: “Focused ultrasound” OR “HIFU” AND “epilepsy”; resulting in a list of 76 articles. No registration was required for this study.

The inclusion criteria were: (i) studies assessing FUS, with magnetic resonance-guided (MRgFUS) or without (FUS), in humans; (ii) retrospective or prospective peer-reviewed research articles involving adult patients diagnosed with DRE; (iii) studies written in English, French, German, or Italian.

Exclusion criteria were: (i) conditions other than DRE; (ii) publications other than original reports and redundant data of a single dataset; (iii) editorials, technical notes, letters, and literature review articles; (iv) studies assessing more than one therapy modality on DRE; (v) non-HIFU techniques; and (vi) non-human studies.

The titles and abstracts of all the articles were screened and all the relevant full-text copies were acquired. Study characteristics (author, year, sample size, study design) were considered.

3. Results

3.1. Articles included

After careful review of abstracts, a total of 10 articles were retained for screening. Six articles failed to assess HIFU in epilepsy. Eventually, four articles – one prospective clinical trial, two case reports, and one safety study [2–4] – met the inclusion criteria (Fig. 1).

All reports assessed ultrasounds in temporal epilepsy; one report studied disconnection in extra-temporal surgery, while one report assessed the effectiveness of thalamic neuromodulation in DRE. Dates of publication and design are summarized in Table 1.

4. Discussion

4.1. State of the art

Our search indicates that development and implementation of FUS in epilepsy are very limited. In total, only four original manuscripts were retrieved for review, of which only one was a prospective study enrolling few patients with rather satisfactory yet limited follow-up. As a comparison, using the MeSH terms “focused ultrasound” OR “HIFU” AND “movement disorders” yielded 139 results, of which seven were clinical trials (Fig. 2), indicating that the use of HIFU in DRE is marginal.

HIFU is a rather recent technology in neuroscience, with limited availability mostly restricted to Europe and North America. At first, HIFU was developed to treat unilateral ET [6,7], while its use in PD targeting the globus pallidus internus (GPI) and the subthalamic nucleus (STN) has been described more recently [8,9]. Wherefore, it appears that the joint ventures involving Insightec® and clinical centers have concentrated their efforts on MD. There are probably multiple reasons for this, but the underlying hypotheses can be formulated as follows: (i) PD and ET are by far predominant over DRE eligible for very limited surgery; (ii) the well-known and somewhat standardized targets of neuromodulation – ventral intermediate nucleus (VIM), subthalamic nucleus (STN), globus pallidus internus (GPI) – can be visualized directly using the latest high-end imaging techniques; and (iii) the central, distant-to-skull base targets, making MD a safer and somewhat easier model to develop an incisionless ablative neuromodulating technique inside the brain.

In their feasibility study, Parker et al. developed a noninvasive HIFU ablation strategy for mesial temporal disconnection, providing tractograms of fornix-fimbria and optic radiations, and maintaining a safety margin between fimbria-fornix outflow and optic radiations [3]. Eventually, the authors were able to demonstrate that targeting the posterior mesio-temporal outflow pathway was feasible, even though it was an experimental, non-interventional study.

Abe et al. were the first group to report a case of HIFU treatment in a patient suffering from mesial temporal lobe epilepsy (MTLE) [4]. The authors targeted the hippocampus but were not able to achieve an ablative procedure because

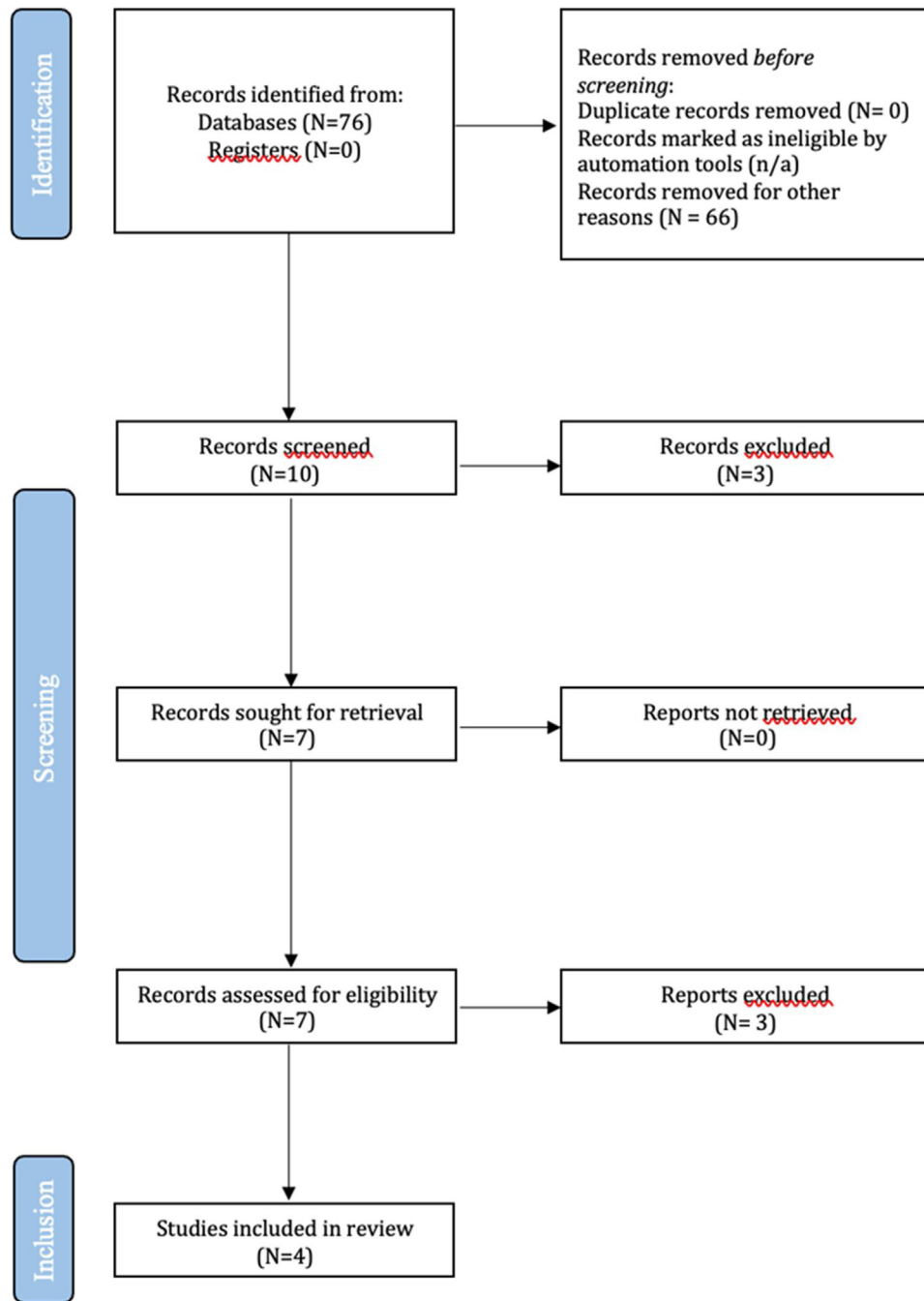


Fig. 1 – Flow chart.

ablation temperature was never reached due to the location of the target. Rather, only “moderate” heating was obtained (max 50°), leading to a neuromodulatory effect. This study shows the previously exposed limitation to the spread of HIFU in DRE, i.e. the inability to reach very central targets, due to their vicinity to the skull base.

Yamaguchi et al. reported the case of a patient with a hypothalamic hamartoma that was disconnected using HIFU. In our opinion, hypothalamic hamartomas may be a clear-cut indication for HIFU, as a paradigm of a very focal EZ located at the midline far from the skull base [5]. Still, this was only a

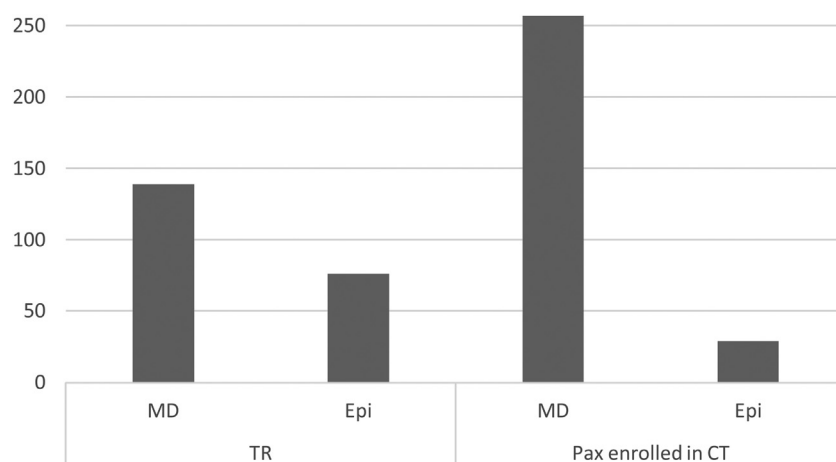
single case report and further data must be collected to assess the safety and efficacy of HIFU in treating hypothalamic hamartomas, especially since optic pathways are in the vicinity and do not tolerate even very moderate heating.

In their pilot study, Krishna et al. assessed safety and effectiveness of targeting the anterior nucleus of the thalamus in two patients suffering from DRE, achieving seizure-freedom and drastic reduction of seizures both patients at 12 months follow-up [2]. Again, this report is based on very few data, illustrating the feasibility but not the safety and the reliability of HIFU in targeting the anterior nucleus of the thalamus.

Table 1 – The four publications retained for this review.

#	Authors	Year	Design	Technique	Transducer	n	Primary endpoint
1	Parker et al. [3]	2019	Feasibility study	HIFU	Large hemispherical phased-array	10	Targeting the fornix-fimbria and temporal lobe outflow
2	Abe et al. [4]	2020	Case report	HIFU	Large hemispherical phased-array	1	First clinical report of MRgFUS in MTLT resulting in seizure-free for up to 12 months
3	Yamaguchi et al. [5]	2020	Case report	HIFU		1	Disconnection of a hypothalamic hamartoma with MRgFUS resulting in seizure-free for 12 months
4	Krishna et al. [2]	2023	Prospective pilot study	HIFU	Large hemispherical phased-array	2	Targeting the ANT in DRE with: patient #1: seizure-free at 12 months, patient 2: frequency reduced from 90–100/month to 3–6/month

MRgFUS: magnetic resonance-guided focused ultrasound; HIFU: high focused ultrasound; EZ: epileptogenic zone; SEEG: stereo-electro-encephalography; ANT; anterior nucleus of thalamus; DRE: drug-resistant epilepsy.

**Fig. 2 – Movement disorders versus epilepsy and HIFU in literature. TR: total reports; MD: movement disorders; Epi: epilepsy; Pax: patients; CT: clinical trials.**

Although its mechanism of action is different, LIFU may also be a useful neurosurgical tool, specifically for neurostimulation. LIFU also uses focused ultrasound waves but at a significantly lower intensity, resulting in minimal heat deposition during a temporary and reversible change in neuronal activity, without visible anatomic alteration of the brain parenchyma.

For example, Brinker et al. were able to deliver repetitive pulsed LIFU across the hippocampus of a patient suffering from MTLT. The patient was described as seizure-free for 12 months [10]. Similarly, Lee et al. used the neuromodulatory effects of LIFU, resulting in spectral modification during stereo-electro-encephalography (SEEG) [10]. In parallel, Stern et al. showed that LIFU does not cause damage to the brain parenchyma [11]. It seems that the neuromodulatory (LIFU) properties of FUS are promising, while its use as a purely thermoablative (HIFU) technology to effectively remove EZ is more limited. The main features of HIFU and LIFU are listed in Table 2.

An important technical consideration for the use of FUS in neurosurgery in general is the selection of a transducer. Single-transducer FUS systems use the geometry of the piezo-

electric element itself (as well as additional material such as a water bag for coupling and element cooling) to passively focus the ultrasound at a particular constant point relative to the transducer. These systems tend to be smaller and are positioned by the operator on the patients scalp close to the desired stimulation target and may include an additional mechanical steering device inside the FUS assembly to modify the focus in order to ablate/modulate a larger area with a specific geometry [10,12,13]. A similar approach can be taken with small phased-array transducers which offer electronic, rather than mechanical, steering of the ultrasound waves and thus more flexibility in determining the ablation/modulation area's geometry and correction for beam aberrations caused by the skull [11]. These two approaches have been principally taken by LIFU systems, rather than HIFU systems, although similar designs have been used for HIFU applications outside of neurosurgery. The last option consists of large hemispherical phased arrays that fit around the greater part of the patient's head [2–4]. These are also electronically focused, allowing for correction of beam aberrations, and their size and angular coverage around the skull allows them to address deep subcortical targets, e.g. for thalamic ablation [2]. The only

Table 2 – Main features of high- and low-intensity focused ultrasound (HIFU and LIFU).

	HIFU	LIFU
Aim	Ablation	Neuromodulation
Intensity	1000 W/cm ²	3 W/cm ²
Emission	> 1000	1
Heating	+++	+
Effect	Permanent	Transient
Clinically available transducers	Large hemispherical phased-array	Single-element transducers & small hemispherical phased-arrays

W: Watts.

neurosurgical HIFU system currently available for clinical application makes use of this transducer type likely due to it being first approved for deep brain ablation which requires said angular coverage.

4.2. Ongoing research

To the best of our knowledge, there are currently only three controlled trials assessing HIFU in epilepsy that are actively recruiting patients. The first one started in 2016 and assesses HIFU in the treatment of focal epilepsy (NCT02804230). The study should be completed in 2023, according to InSightec®, which acts as sponsor. In detail, the study assesses the effectiveness of MRgFUS in thermoablating the EZ by multiple sonications in patients with focal DRE. Broad indications related to temporal and extra-temporal EZ are considered. Its objectives are to include 20 DRE patients from four recruiting US centers.

The second open prospective trial assesses FUS thalamotomy in the prevention of secondary bilateral tonic-clonic generalization in focal epilepsy (NCT03417297). The study started in 2018 and should be completed in 2027, with preliminary results available as early as 2025. Its target population is 10 patients with focal DRE from a single center. As opposed to the aforementioned trial, this study will assess FUS as a direct alternative to DBS in epilepsy, exploring the neuromodulatory properties of FUS. However, the desired neuromodulation will be obtained by a permanent lesion and not by neurostimulation as is the case in DBS.

The third open prospective trial evaluates the safety and effects on anxiety of HIFU in patients suffering from DRE, targeting the anterior nucleus of the thalamus (NCT05032105).

In parallel, five open trials are assessing LIFU as a neuromodulation therapy in temporal lobe epilepsy (NCT03868293; NCT03657056; NCT02151175; NCT05947656; NCT04999046).

In terms of technological research, there have been several recent developments in magnetic resonance imaging-compatible robotic LIFU systems for neuro-interventions using both single-element transducers [14] and smaller phased arrays [15]. The goal of these devices is to improve the accuracy and repeatability of targeting using these transducers, which are less susceptible to operator movement.

4.3. Perspectives

In our opinion, efforts should be made to concentrate on studies addressing FUS in temporal epilepsy, the most common origin of DRE. So far, data available are too limited

to determine whether there is a potential future for HIFU and LIFU in DRE management. Studies such as the experience of Abe et al. indicate that the mesial temporal lobe is beyond the therapeutic range of FUS [11]. One reason is that HIFU was technically unable to attain desired ablation temperatures at deep targets such as the hippocampus or the amygdaloid complex. This is due to the vicinity of the skull base, which produces overheating of the skull that in turn can result in uncontrolled heating of the brain parenchyma.

From that standpoint, using LIFU in the vicinity of the skull base, i.e. as a neuromodulation therapy in temporal lobe epilepsy, should be further assessed as it may offer more realistic perspectives than the HIFU itself. Targets already considered as good candidates for LiTT, such as small lesions, may also represent favorable targets for FUS [16,17]. A net benefit will be provided for those localizations which are difficult to reach or associated with significant risk with traditional neurosurgery, especially in insular-opercular, deep mesial fronto-parietal or cingular locations [18]. These targets are theoretically suitable for FUS as they are distant from the cranial bones.

LIFU may represent a valid alternative to HIFU but provides only transient neuromodulatory effects. These could be insufficient where a definitive and radical disconnection is required.

However, this can also be an alternative for patients refusing surgery or having contraindications for surgical intervention, while HIFU of the deep gray nuclei may also have applications in non-operable drug-resistant generalized epilepsies.

Current studies show that neuromodulation and disconnection may be the keys to the future of the FUS in epilepsy. Analysis of connectivity using diffusion tensor imaging (DTI) and fiber tractography should be fully integrated into FUS technology, since comprehensive understanding of functional networks and their localization are paramount [19,20]. Studies on connectivity of the temporal lobe using DTI could be particularly useful, as it has been the case in ET [21,22].

4.4. Challenges

HIFU is a very focal procedure. The challenge is therefore to find adequate indications, accessible to what it can reasonably be achieved. In anterior and mesial temporal lobe epilepsy HIFU should be compared to selective amygdalohippocampectomy, which is the most focal surgery possible. The outcome should be assessed prospectively with long-term follow-up (3 to 5 years). Patient selection is also a critical point and studies must focus on patients with very focal EZ such as

type IIB focal cortical dysplasia [14,23], hypothalamic hamartomas, or periventricular nodular heterotopias, and on patients with a previous effective DBS which must be explanted for some reason. For LIFU, aside from the technical challenge and its application in humans, the requirement for repetitive procedures may preclude its definitive implementation in clinical practice.

5. Conclusion

Our review shows that HIFU is in its infancy when it comes to focal DRE. The very limited available data illustrate feasibility and limitations of the technique, while multicentric prospective data with larger cohorts and prolonged follow-up are necessary to assess its reliability and overcome its intrinsic limitations, such as the risk of overheating of the brain parenchyma in foci located near the skull base.

Even though research and development were intensified, HIFU would be limited to very focal EZ and, by extension, to very selected cases. In this perspective, HIFU should not be considered as a *game-changer* in epilepsy management in the near future. LIFU, as a non-lesional neuromodulating therapy, is of interest and should not be discarded at this early stage of its development.

Disclosure of interest

The authors declare that they have no competing interest.

REFERENCES

- [1] Brodie MJ, Barry SJ, Bamagous GA, Norrie JD, Kwan P. Patterns of treatment response in newly diagnosed epilepsy. *Neurology* 2012;78(20):1548–54.
- [2] Krishna V, Mindel J, Sammartino F, Block C, Dwivedi AK, Van Gompel JJ, et al. A phase 1 open-label trial evaluating focused ultrasound unilateral anterior thalamotomy for focal onset epilepsy. *Epilepsia* 2023;64(4):831–42.
- [3] Parker WE, Weidman EK, Chazen JL, Niogi SN, Uribe-Cardenas R, Kaplitt MG, et al. Magnetic resonance-guided focused ultrasound for ablation of mesial temporal epilepsy circuits: modeling and theoretical feasibility of a novel noninvasive approach. *J Neurosurg* 2019;1–8. Online ahead of print.
- [4] Abe K, Yamaguchi T, Hori H, Sumi M, Horisawa S, Taira T, et al. Magnetic resonance-guided focused ultrasound for mesial temporal lobe epilepsy: a case report. *BMC Neurol* 2020;20(1):160.
- [5] Yamaguchi T, Hori T, Hori H, Takasaki M, Abe K, Taira T, et al. Magnetic resonance-guided focused ultrasound ablation of hypothalamic hamartoma as a disconnection surgery: a case report. *Acta Neurochir (Wien)* 2020;162(10):2513–7.
- [6] Elias WJ, Huss D, Voss T, Loomba J, Khaled M, Zadicario E, et al. A pilot study of focused ultrasound thalamotomy for essential tremor. *N Engl J Med* 2013;369(7):640–8.
- [7] Elias WJ, Lipsman N, Ondo WG, Ghanouni P, Kim YG, Lee W, et al. A randomized trial of focused ultrasound thalamotomy for essential tremor. *N Engl J Med* 2016;375(8):730–9.
- [8] Krishna V, Fishman PS, Eisenberg HM, Kaplitt M, Baltuch G, Chang JW, et al. Trial of globus pallidus focused ultrasound ablation in Parkinson's disease. *N Engl J Med* 2023;388(8):683–93.
- [9] Martinez-Fernandez R, Manez-Miro JU, Rodriguez-Rojas R, Del Alamo M, Shah BB, Hernandez-Fernandez F, et al. Randomized trial of focused ultrasound subthalamotomy for Parkinson's disease. *N Engl J Med* 2020;383(26):2501–13.
- [10] Brinker ST, Preiswerk F, White PJ, Mariano TY, McDannold NJ, Bubrick EJ. Focused ultrasound platform for investigating therapeutic neuromodulation across the human hippocampus. *Ultrasound Med Biol* 2020;46(5):1270–4.
- [11] Lee CC, Chou CC, Hsiao FJ, Chen YH, Lin CF, Chen CJ, et al. Pilot study of focused ultrasound for drug-resistant epilepsy. *Epilepsia* 2022;63(1):162–75.
- [12] Stern JM, Spivak NM, Becerra SA, Kuhn TP, Korb AS, Kronemyer D, et al. Safety of focused ultrasound neuromodulation in humans with temporal lobe epilepsy. *Brain Stimul* 2021;14(4):1022–31.
- [13] Schafer ME, Spivak NM, Korb AS, Bystritsky A. Design, development, and operation of a low-intensity focused ultrasound pulsation (LIFUP) system for clinical use. *IEEE Trans Ultrason Ferroelectr Freq Control* 2021;68(1):54–64.
- [14] Kim J, Lee S. Development of a wearable robotic positioning system for noninvasive transcranial focused ultrasound stimulation. In: *IEEE/ASME transactions on mechatronics*. New York: IEEE; 2016: 2284–93.
- [15] Seo J, Shin H, Cho S, Lee S, Ryu W, Han SC, et al. A phased array ultrasound system with a robotic arm for neuromodulation. *Med Eng Phys* 2023;118:104023.
- [16] Bourdillon P, Rheims S, Catenox H, Montavont A, Ostrowsky-Coste K, Isnard J, et al. Malformations of cortical development: new surgical advances. *Rev Neurol (Paris)* 2019;175(3):183–8.
- [17] Hoppe C, Helmstaedter C. Laser interstitial thermotherapy (LiTT) in pediatric epilepsy surgery. *Seizure* 2020;77:69–75.
- [18] Ryvlin P, Nguyen DK. Insular seizures and epilepsies: ictal semiology and minimal invasive surgery. *Curr Opin Neurol* 2021;34(2):153–65.
- [19] Alizadeh M, Kozlowski L, Muller J, Ashraf N, Shahrapour S, Mohamed FB, et al. Hemispheric regional based analysis of diffusion tensor imaging and diffusion tensor tractography in patients with temporal lobe epilepsy and correlation with patient outcomes. *Sci Rep* 2019;9(1):215.
- [20] Hori H, Yamaguchi T, Konishi Y, Taira T, Muragaki Y. Correlation between fractional anisotropy changes in the targeted ventral intermediate nucleus and clinical outcome after transcranial MR-guided focused ultrasound thalamotomy for essential tremor: results of a pilot study. *J Neurosurg* 2019;132(2):568–73.
- [21] Chazen JL, Sarva H, Stieg PE, Min RJ, Ballon DJ, Pryor KO, et al. Clinical improvement associated with targeted interruption of the cerebellothalamic tract following MR-guided focused ultrasound for essential tremor. *J Neurosurg* 2018;129(2):315–23.
- [22] Salehi F, Sharma M, Peters TM, Khan AR. White matter tracts in patients with temporal lobe epilepsy: pre- and postoperative assessment. *Cureus* 2017;9(10):e1735.
- [23] Pernot M, Aubry J-F, Tanter M, Andre F, Fink M. Prediction of the skull overheating during high intensity focused ultrasound transcranial brain therapy. In: *IEEE Ultrasonics Symposium*. Montreal, QC; 2004.