



**HAL**  
open science

## Epidural lipomatosis in Cushing s syndrome causing regressive paraplegia

Caroline Bogeat, Mathilde Brière, Marie-Laure Raffin-Sanson, Mirella Hage,  
Caroline Hugeron

► **To cite this version:**

Caroline Bogeat, Mathilde Brière, Marie-Laure Raffin-Sanson, Mirella Hage, Caroline Hugeron. Epidural lipomatosis in Cushing s syndrome causing regressive paraplegia. *Annales d'Endocrinologie* = *Annals of Endocrinology*, 2023, 84 (1), 10.1016/j.ando.2022.11.002 . hal-04349657

**HAL Id: hal-04349657**

**<https://hal.science/hal-04349657>**

Submitted on 19 Dec 2023

**HAL** is a multi-disciplinary open access archive for the deposit and dissemination of scientific research documents, whether they are published or not. The documents may come from teaching and research institutions in France or abroad, or from public or private research centers.

L'archive ouverte pluridisciplinaire **HAL**, est destinée au dépôt et à la diffusion de documents scientifiques de niveau recherche, publiés ou non, émanant des établissements d'enseignement et de recherche français ou étrangers, des laboratoires publics ou privés.

# **Epidural lipomatosis in Cushing's syndrome causing regressive paraplegia**

*Caroline Bogeat, Caroline Hugeron, Mathilde Brière, Marie-Laure Raffin-Sanson, Mirella Hage*

A 59-year-old man with anticoagulated fibrillation and sensory- motor deficit on a multi-operated spine was referred to our endocrinology department for Cushing's syndrome. Diagnosis was based on the discovery of an epidural lipomatosis during work-up for worsening neurological deficit and onset of paraplegia (Fig. 1A).

Laboratory testing revealed elevated 24-hour urinary free cortisol (UFC) (3,813 nmol/L;  $n < 248$  nmol/L), non-suppressed cortisol following overnight dexamethasone suppression test (119 nmol/L;  $n < 50$ ) and elevated ACTH (14 pmol/L;  $n < 13$  pmol/L), indicating ACTH-dependent Cushing's syndrome. Increased ACTH and cortisol levels after desmopressin and corticotropin-releasing hormone (CRH) stimulation suggested a pituitary origin; however, pituitary MRI was normal.

Given the severity of the clinical picture (compressive lipomatosis, pulmonary embolism and hypokalemia), the presence of anticoagulant treatment and the absence of a surgical target, pharmacological treatment combining mitotane (4.5 g/24 hrs), metyrapone (3 g/24 h) and ketoconazole (400 mg/24 h) was started, and achieved rapid decrease and normalization of UFC at 3 months. The patient was then maintained on mitotane alone (3 g/24 h).

After 1 year of pharmacological treatment, regression of the lipomatosis was observed on MRI (Fig. 1B), with clear clinical improvement including resumption of walking with support. Surgical exploration of the pituitary gland was performed, but found no pituitary adenoma.

The patient was successfully maintained postoperatively on mitotane at a lower dose (1.5 g/24 h), with good control of cortisol secretion and minimal side-effects. Investigation in search of the origin of the ACTH secretion was pursued, with pituitary MRI, total body CT scan and MRI, DOTATOC scintigraphy, etc., but no etiology was so far identified. Neurological symptoms improved gradually.

After 2 years of eucortisolism under medical treatment and with intensive rehabilitation, the patient was able to walk more than 1 km without support.

## **1. Discussion**

Epidural spinal lipomatosis consists in excessive deposition of fat in the spinal canal, which can lead to spinal cord compression. It is a rare but well-documented complication of long-term corticosteroid therapy, with over 50 published cases

and, to our knowledge, only 10 cases reported in endogenous Cushing's syndrome [1–10]. Exogenous steroid use is the most common cause of this condition (55% of cases), followed by obesity (25%), Cushing's syndrome (3%) and idiopathic causes (17%) [1,3,11]. Rare cases have been described in hypothyroidism [12,13] and 1 case following bilateral spinal decompression [14]. Epidural spinal lipomatosis is more frequently observed in young men. First-line treatment targets the underlying etiology. Neurological recovery is often observed within a few months. Decompressive laminectomy is sometimes necessary.

In the 10 cases of endogenous Cushing's syndrome, the causes of hypercortisolism were Cushing's disease ( $n = 5$ ), ectopic ACTH syndrome ( $n = 3$ ), or adrenal tumor ( $n = 2$ ). Eight cases were in men (median age: 33 years, range [17–36]) and 2 in women (49 and 58 years old). Interestingly, in all male patients, posterior epidural lipomatosis was responsible for spinal cord compression at the thoracic level, causing more or less complete paraplegia and sensory symptoms mainly at the mid-thoracic level. In the two women, lipomatosis was revealed by sciatica and L5 and S1 nerve root compression [2,6].

The therapeutic approach in most patients consisted in treating hypercortisolism by surgical resection of the causal tumor, sometimes associated to medical therapy. Marked improvement or complete regression of neurological symptoms was seen by 4 to 6 months, lasting up to 2 years after control of hypercortisolism. Spinal surgery was performed in only 2 cases [3,8].

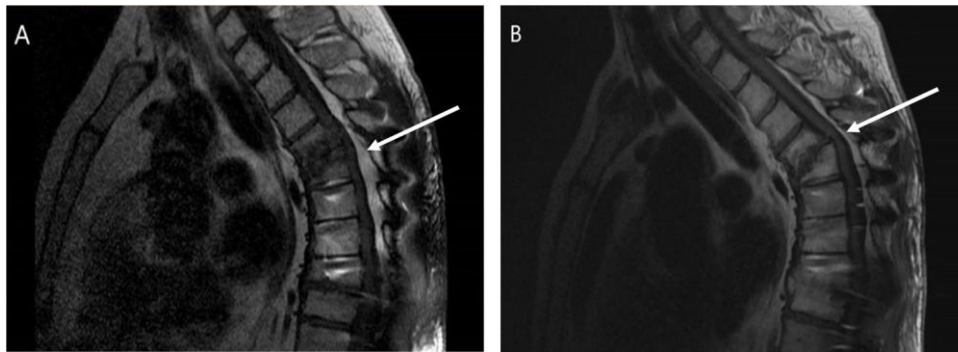
In our patient, the origin of the ACTH hypersecretion was still undetermined at 10 years' follow-up. Achieving normal cortisol levels by pharmacological treatment led to regression of the epidural spinal lipomatosis and improvement in neurological symptoms.

Compressive epidural lipomatosis secondary to endogenous Cushing's syndrome should be considered in patients with neurological deficit and signs of hypercortisolism. More research is needed to determine whether thoracic epidural fat has a particular sensitivity to cortisol, especially in men, causing hypertrophy and, in rare cases, spinal compression.

## References

- [1] Ahmad S, Best T, Lansdown A, Hayhurst C, Smeeton F, Davies S, et al. Spinal epidural lipomatosis: a rare association of cushing's disease. *Endocrinol Dia- betes Metab Case Rep* 2020;2020:1–6.
- [2] Benamou PH, Hilliquin P, Chemla N, Chevrot A, Cormier C, Menkès CJ. Epidural lipomatosis not induced by corticosteroid therapy. Three cases including one in a patient with primary Cushing's disease (review of the literature). *Joint Bone Spine* 1996;63:207–12.
- [3] Bhatia K, Frydenberg E, Steel T, Ow-Yang M, Ho K, Grainger E. Spinal epidu- ral lipomatosis due to a bronchial ACTH-secreting carcinoid tumour. *J Clin Neurosci* 2010;17:1461–2.
- [4] Bodelier AG, Groeneveld W, van der Linden AN, Haak HR. Symptomatic epidural lipomatosis in ectopic Cushing's syndrome. *Eur J Endocrinol* 2004;151:765–9.
- [5] Chaudhary K, Chandy D, Agrawal V, Dhawale A, Nagaonkar S. Spinal epidural lipomatosis with osteoporotic vertebral fractures presenting as acute thoracic myelopathy in a 33-year-old man with cushing disease. *World Neurosurg* 2020;142:136–41.
- [6] Dumont-Fischer D, Rat A-C, Saidenberg-Kermanac'h N, Laurent S, Cohen R, Boissier M-C. Lipomatose épidurale révélatrice d'un syndrome de Cushing endogène. *Joint Bone Spine* 2002;69:317–20.
- [7] Koch CA, Doppman JL, Watson JC, Patronas NJ, Nieman LK. Spinal epidural lipo- matosis in a patient with the ectopic corticotropin syndrome. *N Engl J Med* 1999;341:1399–400.
- [8] Mukhtar N, Alzahrani AS. Spinal epidural lipomatosis: a rare and frequently unrecognized complication of Cushing syndrome. *Endocrine* 2022;76:218–23.
- [9] Noël P, Pepersack T, Vanbinst A, Allé JL. Spinal epidural lipomatosis in Cushing's syndrome secondary to an adrenal tumor. *Neurology* 1992;42:1250–1.
- [10] Sivakumar K, Sheinart K, Lidov M, Cohen B. Symptomatic spinal epidural lipo- matosis in a patient with Cushing's disease. *Neurology* 1995;45:2281–3.

- [11] Fogel GR, Cunningham PY, 3rd, Esses SI. Spinal epidural lipomatosis: case reports, literature review and meta-analysis. *Spine J* 2005;5:202–11.
- [12] Koch CA, Doppman JL, Patronas NJ, Nieman LK, Chrousos GP. Do glucocorticoids cause spinal epidural lipomatosis? When endocrinology and spinal surgery meet. *Trends Endocrinol Metab* 2000;11:86–90.
- [13] Toshniwal PK, Glick RP. Spinal epidural lipomatosis: report of a case secondary to hypothyroidism and review of literature. *J Neurol* 1987;234:172–6.
- [14] Greenish D, Watura K, Harding I. Spinal epidural lipomatosis following bilateral spinal decompression surgery. *BMJ Case Rep* 2019;12:1–3.



**Fig. 1.** MRI aspect of epidural lipomatosis on median T1-weighted sagittal slice (hypersignal lipomatosis is indicated by the arrow). Imaging was carried out before (panel A) and 22 months after treatment (panel B).