



HAL
open science

Alternative Flap Options for Upper Extremity Reconstruction

Yanis Berkane, Riccardo Giorgino, Zhi Yang Ng, Ruben Dukan, Alexandre G Lellouch

► **To cite this version:**

Yanis Berkane, Riccardo Giorgino, Zhi Yang Ng, Ruben Dukan, Alexandre G Lellouch. Alternative Flap Options for Upper Extremity Reconstruction. *Hand Clinics*, 2024, *Hand Clinics*, 40 (2), pp.291-299. <10.1016/j.hcl.2023.08.010>. <hal-04344676>

HAL Id: hal-04344676

<https://hal.science/hal-04344676v1>

Submitted on 28 Feb 2024

HAL is a multi-disciplinary open access archive for the deposit and dissemination of scientific research documents, whether they are published or not. The documents may come from teaching and research institutions in France or abroad, or from public or private research centers.

L'archive ouverte pluridisciplinaire **HAL**, est destinée au dépôt et à la diffusion de documents scientifiques de niveau recherche, publiés ou non, émanant des établissements d'enseignement et de recherche français ou étrangers, des laboratoires publics ou privés.



HAL Authorization

Title Page:

- **Article Title:** Alternative flap options for upper extremity reconstruction

- **Author Names, Degrees, and Affiliations**

Yanis Berkane^{1,2,3} #, MD, MSc; Riccardo Giorgino^{4,5,6} #, MD; Zhi Yang Ng⁷, MBChB, MRCS, PgDip, PhD; Ruben Dukan⁸, MD, MSc; Alexandre G. Lellouch, MD, PhD²

1 Department of Plastic, Reconstructive and Aesthetic Surgery, CHU Rennes, Rennes University, Rennes, France

2 Vascularized Composite Allotransplantation Laboratory, Massachusetts General Hospital, Harvard Medical School, Boston, MA

3 UMR U1236-MICMAC, Immunology and Cell Therapy Lab, Rennes University Hospital, Rennes, France

4 Residency Program in Orthopaedics and Traumatology, University of Milan, Milan, Italy

5 IRCCS Istituto Ortopedico Galeazzi, Milan, Italy

6 Wellman Center for Photomedicine, Massachusetts General Hospital, Harvard Medical School, Boston, MA

7 Department of Plastic and Reconstructive Surgery, John Radcliffe Hospital, Oxford University Hospitals NHS Foundation Trust, Oxford, United Kingdom

8 Department of Hand, Upper Limb & Peripheral Nerve Surgery, Georges-Pompidou European Hospital (HEGP), Paris – France

Contributed equally

- **Mailing addresses and Email addresses**

- *Y.B., A.G.L.: VCA laboratory, 50 Blossom St, Boston, MA 02114
email: yberkane@mgh.harvard.edu; alellouch@mgh.harvard.edu*
- *R.G.: Plastic Surgery Research Laboratory, 50 Blossom St, Boston, MA 02114
email: rgiorgino@mgh.harvard.edu*
- *Z.Y.N.: Department of Plastic and Reconstructive Surgery, John Radcliffe Hospital, Oxford University Hospitals NHS Foundation Trust, Headley Way, Headington, Oxford, OX3 9DU, United Kingdom
email: zhiyang.ng@gmail.com*
- *R.D.: Department of Orthopaedics, Georges Pompidou European Hospital, 20 rue Leblanc, 75015 Paris, France
email: ruben.dukan@gmail.com*

- **Corresponding Author**
 - *Alexandre G. Lellouch, MD, PhD*
 - *Vascularized Composite Allotransplantation Laboratory*
 - *50 Blossom Street, Massachusetts General Hospital*
 - *Boston, MA 02114*
 - *E-mail: alellouch@mgh.harvard.edu*
- **Disclosure Statement**
 - *The Authors have nothing to disclose.*
- **Key Words**
 - Upper extremity, flap reconstruction, DIEP flap, SCIP flap, Microsurgical reconstruction
- **Key Points** (3-5 bulleted sentences indicating the main takeaways/defining elements of the article)
 - Various flap techniques exist for the reconstruction of major upper limb defects, with positive outcomes in success rate, function, and aesthetics
 - Alternative free flap options exist other than the widely used ALT; these include the bi-pedicled DIEP flap for extensive defects, and the SCIP flap which represents a newer alternative with promising results
 - While fasciocutaneous flaps are ideal, their complexity requires case-by-case assessment, and muscle flaps remain a viable alternative
- **Synopsis** (100 words or less)

For major upper limb defects, a wide range of established pedicled and free flap options can be utilized. These include the latissimus dorsi/TDAP, lateral arm, PIA, rectus abdominis, gracilis, ALT. Technical proficiency is essential, and favorable success rates in terms of functional and aesthetic outcomes can be achieved. Herein, alternative flap options (both pedicled and free) are introduced and discussed through a few illustrative case examples.

INTRODUCTION

The reconstructive approach towards major defects of the upper limb has evolved over time. Muscle flaps have progressively been replaced by fasciocutaneous flaps that show similar or better outcomes with lower morbidity (e.g. less tendon adhesions)¹⁻³. With improvements in surgical techniques and anatomical knowledge, available fasciocutaneous options have evolved even further. They can be used in a variety of configurations, such as free or pedicled and even propeller flaps^{4,5}.

When available, pedicled flaps are a reliable solution for defects of the upper extremity⁶. McGregor first described two-stage pedicled groin flaps⁷⁻⁹ using neo-vascularization (or autonomization) principles^{10, 11}. While this traditional technique is less commonly used nowadays^{12, 13}, it has inspired several solutions, such as the superficial inferior epigastric artery (SIEA)¹⁴, lateral intercostal artery perforator (LICAP)¹⁵, and paraumbilical flaps¹⁶. In one-stage reconstruction, the pedicled thoracodorsal artery perforator (TDAP) flap can be used to cover proximal defects from the axillary fold to the elbow^{17, 18}. Its pedicle length can be up to 25cm allowing elbow reconstruction with little to no tension¹⁹. Other established pedicled options include the lateral arm flap^{20,21} and the posterior interosseous artery flap^{22,23}, depending on the defect location.

Current free flap options are led by the anterolateral thigh (ALT) flap, which has established itself as the workhorse for the modern reconstruction of major upper limb defects²⁴⁻²⁶. Refinements in recent years have led to improvement of the initial technique with super-thin dissection planes²⁷, double skin paddles²⁸, and turbocharging²⁹, thereby improving safety and functional and cosmetic outcomes. This perforator-based approach has been supplemented by similar options, such as the free TDAP³⁰⁻³² and, more recently, superficial circumflex iliac artery perforator (SCIP) flaps³³⁻³⁵.

Finally, the development of the profunda artery perforator (PAP) flap in breast reconstruction has led to alternative, novel use in the upper limb³⁶. Further refinements of the PAP flap, with thin and super-thin dissection planes, allow the attainment of excellent outcomes and are now used as the procedure of choice in some centers³⁷. Such modern perforator flaps require meticulous dissection, and improvements in pre-operative planning through computed tomography angiography and color duplex ultrasonography have emerged^{37,38}.

All these microsurgical solutions demand a high level of technical ability and stringent postoperative monitoring protocols but can be limited by the operative time and the patient's overall condition. It is thus critical for the hand surgeon to master several reconstructive techniques. Therefore, the objective of this work is to discuss alternative flap options for major upper limb defect reconstruction through the use of some illustrative case examples.

ALTERNATIVE FLAP OPTIONS

We have selected four different flap techniques performed at our centers for patients with major soft tissue defects of the upper limb that required flap surgery (free or pedicled). Table 1 illustrates the variety of indications and contexts.

Case 1. Free bi-pedicled deep inferior epigastric artery perforator (DIEP) flap

The first case describes a 64-year-old female with type 2 diabetes who suffered a comminuted open fracture of the left humerus and a degloving injury to her left upper limb in a road traffic accident. The patient was intubated in the emergency department at another institution, where a trauma computed tomography (CT) and CT angiography were performed. The CT showed a minor

pulmonary embolism, but no other injuries were found. The patient was then transferred to our center, where she underwent an exploration of the left brachial artery, followed by thrombectomy and a bovine pericardial patch repair performed by the vascular surgeons. An open reduction and internal fixation (ORIF) was then performed on the left radius, with external fixation of the humerus. The external fixation was considered the definitive management due to the already compromised soft tissues in a case complicated by COVID-19 positivity and underlying diabetes, which increased the risks of infection and delayed healing.

In order to cover the resulting soft tissue defect that was near circumferential (Fig 1A), a free bi-pedicled DIEP was performed to resurface the left upper limb. An intra-flap anastomosis (end-to-end) was performed between the “opposite” DIEP pedicle to a branch of the main DIEP pedicle, followed by an extra-flap anastomosis between the DIEA and DIEV to the brachial artery (end-to-side) and the cephalic vein (end-to-end), respectively (Fig 1B). The extended DIEP-based flap allowed for tension-free closure and full coverage of the soft tissue defect (Fig 1C). The donor site was also closed easily as per a standard DIEP procedure (Fig 1D). The patient’s postoperative course was otherwise unremarkable, and primary healing was obtained, with a satisfactory aesthetic and functional outcome at one year of follow-up (Fig 1E). This case illustrates the benefit of the bi-pedicled technique based on the same principles as supercharging³⁹⁻³¹ and turbocharging^{29,40}, improving blood flow through multiple anastomoses to achieve the survival of an extended flap beyond the angiosome of a single perforator. Therefore, the bi-pedicled DIEP flap can be an option in patients with a moderate-to-high body mass index who have sustained major degloving injuries⁴².

Case 2. Pedicled latissimus dorsi flap

Our second patient was a 27-year-old man with ciliary dyskinesia and who was an active smoker. He was the victim of an assault with a firearm (pellet gun) resulting in major trauma of the left arm with extended loss of skin from the mid-arm to the elbow. No significant bone damage was found. Emergent surgical exploration revealed the absence of the radial pulse, preservation of the ulnar pulse, hypoesthesia of the hand, and subtotal loss of prehension in terms of neurological signs. Decompression of the radial artery by evacuating a hematoma allowed for flow restoration. No nerve discontinuity was observed in the radial, ulnar, and median nerves. The elbow joint was preserved. After soft tissue debridement, the defect was extensive (Fig 2A).

In view of the potential for partial vascular damage (given the initial loss of radial artery flow), a free flap was considered risky by our team. A pedicled solution was decided upon, and since the defect size was major, a musculocutaneous latissimus dorsal (LD) flap was preferred to a TDAP, with the best benefit-risk ratio (short surgery time, safety, robustness of the flap). The flap was harvested with the patient in an intermediate supine/lateral decubitus position. A vertical skin paddle was drawn to allow for optimal flap inset after 45 degrees of rotation (Fig 2B). The distal tendon of the LD flap was used to reconstruct the distal biceps. Video A (Supplementary Digital Content) shows the resulting contraction, eventually allowing restoring flexion of the elbow. A strip of muscle in the left arm was left exposed to avoid compression of the pedicle (Fig 2C) with the placement of a split-thickness skin graft two weeks later. Complete wound healing was achieved, and the patient could start physiotherapy after six weeks, with a satisfactory functional outcome at four months follow-up (Fig 2D). This case illustrates that while fasciocutaneous free flaps are in vogue for modern upper extremity defect reconstruction, it is still important to consider

the robustness of pedicled musculocutaneous flaps⁴³. While a vascularized skin paddle should be preferred for the fold and joint areas to avoid motion range limitation, major defects in the context of emergency can be managed adequately with muscle coverage and delayed skin grafting⁴⁴.

Case 3. Pedicled brachioradialis muscle flap

The third case was that of a 19-year-old man with no past medical history who was involved in a mountain biking accident. He sustained trauma to the right upper limb resulting in an open trans-olecranon fracture dislocation associated with a closed comminuted distal radius fracture. His initial surgery was performed at a local facility where he had sustained the injury, using an external fixator. The patient then presented to our center at POD 15 with a wound infection and was taken to the OR. After debridement, an open reduction and osteosynthesis of the olecranon was performed using a screwed plate (Variax, Stryker, Michigan, USA) (Figure 3A). A brachioradialis muscle flap (Figure 3B) associated with a local rotation skin flap was then used for hardware coverage. Additional acellular dermal matrix (ADM) (Duragen, Integra Lifescience, Princeton, NJ) was applied and affixed with staples (Figure 3C) The distal radial fracture was reduced and fixed with a volar locking plate (Aptus, Medartis, Bale, Switzerland). The joint surface was reduced under arthroscopic control and fixed with K-wires. A split-thickness skin graft was performed 3 weeks after application of the ADM, and full wound healing was obtained after 4 weeks. No complication was reported, and the patient achieved a satisfactory range of motion (flexion 130°, extension -20°, Pronation 80°, Supination 80°) (Figure 3D). This case emphasizes the usefulness of local muscle flaps that represent an efficient solution in such difficult situations by obtaining well-vascularized tissue for coverage and providing an optimal wound bed for skin grafting⁴⁵. The brachioradialis flap has been described as an alternative for posterior elbow

wounds⁴⁶. In addition, to improve the quality of the healed tissue, ADM has proven to be a valuable tool in the upper extremity^{47,48}.

Case 4. Free SCIP flap

Finally, the last patient was a 58-year-old female who was treated four months previously for a right forearm sarcoma with surgery and post-operative adjuvant radiotherapy who then presented with radiodermatitis and consequent exposure of the underlying radius (Fig. 4A). Unfortunately, the patient was still actively smoking. After a multidisciplinary team discussion, wide soft tissue resection with bone trimming was decided upon, followed by one-stage soft tissue coverage. Given the location of the defect, a free SCIP flap raised along the superficial fat layer above the superficial fascia, in erthin fashion, was chosen (Fig. 4B). The flap was harvested on the superficial branch of the SCIA only, and the vessels were anastomosed end-to-side to the radial artery and accompanying venae comitantes (Fig. 4C and 4D). No postoperative complication occurred, and the patient's wound had fully healed after four weeks. The result was found to be excellent, with minimal contour deformity of the flap in the forearm after one year (Fig. 4E). The flap's thinness also allowed the patient to resume her usual activities. The donor site healed without complication. The SCIP flap shows high adaptability through the variable thickness, adjustable pedicle length, and flap dimensions^{33, 34}.

DISCUSSION

These selected cases demonstrate the effectiveness of various modern reconstructive techniques for major defects of the upper limbs resulting from various etiologies, with high technical success, satisfactory functional and aesthetic results, and a low rate of complications. Therefore, the modern

hand and reconstructive microsurgeon should keep in mind that alternative solutions, both pedicled and free, do exist besides well-established approaches such as the ALT and TDAP flaps.

LIMITATIONS

One critical parameter missing in our case series and poorly described in the literature is assessing the quality of life following upper limb reconstruction. It could be highly informative to assess function and quality of life using validated questionnaires, such as the Upper Extremity Function Test or the Sollerman hand function test, to better objectively assess the outcomes of all different alternatives. That, however, is beyond the scope of the current manuscript.

SUMMARY

In conclusion, the discussion around this series of patient cases demonstrates the efficacy of various flap reconstruction techniques for major upper limb defects, with favorable outcomes regarding success rate and functional and aesthetic results. Bi-pedicled DIEP flaps can be used for selected patients with extensive defects. Various refinements can improve ALT flaps to reach even better outcomes, while SCIP flaps represent an attractive newer alternative providing high-quality results. Reconstructive surgeons have a range of solutions at their disposal, among which fasciocutaneous flaps are generally considered the most optimal given the functional requirements of the hand. However, technical sophistication and complexity of these options require a case-by-case assessment. Simpler solutions, such as pedicled musculocutaneous flaps combined with skin grafts, should also be part of our armamentarium to ensure that patient outcomes are not compromised regardless of the circumstances.

Clinics Care Points – *Bulleed list of evidence-based pearls and pitfalls relevant to the point of care :*

- *Alternative flap options for reconstruction of major defects of the upper limb can be used successfully*
- *Bipedicled DIEP flaps can be an adequate solution for extensive and deep defects in patients with soft tissue excess at the donor site*
- *Pedicled myocutaneous/ muscle flaps such as the latissimus dorsi and brachioradialis flaps are invaluable options in cases where microsurgery may not be suitable*
- *Newer techniques, such as free SCIP flaps, are challenging but can provide superior results in selected patients*

Acknowledgments:

We would like to acknowledge Mr. Marios Nicolaou from the Odstock Regional Centre for Burns, Plastic and Reconstructive Surgery, Salisbury District Hospital, Wiltshire, United Kingdom, for providing consented pictures of the patient discussed in case 1, and Pr. Nicolas Bertheuil and Dr. Paul Girard from Rennes University Hospital Center, France for providing consented pictures of the patient discussed in case 4.

References

1. Ng, Z. Y. et al. Soft Tissue Reconstruction of Complete Circumferential Defects of the Upper Extremity. *Archives of plastic surgery*, 44(2), 117–123 (2017).
2. Ng, Z. Y., Salgado, C. J., Moran, S. L., & Chim, H. Soft tissue coverage of the mangled upper extremity. *Seminars in plastic surgery*, 29(1), 48–54(2015).
3. Ng, Z. Y., Askari, M., & Chim, H. Approach to complex upper extremity injury: an algorithm. *Seminars in plastic surgery*, 29(1), 5–9 (2015).
4. Kovar, A., Colakoglu, S. & Iorio, M.L. A Systematic Review of Muscle and Fasciocutaneous Flaps in the Treatment of Extremity Osteomyelitis: Evidence for Fasciocutaneous Flap Use. *Plastic and Reconstructive Surgery – Global Open* 7, 1-2 (2019).
5. Vitse, J. et al. Perforator-based propeller flaps reliability in upper extremity soft tissue reconstruction: a systematic review. *J Hand Surg Eur Vol* 42, 157-164 (2017).
6. Sananpanich, K., Tu, Y.K., Kraissarin, J. & Chalidapong, P. Reconstruction of limb soft-tissue defects: using pedicle perforator flaps with preservation of major vessels, a report of 45 cases. *Injury* 39 Suppl 4, 55-66 (2008).
7. McGregor, I.A. Basic principles in skin flap transfer. *Surg Clin North Am* 57, 961-976 (1977).
8. McGregor, I.A. Flap reconstruction in hand surgery: the evolution of presently used methods. *J Hand Surg Am* 4, 1-10 (1979).
9. McGregor, I.A. & Jackson, I.T. The groin flap. *Br J Plast Surg* 25, 3-16 (1972).
10. Giordano, L., et al. Head and neck pedicled flap autonomization using a new high-resolution indocyanine green fluorescence video-angiography device. *Head & neck*, 44(6), 1496–1499 (2022).
11. Berkane, Y. et al. The Superficial Inferior Epigastric Artery Axial Flap to Study Ischemic Preconditioning Effects in a Rat Model. *J Vis Exp* (2023).
12. Rubio-Gallegos, F., Núñez-González, S., Gault, C., Simancas-Racines, D. & Basantes-García, E. McGregor inguinal flap for coverage of large soft tissue losses due to high-voltage electrical burns in the upper limb: a retrospective study. *Int J Burns Trauma* 9, 52-58 (2019).
13. Buchman, S.J., Eglseider, W.A., Jr. & Robertson, B.C. Pedicled groin flaps for upper-extremity reconstruction in the elderly: a report of 4 cases. *Arch Phys Med Rehabil* 83, 850-854 (2002).
14. Habib, M.E. & Reuter, C.H. Bilateral Pedicled Superficial Epigastric Flap in the Management of Circumferential Combined Degloving and Full Thickness Burn Hand Injury^o™A Case Report. *Modern Plastic Surgery Vol.02No.02*, 4 (2012).
15. Yunchuan, P., Jiaqin, X., Sihuan, C. & Zunhong, L. Use of the Lateral Intercostal Perforator-Based Pedicled Abdominal Flap for Upper-Limb Wounds From Severe Electrical Injury. *Annals of Plastic Surgery* 56, 116-121 (2006).
16. Kamath, B.J., Verghese, T. & Bhardwaj, P. "Wing flaps": perforator-based pedicled paraumbilical flaps for skin defects in hand and forearm. *Ann Plast Surg* 59, 495-500 (2007).
17. Ete, G., Paul, K., Akamanchi, A.K., Cordelia, M.J.F. & Agarwal, S. Pedicled thoracodorsal artery perforator flap in the soft-tissue reconstruction of an acute traumatic cubital fossa defect. *J Plast Reconstr Aesthet Surg* 75, 2070-2076 (2022).
18. Oksüz, S., Ulkür, E., Tuncer, S., Sever, C. & Karagöz, H. Elbow reconstruction with a pedicled thoracodorsal artery perforator flap after excision of an upper-extremity giant hairy nevus. *J Plast Reconstr Aesthet Surg* 66, 566-569 (2013).

19. Kulahci, Y., Sahin, C., Karagoz, H. & Zor, F. Pre-expanded Thoracodorsal Artery Perforator Flap. *Clin Plast Surg* 44, 91-97 (2017).
20. Heidekrueger, P.I. et al. The lateral arm flap for reconstruction of tissue defects due to olecranon bursitis. *J Plast Surg Hand Surg* 52, 347-351 (2018).
21. Innocenti, M., Baldrighi, C., Delcroix, L. & Adani, R. Local perforator flaps in soft tissue reconstruction of the upper limb. *Handchir Mikrochir Plast Chir* 41, 315-321 (2009).
22. Engelbrecht, J.J. & Bruce-Chwatt, A.J. The posterior interosseous flap for soft-tissue cover of the hand. *S Afr J Surg* 34, 194-196 (1996).
23. Zaidenberg, E.E., Zancolli, P., Farias Cisneros, E., Miller, A.G. & Moreno, R. Antegrade Posterior Interosseous Flap for Nonhealing Wounds of the Elbow: Anatomical and Clinical Study. *Plastic and Reconstructive Surgery – Global Open* 6, e1959 (2018).
24. Gupta, A. et al. Free tissue transfer to the traumatized upper extremity: Risk factors for postoperative complications in 282 cases. *J Plast Reconstr Aesthet Surg* 68, 1184-1190 (2015).
25. Koteswara Rao Rayidi, V., Prakash, P., Srikanth, R., Sreenivas, J. & Swathi, K. Anterolateral Thigh Flap-the Optimal Flap in Coverage of Severe Elbow Injuries. *Indian J Plast Surg* 52, 314-321 (2019).
26. Yang, Z. et al. Flow-Through Free Anterolateral Thigh Flap in Reconstruction of Severe Limb Injury. *Ann Plast Surg* 84, S165-s170 (2020).
27. Cha, H.G., Hur, J., Ahn, C., Hong, J.P.J. & Suh, H.P. Ultra-Thin Anterolateral Thigh Free Flap: An Adipocutaneous Flap with the Most Superficial Elevation Plane. *Plast Reconstr Surg* (2023).
28. He, J. et al. Customized reconstruction of complex soft tissue defects in the upper extremities with variants of double skin paddle anterolateral thigh perforator flap. *Injury* 52, 1771-1777 (2021).
29. Lee, Y.J. et al. Reconstruction of wide soft tissue defects with extended anterolateral thigh perforator flap turbocharged technique with anteromedial thigh perforator. *Microsurgery* 40, 440-446 (2020).
30. Chang, L.S., Kim, Y.H. & Kim, S.W. Reconstruction of burn scar contracture deformity of the extremities using thin thoracodorsal artery perforator free flaps. *ANZ J Surg* 91, E578-e583 (2021).
31. Lee, S.H. & Mun, G.H. Transverse thoracodorsal artery perforator flaps: experience with 31 free flaps. *J Plast Reconstr Aesthet Surg* 61, 372-379 (2008).
32. Miyamoto, S., Arikawa, M., Kagaya, Y. & Fukunaga, Y. Septocutaneous thoracodorsal artery perforator flaps: a retrospective cohort study. *J Plast Reconstr Aesthet Surg* 72, 78-84 (2019).
33. Berner, J.E., Nikkhah, D., Zhao, J., Prousskaia, E. & Teo, T.C. The Versatility of the Superficial Circumflex Iliac Artery Perforator Flap: A Single Surgeon's 16-Year Experience for Limb Reconstruction and a Systematic Review. *J Reconstr Microsurg* 36, 93-103 (2020).
34. S, A. & D, B. Multifarious uses of the pedicled SCIP flap - a case series. *Acta Chir Plast* 64, 148-154 (2023).
35. Visconti, G., Bianchi, A. & Salgarello, M. The use of the distal posterior radial collateral artery as recipient vessel in elbow resurfacing using SCIP flap. *Microsurgery* 41, 699-700 (2021).
36. Boriani, F., Sassu, P., Atzeni, M., Buckley, C. & Figus, A. The profunda artery perforator flap for upper limb reconstruction: A case report and literature review on the flap applications in reconstruction. *Microsurgery* 42, 714-721 (2022).

37. Chim H. Perforator mapping and clinical experience with the superthin profunda artery perforator flap for reconstruction in the upper and lower extremities. *J Plast Reconstr Aesthet Surg* 81, 60-67 (2023).
38. Yoshimatsu H. et al. Superficial Circumflex Iliac Artery Perforator Flap Elevation Using Preoperative High-Resolution Ultrasonography for Vessel Mapping and Flap Design. *J Reconstr Microsurgery* 38(3), 217-220 (2022).
39. Agarwal, P., Sharma, D. & Kukrele, R. Arteriovenous supercharging: A novel approach to improve reliability of the distally based sural flap. *Trop Doct* 51, 339-344 (2021).
40. Semple, J.L. Retrograde microvascular augmentation (turbocharging) of a single-pedicle TRAM flap through a deep inferior epigastric arterial and venous loop. *Plast Reconstr Surg* 93, 109-117 (1994).
41. Zhang, W., Zhu, W., Li, X., Li, X. & Li, X. Effects of Distal Arterial Supercharging and Distal Venous Superdrainage on the Survival of Multiterritory Perforator Flaps in Rats. *J Invest Surg* 35, 1462-1471 (2022).
42. Ou, Q. et al. Algorithm for covering circumferential wound on limbs with ALTP or/and DIEP flaps based on chain-linked design and combined transplantation. *Injury* 52, 1356-1362 (2021).
43. Hihara, M., Kuro, A., Mitsui, T. & Kakudo, N. Twenty-minute harvesting of flow-through type vastus lateralis muscle flap significantly reduces the need for a temporary intravascular shunt in the treatment of severe upper extremity trauma in civilian patients. *Medicine (Baltimore)* 102, e33311 (2023).
44. He, J. et al. Variations of Extended Latissimus Dorsi Musculocutaneous Flap for Reconstruction of Large Wounds in the Extremity. *Orthop Surg* 14, 2598-2606 (2022).
45. Hihara, M., Kuro, A., Mitsui, T. & Kakudo, N. Twenty-minute harvesting of flow-through type vastus lateralis muscle flap significantly reduces the need for a temporary intravascular shunt in the treatment of severe upper extremity trauma in civilian patients. *Medicine (Baltimore)* 102, e33311 (2023).
46. Sabbag OD, DeDeugd CM, Wagner ER, & Elhassan BT. Brachioradialis Flap for Soft Tissue Coverage of Posterior Elbow Wounds: Case Report and Surgical Technique. *Tech Hand Up Extrem Surg* 1, 2-5 (2019).
47. Fonzone Caccese, F., Crisci, E., Lanzano, G. & Fonzone Caccese, A. Reconstruction of the degloved dorsal wrist using a combination of a local adipofascial flap and acellular dermal matrix. *J Hand Surg Eur Vol.* 48, 361-363 (2023).
48. Ali, B., Wu, J., Borah, G. & Wu, E. Temporary Use of Acellular Dermal Matrix in Upper Extremity Salvage. *Plast Reconstr Surg Glob Open* 8(7) e2965 (2020).

Figure Legends

Figure 1. Case of a 64-year-old female with a comminuted open fracture of the left humerus and degloving injury. A free bi-pedicled DIEP flap was performed to cover the defect and the material. Consented pictures kindly provided by Mr. Marios Nicolaou (Salisbury District Hospital).

(A) Preoperative presentation with a massive soft tissue defect. The brachial artery and cephalic vein (white asterisk) and the extensor digitorum communis tendons (yellow asterisk)

(B) Intra-flap anastomosis between the two deep inferior epigastric arteries (yellow arrow). Anastomosis on the brachial artery (white arrow).

(C) Tension-free closure and full coverage of the soft tissue defect allowed by the extended flap paddle.

(D) Direct closure of the donor site.

(E) Final result. Primary healing, with a satisfactory aesthetic and functional outcome at one year of follow-up.

Figure 2. Case of a 27-year-old male who was the victim of a pellet gun trauma resulting in a major defect of the left arm. A low-risk solution was chosen, and a pedicled musculocutaneous latissimus dorsi (LD) flap was performed.

(A) Preoperative presentation with an evident soft tissue defect.

(B) A vertical skin paddle (yellow arrow) allowed for optimal flap inset after 45 degrees of rotation with low tension on the pedicle (white arrow). No injuries of the vascular axes (brachial artery, white asterisk) or nerves were found. The biceps brachii was partially preserved (yellow asterisk).

(C) A strip of the LD muscle was left exposed (black asterisk) in the medial arm to avoid compression of the pedicle.

(D) Final result. Complete wound healing, with a satisfactory aesthetic and functional outcome at four months follow-up.

Figure 3. Case of a 19-year-old man with an open transolecranon fracture initially treated with an external fixator. A wound infection led to debridement, screwed-plate-based osteosynthesis, and the resulting defect was covered by a combination of a pedicled brachioradialis flap and an acellular dermal matrix prior to skin grafting.

(A) Open reduction and osteosynthesis of the olecranon with a screwed plate (Variax, Stryker, Michigan, USA) (yellow arrow) performed after debridement.

(B) Brachioradialis muscle flap (white arrow) associated with a local rotation skin flap.

(C) Acellular dermal matrix (ADM) (Duragen, Integra Lifescience, Princeton, NJ) was applied to enhance healing and was affixed with staples.

(D) Final result. Full healing, with a satisfactory aesthetic and functional outcome at four weeks follow-up.

Figure 4. Case of a 58-year-old woman presenting with radiodermatitis and bone exposure following radiotherapy. A wide soft tissue resection with bone trimming was performed, and the defect was covered using a free thin SCIP flap, resulting in optimal coverage. Consented pictures kindly provided by Dr. Paul Girard and Pr. Nicolas Bertheuil (CHU de Rennes).

(A) Radiodermatitis and exposure of the radius after surgery and postoperative adjuvant radiotherapy.

(B) Free SCIP flap raised in the thin plane.

(C) Harvesting of the flap on the superficial branch of the Superficial Circumflex Iliac Artery (SCIA, white asterisk).

(D) Final positioning of the flap with the vessels (SCIA) anastomosed end-to-side to the radial artery and accompanying venae comitantes.

(E) Final result. Full healing, with an excellent aesthetic outcome at four weeks of follow-up.

Table 1.

Case	Sex	Age (years)	Comorbidities	Etiology	Flap	Outcome
Patient 1	F	64	T2DM	Comminuted open fracture of the left humerus	Free bi-pedicled DIEP	Fully healed at 1 year follow-up, able to play piano
Patient 2	M	27	Ciliary dyskinesia, active smoking status	Major trauma of the left arm with extended soft tissue defect from mid-arm to elbow	Pedicled musculocutaneous latissimus dorsi flap	Full healing, physiotherapy after 6 weeks, satisfactory functional outcome after 4 months
Patient 3	M	19	None	Loss of substance after mountain biking accident	Pedicled brachioradialis muscle flap	Full healing after 4 weeks (skin graft at week 3)
Patient 4	F	58	Previous sarcoma of the right forearm, active smoking status	Sarcoma of the right forearm treated with surgery and adjuvant radiotherapy	Free SCIP flap	Full healing after 4 weeks

Figures:

- Figure Legends

Figure 1. Case of a 64-year-old female with a comminuted open fracture of the left humerus and degloving injury. A free bi-pedicled DIEP flap was performed to cover the defect and the material. Consented pictures kindly provided by Mr. Marios Nicolaou (Salisbury District Hospital).

(A) Preoperative presentation with a massive soft tissue defect. The brachialis artery and cephalic vein (white asterisk) and the extensor digitorum communis tendons (yellow asterisk)

- (B) Intra flap anastomosis between the two deep inferior epigastric arteries (yellow arrow). Anastomose on the brachial artery (white arrow).
- (C) Tension-free closure and full coverage of the soft tissue defect allowed by the extended flap paddle.
- (D) Direct closure of the donor site.
- (E) Final result. Primary healing, with a satisfactory aesthetic and functional outcome at one year of follow-up.

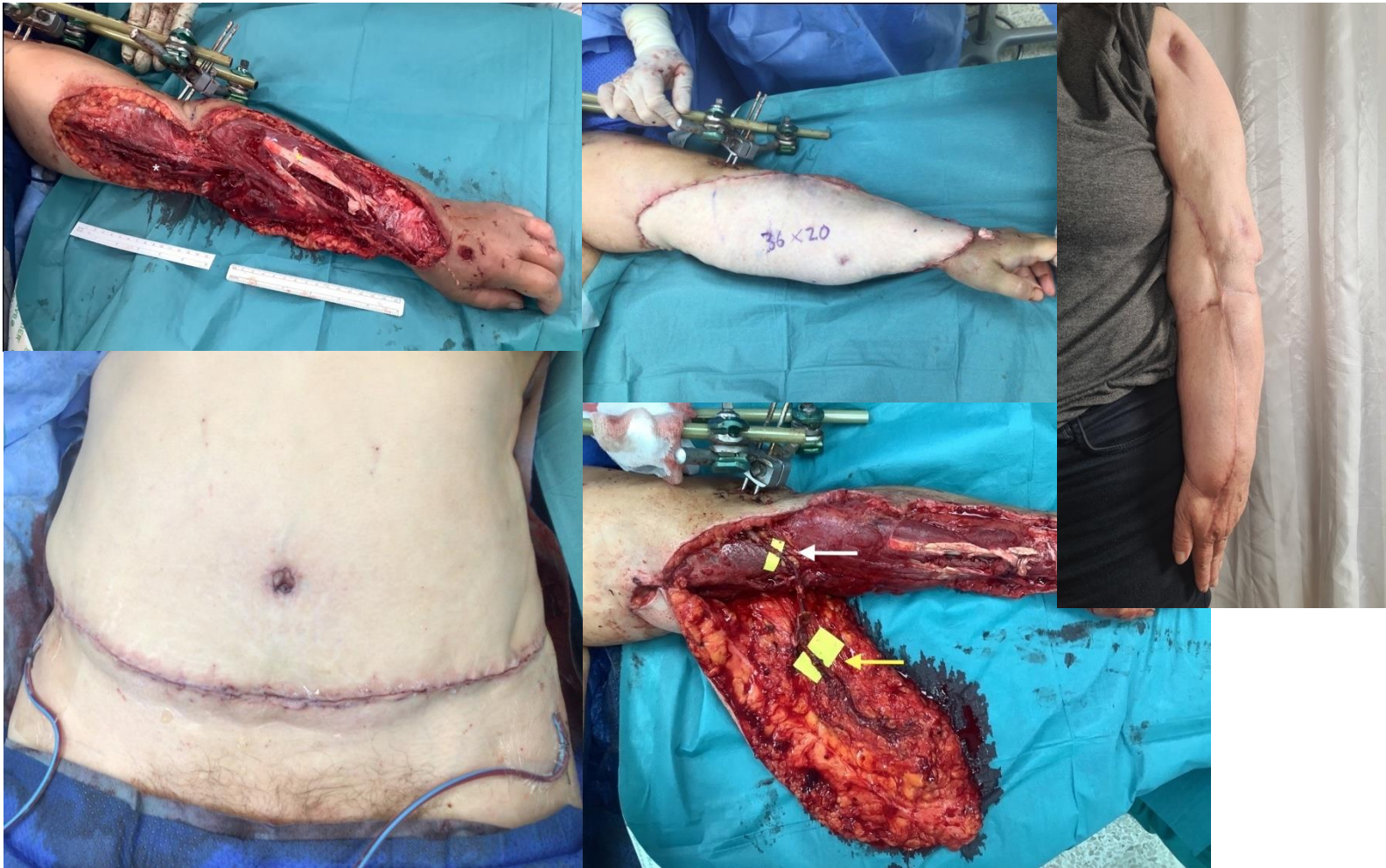


Figure 2. Case of a 27-year-old male who was the victim of a pellet gun trauma resulting in a major defect of the left arm. A low-risk solution was chosen, and a pedicled musculocutaneous latissimus dorsi (LD) flap was performed.

(A) Preoperative presentation with an evident soft tissue defect.

(B) A vertical skin paddle (yellow arrow) allowed for optimal flap inset after 45 degrees of rotation with low tension on the pedicle (white arrow). No injuries of the vascular axes (humeral artery, white asterisk) or nerves were found. The biceps brachii was partially preserved (yellow asterisk).

(C) Left exposure of a strip of the LD muscle (black asterisk) in the left to avoid compression of the pedicle.

(D) Final result. Complete wound healing, with a satisfactory aesthetic and functional outcome at four months follow-up.

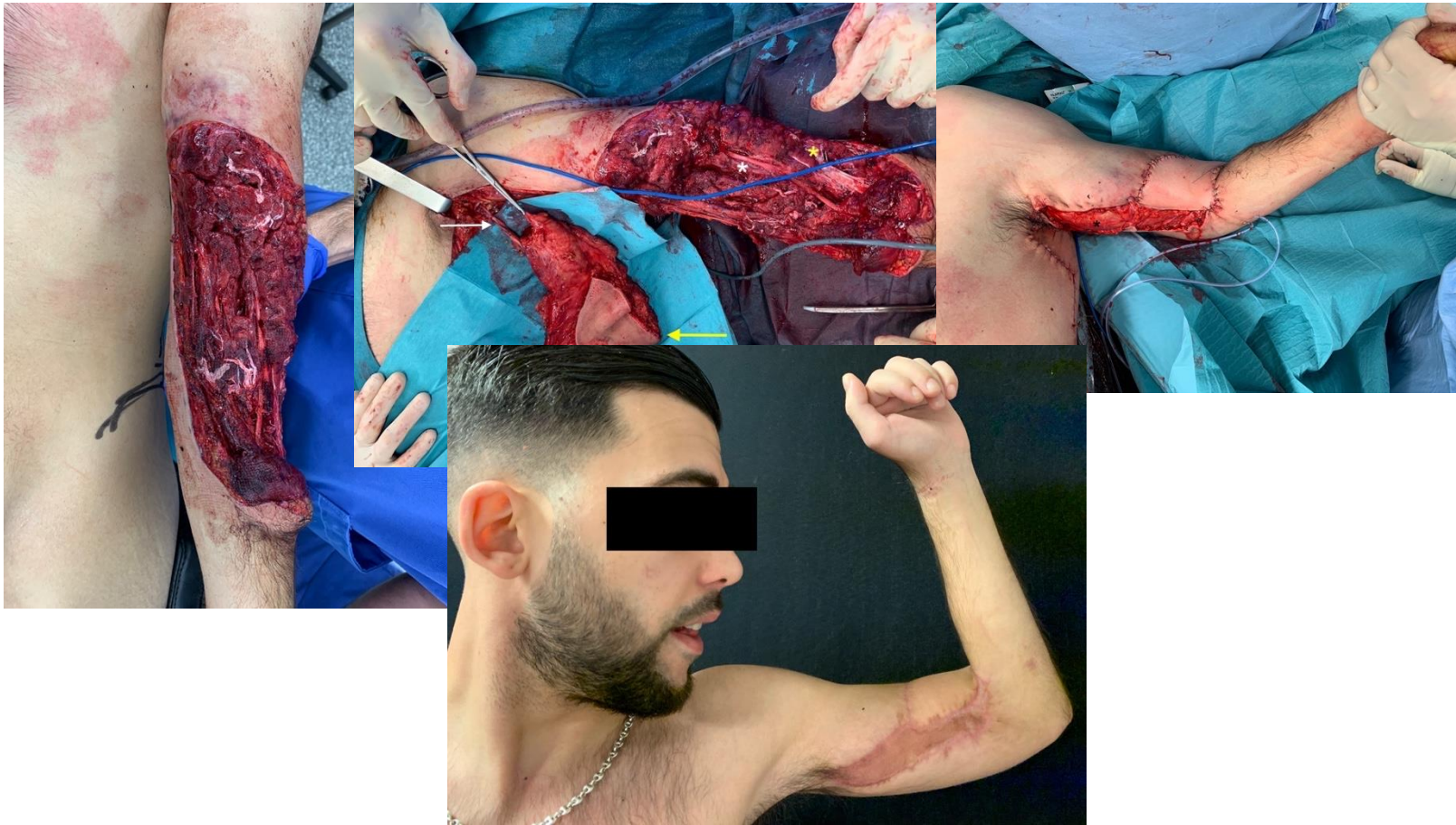

Figure 3. Case of a 19-year-old man with an open transolecranon fracture initially treated with an external fixator. A wound infection led to debridement, screwed-plate-based osteosynthesis, and the resulting defect was covered by a combination of a pedicled brachioradialis flap and an acellular dermal matrix prior to skin grafting.

(A) Open reduction and osteosynthesis of the olecranon with a screwed plate (Variax, Stryker, Michigan, USA) (yellow arrow) performed after debridement.

(B) Brachioradialis muscle flap (white arrow) associated with a local rotation skin flap.

(C) An acellular dermal matrix (ADM) (Duragen, Integra Lifescience, Princeton, NJ) was applied to enhance healing and was affixed with staples.

(D) Final result. Full healing, with a satisfactory aesthetic and functional outcome at four weeks follow-up.

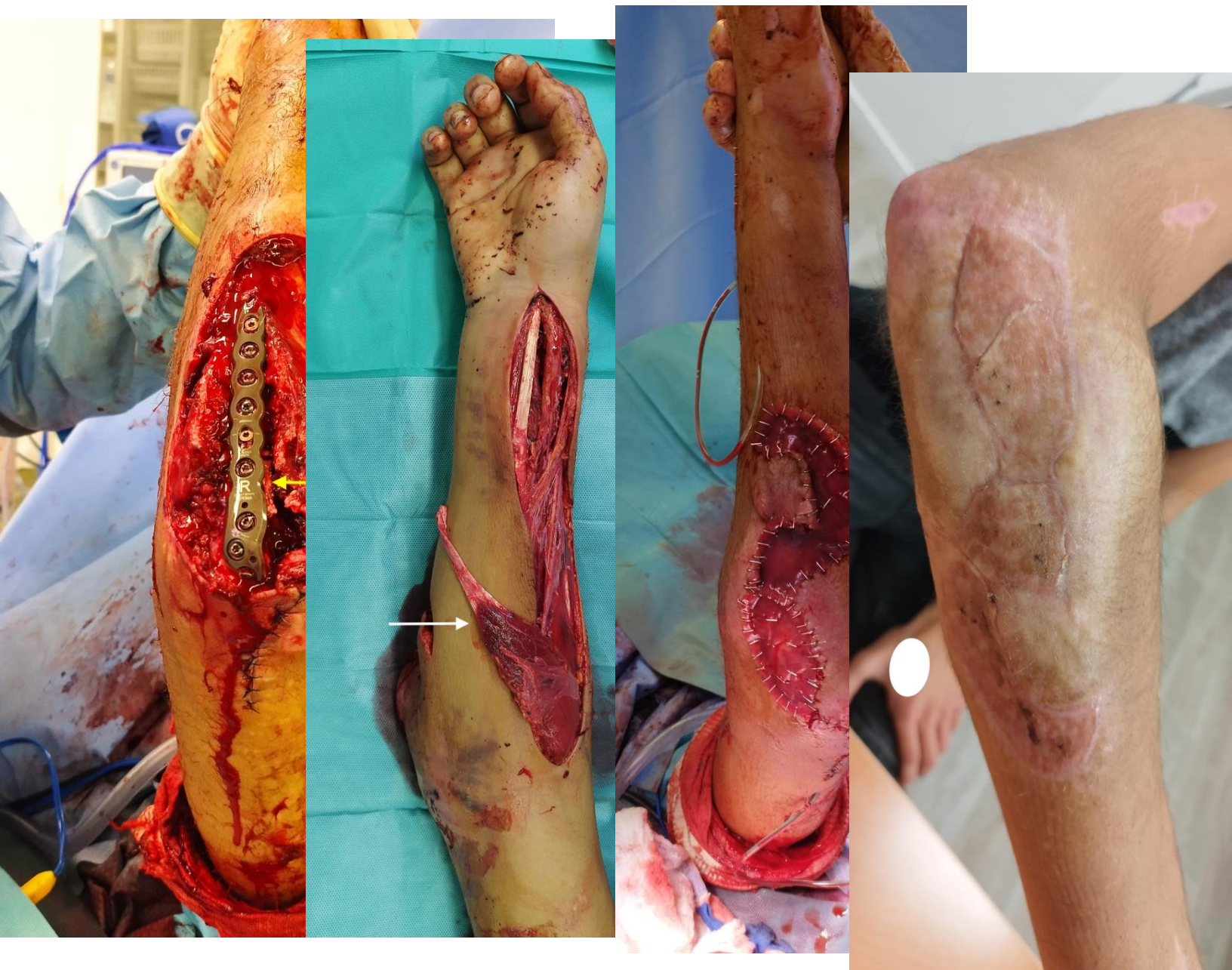

Figure 4. Case of a 58-year-old woman presenting with radiodermatitis and bone exposure following radiotherapy. A wide soft tissue resection with bone trimming was performed, and the defect was covered using a free ultrathin SCIP flap, resulting in optimal coverage. Consented pictures kindly provided by Dr. Paul Girard and Pr. Nicolas Bertheuil (CHU de Rennes).
(A) Radiodermatitis and exposure of the radius after surgery and postoperative adjuvant radiotherapy.
(B) Free SCIP flap raised in supra-thin fashion.

(C) Harvesting of the flap on the superficial branch of the Superficial Circumflex Iliac Artery (SCIA).

(D) Final positioning of the flap with the vessels (SCIA, white asterisk) anastomosed end-to-side to the radial artery and accompanying venae comitantes.

(E) Final result. Full healing, with an excellent aesthetic outcome at four weeks of follow-up.

