



**HAL**  
open science

## **Impact of cervical excisional dimensions on endocervical margins status in adenocarcinoma in situ of the uterine cervix: A multicenter study from the FRANCOGYN group**

Raphael Bartin, Romain Delangle, Jean-Luc Mergui, Henri Azaïs, Pierre-Adrien Bolze, Charles-Andre Philip, Yohan Kerbage, Emilie Raimond, Lise Lecointre, Xavier Carcopino, et al.

### ► **To cite this version:**

Raphael Bartin, Romain Delangle, Jean-Luc Mergui, Henri Azaïs, Pierre-Adrien Bolze, et al.. Impact of cervical excisional dimensions on endocervical margins status in adenocarcinoma in situ of the uterine cervix: A multicenter study from the FRANCOGYN group. *Journal of Gynecology Obstetrics and Human Reproduction*, 2023, 52 (7), pp.102622. 10.1016/j.jogoh.2023.102622 . hal-04344141

**HAL Id: hal-04344141**

**<https://hal.science/hal-04344141>**

Submitted on 14 Dec 2023

**HAL** is a multi-disciplinary open access archive for the deposit and dissemination of scientific research documents, whether they are published or not. The documents may come from teaching and research institutions in France or abroad, or from public or private research centers.

L'archive ouverte pluridisciplinaire **HAL**, est destinée au dépôt et à la diffusion de documents scientifiques de niveau recherche, publiés ou non, émanant des établissements d'enseignement et de recherche français ou étrangers, des laboratoires publics ou privés.

# Impact of cervical excisional dimensions on endocervical margins status in adenocarcinoma in situ of the uterine cervix: A multicenter study from the FRANCOGYN group

Raphael Bartin<sup>a</sup>, Romain Delangle<sup>a</sup>, Jean-Luc Mergui<sup>a</sup>, Henri Azaïs<sup>b</sup>, Pierre-Adrien Bolze<sup>c</sup>, Charles-Andre Philip<sup>d</sup>, Yohan Kerbage<sup>e,f</sup>, Emilie Raimond<sup>g</sup>, Lise Lecointre<sup>h</sup>, Xavier Carcopino<sup>i</sup>, Mathieu Castela<sup>j</sup>, Catherine Uzan<sup>a,k,l</sup>, Geoffroy Canlorbe<sup>a,k,l,\*</sup>

<sup>a</sup> Department of Gynecological and Breast Surgery and Oncology, Pitié-Salpêtrière, Assistance Publique des Hôpitaux de Paris (AP-HP), University Hospital, 75013 Paris, France

<sup>b</sup> Gynecologic and Breast Oncologic Surgery Department, Georges-Pompidou European Hospital, Assistance Publique des Hôpitaux de Paris (AP-HP), 75015 Paris, France

<sup>c</sup> Department of Gynecologic and Oncologic Surgery and Obstetrics, Lyon Sud University Hospital, Hospices Civils de Lyon, Université Lyon 1, France

<sup>d</sup> Department of Gynecologic and Oncologic Surgery and Obstetrics, CHU Lyon Croix-Rousse, Université Lyon 1, France

<sup>e</sup> CHU Lille, Service de chirurgie gynécologique F-59000 Lille, France

<sup>f</sup> Univ. Lille, CHU Lille, F-59000 Lille, France

<sup>g</sup> Department of Obstetrics and Gynaecology, Institute Alix de Champagne University Hospital, Reims, France

<sup>h</sup> Department of Surgical Gynecology, Strasbourg University Hospital, Strasbourg, France

<sup>i</sup> Department of Obstetrics and Gynecology, Hôpital Nord, APHM, Aix-Marseille University (AMU), Univ Avignon, CNRS, IRD, IMBE UMR 7263, 13397, Marseille, France

<sup>j</sup> Scarcell Therapeutics, 101 rue de Sèvres, 75006 Paris, France

<sup>k</sup> Centre de Recherche Saint-Antoine (CRSA), INSERM UMR\_S\_938, Cancer Biology and Therapeutics, Sorbonne University, 75012 Paris, France

<sup>l</sup> University Institute of Cancer, Sorbonne University, 75013 Paris, France

---

## A B S T R A C T

**Objective:** Excisional procedures have a central role in the management of adenocarcinoma in situ of the cervix (AIS). We aimed to evaluate the relationship between the excisional specimen dimensions and the endocervical margin status.

**Methods:** We conducted a multicentric retrospective study in seven French centers. All cases with proven AIS on a colposcopic biopsy and undergoing an excisional procedure afterwards were included in the analysis. We evaluated the impact of excision length, along with the lateral and anteroposterior diameters on the endocervical margin status. An additional subgroup analysis of the impact of maternal age on endocervical margin status was also conducted.

**Results:** Of the 101 cases of AIS diagnosed on initial biopsy, 95 underwent a primary excisional procedure, among which 80% ( $n = 76/95$ ) had uninvolved endocervical margins and 20% ( $n = 19/95$ ) had positive endocervical margins. The excisional specimen length was not significantly related to the endocervical margin status. Conversely, both lateral and antero-posterior diameters were significantly correlated with the negative endocervical margins status: OR = 1.19, 95% CI [1.03, 1.40],  $p = 0.025$ , for the lateral diameter and OR = 1.34, 95% CI [1.14, 1.64],  $p = 0.001$  for the antero-posterior diameter. The median lateral diameter was 20 mm, IQR (18, 24) in case of endocervical negative margins vs. 18 mm IQR (15, 24) in case of positive endocervical margins ( $p = 0.039$ ), and the median anteroposterior diameter was 17 mm IQR (15, 20) in case of negative endocervical margins vs 14 mm IQR (11, 15) in case of positive endocervical margins ( $p = 0.004$ ), respectively. Additionally, in patients over 45 years old, endocervical margin were more likely to be positive despite similar excisional dimensions (7/17 (41%) of positive endocervical margins before 45 years old vs 12/78 (15%) after,  $p = 0.039$ )

**Conclusions:** Endocervical margin statuses were significantly related to the transverse diameters (lateral and anteroposterior diameters), but not to the excision specimen length. Reducing the excised length may lead to fewer post-procedure complications but would still allow to obtain a large proportion of negative endocervical margins.

### Keywords:

Human papilloma virus  
Adenocarcinoma in situ  
Cervical excision  
Margin status

---

\* Corresponding author at: Service de chirurgie gynécologique, hôpital de la Pitié-Salpêtrière, 45-83 boulevard de l'hôpital, 75013 Paris.  
E-mail address: [geoffroy.canlorbe@aphp.fr](mailto:geoffroy.canlorbe@aphp.fr) (G. Canlorbe).

## Introduction

Adenocarcinoma in situ of the uterine cervix (AIS) is an intraepithelial pre-neoplastic lesion affecting the endocervical glands. It is highly related to HPV 18 and 16 infections, and its association with high grade squamous intraepithelial lesion is common [1,2]. With a rising incidence, AIS is known to be a precursor for the development of invasive adenocarcinoma, which accounts for 15–20% of all cervical cancers [3].

Although hysterectomy remains the gold standard treatment, excisional procedures have a central role in the management of AIS. First, considering its potential association with undiagnosed invasive adenocarcinoma, a complete histological analysis is required before any further treatment. Second, as an important part of the population affected is young and desires to keep the possibility of a future pregnancy, conservative therapies are often required [4,5]. Thus, excisional procedures combined with a close postoperative virological and colposcopic surveillance have been evaluated and proven to be an acceptable approach in cases requiring fertility-sparing [6,7]. In both situations, obtaining a complete excision with uninvolved margins is the cornerstone of AIS management, particularly in case of conservative management as the margin status following excisional procedure is an important predictive factor for persistent or recurrent AIS [8–12]. The excision must be limited to the pathological area as much as possible, especially in the younger population, as a deep cervical excision may increase the risk of preterm delivery [13]. Due to the progression of the disease along the endocervical canal, intuitively, a deeper excision should be associated with a higher probability of negative endocervical margins on the excised specimen and may lead to fewer recurrences. Nonetheless, no clear relationship between the excised specimen dimensions and the endocervical margin status have been established yet [6,12].

Therefore, we aimed to evaluate the impact of the excisional dimensions on the endocervical margin status in women diagnosed with AIS undergoing excisional procedure.

## Material and methods

### Study population and procedure

We conducted a retrospective study in seven French centers: Lille University Hospital, Lyon Sud University Hospital, Reims University hospital, Strasbourg University hospital, Marseille hôpital Nord, Marseille University, Hôpital Pitié-Salpêtrière (Assistance Public des hôpitaux de Paris, AP-HP), Hôpital Européen Georges Pompidou (AP-HP)). Patients diagnosed with AIS on initial biopsy who had undergone excisional procedure in these centers between 2008 and 2021 were included. Patients with primary hysterectomy were excluded. Surgical excisional procedures and cervical excisional dimensions were left at the discretion of surgeons and centers.

### AIS management

Patients were managed according to French guidelines [14]. Briefly, when diagnosed on a cervical biopsy, primary excisional procedure was systematically performed in order to confirm the diagnosis, whether or not a conservative approach was considered. The cone was analyzed by pathologists and margins were evaluated. In case of positive margins (i.e. contact between pathological tissue and excision specimen edges) a second procedure was performed to complete the excision. The following management was discussed in multidisciplinary consultation meeting. Although hysterectomy was indicated in patients with negative margins and without any invasive component, conservative management with follow-up was considered in young patients for fertility-sparing, or in case of refusal.

### Population characteristics

Preoperative characteristics reported were age at initial diagnosis (inferior to 35 years old, 35 to 45, and superior to 45 years old), immunosuppression status and etiology. The results of referral cytology were divided into minor anomalies (defined by a smear test resulting in either ASC-US or LSIL) and major anomalies (defined by a smear test resulting in either ASC-H, HSIL, AGC), according to the Bethesda 2014 classification. The squamocolumnar junction on initial colposcopy was either easily visualized (TZ1–2) or not (TZ3).

### Outcomes

Endocervical negative margins were defined as the absence of contact between the pathological endocervical tissue and the internal excision surface. No distance threshold was required for the excision to be considered negative. All measurements were performed by the pathologist either on fresh specimen or after formalin, according to local protocols as follows (detailed in Fig. 1):

- Length: defined as the distance between the excision base and the higher excision point
- Lateral diameter: defined as the distance between 3- and 9-hour points on the cone base
- Antero-posterior diameter: defined as the distance between 6- and 12-hour points on the cone base

### Statistical analysis

Continuous variables are presented as median and interquartile range (IQR) and were compared using the Wilcoxon-Mann-Whitney test. Frequencies and percentages were used for categorical variables and compared using the Chi-Square test or Fisher exact test when appropriate. A logistic regression model analysis was performed to evaluate the association between the probability of negative endocervical margins and cervical excisional dimension (in mm). Odds ratios (OR) with corresponding 95% CIs are reported. Each excisional dimension (i.e. the length and the lateral diameters) was treated as an independent variable. Statistical significance was defined by a  $p$  value  $<0.05$ . All statistical analyses were carried out using R (<http://www.r-project.org>; R Foundation, Vienna, Austria).

### Ethical statement

The research protocol was approved by the Institutional Review Board of the Collège National des Gynécologues et Obstétriciens Français (CEROG 2020-GYN-1211)

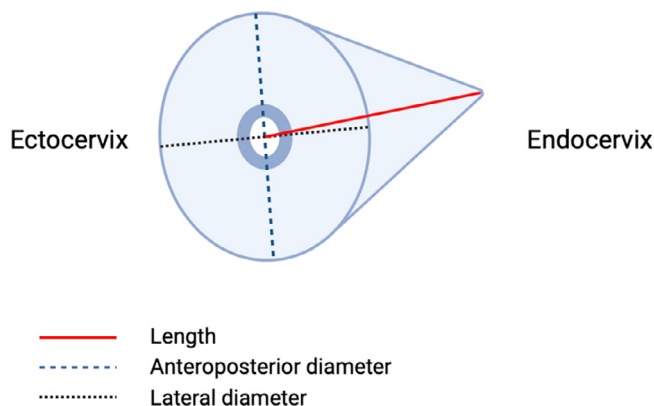
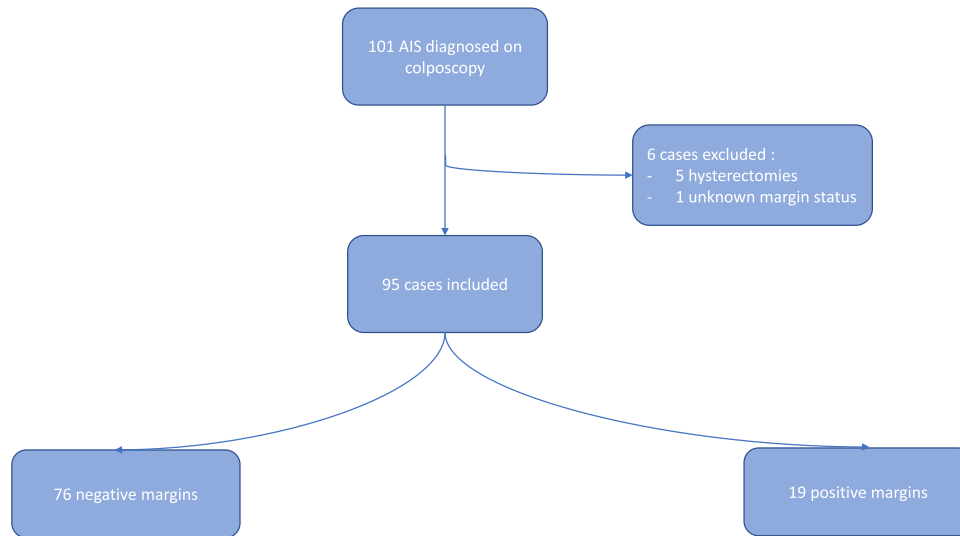

Fig. 1. Schematic representation of a conic excision and of the evaluated excised dimensions.



**Fig. 2.** Flowchart

Abbreviations: AIS (adenocarcinoma in situ).

## Results

### Description of the study population

The flowchart is represented in Fig. 2. Of the 101 cases of AIS diagnosed on the initial biopsy, 5 were treated with primary hysterectomy and were therefore excluded. Among the 96 patients that underwent an excisional procedure, 1 case had missing data about margin status. Finally, 95 cases were included with 76/95 patients having negative endocervical margins after the first excision (80%) and 19/95 (20%) having positive endocervical margins.

Comparative population characteristics according to the endocervical margin status are presented in Table 1 and were similar between both groups. Overall, 44% of patients were under 35 years old, 38% were between 35 and 45 years old, and only 18% of patients were older than 45 years old ( $p = 0.086$ ). The results of initial cytology were available for 84 patients. Major anomalies were suspected on initial smear tests in 81% of patients in the 'Negative margins' group and in 87% of patients in the 'Positive margins' groups,  $p = 0.7$ . Among the 64 patients for whom the endocervical visualization on

colposcopy was specified, 94% were either TZ1 or TZ2. Additional endocervical curettage was performed in 18/76 (24%) of patients with positive endocervical margins and 5/19 (26%) of patients with negative endocervical margins,  $p = 0.8$ .

### Impact of excisional dimensions on the endocervical margin status

Fig. 3 displays the evolution of the probability of negative endocervical margins according to the three excisional dimensions, modelled from the logistic regression model analysis. The analysis of the raw data showed that the proportion of patients with negative endocervical margin rose from 68% in length <10 mm to 84% for a length of 10–15 mm. Beyond this length, the proportion of negative endocervical margins remained quite stable. Overall, we found no significant association between the probability of negative endocervical margins and the length of cervical excision (OR = 1.08, 95% CI [0.99, 1.20],  $p = 0.10$ ). Conversely, the probability of negative endocervical margins was significantly correlated with both lateral (OR = 1.19, 95% CI [1.03, 1.40],  $p = 0.025$ ) and antero-posterior diameters (OR = 1.34, 95% CI [1.14, 1.64],  $p = 0.001$ ). Table 2 compares the specimen

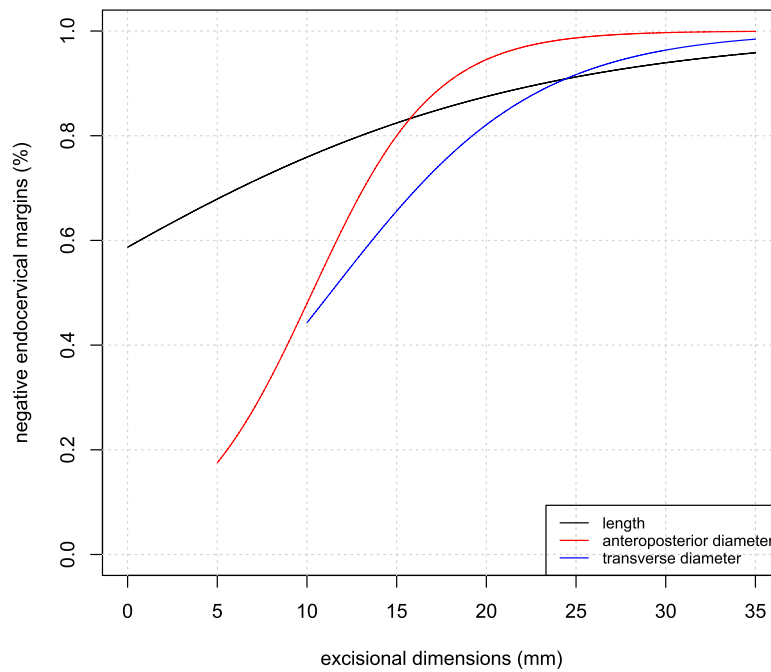
**Table 1**  
Comparative population characteristics according to the endocervical margin status.

Characteristic	Negative margins, $N = 76^1$	Positive margins, $N = 19^1$	Overall, $N = 95^1$	p-value <sup>2</sup>
<b>Age (years)</b>				0.086
< 35	36 (47%)	6 (32%)	42 (44%)	
35–45	30 (39%)	6 (32%)	36 (38%)	
≥ 45	10 (13%)	7 (37%)	17 (18%)	
<b>Immunosuppression</b>	2 (2.7%)	1 (5.3%)	3 (3.2%)	0.5
<b>IS type</b>				>0.9
HIV	0 (0%)	0 (0%)	0 (0%)	
Transplant	1 (50%)	0 (0%)	1 (33%)	
Other	1 (50%)	1 (100%)	2 (67%)	
<b>Referral cytology</b>				0.7
Low risk	13 (19%)	2 (13%)	15 (18%)	
High risk	54 (81%)	14 (87%)	68 (82%)	
missing	8	3	11	
<b>Endocervical curettage</b>	18 (25%)	5 (28%)	23 (25%)	0.8
<b>Squamocolumnar junction</b>				0.6
TZ1-TZ2	49 (94%)	11 (92%)	60 (94%)	
TZ3	3 (6%)	1 (8%)	4 (6%)	
missing	24	7	31	

Abbreviations: TZ (transformation zone), IS (immunosuppression).

<sup>1</sup> Statistics presented: n (%).

<sup>2</sup> Statistical tests performed: Fisher's exact test; chi-square test of independence.



**Fig. 3.** Estimated probability of negative endocervical margins according to the three excisional dimensions. Abbreviations: AP (anteroposterior diameter).

**Table 2**

Comparison of excisional dimensions according to the endocervical margin status in AIS-affected population.

Measurement	Negative margins, N = 76 <sup>1</sup>	Positive margins, N = 19 <sup>1</sup>	p-value <sup>2</sup>
<b>Length (mm)</b>	16 (12, 20)	15 (9, 20)	0.6
<b>Lateral diameter (mm)</b>	20.0 (18.2, 24.0)	18.0 (15.0, 23.8)	<b>0.039</b>
<b>AP diameter (mm)</b>	17.0 (15.0, 20.0)	14.0 (11.2, 15.0)	<b>0.004</b>

<sup>1</sup> Statistics presented: Median (IQR).

<sup>2</sup> Statistical tests performed: Wilcoxon rank-sum test.

dimensions of negative and positive margins groups. No significant difference was found regarding the excision length between both groups (median length of 16 mm IQR (12, 20) in the 'Negative margins' group vs. 15 mm IQR (9, 20) in the 'Positive margins' group,  $p = 0.6$ ), whereas both lateral and antero-posterior diameters were significantly higher in case of negative endocervical margins.

The median lateral diameters were 20 mm, IQR (18, 24) in case of negative endocervical margins vs. 18 mm, IQR (15, 24) in case of positive endocervical margins ( $p = 0.039$ ), and the median antero-posterior diameters were 17 mm, IQR (15, 20) vs 14 mm, IQR (11, 15) ( $p = 0.004$ ), respectively.

#### Impact of age on endocervical margin status

Table 3 shows the compared excisional outcomes and endocervical margin status according to women's age. Despite similar excisional dimensions (regarding length, lateral and antero-posterior diameters), the endocervical margin status was significantly related to women's age: 12/78 (15%) of women had positive endocervical margins before 45 years old and 7/17 (41%) after 45 years old ( $p = 0.039$ ).

## Discussion

### Main findings

Beyond 10–15 mm, excision length did not seem to be clearly associated with the proportion of negative endocervical margins.

**Table 3**

Compared characteristics of AIS margin status and excisional dimensions according to age.

Characteristic	< 45 years old, N = 78 <sup>1</sup>	≥ 45 years old, N = 17 <sup>1</sup>	p-value[2]
<b>Margin status</b>			<b>0.039</b>
negative margins	66 (85%)	10 (59%)	
positive margins	12 (15%)	7 (41%)	
<b>Excisional dimensions</b>			
Length	16 (12, 20)	17 (10, 20)	0.7
Lateral diameter	20.0 (18.0, 24.0)	18.0 (17.5, 23.0)	0.4
AP diameter	16.0 (14.0, 19.0)	15.0 (15.0, 20.8)	0.7

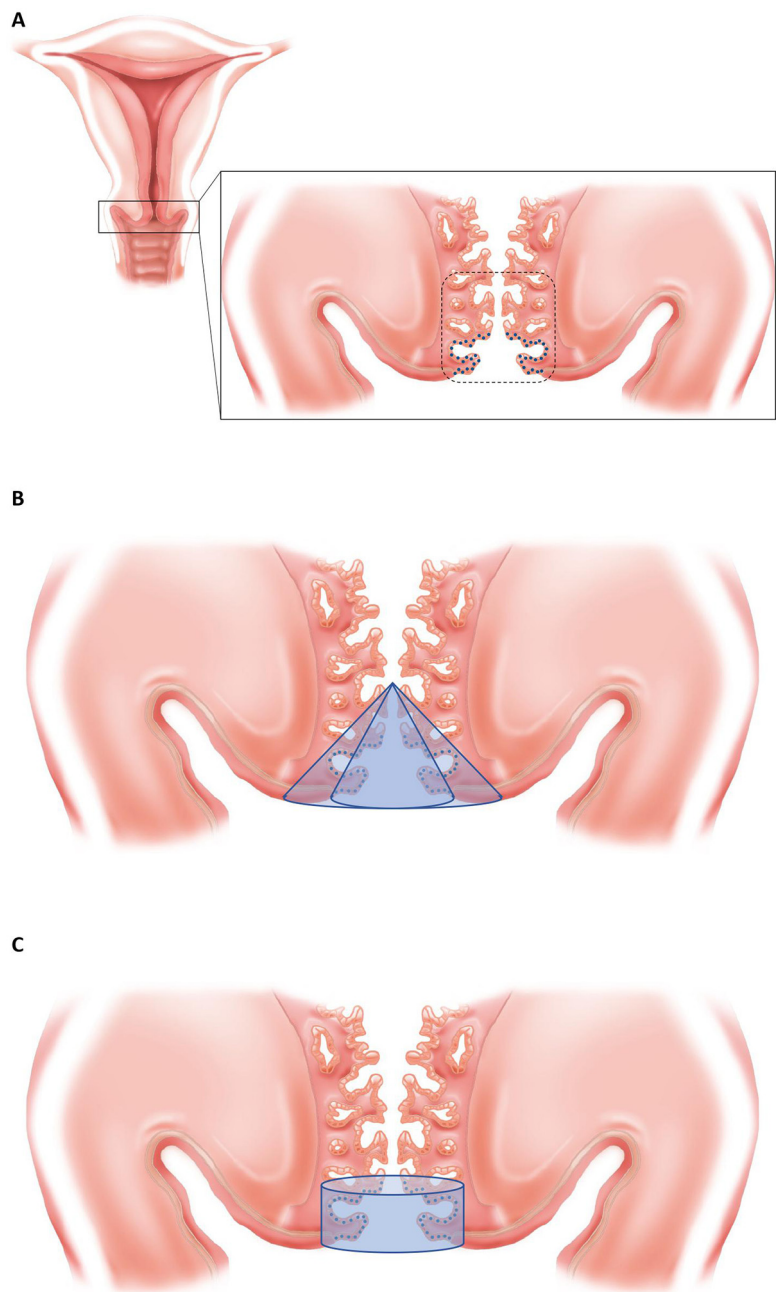
However, both lateral and antero-posterior diameters had a significant impact on the endocervical margin status (medians dimensions of 20 mm (18, 24) in the 'negative margins group' vs. 18 mm (15, 24) ( $p = 0.039$ ) in the 'positive margins' group, and 17 mm (15, 20) vs. 14 mm (11, 15) ( $p = 0.004$ ), respectively), in the overall population. Nonetheless, despite similar specimen dimensions, women over 45 years old had a significantly higher risk of positive margins after an excisional procedure than younger women.

### Interpretation

Achieving negative endocervical margins is the keystone of conservative management in AIS. Positive margins are associated with an increased risk of recurrence or long-term AIS persistence [12,15], which may trigger recurrent procedures, or invasive adenocarcinoma. Hence, optimizing the procedures to achieve negative margins with the is the smallest excision specimen possible is major point. AIS is a preneoplastic lesion developing in the glandular epithelium of the endocervical canal [16]. As all in situ lesions, by definition, cellular anomalies are strictly limited to the epithelium and cannot cross the basal membrane. Thus, AIS extend preferentially vertically, along the endocervical canal, and its lateral extension in the transverse plane is limited by the basal membrane. Intuitively, a deeper excision (i.e., increased length) should be associated with higher rates of endocervical negative margins. Multiple reasons may explain why no

clear influence of the excision length on the endocervical margin status have been found. First, the development of AIS appears to start essentially around the squamocolumnar junction and therefore close to the external cervical os [17,18]. Bertrand et al. reported that the large majority of AIS extend to less than 15 mm into the endocervical canal and deeper localizations are quite rare [19]. Therefore, an excision length of 10–15 mm might be sufficient in most cases. This is consistent with the results reported by Tan et al. especially in the population of young women under 40 years old and corroborates both recent American guidelines and our own observation [9,20]. Secondly, although most of AIS are unifocal, various studies have

reported circular extension into multiple quadrants all around the cervical canal. [16,19,21] Moreover, the glandular architecture of the endocervical epithelium is not a straight line along the cervical lumen but is composed of crypts and clefts. If AIS usually develops in the primary clefts (close to the canal), it may also involve the deeper tunnels extending from the gland clefts, depending on the histological subtypes [22]. Despite being limited by the basal membrane, lateral extension of AIS exists, at least partly. Thus, the inner excision surface (which depends on the external excision surface i.e., the lateral and anteroposterior diameters) should be large enough to include all the pathological glandular epithelium. All these observations may



**Fig. 4.** schematic representation of the uterine cervix and different excisional shapes

Abbreviations: AIS (adenocarcinoma in situ)

A – schematic histological representation of the endocervix in coronal plane. The non-linear and cryptic architecture of the glandular endocervical epithelium explains the transverse extension of AIS, despite being limited by the basal membrane. The dashed line corresponds to the transformation zone, mainly affected by AIS.

B – Conic excision. At equal length, obtaining endocervical negative margins (excision inner surface) depends on the external surface (visible on the ectocervix)

C – Cylindrical excision. An excision with negative endocervical margins requires both lower length and lateral dimensions (lateral and anteroposterior diameters) than in conic excision.



explain why a conservative procedure with uninvolved endocervical margins requires rather a large excision (increased lateral and anteroposterior diameters) more than a deep excision (increased excision length). However, considering the heterogeneity of procedures in our cohort, it seems difficult to give precise lateral or anteroposterior diameter thresholds, although 20 mm appear sufficient in most cases. One way to achieve a high rate of uninvolved endocervical margins while keeping the excision to the pathological area as much as possible may be to perform a cylindrical excision. This technique has been previously described by Azais et al. [23]. Briefly, instead of realizing a conventional conic excision, the edges of the removed tissue should be parallel to the endocervical canal. A preoperative colposcopy is realized: this step is essential to localize with precision the contours of the ectocervical incision and removing the entire transitional zone. Then, a circular incision is performed, delimiting the inner excisional surface. The pathological tissue is progressively removed from the exocervical incision to the inner delimitation, realizing a cylinder. The schematic representation in Fig. 4 helps to understand how a cylindrical excision supposedly reduces the excision dimensions while keeping a high rate of uninvolved endocervical margins.

In our study, AIS-affected population was quite young, with 44% of patients being under 35 years old and 82% under 45 years old which is consistent with previously reported literature: Salani et al. reported in a meta-analysis of 1278 cases of AIS a mean age of 36.8 years old (range 31–44.2) [24]. Furthermore, in their study, 29% of women were nulliparous at the time of diagnosis. Considering these characteristics, many of those patients may require a conservative approach alone. Nonetheless, while excisional procedures may indeed allow fertility-sparing, they are not free of consequences. Cervical excisions are known to be associated with an increased risk of obstetrical adverse outcomes, particularly preterm delivery or premature preterm of membranes [13,25–27]. Conversely, the transverse diameter does not seem to impact the gestational age at delivery [28]. Thus, reducing the excision length may undermine risks of potential obstetrical adverse events in women with further pregnancies.

Other complications may be triggered by a deep excision procedure. Particularly, cervical stenosis can be responsible for clinical symptoms such as menstrual disorders or hematometra and tends to make the postoperative colposcopic follow-up technically more difficult. The excision specimen length is known to be an independent risk factor for the development of such a complication, especially for excision lengths beyond 20 mm [29–31]. In case of conservatively treated AIS, a close follow-up is essential. Limiting the excision length to 15 mm could reduce the risks of developing cervical stenosis and allow a better and easier colposcopic follow-up.

Our results support the idea of age as an independent risk factor for positive endocervical margins: despite having similar excisional dimensions, endocervical margins were more frequently involved in patients over 45 years old. This suggests different histological characteristics depending on age at diagnosis, with a potentially deeper and larger invasion which may be related to later diagnosis and longer evolution of the pathology. Thus, the limitation of excisional dimensions defined previously may not be suited to older patients, who could benefit from a deeper and larger excision. However, considering the small sample of women over 45 years old in our cohort, we could not perform an optimal subgroup analysis to evaluate this hypothesis.

### Limitations

Several limitations can be acknowledged. As we conducted a retrospective multicentric study, all excisional procedure techniques were included in this study. This may have provided heterogeneity, as each center had its own specificity. However, comparative studies (including a recent prospective phase 2 clinical trial) suggests that the main procedures (essentially CKC and LEEP) may be comparable [6,11]. Therefore, the rates of uninvolved endocervical margin should

not have been impacted by this technique heterogeneity. Nonetheless, no study has compared the impact of excision shapes on the margin status. Such a study would help to assess the impact of cylindrical excision which may be more appropriate in case of AIS. Second, we had little data on long-term follow-up and on the postoperative complications, nor were we able to report separately isolated AIS and concurrent cervical intraepithelial neoplasia, although it may impact the risk of persistent lesion [10]. Finally, a correlation between surgical and histological (uni or multifocal spots, length of affected tissue, histological subtypes) data would have been interesting, particularly in the older population to determine more precisely the reasons for the differences regarding the endocervical margins status.

### Conclusion

In AIS of the uterine cervix, the main objective of excisional procedures is to obtain uninvolved margins. Endocervical margin status may depend mostly on lateral excisional diameters, with optimal proportion of endocervical negative margins beyond 15–20 mm, rather than excisional length. A 15 mm length may be sufficient in most cases and may undermine postoperative complications such as obstetrical adverse outcomes, particularly important in a population of young women with a potential desire of future pregnancy.

### Disclosures

None

### Funding

None

### Declaration of Competing Interest

The authors declare that they have no known competing financial interests or personal relationships that could have appeared to influence the work reported in this paper.

### References

- [1] Madeleine MM, Daling JR, Schwartz SM, et al. Human papillomavirus and long-term oral contraceptive use increase the risk of adenocarcinoma in situ of the Cervix. *Cancer Epidemiol Biomark Prev* 2001;10(3):171.
- [2] Park KJ. Cervical adenocarcinoma: integration of HPV status, pattern of invasion, morphology and molecular markers into classification. *Histopathology* 2020;76(1):112–27. doi: 10.1111/his.13995.
- [3] van der Horst J, Siebers AG, Bulten J, Massuger LF, de Kok IM. Increasing incidence of invasive and in situ cervical adenocarcinoma in the Netherlands during 2004–2013. *Cancer Med* 2017;6(2):416–23. doi: 10.1002/cam4.971.
- [4] Ciavattini A, Giannella L, Delli Carpini G, et al. Adenocarcinoma in situ of the uterine cervix: clinical practice guidelines from the Italian society of colposcopy and cervical pathology (SICPCV). *Eur J Obstet Gynecol Reprod Biol* 2019;240:273–7. doi: 10.1016/j.ejogrb.2019.07.014.
- [5] Teoh D, Musa F, Salani R, Huh W, Jimenez E. Diagnosis and management of adenocarcinoma in situ: a Society of Gynecologic Oncology Evidence-Based Review and Recommendations. *Obstet Gynecol* 2020;135(4):869–78. doi: 10.1097/AOG.0000000000003761.
- [6] Munro A, Leung Y, Spilsbury K, et al. Comparison of cold knife cone biopsy and loop electrosurgical excision procedure in the management of cervical adenocarcinoma in situ: what is the gold standard? *Gynecol Oncol* 2015;137(2):258–63. doi: 10.1016/j.ygyno.2015.02.024.
- [7] Bai H, Liu J, Wang Q, et al. Oncological and reproductive outcomes of adenocarcinoma in situ of the cervix managed with the loop electrosurgical excision procedure. *BMC Cancer* 2018;18(1):461. doi: 10.1186/s12885-018-4386-6.
- [8] Upadhyay Baskota S, Wang T, Zhao C. Follow-up findings in postconservative treatment surveillance for women with cervical adenocarcinoma in situ. *J Low Genit Tract Dis* 2021;25(1):38–42. doi: 10.1097/LGT.0000000000000579.
- [9] Tan JHJ, Malloy MJ, Thangamani R, et al. Management and long-term outcomes of women with adenocarcinoma in situ of the cervix: a retrospective study. *Aust N Z J Obstet Gynaecol* 2020;60(1):123–9. doi: 10.1111/ajo.13047.
- [10] Munro A, Codde J, Spilsbury K, et al. Risk of persistent and recurrent cervical neoplasia following incidentally detected adenocarcinoma in situ. *Am J Obstet Gynecol* 2017;216(3):272.e1–7. doi: 10.1016/j.ajog.2016.11.1044.

- [11] Cohen PA, Leung Y, Anderson L, et al. Excisional treatment comparison for in situ endocervical adenocarcinoma (EXCISE): a phase 2 pilot randomized controlled trial to compare histopathological margin status, specimen size and fragmentation after loop electrosurgical excision procedure and cold knife cone biopsy. *Gynecol Oncol* 2020;159(3):623–9. doi: [10.1016/j.ygyno.2020.09.053](https://doi.org/10.1016/j.ygyno.2020.09.053).
- [12] Young JL, Jazaeri AA, Lachance JA, et al. Cervical adenocarcinoma in situ: the predictive value of conization margin status. *Am J Obstet Gynecol* 2007;197(2):195.e1–8. doi: [10.1016/j.ajog.2007.04.035](https://doi.org/10.1016/j.ajog.2007.04.035).
- [13] Bevis KS, Biggio JR. Cervical conization and the risk of preterm delivery. *Am J Obstet Gynecol* 2011;205(1):19–27. doi: [10.1016/j.ajog.2011.01.003](https://doi.org/10.1016/j.ajog.2011.01.003).
- [14] Conduite à tenir devant une femme ayant une cytologie cervico-utérine anormale, Thésaurus, Collection recommandations et référentiels, INCa, décembre 2016.
- [15] Baalbergen A, Helmerhorst TJM. Adenocarcinoma in situ of the uterine cervix—a systematic review. *Int J Gynecol Cancer* 2014;24(9):1543–8. doi: [10.1097/IGC.0000000000000260](https://doi.org/10.1097/IGC.0000000000000260).
- [16] Zaino RJ. Symposium part I: adenocarcinoma in situ, glandular dysplasia, and early invasive adenocarcinoma of the uterine cervix. *Int J Gynecol Pathol* 2002;21(4):314–26. doi: [10.1097/00004347-200210000-00002](https://doi.org/10.1097/00004347-200210000-00002).
- [17] Jaworski RC, Pacey NF, Greenberg ML, Osborn RA. The histologic diagnosis of adenocarcinoma in situ and related lesions of the cervix uteri. *Adenocarcinoma in situ*. *Cancer* 1988;61(6):1171–81. doi: [10.1002/1097-0142\(19880315\)61:6<1171::AID-CNCR2820610620>3.0.CO;2-X](https://doi.org/10.1002/1097-0142(19880315)61:6<1171::AID-CNCR2820610620>3.0.CO;2-X).
- [18] Andersen ES, Arffmann E. Adenocarcinoma in situ of the uterine cervix: a clinicopathologic study of 36 cases. *Gynecol Oncol* 1989;35(1):1–7. doi: [10.1016/0090-8258\(89\)90001-2](https://doi.org/10.1016/0090-8258(89)90001-2).
- [19] Bertrand M, Lickrish GM, Colgan TJ. The anatomic distribution of cervical adenocarcinoma in situ: implications for treatment. *Am J Obstet Gynecol* 1987;157(1):21–5. doi: [10.1016/S0002-9378\(87\)80338-1](https://doi.org/10.1016/S0002-9378(87)80338-1).
- [20] Perkins RB, Guido RS, Castle PE, et al. 2019 ASCCP risk-based management consensus guidelines for abnormal cervical cancer screening tests and cancer precursors. *J Low Genit Tract Dis* 2020;24(2):102–31. doi: [10.1097/LGT.0000000000000525](https://doi.org/10.1097/LGT.0000000000000525).
- [21] Shin CH, Schorge JO, Lee KR, Sheets EE. Conservative management of adenocarcinoma in situ of the cervix. *Gynecol Oncol* 2000;79(1):6–10. doi: [10.1006/gyngo.2000.5962](https://doi.org/10.1006/gyngo.2000.5962).
- [22] Noda K, Kimura K, Ikeda M, Teshima K. Studies on the histogenesis of cervical adenocarcinoma. *Int J Gynecol Pathol* 1983;1(4):336–46. doi: [10.1097/00004347-198301040-00003](https://doi.org/10.1097/00004347-198301040-00003).
- [23] Azaïs H, Canlorbe G, Belghiti J, Nikpayam M, Mergui JL, Uzan C. Comment je fais... une exérèse cylindrique pour adénocarcinome in situ du col utérin. *Gynécologie Obstétrique Fertil Sénologie* 2017;45(7–8):439–40. doi: [10.1016/j.gofs.2017.06.004](https://doi.org/10.1016/j.gofs.2017.06.004).
- [24] Salani R, Puri I, Bristow RE. Adenocarcinoma in situ of the uterine cervix: a meta-analysis of 1278 patients evaluating the predictive value of conization margin status. *Am J Obstet Gynecol* 2009;200(2):182.e1–5. doi: [10.1016/j.ajog.2008.09.012](https://doi.org/10.1016/j.ajog.2008.09.012).
- [25] Zhuang H, Hong S, Zheng L, et al. Effects of cervical conisation on pregnancy outcome: a meta-analysis. *J Obstet Gynaecol* 2019;39(1):74–81. doi: [10.1080/01443615.2018.1463206](https://doi.org/10.1080/01443615.2018.1463206).
- [26] Kyrgiou M, Koliopoulos G, Martin-Hirsch P, Arbyn M, Prendiville W, Paraskevaidis E. Obstetric outcomes after conservative treatment for intraepithelial or early invasive cervical lesions: systematic review and meta-analysis. *The Lancet* 2006;367(9509):489–98. doi: [10.1016/S0140-6736\(06\)68181-6](https://doi.org/10.1016/S0140-6736(06)68181-6).
- [27] Kyrgiou M, Athanasiou A, Paraskevaidi M, et al. Adverse obstetric outcomes after local treatment for cervical preinvasive and early invasive disease according to cone depth: systematic review and meta-analysis. *BMJ* 2016;i3633. Published online July 28. doi: [10.1136/bmj.i3633](https://doi.org/10.1136/bmj.i3633).
- [28] Liverani CA, Di Giuseppe J, Clemente N, et al. Length but not transverse diameter of the excision specimen for high-grade cervical intraepithelial neoplasia (CIN 2–3) is a predictor of pregnancy outcome. *Eur J Cancer Prev* 2016;25(5):416–22. doi: [10.1097/CEJ.0000000000000196](https://doi.org/10.1097/CEJ.0000000000000196).
- [29] Baldauf J, Dreyfus M, Ritter J, Meyer P, Philippe E. Risk of cervical stenosis after large loop excision or laser conization. *Obstet Gynecol* 1996;88(6):933–8. doi: [10.1016/S0029-7844\(96\)00331-6](https://doi.org/10.1016/S0029-7844(96)00331-6).
- [30] Houlard S, Perrotin F, Fourquet F, Marret H, Lansac J, Body G. Risk factors for cervical stenosis after laser cone biopsy. *Eur J Obstet Gynecol Reprod Biol* 2002;104(2):144–7. doi: [10.1016/S0301-2115\(02\)00062-3](https://doi.org/10.1016/S0301-2115(02)00062-3).
- [31] Tanaka Y, Ueda Y, Kakuda M, et al. Predictors for recurrent/persistent high-grade intraepithelial lesions and cervical stenosis after therapeutic conization: a retrospective analysis of 522 cases. *Int J Clin Oncol* 2017;22(5):921–6. doi: [10.1007/s10147-017-1124-z](https://doi.org/10.1007/s10147-017-1124-z).