



HAL
open science

Mild endometriosis of the uterosacral ligaments: a retrospective study of magnetic resonance imaging performance for diagnosis

Margaux Stoppa, Aubert Agostini, Audrey Pivano, Pascale Siles, Lisa Calderon, Antoine Netter

► To cite this version:

Margaux Stoppa, Aubert Agostini, Audrey Pivano, Pascale Siles, Lisa Calderon, et al.. Mild endometriosis of the uterosacral ligaments: a retrospective study of magnetic resonance imaging performance for diagnosis. *Reproductive BioMedicine Online*, 2023, 46 (6), pp.947-955. 10.1016/j.rbmo.2023.03.002 . hal-04343437

HAL Id: hal-04343437

<https://hal.science/hal-04343437>

Submitted on 13 Dec 2023

HAL is a multi-disciplinary open access archive for the deposit and dissemination of scientific research documents, whether they are published or not. The documents may come from teaching and research institutions in France or abroad, or from public or private research centers.

L'archive ouverte pluridisciplinaire **HAL**, est destinée au dépôt et à la diffusion de documents scientifiques de niveau recherche, publiés ou non, émanant des établissements d'enseignement et de recherche français ou étrangers, des laboratoires publics ou privés.

ARTICLE

Mild endometriosis of the uterosacral ligaments: a retrospective study of magnetic resonance imaging performance for diagnosis

Margaux Stoppa¹, Aubert Agostini², Audrey Pivano², Pascale Siles¹,
Lisa Calderon¹, Antoine Netter^{2,3,*}

KEY MESSAGE

The identification of minimal changes in the normal appearance of USL should not automatically lead to the conclusion of mild endometriosis at this location. This should not be the sole argument for performing surgery, and the history, intensity of painful symptoms and clinical examination remain paramount in this context.

ABSTRACT

Research question: What are the diagnostic performances of magnetic resonance imaging (MRI) scans when used to identify mild endometriosis of the uterosacral ligaments (USL)?

Design: Monocentric retrospective study of patients who underwent a pelvic MRI followed by laparoscopy for determination of endometriosis between January 2016 and December 2020. Patients were included whether endometriosis of USL was suspected or not, but patients presenting large lesions that left no doubt as to their endometriotic nature on the MRI were excluded. Six criteria for the description of USL on MRI were studied to determine their diagnostic performances in predicting the presence of endometriosis on laparoscopy as follows: asymmetry, thickening, irregularity, straightness, the presence of a nodule or a hypersignal T1 spot.

Results: Seventy-seven patients were included. Among the criteria, 'asymmetry' and 'thickening' had the highest sensitivities (0.69 [95% confidence interval 0.54–0.80] and 0.51 [0.40–0.63], respectively) but moderate specificities (0.52 [0.31–0.73] and 0.62 [0.50–0.72]). Conversely, 'irregularity', 'nodule', 'straightness' and 'hypersignal T1 spot' were associated with high specificities (0.81 [0.70–0.89], 0.96 [0.89–0.99], 0.95 [0.87–0.99] and 0.99 [0.93–1.00], respectively) but poor sensitivities (0.22 [0.14–0.33], 0.12 [0.06–0.21], 0.08 [0.03–0.16] and 0.08 [0.03–0.16], respectively). The presence of at least one criterion for the description of the USL was associated with good sensitivity (0.80 [0.66–0.89]) but poor specificity (0.35 [0.16–0.57]).

Conclusions: The results suggest that the identification of minimal changes in the normal appearance of USL should not automatically lead to a conclusion of mild endometriosis at this location.

¹ Department of Women's Health Imaging, Assistance Publique Hôpitaux de Marseille, La Timone Hospital, 13005 Marseille, Aix Marseille University, France

² Department of Obstetrics and Gynecology, Assistance Publique Hôpitaux de Marseille, La Conception Hospital, 13005 Marseille, Aix Marseille University, France

³ Institut Méditerranéen de Biodiversité et d'Ecologie marine et continentale (IMBE), Aix Marseille University, CNRS, IRD, Avignon University, Marseille, France

KEYWORDS

Endometriosis
MRI
Uterosacral ligaments

INTRODUCTION

Although it affects approximately 10% of women of reproductive age, the diagnosis of endometriosis is still problematic, often with a long delay that postpones adequate management (Ballard *et al.*, 2006; Zondervan *et al.*, 2020). Magnetic resonance imaging (MRI) is recognized as one of the preferred methods of diagnosis because it allows complete mapping of deep endometriosis lesions to monitor their evolution or to plan excision surgery (Gerges *et al.*, 2021; Netter *et al.*, 2019). Among the structures that are routinely observed by radiologists, the uterosacral ligaments (USL) are the most frequent location of deep endometriosis (Hajati and Hajati, 2022). USL connect the posterior surface of the uterine cervix to the anterior surface of the first sacral pieces. Their common origin is behind the uterus, near the isthmus on the midline, where their union forms the torus uterinum (Gray and Lewis, 1918).

According to the literature, MRI scans have very good diagnostic performance in detecting the presence of deep endometriosis on USL, with high specificity and sensitivity (superior to 0.80 for both) (Gerges *et al.*, 2021). However, this structure, which measures approximately 1 mm in diameter, has not traditionally been observed on MRI in the absence of any lesion. With the advent of more efficient MRI and the generalization of thin sections (2–3 mm) passing specifically in the plane of USL, radiologists can now perceive all subtleties in the shape and size of these organs (Bazot *et al.*, 2011). There are no precise semiological criteria for the description of USL, and it has become difficult to differentiate between variants of normal and mild endometriotic involvement. Confirming the absence of endometriosis is thus particularly problematic, especially when no other lesion is found in the pelvis and the deformities observed on the USL are minimal.

With the high profile of endometriosis in the media over the last decade, the number of pelvic MRI scans requested for suspected endometriosis has dramatically increased (Holowka, 2022; Towne *et al.*, 2021). As a result, cases of women with suggestive symptoms whose MRI reveals only very slight abnormalities have become common (Le Moal *et al.*, 2022). Radiologists are often forced to describe these abnormalities, which often concern

USL, without being able to confirm their pathological nature or the presence of endometriosis. This uncertainty on the part of medical staff often causes additional stress for patients and complicates management decisions, especially regarding surgery.

This study sought to determine the diagnostic value of MRI semiology in identifying mild endometriosis of the USL.

MATERIALS AND METHODS

Study design

This retrospective study was conducted between January 2016 and December 2020 in the Department of Medical Imaging at La Timone Hospital and the Department of Obstetrics and Gynecology at La Conception Hospital, Marseille, France. The study was approved by an independent ethics committee (RGPD/Ap-Hm 2022-63, 22 August 2022).

Study population

Women whose medical cases were discussed during monthly pluridisciplinary endometriosis meetings during the study period were screened for eligibility. To be included in the study, women needed to have undergone laparoscopy for endometriosis when between 18 and 45 years old and also to have undergone an MRI of sufficient quality during the year before surgery. Patients could be included whether endometriosis of the USL was suspected or not (FIGURE 1A and 1B). Exclusion criteria were large lesions leaving no doubt as to their endometriotic nature on an MRI (according to two radiologists), an absence of description of the USL on the surgical report, and insufficient quality of the MRI that prohibited the proper assessment of USL implication (FIGURE 1C and 1D).

MRI technique and analysis

All MRI were performed at the Women's Health Imaging Department at La Timone Hospital (Marseille, France) no more than a year before surgery. MRI were performed with a Siemens Spectra 3.0T MRI device (Siemens AG, Munich, Germany) according to the guidelines for endometriosis of the European Society of Urogenital Radiology (Bazot *et al.*, 2017). This protocol includes T1-weighted sequences with and without fat saturation, and T2-weighted sequences in the sagittal, axial \pm coronal planes and a thin section

sequence (2 mm) in an axial oblique plane perpendicular to the long axis of the cervix, i.e. the plane of the USL. The protocol also requires digestive preparation and use of an antispasmodic to reduce intestinal peristalsis. The sequences are acquired with anterior and posterior abdominal saturation bands to avoid the signal from s. c. fat.

Every MRI was independently interpreted by two experienced radiologists (LC and MS) who did not have access to any medical files or any information regarding the surgery. In cases of disagreement over the presence of endometriosis of the USL, the MRI in question could be secondarily and jointly read again by two radiologists to reach consensus.

After an exploration of the literature and a discussion with different radiologists at the study unit, six criteria for describing USL were chosen: (i) asymmetry between the two USL (FIGURE 2A), (ii) thickening (FIGURE 2B), (iii) irregularity (FIGURE 2C) and (iv) straightness (FIGURE 2D) on T2-weighted sequences, (v) the presence of a nodule on any sequence (FIGURE 2E) and (vi) the presence of a focal T1 hypersignal (FIGURE 2F). The radiologists were asked to fill a grid with the characteristics of the USL for each side. They also measured the proximal diameter of each ligament on the T2 sequence in the sagittal or axial plane and reported the presence of ovarian endometriomas and superficial or deep lesions of endometriosis, according to previously published criteria (Netter *et al.*, 2021).

Surgery and histopathology

Surgical and histopathology reports were retrospectively analysed to ascertain the visual presence of endometriosis during surgery and its histological confirmation. All patients underwent laparoscopy in the study unit. Since 2016, standardized surgical reports have been used, including a description of the right and left USL to assess the presence or absence of endometriosis according to the surgeon. Visible lesions are generally resected in their entirety and sent for histopathology to confirm the presence or absence of endometriosis. Occasionally, USL apparently free of endometriosis may also be biopsied, particularly when no other endometriosis lesions are found during exploration of the peritoneal cavity.

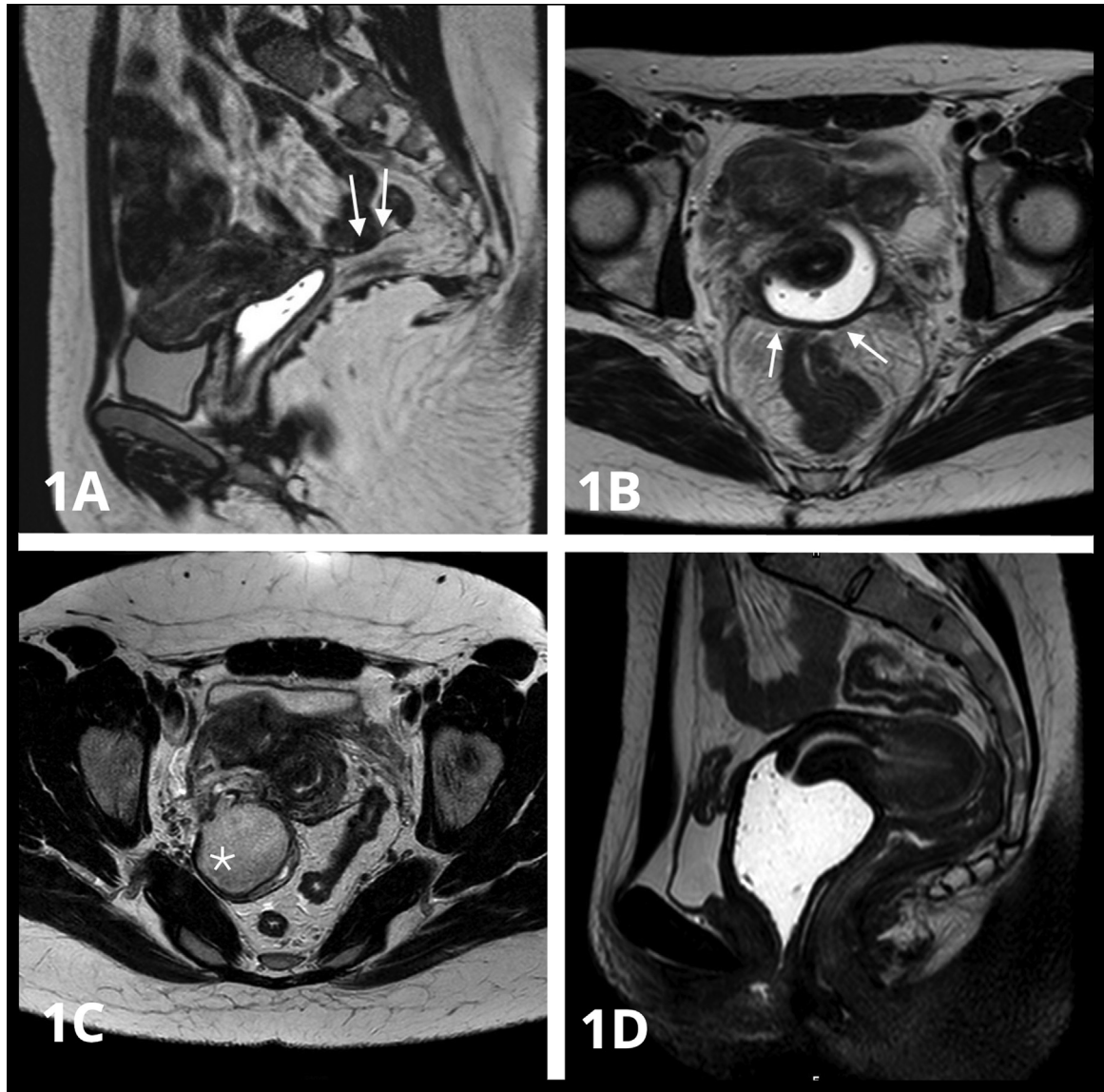


FIGURE 1 Normal uterosacral ligaments (USL) and examples of situations that do not allow proper visualization of USL from the MRI. 1A and 1B: Axial and sagittal T2-weighted sections showing normal USL (arrows) with no lesions found during laparoscopy. 1C: The T2-weighted axial section; endometrioma of the right ovary (star) interfering with visualization of the right USL. 1D: The T2-weighted sagittal section; retroverted retroflexed uterus hindering the visualization of the USL. MRI = magnetic resonance imaging; USL = uterosacral ligament.

Statistical analysis

The number of subjects included was constrained by the duration of the study, dating back to the date of implementation of standardization of the surgical reports for endometriosis (January 2016).

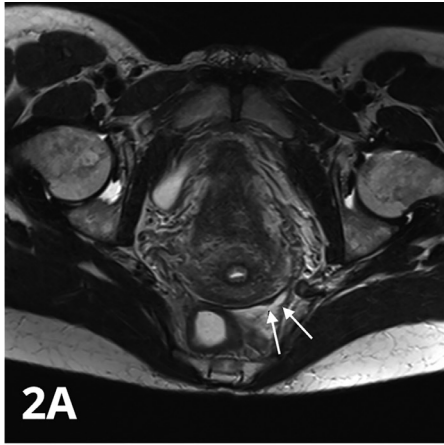
Descriptive data are reported using means \pm SD or medians (minimum–maximum) for quantitative variables and by counts (percentages) for categorical variables. Therefore, the demographic characteristics, symptomatology and clinical examination of the women were described as well as surgical and imaging data.

For each previously defined MRI sign, the agreement between the two radiologists responsible for the review was calculated using Cohen's kappa (κ) method and is expressed as κ (95% confidence interval [95% CI]). Additionally, the right and left USL were individually considered in this analysis.

The diagnostic performance (primary end-point) of each MRI sign was estimated using the presence or absence of endometriosis from the laparoscopy as the reference. The right and left USL were individually considered for all criteria, except for the

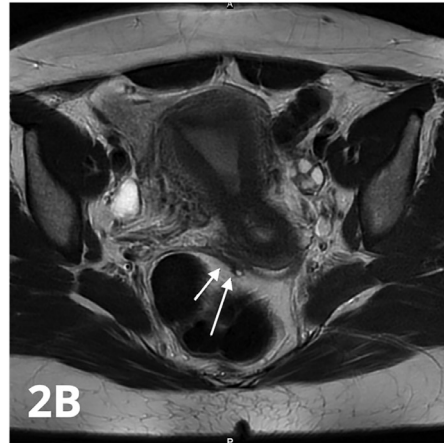asymmetry criterion, which required consideration of both USL. For each sign, the sensitivity, specificity, positive likelihood ratio, negative likelihood ratio, positive predictive value, negative predictive value and accuracy are reported with the 95% CI.

A receiver operating characteristic (ROC) curve was used to evaluate the ability of the measurement of USL thickness from the MRI to predict the presence or absence of endometriosis based on laparoscopy. A cut-off value for USL thickness measurement was examined using the Youden index (sensitivity + specificity – 1)



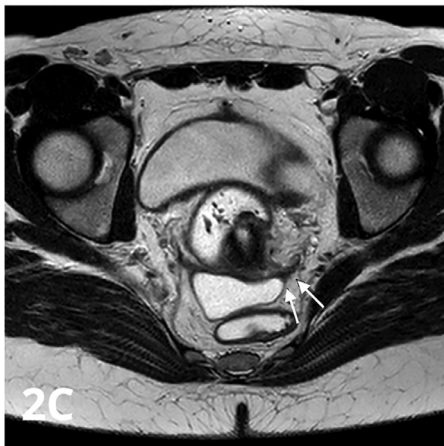
2A

Asymmetry



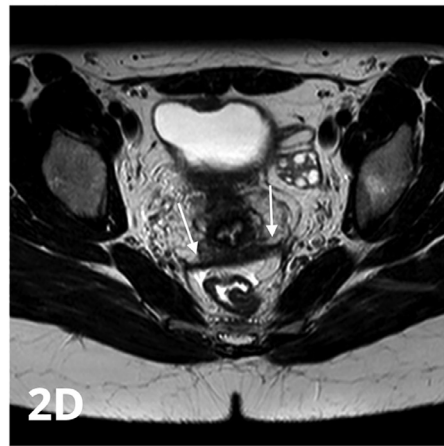
2B

Thickening



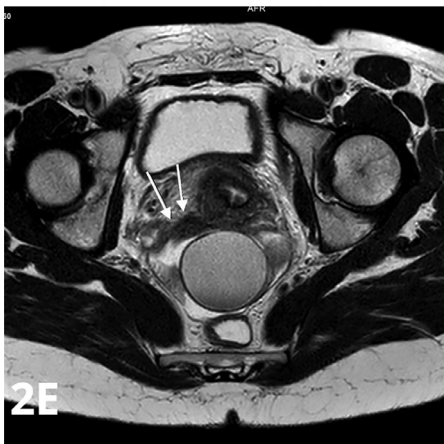
2C

Irregularity



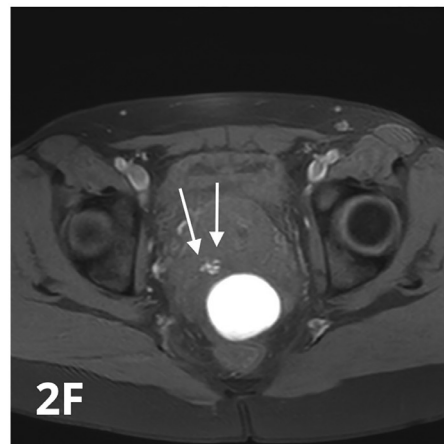
2D

Straightness



2E

Nodule



2F

Spot

FIGURE 2 Morphological criteria for the description of uterosacral ligaments (USL) on the MRI. 2A: The axial T2-weighted section showing asymmetry of the USL with a 2 mm nodular thickening of the right USL (arrows). 2B: The axial T2-weighted section with vaginal tagging showing thickening of the left USL (arrows). 2C: The axial T2-weighted section showing an irregular aspect of the right USL (arrows). 2D: The axial section in T2 weighting; the straightness of the right and left USL (arrows). 2E: The T2-weighted axial section; the right USL nodule measured at 6 mm (arrows). 2F: T1-weighted axial section; the haemorrhagic spot (arrows) at the origin of the right USL. Endometrioma of the left ovary. MRI = magnetic resonance imaging; USL = uterosacral ligament.

to find the best compromise between specificity and sensitivity.

All statistical analyses were two-sided, and the results were considered statistically significant when the *P*-value was <0.05. These analyses were performed using SPSS Statistics for Windows, Version 20.0 (IBM Corp., Armonk, NY, USA).

RESULTS

Population and surgery

Between January 2016 and December 2020, 539 medical files were presented during the monthly endometriosis multidisciplinary team meetings. After applying exclusion criteria, 77 patients were included in the retrospective analysis (FIGURE 3). The women's characteristics are summarized in TABLE 1. The mean age was 30.5 ± 7.0 years, and the vast majority of patients underwent surgery for pain symptoms (73/77, 94.8%).

The surgical characteristics are reported in TABLE 2. Almost half of the included women had minimal or moderate endometriosis according to the American Society for Reproductive Medicine's revised

classification of endometriosis (rASRM) score [28/58 (48.3%)]. Clinical examination under general anaesthesia was reported for 42 women, and USL lesions on either side or both sides was suspected for 25/42 (59.5%). During laparoscopy, USL endometriosis was suspected in 54/77 (70.1%) patients. Fifty-seven women had ablation of one or both USL, and endometriosis was histologically confirmed for 39/57 (68.4%).

MRI analysis

The MRI characteristics of the women are reported in TABLE 3. The most frequently reported criteria for the description of USL by the radiologists were 'thickening' (54/77 women [70.1%]), followed by 'asymmetry' (48/77 [62.3%]), 'irregularity' (28/77 [36.4%]), 'nodule' (10/77 [13.0%]), 'hypersignal T1 spot' (7/77 [9.1%]) and 'straightness' (5/77 [6.5%]).

The diagnostic performance of each MRI criterion for the surgical confirmation of USL endometriosis is presented in TABLE 4.

Among these criteria, 'asymmetry' and 'thickening' had the highest sensitivities (0.69 [95% CI 0.54–0.80] and 0.51 [95% CI 0.40–0.63], respectively) but moderate specificities (0.52 [95% CI 0.31–0.73] and

0.62 [95% CI 0.50–0.72], respectively). Conversely, 'irregularity', 'nodule', 'straightness' and 'hypersignal T1 spot' were associated with high specificities (0.81 [95% CI 0.70–0.89], 0.96 [95% CI 0.89–0.99], 0.95 [95% CI 0.87–0.99] and 0.99 [95% CI 0.93–1.00], respectively) but poor sensitivities (0.22 [95% CI 0.14–0.33], 0.12 [95% CI 0.06–0.21], 0.08 [95% CI 0.03–0.16] and 0.08 [95% CI 0.03–0.16], respectively). The presence of at least one criterion for the description of the USL was associated with good sensitivity (0.80 [95% CI 0.66–0.89]) but poor specificity (0.35 [95% CI 0.16–0.57]).

A ROC curve (FIGURE 4) was used to determine the predictive value of the USL diameter, and the area under the curve was 0.588 (95% CI 0.464–0.703). The best cut-off value for the prediction of endometriosis was found at a diameter of 3.85 mm, which was associated with a sensitivity of 0.46 and a specificity of 0.83 (Youden index 0.293).

The inter-observer agreement was assessed for each criterion and the diameter of the USL (TABLE 5). Agreement between the radiologists were excellent for 'straightness' (Cohen's $\kappa = 0.827$ [95% CI

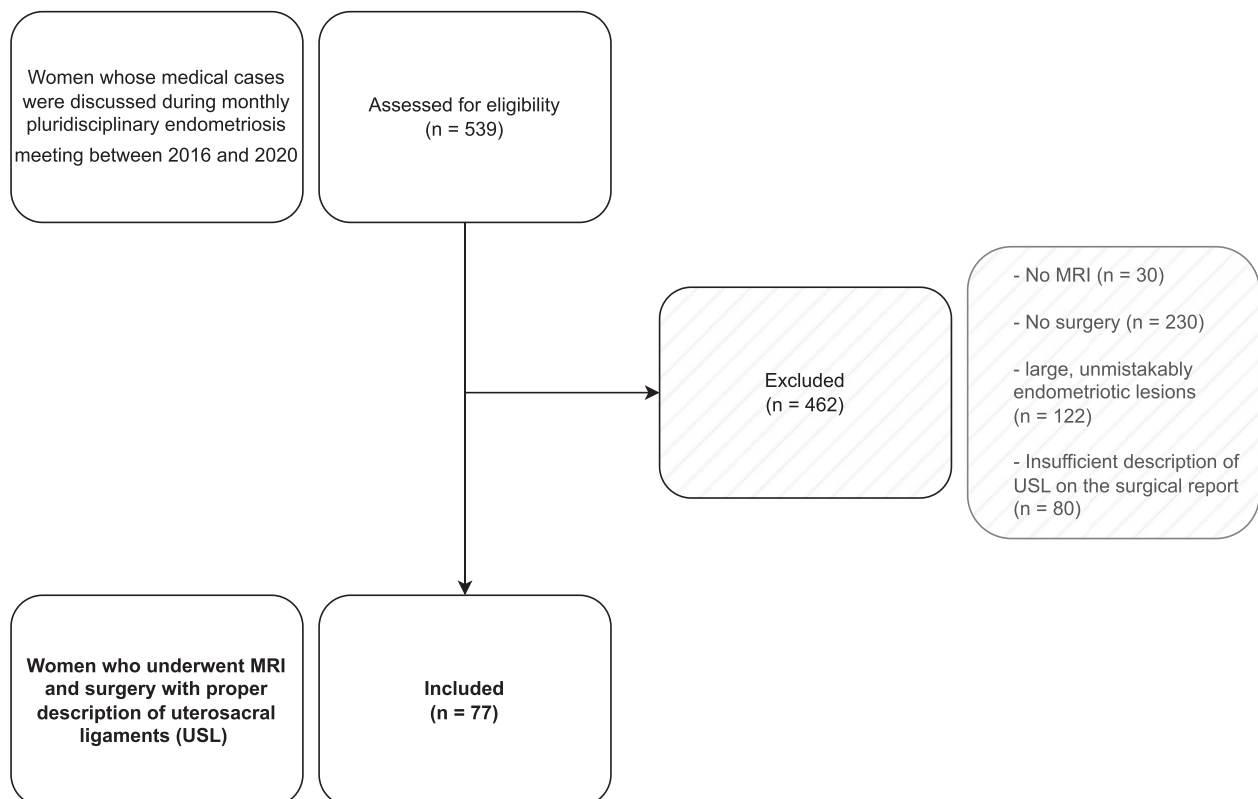


FIGURE 3 A flow chart summarizing the population included in this study.

TABLE 1 POPULATION CHARACTERISTICS

Characteristic	n = 77
Age at MRI (years), mean ± SD	30.5 ± 7.0
BMI (kg/m ²), mean ± SD (n = 30)	22.5 ± 4.1
Reason for surgery	
Pelvic pain	73/77 (94.8)
Infertility	4/77 (5.2)
Obstetrical history	
Nulligesta	42/77 (54.5)
Nullipara	55/77 (71.4)
Miscarriage	10/77 (13.0)
Ectopic pregnancy	4/77 (5.2)
Hormonal treatment	40/77 (51.9)
Symptoms	
Dysmenorrhoea	67/77 (87.0)
Digestive symptoms	40/77 (51.9)
Pain with urination	20/77 (26.0)
Deep dyspareunia	60/77 (77.9)
USL lesion on vaginal exam	
Total	20/43 (46.5)
Bilateral	4/43 (9.3)
Left	15/43 (34.9)
Right	9/43 (20.9)

Data are presented as n/N (%) unless otherwise stated.

BMI = body mass index; MRI = magnetic resonance imaging; USL = uterosacral ligament.

0.592–1.062]), good for the measurement of diameter (intraclass correlation coefficient 0.609 [95% CI 0.462–0.723]) and ‘thickening’ ($\kappa = 0.633$ [0.510–0.756]), moderate for ‘asymmetry’ ($\kappa = 0.593$ [95% CI 0.411–0.775]) and ‘irregularity’ ($\kappa = 0.465$ [95% CI 0.285–0.645]) and poor for ‘nodule’ ($\kappa = 0.386$ [95% CI 0.098–0.674]) and ‘hypersignal T1 spot’ ($\kappa = 0.319$ [95% CI 0.157–0.795]).

DISCUSSION

This is the first study to specifically address the MRI description of mild USL endometriosis. The study population was largely selected to keep only the most subtle and doubtful cases, which are challenging for radiologists. The study suggests that MRI is an imperfect examination in cases of mild USL endometriosis and that even experienced radiologists will have difficulty stating with certainty the presence or absence of endometriosis in these specific cases. Six

TABLE 2 SURGICAL AND HISTOPATHOLOGICAL DATA

Palpation of USL lesion by clinical examination under anaesthesia	
Total	25/42 (59.5)
Bilateral ^a	8/42 (19.0)
Right	17/42 (40.5)
Left	16/42 (38.1)
Endometriosis lesion of a USL visualized laparoscopically	
Total	54/77 (70.1)
Bilateral ^a	21/77 (27.3)
Right	37/77 (48.1)
Left	38/77 (49.4)
USL resection	
Total	57/77 (74.0)
Bilateral ^a	22/77 (28.6)
Right	40/77 (51.9)
Left	39/77 (50.6)
Other endometriosis lesion visualized by laparoscopy	
Endometrioma	22/77 (28.6)
Superficial peritoneal endometriosis	53/77 (68.8)
Absence of endometriosis lesion at laparoscopy	7/77 (9.1)
rASRM score	
Median (minimum–maximum)	12 (0–108)
Minimal (I) or moderate (II)	28/58 (48.3)
Moderate (III) or severe (IV)	30/58 (51.7)

Histological confirmation of USL endometriosis	
Total	39/57 (68.4)
Bilateral ^a	14/22 (63.6)
Right	27/40 (67.5)
Left	26/39 (66.7)

Histological confirmation of other endometriosis location	
Total	44/53 (83.0)

Data are presented as n/N (%) unless otherwise stated.

rASRM = revised American Society for Reproductive Medicine classification of endometriosis; USL = uterosacral ligament.

^a For statistical reasons an involvement of both USL (bilateral) is also counted in right and left.

criteria were listed, and one MRI measurement; their values for detecting the presence of endometriosis were precisely reported. None of the reported criteria has sufficient diagnostic performance to be used alone, and when considered together, they lose all specificity. Asymmetry and thickening

TABLE 3 MRI CHARACTERISTICS OF THE USL

Characteristic	n = 77
Asymmetry	48/77 (62.3)
Thickening	
Total	54/77 (70.1)
Bilateral ^a	15/77 (19.5)
Right	36/77 (46.8)
Left	33/77 (42.9)
Irregularity	
Total	28/77 (36.4)
Bilateral ^a	4/77 (5.2)
Right	19/77 (24.7)
Left	13/77 (16.9)
Nodule	
Total	10/77 (13.0)
Bilateral ^a	2/77 (2.6)
Right	5/77 (6.5)
Left	7/77 (9.1)
Straightness	
Total	5/77 (6.5)
Bilateral ^a	5/77 (6.5)
Right	5/77 (6.5)
Left	5/77 (6.5)
Hypersignal T1 spot	
Total	7/77 (9.1)
Bilateral ^a	1/77 (1.3)
Right	5/77 (6.5)
Left	2/77 (2.6)
USL diameter (mm), mean ± SD	
Right	3.3 ± 2.3
Left	3.5 ± 2.0
Other endometriosis lesion	
Total	46/77 (59.7)
Ovary	36/77 (46.8)

Data are presented as n/N (%) unless otherwise stated.

The diagnostic performance of each MRI sign was estimated by using the presence or absence of endometriosis from the laparoscopy as the reference. The right and left USL were individually considered for all criteria, except for the asymmetry criterion, which required consideration of both USL. CI were calculated using the Clopper–Pearson exact method.

^a For statistical reasons an involvement of both USL (bilateral) is also counted in right and left. CI = confidence interval; MRI = magnetic resonance imaging; USL = uterosacral ligament.

were the most sensitive morphological criteria but were associated with moderate specificities, while the presence of a nodule, a hypersignal T1 spot or the

TABLE 4 DIAGNOSTIC PERFORMANCES OF MRI MORPHOLOGICAL CRITERIA FOR THE DETECTION OF ENDOMETRIOSIS LESIONS OF THE USL

	Sensitivity (95% CI)	Specificity (95% CI)	PVR (95% CI)	NVR (95% CI)	PPV (95% CI)	NPV (95% CI)	Precision (95% CI)
Asymmetry (n = 77)	0.69 (0.54–0.80)	0.52 (0.31–0.73)	1.43 (0.90–2.28)	0.60 (0.35–1.05)	0.77 (0.68–0.84)	0.42 (0.29–0.55)	0.64 (0.52–0.74)
Thickening (n = 154)	0.51 (0.40–0.63)	0.62 (0.50–0.72)	1.33 (0.93–1.90)	0.79 (0.59–1.06)	0.56 (0.47–0.65)	0.57 (0.50–0.64)	0.57 (0.48–0.65)
Irregularity (n = 154)	0.22 (0.14–0.33)	0.81 (0.70–0.89)	1.6 (0.63–2.16)	0.96 (0.82–1.13)	0.53 (0.38–0.67)	0.52 (0.48–0.56)	0.52 (0.44–0.60)
Nodule (n = 154)	0.12 (0.06–0.21)	0.96 (0.89–0.99)	3.08 (0.87–10.94)	0.92 (0.83–1.01)	0.75 (0.45–0.91)	0.53 (0.51–0.55)	0.55 (0.47–0.63)
Straightness (n = 154)	0.08 (0.03–0.16)	0.95 (0.87–0.99)	1.54 (0.45–5.24)	0.97 (0.89–1.06)	0.60 (0.30–0.83)	0.52 (0.50–0.54)	0.52 (0.44–0.60)
Hypersignal T1 spot (n = 154)	0.08 (0.03–0.16)	0.99 (0.93–1.00)	6.16 (0.76–49.95)	0.93 (0.87–1.00)	0.86 (0.42–0.98)	0.53 (0.51–0.54)	0.54 (0.46–0.62)
Presence of at least one criterion on at least one USL (n = 77)	0.80 (0.66–0.89)	0.35 (0.16–0.57)	1.22 (0.88–1.69)	0.59 (0.27–1.26)	0.74 (0.67–0.80)	0.42 (0.25–0.61)	0.66 (0.54–0.77)

CI = confidence interval; NPV = negative predictive value; NVR = negative likelihood ratio; PPV = positive predictive value; PVR = positive likelihood ratio; USL = uterosacral ligament.

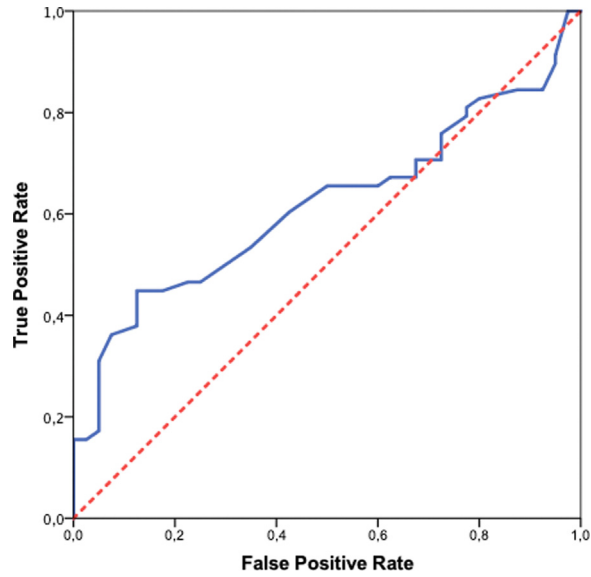


FIGURE 4 The receiving operative characteristic curve for the prediction of endometriosis assessment during laparoscopy according to the uterosacral ligament diameter in the magnetic resonance imaging scan. Area under the curve 0.588 (95% confidence interval 0.464–0.703); $P = 0.132$. The maximum Youden index was calculated at 0.293 for a 3.85 mm measurement with a sensitivity of 0.46 and a specificity of 0.83.

irregular appearance of USL appeared to have good specificities but low sensitivities in this population. Concerning the diameter measurement, the threshold value reported has good specificity but low sensitivity and is therefore of little use in most cases (when the diameter is below the threshold). Furthermore, apart from the criteria ‘thickening’ and ‘straightness’ and the diameter measurement, the other criteria remain subject to moderate to low agreement between observers.

Bazot and Darai (2017) describe USL involvement as basically a spiculated nodule or irregular thickening with hypointense on T2-weighted sequences and where asymmetry would be strongly suggestive of the diagnosis; this highlights the importance of comparing the two

ligaments. Histologically, hypointense lesions on T2-weighted sequences reflect fibromuscular hyperplasia lesions, and focal T1-weighted hypersignals correspond to haemorrhagic implants as observed in other endometriosis locations (*Anafet et al., 2000*). The straightness aspect of USL is not described in the literature, but this criterion showed very good specificity and good inter-observer correlation in the current study. It is possible that this aspect reflects an incipient rigid fibrous infiltration in endometriosis of the ligaments at a lesser stage than for the ‘arciform’ aspect classically described by authors in the case of severe bilateral involvement (*Bazot and Darai, 2017*). However, the criterion of ‘thickening’ of the USL, which is cited in several reference publications as a sign of endometriosis, appears to be of little

TABLE 5 INTER-OBSERVER AGREEMENT FOR USL ANALYSIS

Characteristic	Cohen’s kappa (95% CI)	P-value
Diameter, mm	0.609 (0.462–0.723)	<0.001
Asymmetry	0.593 (0.411–0.775)	<0.001
Thickening	0.633 (0.510–0.756)	<0.001
Irregularity	0.465 (0.285–0.645)	<0.001
Straightness	0.827 (0.592–1.062)	<0.001
Nodule	0.386 (0.098–0.674)	<0.001
Hypersignal T1 spot	0.319 (0.157–0.795)	<0.001

CI = confidence interval; USL = uterosacral ligament.

relevance in this study population, with insufficient sensitivity and specificity (Bazot and Darai, 2017; Coutinho et al., 2011). To refine this notion of thickening, several authors have already attempted to determine a threshold for measuring the diameter of the USL to evoke the diagnosis of endometriosis, i.e. >9 mm for Kinkel et al. (1999) or >3 mm for Bazot and Darai (2017). In the current study population, the diameter measurement was moderately correlated with the presence of an endometriotic lesion (area under the curve 0.59) with cases of ligaments measured at less than 3 mm even though they were pathological at laparoscopy. Some studies also suggest that healthy USL may have a thickened appearance and postulated that pathological ligaments may be thin in the 'fibrous' phase of the disease and that the ligaments may be more voluminous in the active inflammatory phase of endometriosis (Ohba et al., 1996). Furthermore, measurement of the diameter of the USL is not always feasible as analysis of this area may be limited by uterine retroflexion and the presence of myoma or endometrioma within the pouch of Douglas (Bazot et al., 2011).

Gerges et al. (2021) conducted a systematic review and meta-analysis to determine the optimal modality for the detection of USL. They included four MRI studies with a total of 440 women and found high sensitivity (81% [66–90%]) and specificity (83 [62–94%]) (Alborzi et al., 2018; Bazot et al., 2013; Fiaschetti et al., 2012; Manganaro et al., 2013). Other previous meta-analyses reported similar results (Guerrero et al., 2018; Nisenblat et al., 2016; Noventa et al., 2019). These differences are not surprising, as the populations included in these studies used broader selection than in the current study and included women for whom the presence of USL endometriosis was obvious on MRI. Indeed, almost half of the current study population had minimal to moderate endometriosis with a median rASRM score of 12, and for 9.1% of patients, no endometriosis lesions were ultimately found during laparoscopy. In this sense, this study specifically addresses the issue of cases that radiologists are likely to misidentify as endometriosis.

The main weakness of the present study is its retrospective nature, which systematically raises the question of data quality. There are no such concerns regarding the data in this study because the consultations and operative reports

were standardized for endometriosis patients throughout the study period. Thus, the description of USL was systematically reported and often associated with laparoscopic images for all procedures. Additionally, the retrospective nature of the study has no impact on the interpretation of the MRI scans as they were reviewed as part of the study. Some might argue that the sample is too small to draw conclusions. This is due to the very restrictive exclusion criteria that were used to retain only the most dubious cases, which were truly challenging for radiologists. Moreover, the sample size is comparable to that of other studies dealing with the recognition of USL in MRI. Another criticism is the creation of criteria that are not justified by a sound literary basis. To our knowledge, there are no other studies or data in the literature concerning the MRI description of anatomical variations of USL or mild endometriosis at this location. Six distinct criteria were provided, which are used in current practice and whose iconographies will inevitably evoke subtle deformities that radiologists have already encountered. Although these criteria can also be reused for scientific or practical purposes, they are primarily useful in this study as they demonstrate that mild USL deformities are not necessarily indicative of endometriosis.

Thus, the current results suggest that the identification of minimal changes in the normal appearance of USL should not automatically lead to the conclusion of mild endometriosis at this location. More importantly, this should not be the sole argument for performing surgery, and the history, intensity of painful symptoms and clinical examination remain paramount in this context.

DATA AVAILABILITY

Data will be made available on request.

REFERENCES

- Alborzi, S., Rasekhi, A., Shomali, Z., Madadi, G., Alborzi, M., Kazemi, M., Hosseini Nohandani, A., 2018. Diagnostic accuracy of magnetic resonance imaging, transvaginal, and transectal ultrasonography in deep infiltrating endometriosis. *Medicine (Baltimore)* 97, e9536. <https://doi.org/10.1097/MD.0000000000009536>
- Anaf, V., Simon, P., Fayt, I., Noel, J., 2000. Smooth muscles are frequent components of endometriotic lesions. *Hum. Reprod.* 15, 767–771. <https://doi.org/10.1093/humrep/15.4.767>
- Ballard, K., Lowton, K., Wright, J., 2006. What's the delay? A qualitative study of women's experiences of reaching a diagnosis of endometriosis. *Fertil. Steril.* 86, 1296–1301. <https://doi.org/10.1016/j.fertnstert.2006.04.054>
- Bazot, M., Darai, E., 2017. Diagnosis of deep endometriosis: clinical examination, ultrasonography, magnetic resonance imaging, and other techniques. *Fertil. Steril.* 108, 886–894. <https://doi.org/10.1016/j.fertnstert.2017.10.026>
- Bazot, M., Bharwani, N., Huchon, C., Kinkel, K., Cunha, T.M., Guerra, A., Manganaro, L., Buñesch, L., Kido, A., Togashi, K., Thomassin-Naggara, I., Rockall, A.G., 2017. European Society of Urogenital Radiology (ESUR) guidelines: MR imaging of pelvic endometriosis. *Eur. Radiol.* 27, 2765–2775. <https://doi.org/10.1007/s00330-016-4673-z>
- Bazot, M., Gasner, A., Ballester, M., Darai, E., 2011. Value of thin-section oblique axial T2-weighted magnetic resonance images to assess uterosacral ligament endometriosis. *Hum. Reprod.* 26, 346–353. <https://doi.org/10.1093/humrep/deq336>
- Bazot, M., Stivalet, A., Darai, E., Coudray, C., Thomassin-Naggara, I., Poncelet, E., 2013. Comparison of 3D and 2D FSE T2-weighted MRI in the diagnosis of deep pelvic endometriosis: preliminary results. *Clin. Radiol.* 68, 47–54. <https://doi.org/10.1016/j.crad.2012.05.014>
- Coutinho, A., Bittencourt, L.K., Pires, C.E., Junqueira, F., Lima, C.M.A., de, O., Coutinho, E., Domingues, M.A., Domingues, R.C., Marchiori, E., 2011. MR imaging in deep pelvic endometriosis: a pictorial essay. *Radiographics* 31, 549–567. <https://doi.org/10.1148/rg.312105144>
- Fiaschetti, V., Crusco, S., Meschini, A., Cama, V., Di Vito, L., Marziali, M., Piccione, E., Calabria, F., Simonetti, G., 2012. Deeply infiltrating endometriosis: evaluation of retro-cervical space on MRI after vaginal opacification. *Eur. J. Radiol.* 81, 3638–3645. <https://doi.org/10.1016/j.ejrad.2011.06.058>
- Gerges, B., Li, W., Leonardi, M., Mol, B.W., Condous, G., 2021. Meta-analysis and systematic review to determine the optimal imaging modality for the detection of uterosacral ligaments/torus uterinus, rectovaginal septum and vaginal deep endometriosis. *Hum. Reprod. Open.* 2021. <https://doi.org/10.1093/hropen/hoab041> hoab041.
- Gray, H., Lewis, W.H., 1918. *Anatomy of the Human Body*. Philadelphia: Lea and Febiger. 1260–1261.
- Guerrero, S., Saba, L., Pascual, M.A., Ajossa, S., Rodriguez, I., Mais, V., Alcazar, J.L., 2018. Transvaginal ultrasound vs magnetic resonance imaging for diagnosing deep infiltrating endometriosis: systematic review and meta-analysis. *Ultrasound Obstet Gynecol* 51, 586–595. <https://doi.org/10.1002/uog.18961>

- Hajati, A., Hajati, O., 2022. A review of more than 2000 cases of site-specific pelvic endometriosis rates by MRI: a guide to minimizing under/overdiagnosis non-invasively. *Insights Imaging* 13, 129. <https://doi.org/10.1186/s13244-022-01270-z>.
- Holowka, E.M., 2022. Mediating pain: navigating endometriosis on social media. *Front Pain Res (Lausanne)* 3, 889990. <https://doi.org/10.3389/fpain.2022.889990>.
- Kinkel, K., Chapron, C., Balleyguier, C., Fritel, X., Dubuisson, J.B., Moreau, J.F., 1999. Magnetic resonance imaging characteristics of deep endometriosis. *Hum. Reprod.* 14, 1080–1086. <https://doi.org/10.1093/humrep/14.4.1080>.
- Le Moal, J., Gorla, S., Chesneau, J., Fauconnier, A., Kvaskoff, M., De Crouy-Chanel, P., Kahn, V., Daraï, E., Canis, M., 2022. Increasing incidence and spatial hotspots of hospitalized endometriosis in France from 2011 to 2017. *Sci. Rep.* 12, 6966. <https://doi.org/10.1038/s41598-022-11017-x>.
- Manganaro, L., Vinci, V., Bernardo, S., Storelli, P., Fuggetta, E., Sollazzo, P., Ticino, A., Sergi, M.E., Brunelli, R., Panici, P.B., Porpora, M.G., 2013. The role of 3.0T MRI in the assessment of deep endometriosis located on the uterosacral ligaments. *J. Endometr. Pelvic. Pain Disord.* 5, 10–16. <https://doi.org/10.5301/JE.5000152>.
- Netter, A., d'Avout-Fourdinier, P., Agostini, A., Chanavaz-Lacheray, I., Lampika, M., Farella, M., Henriet, C., Roman, H., 2019. Progression of deep infiltrating rectosigmoid endometriotic nodules. *Hum. Reprod.* 34, 2144–2152. <https://doi.org/10.1093/humrep/dez188>.
- Netter, A., Dechaud, H., Chêne, G., Hebert, T., Dubernard, G., Faller, É., Benichou, R., Chapron, C., Canis, M., Roman, H., 2021. Surgical management of endometriotic women with pregnancy intention in France: a national snapshot of centers performing a high volume of endometriosis procedures. *J. Gynecol. Obstet. Hum. Reprod.* 50, 102130. <https://doi.org/10.1016/j.jogoh.2021.102130>.
- Nisenblatt, V., Bossuyt, P.M.M., Farquhar, C., Johnson, N., Hull, M.L., 2016. Imaging modalities for the non-invasive diagnosis of endometriosis. *Cochrane Database Syst Rev* 2, CD009591. <https://doi.org/10.1002/14651858.CD009591.pub2>.
- Noventa, M., Scioscia, M., Schincariol, M., Cavallin, F., Pontrelli, G., Virgilio, B., Vitale, S.G., Laganà, A.S., Dessole, F., Cosmi, E., D'Antona, D., Andrisani, A., Saccardi, C., Vitagliano, A., Ambrosini, G., 2019. Imaging modalities for diagnosis of deep pelvic endometriosis: comparison between transvaginal sonography, rectal endoscopy sonography and magnetic resonance imaging. A head-to-head meta-analysis. *Diagnostics (Basel)* 9, E225. <https://doi.org/10.3390/diagnostics9040225>.
- Ohba, T., Mizutani, H., Maeda, T., Matsuura, K., Okamura, H., 1996. Evaluation of endometriosis in uterosacral ligaments by transrectal ultrasonography. *Hum. Reprod.* 11, 2014–2017. <https://doi.org/10.1093/oxfordjournals.humrep.a019535>.
- Towne, J., Suliman, Y., Russell, K.A., Stuparich, M.A., Nahas, S., Behbehani, S., 2021. Health information in the era of social media: an analysis of the nature and accuracy of posts made by public Facebook pages for patients with endometriosis. *J. Minim. Invasive Gynecol.* 28, 1637–1642. <https://doi.org/10.1016/j.jmig.2021.02.005>.
- Zondervan, K.T., Becker, C.M., Missmer, S.A., 2020. Endometriosis. *N. Engl. J. Med.* 382, 1244–1256. <https://doi.org/10.1056/NEJMra1810764>.