



HAL
open science

Amphotericin B deoxycholate instillations through nephrostomy catheter as salvage treatment of massive *Nakaseomyces glabrata* renal fungus balls

Joseph Le Moulec, Léa Picard, Sorya Belaz, Audrey Couturier, Matthieu Revest, Pierre Tattevin, David Luque-Paz

► To cite this version:

Joseph Le Moulec, Léa Picard, Sorya Belaz, Audrey Couturier, Matthieu Revest, et al.. Amphotericin B deoxycholate instillations through nephrostomy catheter as salvage treatment of massive *Nakaseomyces glabrata* renal fungus balls. *Journal of Medical Mycology = Journal de Mycologie Médicale*, 2024, *Journal de Mycologie Médicale*, 34 (1), pp.101454. 10.1016/j.mycmed.2023.101454 . hal-04338313

HAL Id: hal-04338313

<https://hal.science/hal-04338313>

Submitted on 20 Feb 2024

HAL is a multi-disciplinary open access archive for the deposit and dissemination of scientific research documents, whether they are published or not. The documents may come from teaching and research institutions in France or abroad, or from public or private research centers.

L'archive ouverte pluridisciplinaire **HAL**, est destinée au dépôt et à la diffusion de documents scientifiques de niveau recherche, publiés ou non, émanant des établissements d'enseignement et de recherche français ou étrangers, des laboratoires publics ou privés.



Distributed under a Creative Commons Attribution - NonCommercial 4.0 International License

Letter to the editor

Amphotericin B deoxycholate instillations through nephrostomy catheter as salvage treatment of massive *Nakaseomyces glabrata* renal fungus balls

Joseph Le Moulec,¹ Léa Picard,¹ Sorya Belaz,² Audrey Couturier,¹ Matthieu Revest,¹ Pierre Tattevin,¹ David Luque-Paz¹

1 Infectious Diseases and Intensive Care Unit, Pontchaillou University Hospital, Rennes, France

2 Department of Parasitology and Mycology, Pontchaillou University Hospital, Rennes, France

Corresponding author:

David Luque-Paz, MD, MSc

Infectious Diseases and Intensive Care Unit

Pontchaillou University Hospital, 2, rue Henri Le Guilloux, 35033 Rennes Cedex 9, France.

Phone: +33 299289564.

ORCID: 0000-0002-9197-7305.

E-mail: david.luque.paz@chu-rennes.fr

Keywords: Fungus ball; *Candida glabrata*; amphotericin B deoxycholate

Ethical approval

Patient has given consent for publication.

Author contributions statement

JLM, DLP and PT wrote the original draft. JLM, LP, AC, MR and PT were in charge of the patient.

SB performed the laboratory analyses. LP, AC, MR and SB reviewed and edited the manuscript.

Declaration of Competing Interest

None

Funding source

None

Acknowledgment

None

Manuscript

Renal fungus ball, which is defined as a macroscopic aggregation of necrotic debris and mycelia filling renal pelvis, is a rare and difficult-to-treat complication of candiduria [1]. Only few cases have been reported in literature, and most of these were due to *Candida albicans*, usually susceptible to azoles [2,3]. For *Candida* species resistant to azoles, medical treatment may be challenging, as echinocandins exhibit poor excretion into urine. Liposomal amphotericin B penetration in the renal

parenchyma is lower than amphotericin B deoxycholate formulation [4]. Additionally, the presence of biofilm can limit antifungal diffusion. Surgical treatment may be the last resort, although this option may not be feasible in all patients due to severe comorbidities or frailty. Here, we present a case of massive *Nakaseomyces glabrata* (formerly *Candida glabrata*) renal fungus balls in an elderly patient with contra-indication for surgery, who was successfully treated by amphotericin B deoxycholate instillations through nephrostomy catheter in combination with intravenous amphotericin B deoxycholate and oral 5-fluorocytosine.

An 84-year-old man with a medical history of diabetes mellitus and prostatic adenocarcinoma treated by hormonal therapy and radiotherapy, was admitted for acute renal failure. Eight weeks before admission, he was successfully treated for symptomatic *Klebsiella oxytoca* urinary tract infection (UTI) with ceftriaxone, then for *C. albicans* candiduria with fluconazole. On admission, patient was afebrile, with bilateral flank pain, and vesical globe (volume estimated at 800 cc on bladder scan). Urethral catheterization failed, and supra-pubic catheter was inserted. Urine cultures grew *N. glabrata* (10^6 CFU/mL), resistant to fluconazole (Minimal Inhibitory Concentration, MIC >256 mg/L using E-test gradient strips, bioMérieux, Marcy-l'Étoile, France) and voriconazole (MIC 6 mg/L), but susceptible to amphotericin B (MIC 0.5 mg/l) and micafungin (MIC 0.016 mg/L). Abdominal CT scan showed filling defects on nephrogram phase in both pyelic kidneys, suggestive of renal fungus balls (Figure 1A). The patient was deemed not eligible for nephrolithotomy surgery given his underlying comorbidities, and previous radiotherapy, with high risk of post-operative complications. Endoscopic resection was attempted but failed as the pyelocaliceal cavities could not be catheterized. The patient was treated with local instillations through bilateral nephrostomy catheters of amphotericin B deoxycholate (50 mg diluted in 500 mL of sterile water), overnight for 6 weeks, in combination with 2-week course of intravenous amphotericin B deoxycholate (0.3 mg/kg/day) and oral 5-fluorocytosine (100 mg/kg/day after the rapid resolution of renal failure). Serious adverse events occurred during the first month, including i) methicillin-susceptible *Staphylococcus aureus* bacteremia secondary to left-sided pyelonephritis at day-14, successfully treated by two-week course of intravenous cloxacillin; ii) extended spectrum beta-lactamase producing *Enterobacter cloacae* bacteremia at day-27 with left-

sided pyelonephritis treated by two-week course of intravenous meropenem. The patient initially reported local pain at instillation site during amphotericin B instillations that could be controlled with reduced infusion flow (ie, 500 mL overnight, during 12 h), and opiates. Renal failure rapidly resolved following nephrostomy, and no biological adverse event related to amphotericin B deoxycholate or 5-fluorocytosine was observed.

A CT scan performed after 1-month of amphotericin B deoxycholate instillations showed a complete resorption of fungus ball on the left side, while a residual minimal defect of 10 mm in the inferior right calyx led to pursue amphotericin B deoxycholate instillations through the right nephrostomy until day-42. A CT scan performed 6-week after discontinuation of amphotericin B deoxycholate instillations found a 5 mm minimal defect in the medium calyx on the right side on nephrogram phase (Figure 1B). The supra-pubic catheter and both nephrostomy tubes could be explanted. The patient had no symptoms of relapse, and iterative urinalysis yielded negative bacterial and fungal cultures at 3-month and 6-month follow-up.

We report the successful use of 6-week course of amphotericin B instillations, combined with intravenous amphotericin B deoxycholate and oral 5-fluorocytosine during the first 2 weeks, as a salvage treatment for *N. glabrata* renal bilateral massive fungus ball in an elderly patient with contraindications for surgery and failure of per-endoscopic procedures. To our knowledge, this is the third report of *N. glabrata* renal fungus balls cured by medical treatment alone [5]. Despite the occurrence of serious adverse events (severe pain during first instillations, then 2 episodes of bloodstream infections related to bacterial pyelonephritis), the final outcome was satisfactory as the patient was cured, with no sequel. This observation advocates for the use of amphotericin B instillations as salvage treatment of azole-resistant fungus balls.

Fungal ball is an emerging disease due to the increasing prevalence of main risk factors, ie old age, diabetes mellitus, and broad-spectrum antibiotic use [6]. *C. albicans* is the main yeast responsible for renal fungus ball, with only four cases of successfully treated and reported cases of renal fungus balls caused by *N. glabrata* thus far. Doemeny *et al* combined local instillations with amphotericin B deoxycholate and percutaneous extraction [7]. Berlanga *et al* combined intravenous amphotericin B

deoxycholate, amphotericin B deoxycholate instillations, and endoscopic removal [8]. Rohloff *et al* combined amphotericin B deoxycholate instillations, intravenous micafungin, and fluconazole [5]. Viswambaram *et al* used amphotericin B deoxycholate instillations, intravenous liposomal amphotericin, and oral 5-fluorocytosine [9].

Besides surgery, there is no strong recommendation for fungus balls due to azole-resistant species, such as *Nakaseomyces glabrata*. The Infectious Diseases Society of America (IDSA) recommends intravenous amphotericin B deoxycholate (0.3-0.6 mg/kg daily for 7 days,) with or without oral 5-fluorocytosine (25 mg/kg 4 times daily) and suggests that amphotericin B deoxycholate irrigation through nephrostomy tube (25-50 mg/L in 200-500mL sterile water) may be useful [4].

Nephrostomy catheters are associated with serious adverse events, including UTI and sepsis, with a cumulative incidence estimated at 6% and 5%, respectively [10]. In addition, instillations through nephrostomy catheter usually led to extended hospital stay, as they are difficult to manage as outpatients. Although prolonged use of intravenous amphotericin B deoxycholate is associated with a high-risk of nephrotoxicity, this was not the case in our patient, despite daily instillations of amphotericin B deoxycholate during, respectively, 30 days and 42 days for the left and the right kidney. This is especially remarkable given that our patient was just recovering from obstructive acute renal failure.

In conclusion, this case report supports the use of amphotericin B deoxycholate instillation through nephrostomy catheter as salvage treatment of massive renal fungus balls due to azole-resistant *Candida* species, especially when surgery and endoscopic procedures cannot be performed.

References

- [1] Praz V, Burruni R, Meid F, Wisard M, Jichlinski P, Tawadros T. Fungus ball in the urinary tract: A rare entity. *Can Urol Assoc J* 2014;8:E118-120. <https://doi.org/10.5489/cuaj.1254>.
- [2] Abdeljaleel OA, Alnadhari I, Mahmoud S, Khachatryan G, Salah M, Ali O, et al. Treatment of Renal Fungal Ball with Fluconazole Instillation Through a Nephrostomy Tube: Case Report and Literature Review. *Am J Case Rep* 2018;19:1179–83. <https://doi.org/10.12659/AJCR.911113>.
- [3] Clark MA, Gaunt T, Czachor JS. The use of fluconazole as a local irrigant for nephrostomy tubes. *Mil Med* 1999;164:239–41.
- [4] Pappas PG, Kauffman CA, Andes DR, Clancy CJ, Marr KA, Ostrosky-Zeichner L, et al. Clinical Practice Guideline for the Management of Candidiasis: 2016 Update by the Infectious Diseases Society of America. *Clin Infect Dis* 2016;62:e1-50. <https://doi.org/10.1093/cid/civ933>.
- [5] Rohloff MA, Shakuri-Rad J, Dehaan AP. Candida Bezoars in Adults: Determining Optimal Management. *J Endourol Case Rep* 2017;3:45–8. <https://doi.org/10.1089/cren.2017.0021>.
- [6] Kauffman CA. Candiduria. *Clin Infect Dis* 2005;41 Suppl 6:S371-376. <https://doi.org/10.1086/430918>.
- [7] Doemeny JM, Banner MP, Shapiro MJ, Amendola MA, Pollack HM. Percutaneous extraction of renal fungus ball. *AJR Am J Roentgenol* 1988;150:1331–2. <https://doi.org/10.2214/ajr.150.6.1331>.
- [8] Berlanga GA, Machen GL, Lowry PS, Brust KB. Management of a renal fungal bezoar caused by multidrug-resistant *Candida glabrata*. *Proc (Bayl Univ Med Cent)* 2016;29:416–7. <https://doi.org/10.1080/08998280.2016.11929493>.
- [9] Viswambaram P, Misko J, Rawlins M, Clark S, Dyer J, Hayne D. Multi-route antifungal administration in the management of urinary *Candida glabrata* bezoar. *Urol Case Rep* 2020;33:101275. <https://doi.org/10.1016/j.eucr.2020.101275>.
- [10] Gauhar V, Traxer O, García Rojo E, Scarcella S, Pavia MP, Chan VW-S, et al. Complications and outcomes of tubeless versus nephrostomy tube in percutaneous nephrolithotomy: a systematic review and meta-analysis of randomized clinical trials. *Urolithiasis* 2022;50:511–22. <https://doi.org/10.1007/s00240-022-01337-y>.

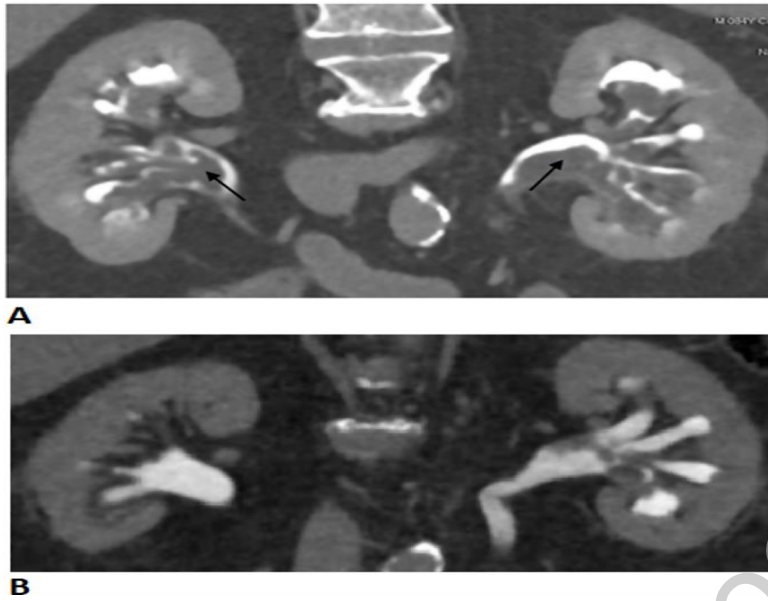
Figure Legends

Figure 1. Computed tomography urography coronal sections revealing massive renal fungus balls.

- A. Initial CT scan with filling defects in both pyelic kidneys (black arrows); B. CT scan 6 weeks after the end of treatment showing on the right kidney a 5 mm minimal defect in the medium calyx and on the left kidney some small defects in renal cavities.

Author contributions statement

JLM, DLP and PT wrote the original draft. JLM, LP, AC, MR and PT were in charge of the patient. SB performed the laboratory analyses. LP, AC, MR and SB reviewed and edited the manuscript.

Funding source

None

Acknowledgment

None

Declaration of Competing Interest

None

Journal Pre-proof