



HAL
open science

Oldest evidence of tuberculosis in the Mediterranean islands: From the mainland to Cyprus

Françoise Le Mort, Joseph Oussama Baker, Bérénice Chamel, Hélène Coqueugniot, Olivier Dutour

► To cite this version:

Françoise Le Mort, Joseph Oussama Baker, Bérénice Chamel, Hélène Coqueugniot, Olivier Dutour. Oldest evidence of tuberculosis in the Mediterranean islands: From the mainland to Cyprus. *Tuberculosis*, 2023, 143 (Supplément), pp.102388. 10.1016/j.tube.2023.102388 . hal-04336499v2

HAL Id: hal-04336499

<https://hal.science/hal-04336499v2>

Submitted on 14 Dec 2023

HAL is a multi-disciplinary open access archive for the deposit and dissemination of scientific research documents, whether they are published or not. The documents may come from teaching and research institutions in France or abroad, or from public or private research centers.

L'archive ouverte pluridisciplinaire **HAL**, est destinée au dépôt et à la diffusion de documents scientifiques de niveau recherche, publiés ou non, émanant des établissements d'enseignement et de recherche français ou étrangers, des laboratoires publics ou privés.

1 **Oldest evidence of tuberculosis in the Mediterranean islands: from the mainland to Cyprus**

2

3 *Françoise LE MORT ^a, Joseph Oussama BAKER ^{a,b}, Bérénice CHAMEL ^a, Hélène COQUEUGNIOT ^{c,b},
4 Olivier DUTOUR ^{b,c}

5

6 ^a Univ Lyon, Archéorient (UMR 5133 CNRS/Université Lyon 2), Maison de l’Orient et de la Méditerranée –
7 Jean Pouilloux, 7 rue Raulin, 69365 Lyon cedex 07, France

8 francoise.le-mort@mom.fr, oussamareha@yahoo.com, berenicechamel@gmail.com

9 ^b École Pratique des Hautes Études, PSL Université, 4-14 rue Ferrus, 75014 Paris, France

10 olivier.dutour@ephe.psl.eu

11 ^c UMR 5199 – PACEA, Allée Geoffroy St Hilaire, CS 50023, 33615 Pessac Cedex, France

12 helene.coqueugniot@u-bordeaux.fr

13

14 ***Corresponding author:** Françoise Le Mort, Univ Lyon, Archéorient (UMR 5133 CNRS/Université Lyon 2),
15 Maison de l’Orient et de la Méditerranée – Jean Pouilloux, 7 rue Raulin, 69365 Lyon cedex 07, France

16 francoise.le-mort@mom.fr; Tel: +33 472715843; Fax: +33 478580148

17

18 **Summary**

19

20 Recent studies combining macroscopical observations and microCT analysis strongly suggested the
21 diagnosis of tuberculosis for a child from the site of Khirokitia (Cyprus, 7th - early 6th millennium cal. BC),
22 whose age at death is between 5 and 7 years. Many single primary burials were discovered at the site
23 where the dead (MNI=243) are buried in the same way, whatever their age. Nevertheless, the burial of this
24 child presents a unique feature on the site (a male *Ovis* trophy marking the limit of the burial pit), probably
25 indicating specific attention for this young deceased. This case is the oldest known in the Mediterranean
26 islands and presents a particular interest from a paleoepidemiological point of view. Indeed, considering,
27 on the one hand, the settlement pattern of the island of Cyprus by migrants from the Near East, and on the
28 other hand, the presence of human tuberculosis in the Near East as early as about 10,500 years BP, it is
29 very likely that the prehistoric migrants brought the disease from mainland to Cyprus.

30

31 **Keywords:** Tuberculosis; μ CT; Pre-Pottery Neolithic; Cyprus

32

33 **1. INTRODUCTION**

34

35 The numerous Mediterranean islands have experienced various settlement patterns. They are therefore of
36 great interest for the study of the diffusion of pathogens in the past. Given its proximity to the Levantine
37 and Anatolian coasts as well as the age and the modalities of its settlement, the island of Cyprus offers a
38 unique place to study the interactions of the Neolithic populations of the Near East with their insular
39 environment. Discoveries during recent decades have highlighted the affinities of the first island
40 communities (9th-8th mill. cal. BC) with the mainland [1]. Later, the island's culture appears to follow a
41 distinct trajectory until the emergence, during the 7th millennium cal. BC, of the so-called "Khirokitia
42 Culture" [2, 3, 4, 5]. The case presented here, coming from the site of Khirokitia, showed a pattern of
43 osteological changes strongly suggestive of tuberculosis infection. Although the diagnosis proposed here is
44 morphological and not molecular (the climate of the region is not suitable for long-term preservation of
45 organic components of bone, including DNA) [6, 7], this case is the only probable prehistoric evidence of
46 human tuberculosis in the Mediterranean islands.

47

48 **2. MATERIAL AND METHODS**

49 2.1. Archaeological context

50 The site of Khirokitia, situated in the Larnaka District, at about 6 km directly from the present southern
51 coast of the Cyprus island, was excavated first by P. Dikaios between 1936 and 1946 [8] and second by A. Le
52 Brun from 1977 to 2009 [2, 3, 4, 5]. The occupation of the site, which illustrates the last phase of the Pre-
53 Pottery Neolithic of Cyprus, took place in the second half of the 7th millennium cal. BC and the first half of
54 the 6th millennium cal. BC. In the course of recent excavations, nine stratigraphic levels have been
55 recognized in the east sector (A to H, J) which was occupied first and three (I to III) in the west sector; it also
56 appeared that the boundaries of the village fluctuated during its occupation [2, 3, 4, 5, 9, 10] (Figure 1). The
57 inhabitants of Khirokitia were engaged in farming, herding, hunting and gathering activities [11, 12, 13, 14,
58 15].

59 Many burials were discovered on the site, all of which are primary burials. The bodies lied in a contracted
60 position in burial pits that were dug into the floors of houses while those houses were occupied. The dead
61 are all buried in the same way, whatever their age-at-death. The reappraisal of the skeletons uncovered
62 during the old excavations, and the study of the human remains from recent excavations allowed us to
63 identify at least 243 individuals, ¹ of which 135 are juveniles. Grave goods were only buried with a few of
64 the deceased, usually consisting of a rough or shaped stone or a quern covering part of the body, and/ or
65 one or several stone vessels. Less than a quarter of the burials included a stone placed on the body; stone

¹ In a few cases, when bones from several burials uncovered during Dikaios excavations were mixed together, it was necessary to estimate the minimum number of individuals.

66 vessels are even rarer. Faunal remains or ornaments were deposited in a few burials [8, 2, 3, 16, 4, 17, 18,
67 19, 20].

68

69 2.2. Burial 207

70 The case reported here comes from building S. 84 in the west sector of the site. This building was used from
71 level II to level Ib², that is during the last phase of the occupation of the site; it yielded only one burial. The
72 pit, which contained the remains of an immature individual, is subcircular in shape; dug into the fill of level
73 Ic, it was sealed by the deposits of level Ia [2]. Attempts to date the bones and teeth of this individual were
74 unsuccessful due to poor preservation of collagen³, which is common in prehistoric Cyprus [21, 7, 23]). No
75 14C date is available for level I but dating of a charcoal sample from level II provided a date between 6440-
76 6102 cal. BC. [5]. The body, oriented southwest-northeast, was resting in a contracted position; a shaped
77 stone placed on the deceased before filling the pit was covering the head, the neck and the upper part of
78 the thorax. The north-northwestern limit of the burial pit was marked by a male *Ovis* trophy (Figure 1) [2,
79 24]. The preservation is rather good regarding the relative completeness of the skeleton. On the other
80 hand, the skull is incomplete, the ribs and the vertebrae are fragmentary as well as most of the extremities
81 of the long bones of the lower limbs. However, a set of pathological lesions can be clearly observed on skull
82 vault and long bones (Figure 2).

83

84 2.3. Methods

85 As is usually the case with human and animal remains from prehistoric Cyprus, the skeleton was covered
86 with concretions. The bones were therefore cleaned with a dilute acetic acid solution in order to dissolve
87 the concretions and to allow study of the skeleton [25]. This method gave quite good results. According to
88 dental development [26] the child died between 5 and 7 years. All skeletal remains were carefully
89 examined macroscopically for possible changes due to TB, according to criteria commonly accepted in
90 palaeopathological literature [27, 28, 29]. The skeletal pieces matching with these criteria were thus
91 examined with a binocular lens. Finally, in order to eliminate the possibility of lesions of taphonomic origin
92 and to have access to the inner structure of the bones showing lesions, micro-computed tomography (μ -CT)
93 imaging techniques, which permit non-destructive study of pathologies [30, 31] were applied to a selected
94 set of pieces. The bones were μ -CT scanned with a GE v|tome|x S at a resolution from 15 to 32 μ m, a
95 number of images for a complete rotation between 1650 and 2550, a voltage from 100 to 120 kv, a current
96 between 200 and 250 μ A and a filter of 0.1mm Cu.. The images were reconstructed with the TIVMI® v2.3
97 software based on the HMH (Half-Maximum Height) algorithm [32] extended to 3D [33].

98

² Level I has been subdivided in 3 sub-levels, Ia, Ib and Ic.

³ Personal communication Christine Oberlin, *Centre de Datation par le Radiocarbonate*, Lyon, France.

99 3. RESULTS

100 The skeleton exhibited cranial and infracranial lesions including endocranial lesions, periosteal reaction and
101 porotic lesions (Figure 2).

102

103 Endocranial lesions

104 Extensive endocranial lesions with labyrinth-like pattern occupy large areas on several bones of the vault :
105 (i) right parietal bone, in the middle region and along the sagittal suture, (ii) preserved superior part of the
106 left parietal bone, (iii) squamous part of the occipital bone along the superior sagittal sulcus and on the
107 right cerebral fossa, and (iv) frontal bone along the groove for the superior sagittal sinus (Figure 3). This
108 pattern, firstly described as *serpens endocrania symmetrica* or SES [27] has been recently redescribed [34,
109 35] taking into account a variability of morphological expressions (granulations, vascular imprints,
110 periosteal appositions...). Whatever the terminology used, these lesions have been recognized by the
111 authors of these recent papers as being closely related to a tuberculous infection of the meningeal spaces
112 (tuberculous leptomenigitis). MicroCT analysis of a fragment of the left parietal bone (Figure 4) confirmed
113 that the lesions are not of taphonomic origin: changes are not related to an erosion of the inner table
114 exposing the diploe, but to a pathological process remodelling the inner table. The serpentine aspect is due
115 to irregular bone formation developed on the inner table (spicules observed on sections) due to
116 inflammatory/infectious process developed in the epidural space, in close contact to the dura matter,
117 which is the periosteum of the inner table. Very same pattern was observed on the endocranial surface of
118 Neolithic child from Atlit Yam and molecularly characterized as *M. tuberculosis* [36].

119

120 Infracranial lesions

121 The symmetrical periosteal reaction observed on the tibiae (Figure 5) as well periosteal reaction observed
122 on the left first metatarsal bone are in favor of a secondary hypertrophic pulmonary osteoarthropathy
123 (HPO), which reinforce, associated to the endocranial changes, the diagnosis of tuberculosis [37, 38, 39].

124

125 Porotic lesions

126 *Cribrra orbitalia* (CO) is observed on the right orbital roof (the left one is missing) and *cribra femoris* (CF) are
127 present on the two femurs. MicroCT analysis of a fragment of the right orbit (Figure 6A) and of a proximal
128 fragment of the right femur (Figure 6B) show that these porotic lesions are not of taphonomic origin.
129 Classically attributed to anemia [40], it has been recently suggested that such porotic lesions might result
130 from a focal intraosseous TB infection of the medullary space [41]. Nevertheless, the μ -CT images of the
131 orbit showed wide diploic spaces (Figure 6A), some opened at the orbital roof having a vermiculated aspect
132 and images of the femur do not reveal any focal modification of the metaphyseal trabecular
133 microarchitecture (Figure 6B). Therefore, the pathophysiology of these porosities, which appear in
134 communication with the medullary spaces without any reaction of the trabecular bone remains to be

135 clarified. Moreover, the association of these porotic lesions is not systematic, and their etiology is probably
136 different [42] At this stage, even if a co-occurrence has been recently showed between skeletal porotic
137 lesions of this type and mortality by pulmonary infections including TB [43] no morphological evidence
138 evoking TB can be put forward here.

139

140 4. DISCUSSION

141 The differential diagnosis can be discussed separately for each of the lesions observed: endocranial lesions
142 may possibly result from subdural bleeding, periosteal reactions from a growth spurt and orbital porosities
143 from anemia. However, the association of these skeletal changes observed on this child skeleton allowed us
144 to propose a diagnosis of tuberculosis.

145 It is interesting to note that the burial of this young individual exhibits two particularities while the funerary
146 practices at Khirokitia are characterized by their homogeneity [16, 18]. First, a shaped stone has been
147 placed on the upper part of the body. This is not unique, as shaped stones have been found in 11 other
148 burials, but all of them are adult burials [16, 17]. Second, a male *Ovis* trophy marks the limit of the burial
149 pit, which is unique on the site. The analysis of human-animal relationships in the Pre-Pottery burials in
150 Cyprus [20] presents evidence that suggests a strong relation between humans and domestic ovicaprids.
151 Ovicaprid burials as well as deposition of ovicaprid remains in human burials have been observed at
152 Khirokitia but no other *Ovis* trophy was found in relation to a human burial. It thus seems that specific
153 attention was paid to this young deceased who, during his/her short lifetime, must have shown apparent
154 signs of illness.

155 No bone lesion suggestive of tuberculosis was observed on the other Pre-Pottery sites in Cyprus.
156 Nevertheless, earlier Neolithic Cypriot sites, Kissonerga *Mylothkia*, Shillourokambos and Kalavassos *Tenta*
157 yielded a small number of poorly preserved individuals, as well as the site of Cap Andreas *Kastros* which is
158 contemporary to Khirokitia [44, 45, 46, 47].

159 On the mainland, the earliest evidence of tuberculosis, dating back to the 9th millennium cal BC, are known
160 from two Pre-Pottery Neolithic sites in Syria, Dja'de el Mughara and Tell Aswad [48, 49, 50]. Before these
161 discoveries, the two cases from Atlit Yam (Israel, 8th-7th mill. cal BC) [36] were the oldest known. Probable
162 contemporary cases have also been reported from Abu Hureyra and Tell Ain el Kerkh in Syria [51] and from
163 Ain Ghazal in Jordan (7th mill. cal BC) [52] .

164 As Cyprus was populated by migrants from the mainland, as demonstrated by archaeological [53, 1] and
165 genetic [54, 55] data, these migrants highly likely introduced the disease on the island. Cyprus underwent
166 several waves of migration during the Pre-Pottery Neolithic period [56], but the available data do not
167 currently enable us to date the introduction of the *Mycobacterium complex* on the island. Several
168 hypotheses can be considered. The migrants at the origin of the first island communities (9th-8th mill. cal BC)
169 might have brought it with them but the poor state of preservation and the small number of skeletal

170 remains would not allow us to recognize possible changes due to TB. Another hypothesis would be a later
171 introduction during the 7th mill. cal BC.

172

173 **4. CONCLUSION**

174 This study concerning Pre-Pottery Neolithic Cyprus not only adds a specific case to the growing list of
175 paleopathological cases of TB identified in the Neolithic Near East but also brings new data on the earliest
176 diffusion of infection of human populations by the *Mycobacterium tuberculosis* complex in the
177 Mediterranean. It also raises questions regarding the time of its introduction in Cyprus, but more data is
178 needed to answer them.

179 It has to be noted that the evidence of prehistoric tuberculosis from Cyprus regards an immature individual.
180 The same applies to most of the cases of TB infection observed at Dja'de el Mughara (9 out of 10) [48, 49],
181 and for one of the two affected individuals at Tell Aswad [48, 50] and Atlit Yam [36].

182 The numerous excavations conducted in the Near East produced large quantities of human skeletal
183 remains. Despite this, ancient populations were, until recently, poorly understood in terms of mortuary
184 practices, demography, activity patterns, diet, pathological conditions and genetic relatedness. In the last
185 few decades, the increase of new dynamic field and laboratory investigations has led to a series of
186 important advances in the knowledge of past populations of the Near East [57]. By the same time, the
187 picture of the Pre-Pottery Neolithic in Cyprus has completely changed but many aspects of its fluctuating
188 relationships with the mainland have still to be investigated. Future cross-disciplinary research in the region
189 should lead to a better understanding of the evolution of the health status of these populations and of the
190 spread of infectious diseases during the Neolithization process.

191

192

193 **ACKNOWLEDGEMENTS**

194 This work was financially supported by the French Archaeological Mission at Khirokitia (French Ministry of
195 Foreign Affairs). The first author wishes to express her gratitude to A. Le Brun who has entrusted to her the
196 study of the burials and skeletal remains from Khirokitia. We warmly thank Dr. Solomidou-Yeronomidou,
197 Director of the Department of Antiquities of Cyprus, who kindly gave us permission to export the skeleton
198 to France for analysis. Deep thanks are also given to O. Le Brun for their help during this work and for her
199 assistance in the illustration of this paper. The μ -CT acquisitions were performed using facilities of imaging
200 technical platform of PACEA UMR 5199 and LabEx LaScArBx, Grant/Award Number: ANR-10-LABX-52;
201 Nouvelle-Aquitaine Regional Council. We are also grateful to V. Merle for allowing us to use the
202 microscopical facilities of the ArAr laboratory in Lyon and to V. Regis (University Paris-Cité) for his rereading
203 of English. In addition, we would like to thank the reviewers for their useful comments.

204
205
206
207
208
209
210
211
212
213
214
215
216
217
218
219
220
221
222
223
224
225
226
227
228

229 **REFERENCES**

- 230 [1] Vigne JD, Briois F, Tengberg M. Nouvelles données sur les débuts du Néolithique à Chypre. New Data on
231 the Beginnings of the Neolithic in Cyprus. Paris: Société préhistorique française; 2017.
- 232 [2] Le Brun A. Fouilles récentes à Khirokitia (Chypre), 1977-1981. Études néolithiques 41. Paris: Éditions
233 Recherche sur les civilisations; 1984.
- 234 [3] Le Brun A. Fouilles récentes à Khirokitia (Chypre), 1983-1986. Études néolithiques 81. Paris: Éditions
235 Recherche sur les Civilisations; 1989.
- 236 [4] Le Brun A. Fouilles récentes à Khirokitia (Chypre), 1988-1991. Paris: Éditions Recherche sur les
237 Civilisations; 1994.
- 238 [5] Le Brun A. Fouilles récentes à Khirokitia (Chypre), 1993-2009. Nicosia: Department of Antiquities,
239 Cyprus; 2021.
- 240 [6] Bollongino R, Tresset A, Vigne JD. Environment and excavation: Pre-lab impacts on ancient DNA
241 analyses. C.R. Palevol 2008; 7:91-98. <https://doi.org/10.1016/j.crpv.2008.02.002>
- 242 [7] Goude G, Clarke J, Webb JM, Frankel D, Georgiou G, Herrscher E, Lorentz KO. Exploring the potential of
243 human bone and teeth collagen from Prehistoric Cyprus for isotopic analysis. J Archaeol Sci Rep 2018;
244 22:115–22. <https://doi.org/10.1016/j.jasrep.2018.09.018>
- 245 [8] Dikaios P. Khirokitia. Final report on the excavation of a Neolithic settlement in Cyprus on behalf of the
246 Department of Antiquities 1936-1946. Monograph of the Department of Antiquities of the Government of
247 Cyprus 1. Oxford: University Press; 1953.
- 248 [9] Le Brun A, Daune-Le Brun O. Khirokitia (Chypre) : la taille et les pulsations de l'établissement néolithique
249 pré-céramique, nouvelles données. Paléorient 2009;35:67-76.
- 250 [10] Daune-Le Brun O, Hourani F, Le Brun A. Khirokitia (Chypre, VII^e-VI^e millénaires av. J.-C.), la séquence
251 stratigraphique dans son contexte. In: Vigne JD., Briois F, Tengberg M, editors. Nouvelles données sur les
252 débuts du Néolithique à Chypre. Paris: Société préhistorique française; 2017, p. 217-28.
- 253 [11] Le Brun A. L'économie de Chypre au Néolithique. In: Karageorghis V, Michaelides D, editors. The
254 Development of the Cypriot Economy from the Prehistoric Period to the Present Day. Nicosia: The
255 University of Cyprus and the Bank of Cyprus; 1996, p. 1-16.
- 256 [12] Davis S.J.M. The zoo-archaeology of Khirokitia (Neolithic Cyprus), including a view from the Mainland.
257 In: Guilaine J, Le Brun A, editors. Le Néolithique de Chypre. Athènes: École Française d'Athènes (Bulletin de
258 Correspondance Hellénique, Supplément 43); 2003, p. 253-68.
- 259 [13] Davis S.J.M. The Neolithic mammals from Khirokitia, Cyprus: *stasis* and change on an oceanic Island. In:
260 Le Brun A, editor. Fouilles récentes à Khirokitia (Chypre), 1993-2009. Nicosia: Department of Antiquities,
261 Cyprus; 2021, p. 297-406.
- 262 [14] Pares A, Tengberg M. Etude des pratiques d'exploitation et d'utilisation des ressources végétales du
263 village de Khirokitia (Chypre) au Néolithique précéramique récent chypriote (VII^e-VI^e millénaires av. J.-C. In:

264 Vigne JD., Briois F, Tengberg M, editors. Nouvelles données sur les débuts du Néolithique à Chypre.
 265 Paris: Société préhistorique française; 2017, p. 241-52.

266 [15] Rousou M. Exploitation des ressources végétales et impact environnemental des premiers
 267 peuplements humains à Chypre : approches anthracologique et carpologique. PhD thesis. Muséum
 268 national d'Histoire Naturelle, Paris, France and University of Cyprus, Nicosia; 2022.

269 [16] Le Brun A. Le traitement des morts et les représentations des vivants à Khirokitia. In: Peltenburg E,
 270 editor. Early Society in Cyprus. Edinburgh: Edinburgh University Press; 1989, p. 71-81.

271 [17] Le Mort F. Les sépultures. In: Le Brun A, editor. Fouilles récentes à Khirokitia (Chypre), 1988-1991.
 272 Paris: Editions Recherche sur les Civilisations; 1994, p. 157-98.

273 [18] Le Mort F. Les restes humains de Khirokitia : particularités et interprétations. In: Guilaine J, Le Brun A,
 274 editors. Le Néolithique de Chypre. Athènes: École Française d'Athènes (Bulletin de Correspondance
 275 Hellénique, Supplément 43); 2003, p. 313-25 .

276 [19] Le Mort F. Infant burials in Pre-Pottery Neolithic Cyprus: Evidence from Khirokitia. In: Bacvarov K,
 277 editor. Babies Reborn: Infant/Child Burials in Pre- and Protohistory. British Archaeological Reports
 278 International Series 1852. Oxford: Archaeopress; 2008, p. 23-32.

279 [20] Le Mort F, Vigne JD, Davis SJM, Guilaine J, Le Brun A. Man-animal relationships in the Pre-Pottery
 280 burials at Shillourokambos and Khirokitia (Cyprus, 8th and 7th millennia cal. BC). In: Vila E, Gourichon L,
 281 Choyke AM, Buitenhuis H, editors. Archaeozoology of the Near East VIII. Travaux de la Maison de l'Orient et
 282 de la Méditerranée 49. Lyon: Maison de l'Orient et de la Méditerranée; 2008, p. 219-41.

283 [21] Lange-Badré B, Le Mort F. Isotopes stables du carbone et de l'azote et éléments traces, indicateurs du
 284 régime alimentaire de la population néolithique de Khirokitia (Chypre). In: Camps G, editor. L'homme
 285 préhistorique et la mer. Paris: Éditions du C.T.H.S; 1998, p. 415-26.

286 [23] Voskos I, Vika E. Prehistoric human remains reviewed: Palaeopathology and palaeodiet in Neolithic and
 287 Chalcolithic Cyprus, Limassol district. J Archaeol Sci Rep 2020;102518.
 288 <https://doi.org/10.1016/j.jasrep.2020.102518>.

289 [24] Davis SJM. Khirokitia and its Mammal Remains. A neolithic Noah's Ark. In: Le Brun A, editor. Fouilles
 290 récentes à Khirokitia (Chypre), 1977-1981. Études néolithiques 41. Paris: Éditions Recherche sur les
 291 civilisations; 1984, p. 147-62.

292 [25] Ortiz A, Chamel B. Taphonomic agents in the formation of mortuary deposits: excavation methods and
 293 treatment of human bones at the Pre-Pottery Neolithic sites of Bal'as and Tell Halula (Syria). In: Borrell F,
 294 Bouso M, Gómez A, Tornero C, Vicente O, editors. Broadening Horizons 3, 3rd Conference of Young
 295 Researchers Working in the Ancient Near-East. Barcelone; 2010, p. 41-56.

296 [26] Moorrees CFA, Fanning EA, Hunt Jr. EE. Age variation of formation stages for ten permanent teeth.
 297 J Dent Res 1963;42:1490-502.

298 [27] Hershkovitz I, Greenwald CM, Latimer B, Jellema LM, Wish-Baratz S, Eshed V, Dutour O,
299 Rothschild BM. Serpens Endocrania Symmetrica (SES): a new term and a possible clue for identifying
300 intrathoracic disease in skeletal populations. *Am J Phys Anthropol* 2002;118:201-16.

301 [28] Lewis M. *Paleopathology of Children*. London, San Diego, Cambridge, Oxford: Academic Press; 2018.

302 [29] Roberts CA, Buikstra JE. Bacterial Infections. In: Buikstra JE, editor. *Ortner's Identification of*
303 *Pathological Conditions in Human Skeletal Remains*. London, San Diego, Cambridge, Oxford: Academic
304 Press; 2019, p. 321-439.

305 [30] Coqueugniot H, Dutailly B, Dutour O. The third dimension in paleopathology: how can three-
306 dimensional imaging by computed tomography (3D CT) bring an added-value to retrospective diagnosis? *Int*
307 *J Osteoarchaeol* 2020;30:538-50. <https://doi.org/10.1002/oa.2881>.

308 [31] Coqueugniot H, Dutailly B, Desbarats P, Boulestin B, Pap I, Szikossy I, Baker O, Montaudon M,
309 Panuel M, Karlinger K, Kovács B, Kristóf LA, Pálfi G, Dutour O. Three-dimensional imaging of past skeletal
310 TB: from lesion to process. *Tuberculosis* 2015; 95:S73–S79. <https://doi.org/10.1016/j.tube.2015.02.004>.

311 [32] Spoor CF, Zonneveld FW, Macho GA. Linear measurements of cortical bone and dental enamel by
312 computed tomography: applications and problems. *Am J Phys Anthropol* 1993;91:469–84.

313 [33] Dutailly B, Coqueugniot H, Desbarats P, Gueorguieva S, Synave R. 3D surface reconstruction using HMH
314 algorithm. *Proceedings of IEEE International Conference on Image Processing 2009*: 2505-8.

315 [34] Spekker O, Hunt DR, Paja L, Molnár E, Gy P, Schultz M. Tracking down the White Plague: The skeletal
316 evidence of tuberculous meningitis in the Robert J. Terry Anatomical Skeletal Collection. *PLoS ONE* 2020;
317 15(3):e0230418. <https://doi.org/10.1371/journal.pone.0230418>

318 [35] Spekker O, Hunt DR, Berthon W, Molnár E, Pálfi G. Insights into the diagnostic efficacy and
319 macroscopic appearance of endocranial bony changes indicative of tuberculous meningitis: Three example
320 cases from the Robert J. Terry Anatomical Skeletal Collection. *Int J Osteoarchaeol* 2022;32(2):444–56.
321 <https://doi.org/10.1002/oa.3079>.

322 [36] Hershkovitz I, Donoghue HD, Minnikin DE, Besra GS, Lee OY, Gernaey AM, Galili E, Eshed V,
323 Greenblatt CL, Lemma E, Bar-Gal GK, Spigelman M. Detection and molecular characterization of 9,000-year-
324 old *Mycobacterium tuberculosis* from a Neolithic settlement in the Eastern Mediterranean. *PLoS One* 2008;
325 3,10:e3426. <https://doi.org/10.1371/journal.pone.0003426>.

326 [37] Assis S, Santos AL, Roberts C A. Evidence of hypertrophic osteoarthropathy in individuals from the
327 Coimbra Skeletal Identified Collection (Portugal). *Int J Paleopathol* 2011;1(3–4):155–63.
328 <https://doi.org/10.1016/j.ijpp.2012.02.009A>

329 [38] Kelly P, Manning P, Corcoran P, Clancy L. Hypertrophic osteoarthropathy in association with pulmonary
330 tuberculosis. *Chest* 1991;99(3):769–70. <https://doi.org/10.1378/chest.99.3.769>

331 [39] Masson M, Molnár E, Donoghue H D, Besra G S, Minnikin DE, Wu HHT, Lee OYC, Bull ID, Gy P.
332 Osteological and biomolecular evidence of a 7000-year-old case of hypertrophic pulmonary osteopathy

333 secondary to tuberculosis from Neolithic Hungary. PLoS ONE 2013; 8(10):e78252.
334 <https://doi.org/10.1371/journal.pone.0078252>

335 [40] Walker PL, Bathurst RR, Richman R, Gjerdrum T, Andrushko VA. The causes of porotic hyperostosis and
336 cribra orbitalia: a reappraisal of the iron-deficiency-anemia hypothesis. *Am J Phys Anthropol*
337 2009;139(2):109-25. <https://doi.org/10.1002/ajpa.21031>. PMID: 19280675.

338 [41] Blondiaux J, de Broucker A, Colard T, Haque A, Naji S. Tuberculosis and survival in past populations: A
339 paleo-epidemiological appraisal. *Tuberculosis* 2015; 95:S93-S100.
340 <https://doi.org/10.1016/j.tube.2015.02.002>.

341 [42] Schats R. Cribrotic lesions in archaeological human skeletal remains. Prevalence, co-occurrence, and
342 association in medieval and early modern Netherlands. *Int J Paleopath* 2021; 35:81-9.
343 <https://doi.org/10.1016/j.ijpp.2021.10.003>.

344 [43] Gomes RAMP, Petit J, Dutour O, Santos AL. Frequency and co-occurrence of porous skeletal lesions in
345 identified non-adults from Portugal (19th to 20th centuries) and its association with respiratory infections
346 as cause of death. *Int J Osteoarchaeol* 2022;32(5):1061–72. <https://doi.org/10.1002/oa.3132>

347 [44] Fox SC, Lunt DA, Watt ME. Human remains. In: Peltenburg E, editor. The colonisation and settlement of
348 Cyprus. Investigations at Kissonerga-Myliouthkia, 1976-1996. *Studies in Mediterranean Archaeology* 70.4.
349 Sävedalen: Paul Åströms Förlag; 2003, p. 43-7.

350 [45] Le Mort F, Harter-Lailheugue S, Bouchet F. Biologie de la population humaine. In: Guilaine J, Briois F,
351 Vigne JD, editors. Shillourokambos, un établissement néolithique précéramique à Chypre. Les fouilles du
352 secteur 3. Paris: CNRS Éditions; 2021, p. 695-710.

353 [46] Moyer CJ. Human burials. In: Todd IA, editor. Vassilikos Valley project 7: Excavations at Kalavassos-Tenta,
354 volume II. *Studies in Mediterranean Archaeology* 71.7. Jonsered: Paul Åströms Förlag; 2005, p. 1-15.

355 [47] Massei Solivères O. Étude des crânes du Cap Andreas-Kastros, Appendice II. In: Le Brun A, editor. Un site
356 néolithique précéramique en Chypre : Cap Andreas-Kastros. Paris: Éditions Recherche sur les Civilisations;
357 1981, p. 83-7.

358 [48] Baker O, Lee OYC, Wu HHT, Besra GS, Minnikin DE, Llewellyn G, Williams CM, Maixner F, O'Sullivan N,
359 Zink A, Chamel B, Khawam R, Coqueugniot E, Helmer D, Le Mort F, Perrin P, Gourichon L, Dutailly B, Palfi G,
360 Coqueugniot H, Dutour O. Human tuberculosis predates domestication in ancient Syria. *Tuberculosis* 2015;
361 95:S4-S12. <https://doi.org/10.1016/j.tube.2015.02.001>.

362 [49] Baker O, Chamel B, Coqueugniot E, Khawam R, Stordeur D, Perrin P, Palfi G, Gourichon L, Coqueugniot H,
363 Le Mort F, Dutour O. Prehistory of human tuberculosis: Earliest evidences from the onset of animal husbandry
364 in the Near East. *Paléorient* 2017; 43:35-52.

365 [50] Baker JO, Chamel B, Dutour O. New New Paleopathological Evidence of Tuberculosis in Child Skeletal
366 Remains from Tell Aswad (8,730-8,290 cal. BC, southern Syria). *Paléorient* 2021; 47:97-108.
367 <https://doi.org/10.4000/paleorient.926>.

- 368 [51] Chamel B. Bioanthropologie et pratiques funéraires des populations néolithiques du Proche-Orient :
369 l'impact de la Néolithisation (étude de sept sites syriens - 9820-6000 cal. BC). PhD thesis, Université Lyon 2 ;
370 2014.
- 371 [52] El-Najjar M, Al-Sarie I, Al-Shiyab A. Cases of tuberculosis at 'Ain Ghazal, Jordan. *Paléorient* 1996; 22:123-
372 8.
- 373 [53] Vigne JD, Briois F, Zazzo A, Willcox G, Cucchi T, Thiébault S, Carrère I, Franel Y, Touquet R, Martin C,
374 Moreau C, Comby C, Guilaine J. First wave of cultivators spread to Cyprus at least 10,600 y ago. *Proc Natl*
375 *Acad Sci USA* 2012; 109:8445-9. <https://doi.org/10.1073/pnas.1201693109>
- 376 [54] Voskarides K, Mazières S, Hadjipanagi D, Di Cristofaro J, Ignatiou A, Stefanou C, King RJ, Underhill PA,
377 Chiaroni J, Deltas C. Y-chromosome phylogeographic analysis of the Greek-Cypriot population reveals
378 elements consistent with Neolithic and Bronze Age settlements. *Investig Genet* 2016; 7,1.
379 <https://doi.org/10.1186/s13323-016-0032-8>)
- 380 [55] Fernández E, Pérez-Pérez A, Gamba C, Prats E, Cuesta P, Anfruns J, Molist M, Arroyo-Pardo E,
381 Turbón D. Ancient DNA Analysis of 8000 B.C. Near Eastern Farmers Supports an Early Neolithic Pioneer
382 Maritime Colonization of Mainland Europe through Cyprus and the Aegean Islands. *PLOS Genet*
383 10(6):e1004401. <https://doi.org/10.1371/journal.pgen.1004401>
- 384 [56] Vigne JD, Cucchi T, Rousou M, Bailon S, Carrère I, Devillers B, Douché C, Gourichon L, Hadjikoumis A,
385 Mylona P, Papayianni K, Parès A, Tengberg M, Zazzo A, Guilaine J, Briois F. Historical dynamics of the
386 human-environment interactions in Cyprus during the 12th-10th millennia cal. BP: The last 30 years
387 contributions of the Amathous area (Limassol district). *J Archaeol Sci Rep* 2023; 50:104049.
388 <https://doi.org/10.1016/j.jasrep.2023.104049>
- 389 [57] Le Mort F, Tillier AM. Recent trends in Near Eastern and Cypriot human bioarchaeology. *ArchéOrient -*
390 *Le Blog*, April 15, 2022. <https://archeorient.hypotheses.org/18271>

391

392

393 **AUTHORS CONTRIBUTIONS SECTION**

394 F. Le Mort, H. Coqueugniot and O. Dutour wrote the paper. All the authors contributed to the study of the
395 skeleton. MicroCT analysis was performed by H. Coqueugniot.

396

397

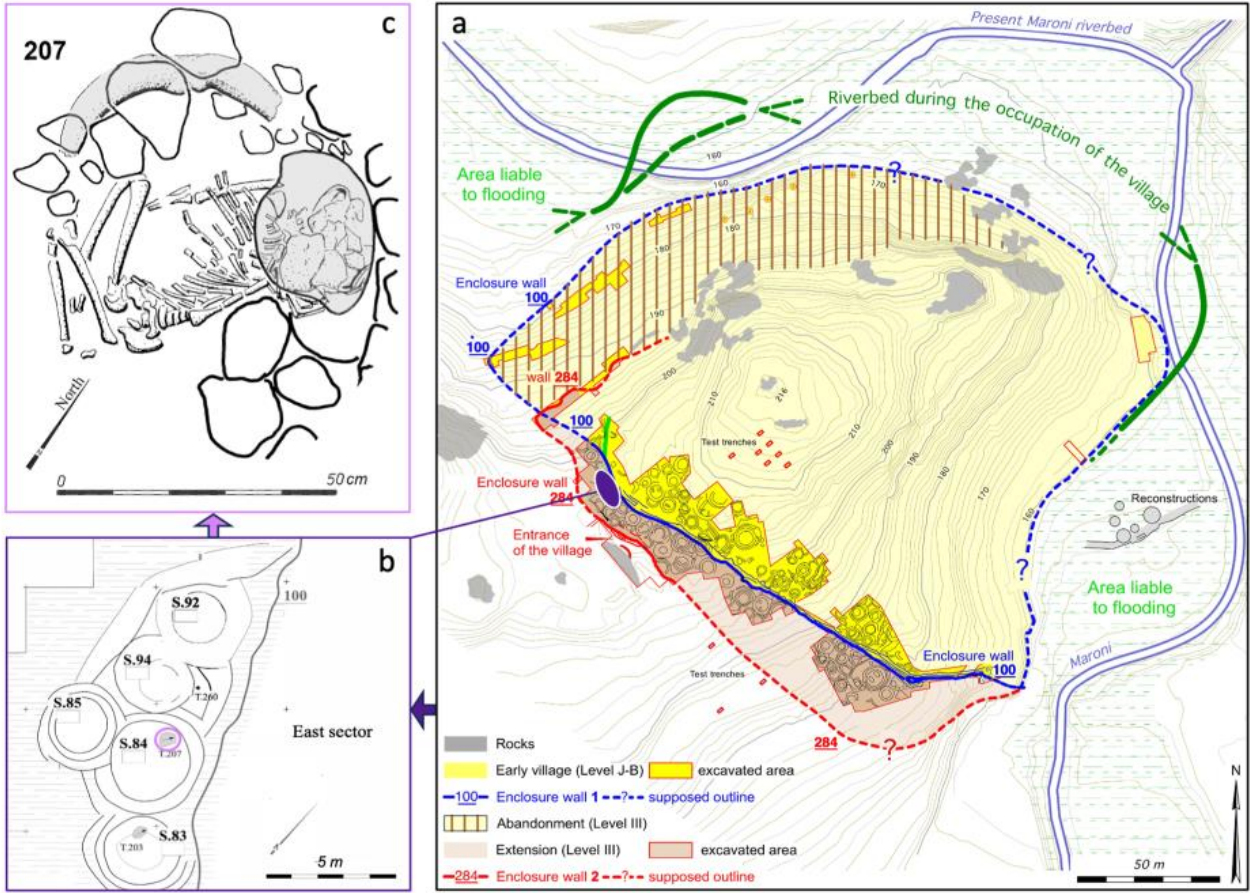
398

399

400

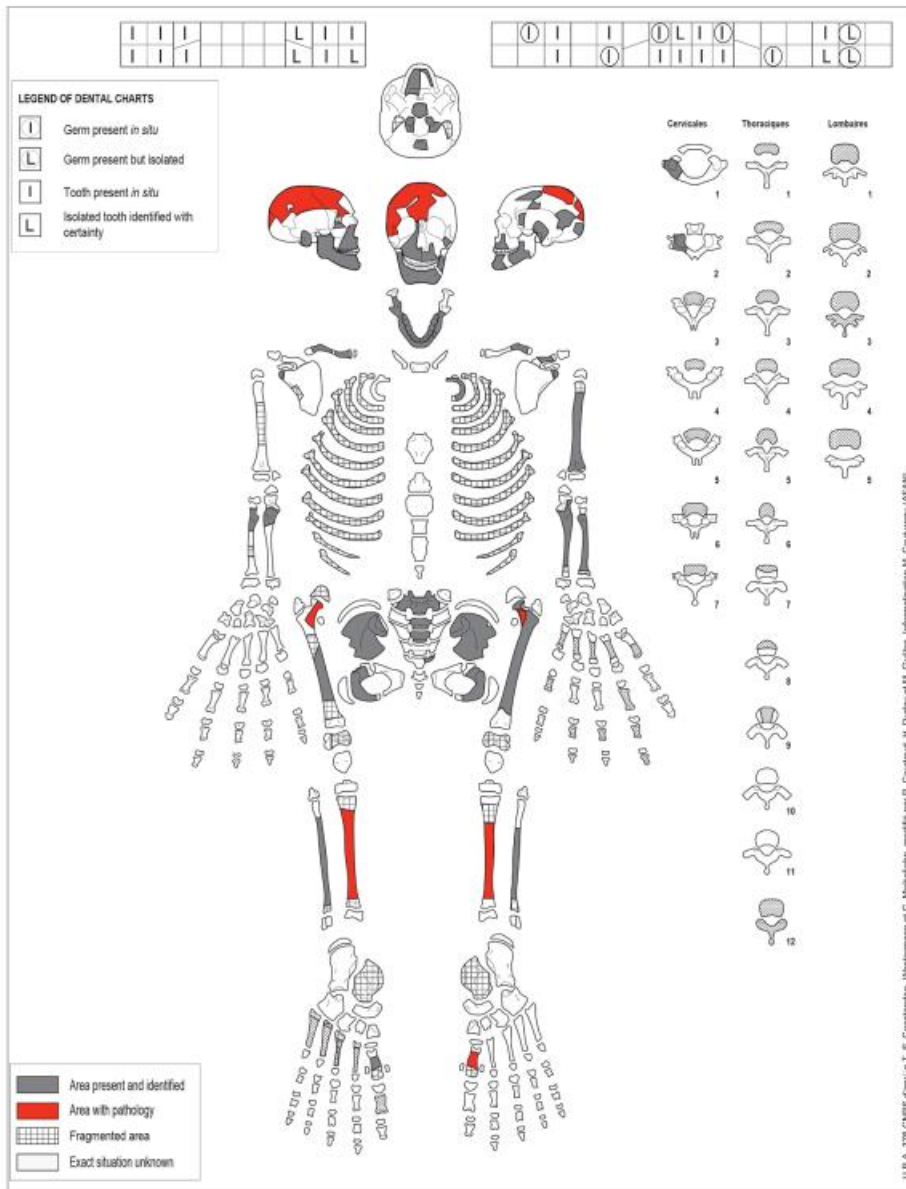
401

402




403
404
405
406
407

Figure 1.

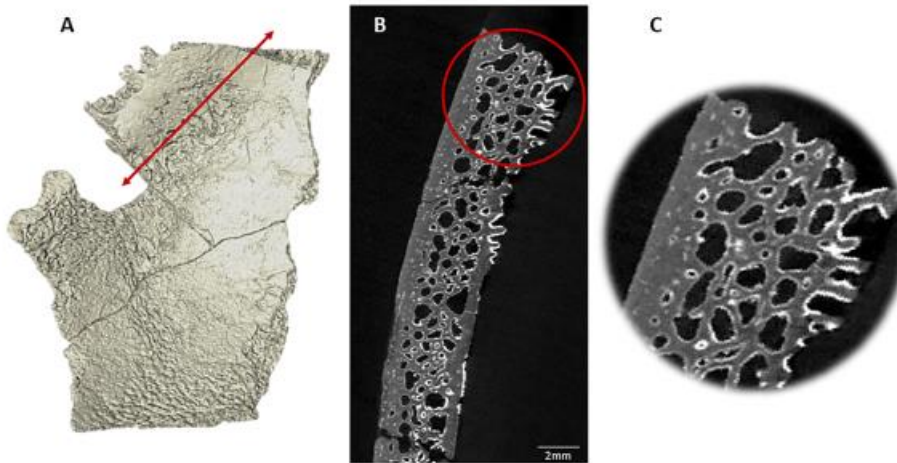


408
409
410

Figure 2.



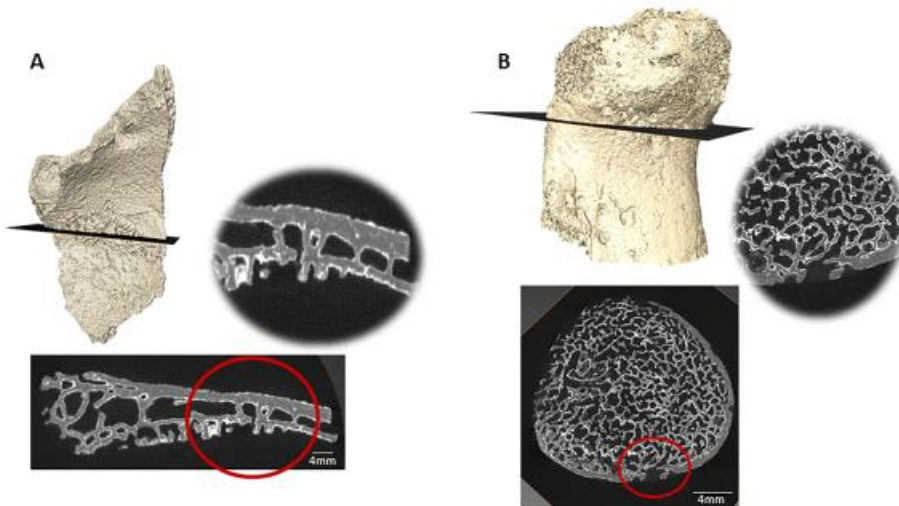
412
413 **Figure 3**
414
415
416



417
418 **Figure 4**
419
420



421
422 **Figure 5**
423
424
425



426 **Figure 6**

427 **CAPTIONS TO ILLUSTRATIONS**

428 Figure 1: Khirokitia. a) general plan of the settlement; b) plan of leved Ib in the area in purple on the
429 general plan, with the location of burial 207 in structure 84; c) child burial 207 (© French Archaeological
430 Mission at Khirokitia).

431 Figure 2: Preservation sheet of the individual from burial 207. Lesions are indicated in red.

432 Figure 3: *Serpens endocrania symmetrica*: a) on the frontal and right parietal bone; b) on the left parietal
433 bone; c) on the occipital bone; enlargement on the right (d) and left (e) parietal bone

434 Figure 4: A. *Serpens endocrania symmetrica* on the endocranial surface of a parietal. The red arrow
435 indicates the location of the μ CT section.

436 B. μ CT section showing the "postage stamp" indentation of the inner bone table.

437 C. Detail of the indentation pattern.

438 Figure 5: Periosteal reaction on the lateral side of the left tibia.

439 Figure 6: A. *Cribra orbitalia* showing a vermiculated pattern. μ CT section reveals widening of diploic spaces.
440 Some of them are opened at the orbital roof surface.

441 B. *Cribra femoris* on the anterior part of femoral neck. μ CT section at the *cribra femoris* area shows no focal
442 changes in the metaphyseal trabecular microarchitecture. Detail of the microarchitecture reveals that the
443 porosities communicate with the medullary spaces without any reaction of the trabecular bone.

444

445

446

447

448